



Propeller Flaps

Nikhil Panse¹ Ankur Karanjkar¹

¹Department of Plastic & Reconstructive Surgery, B. J. Government Medical, College and Sassoon Hospital, Pune, Maharashtra, India

Indian J Plast Surg 2022;55:321–330.

Address for correspondence Nikhil Panse, MCh, DNB, Department of Plastic and Reconstructive Surgery, B.J.G.M.C. and Sassoon General Hospital, Pune, Maharashtra 411001, India (e-mail: nikhil.panse@rediffmail.com).

Abstract

A propeller flap is an islanded flap that reaches the recipient site through an axial rotation around its vascular axis. The degree of rotation varies from 90 degrees to 180 degrees. It is a highly reliable local reconstructive option. These flaps are simple, single-stage, easy to harvest, and not constrained by routine length-to-width ratios. Since their introduction, the technique has continued to evolve and more applications for the use of propeller flaps are being explored. In spite of their growing use in clinical practice in recent years, many reconstructive surgeons are unaware of their versatility, unsure of their safety, and apprehensive about using propeller flaps confidently. This article aims at understanding the nomenclature, key principles, biogeometry and planning, operative technical details, applications, and complications of propeller flaps.

Keywords

- ▶ propeller flap
- ▶ local flap
- ▶ perforator flap
- ▶ biogeometry
- ▶ post-burn reconstruction
- ▶ head and neck flaps
- ▶ extremity flaps

Introduction

The reconstruction of a tissue defect with local flaps is always difficult for the reconstructive surgeon. As anatomical and physiological understanding of tissue vascularity is evolving, innovative local flap designs such as “propeller flaps” are possible. The propeller flap is a local islanded flap, designed like a propeller blade with two blades of unequal length and the nourishing vascular pedicle forming the pivot point.¹ When the blades are switched, one arm comfortably covers the defect, and the other covers the donor defect partially or completely. The potential of this flap to rotate up to 180 degrees with the ability to recruit tissues from adjoining non-traumatized areas makes this an extremely versatile flap for a variety of reconstructions.^{1–3} Propeller flap is the iteration of flap design that began with random pattern flaps. Because of its fairly recent inclusion in the armamentarium of reconstructive surgeons, certain mistrust has overshadowed the safety of propeller flaps in clinical practice. This study aims to describe the evolution, key principles, and

biogeometry, operative technique, and clinical applications of the propeller flap.

History and Evolution

Katsaros first introduced the concept of propeller flaps in 1982. He used an islanded tensor fascia lata flap propelled through 180 degrees to cover a chest wall defect.⁴ Hyakusoku et al in 1991⁵ used a random subcutaneous pedicle as a pivot with two lobes and published the propeller flap method in the British Journal of Plastic Surgery.⁶ Later, further modifications such as the multilobed propeller flap and the pinwheel flap were introduced.^{7–9} Hallock used the term “propeller flap” to define a fasciocutaneous flap based on a skeletonized perforator vessel and rotated by 180 degrees. This gave rise to the concept of perforator propeller flaps.¹⁰ Teo greatly contributed to the definition, surgical technique, and application of perforator propeller flaps. Ever since their introduction, propeller flaps have been modified, re-designed, and their clinical applications are still evolving.^{11–13}

article published online
July 18, 2022

DOI <https://doi.org/10.1055/s-0041-1740529>.
ISSN 0970-0358.

© 2022. Association of Plastic Surgeons of India. All rights reserved. This is an open access article published by Thieme under the terms of the Creative Commons Attribution-NonDerivative-NonCommercial-License, permitting copying and reproduction so long as the original work is given appropriate credit. Contents may not be used for commercial purposes, or adapted, remixed, transformed or built upon. (<https://creativecommons.org/licenses/by-nc-nd/4.0/>)
Thieme Medical and Scientific Publishers Pvt. Ltd., A-12, 2nd Floor, Sector 2, Noida-201301 UP, India

Nomenclature and Terminologies

The Advisory Panel of the First Tokyo Meeting on Perforators and Propeller Flaps 2009 reached a terminology consensus on propeller flaps.¹⁴

A propeller flap is defined as an "island flap that reaches the recipient site through an axial rotation." The axial rotation differentiates it from other pedicled flaps. While categorizing it as a propeller flap, three components are considered: type of nourishing pedicle, degree of skin island rotation, and artery of origin of perforator vessel/cluster of perforators. However, if the source vessel is not confirmed (as in free-style design), then the anatomical region or underlying muscle is specified^{14,15} (– Table 1).

Preoperative Considerations

Preoperative clinical examination and doppler studies give us fair guidelines regarding appropriate patient selection for executing a propeller flap. Potential risk factors such as

tobacco consumption in any form, systemic diseases such as diabetes mellitus (DM), collagen vascular disease or peripheral vascular disease (PVD), should be noted. The opinion is divided on the impact of these factors on the complication rate. Innocenti et al³ found no significant association between complications and these comorbidities in their study of lower extremity propeller flaps. They also did not identify any significant risk factors pertaining to defects, flap size, or arc of rotation.³ However, Quaba et al¹⁶ and Jakubietz et al¹⁷ reported that obvious contraindications for local perforator flaps are patients with PVD and/or insulin-dependent DM. In our experience, if there is a good perforator intraoperatively along with a good Doppler signal, the comorbidities do not have high risks of complications.^{18,19} However, multicenter studies with large sample sizes will be necessary to determine which patients and comorbidities are at higher risk of complications.

The location of the defect and its reconstructive requirements should be considered. The area surrounding the defect should be examined for any signs of inflammation, scars, or

Table 1 Classification and nomenclature of Propeller Flaps

Basis of classification			
Type of pedicle	Perforator pedicled propeller flaps (PPP)	Skeletonised perforator act as a pivot point. Axial rotation of 180° is possible. It is the most commonly used propeller flap. Example – Peroneal artery perforator 180° propeller flap.	
	Non-perforator pedicled propeller flaps	Subcutaneous-pedicled propeller flaps (SPP flaps)	Cluster of small perforators in underlying subcutaneous tissue act as the pivot point. Perforators are not skeletonised. Safe rotation of flap is up to 90°. Example – SPP flaps for post burn contractures.
		Vascular-pedicled propeller flaps (VPP flaps) or axial propeller flap	Pivot point for rotation is the base of axial vascular pedicle and not on a perforator itself. It is also known as an axial propeller flap. Safe rotation of reliable large skin paddle up to 180° is possible. Examples - Radial artery based flap, Facial artery based flap, Supratrochlear artery based flap, Lingual artery based flap.
Position of pedicle	Central axis propeller flap	Location of nourishing pedicle is at the centre. Central location of pedicle imparts homogeneous blood supply to skin paddle, thus enhancing reliability of flap. Mainly indicated for coverage of two adjacent defects.	
	Acentric axis propeller flap	Pivot point for rotation arc of the flap is at its periphery. These flaps are very useful to cover defects, located in areas distant from regions rich in perforators.	
Modification of propeller flap	Composite propeller Flap	When the skin island of flap contains more than one single tissue such as tendon, nerve or underlying cartilage and is propelled in defect through 180° rotation for functional reconstruction, it is considered as a composite propeller flap	
	Supercharged propeller flap	The supercharged propeller flap is a modification of the perforator pedicled propeller flap. An extra pedicle can be introduced by supercharging if a lengthy propeller flap is required.	
	Multi-lobed propeller flap	Flaps with multiple lobes with axial rotation.	

irradiation. Propeller flaps are to be avoided in the presence of subdermal and suprafascial plexus injuries to the surrounding tissues.

Preoperative identification of the perforator with handheld Doppler (8–10 MHz) is desirable. In the upper extremity, the deep vessels become superficial distally, and Doppler specificity decreases. However, success in detecting good perforators increases with an operator's experience.^{20,21} Various methods described for the identification of perforators such as duplex ultrasound, color Doppler, arteriography, magnetic resonance angiography, and high-resolution computed tomography are more sensitive and can provide additional information. In our experience, the handheld Doppler probe is easy, simple, cost-effective, and adequate for the identification of perforators and satisfactorily correlates with the intraoperative "good" perforator."

Flap Biogeometry, Physiology, and Planning

Propeller flaps are generally raised as long and narrow flaps and are not limited by the rules of length-to-width ratios. The perforator is eccentrically placed, and these flaps are to be considered as two flaps on either side of the perforator, and not as a single flap. For example, if we have a flap of width "x" and length "5x," and we have an eccentrically located perforator entering the flap at a distance of "3x," we essentially have two flaps with ratios of 1:2 and 1:3^{2,22} (► Fig. 1).

When we consider flap physiology, the available literature on the vascular territories supplied by a single perforator is based on cadaver and injection studies.^{3,23,24} Intraoperatively, there are a lot of dynamic changes that occur after the ligation of extra perforators. There is an opening of adjacent potential vascular territories that assures an optimal blood supply to the flap by recruiting cutaneous territory beyond the anatomic territory of an individual perforator.³ It is easy to understand that the larger the perforator dimensions, the higher the perfusion pressure, and the higher its potential to recruit adjacent perforasome territories.^{13,25} These changes are in addition to systemic factors and extrinsic factors such

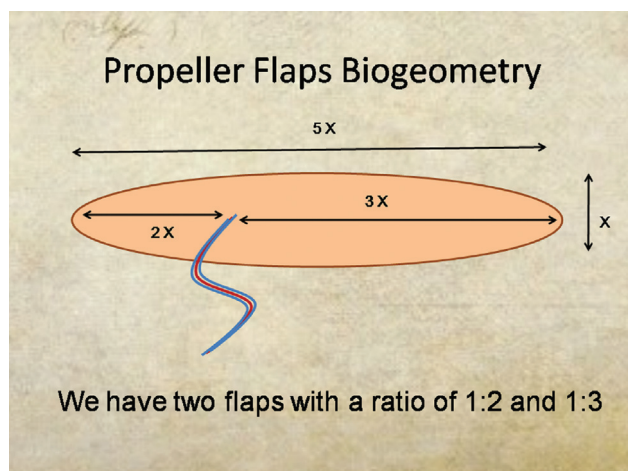


Fig. 1 Propeller flap biogeometry.

as operation theater temperature and hypothermia, among other things. Therefore, the answer to how much flap can be safely harvested on a single perforator in a clinical setting still eludes us, and can be known only after the flap harvest is complete and the tourniquet is released.^{22,26–29}

Flap design: The flap planning and surgical technique have been fairly well established with minor variations from various authors.^{2,7,29–34} We identify the most favorable perforator with a handheld Doppler. To mark the length of the flap, the distance from the perforator to the distal edge of the defect is noted. Around 1 to 2 cm is added to it, depending on the thickness of the tissues, to mark the proximal edge of the flap. It should permit comfortable reach of the flap into the defect without any tension when axially rotated. Free-styling of the design is considered depending on the requirements of the defect. The width of the flap is planned in accordance with the width of the defect when a 180-degree rotation of the flap is anticipated. It is important that the perforator, when it enters the flap, is equidistant from the lateral edges of the flap so that there is no excessive sideways traction on the perforator during closure. The design of the flap is always confirmed and altered if necessary, after intraoperative identification of the suitable perforator.

Surgical Steps and Technical Considerations

Propeller flap harvest must be done under adequate exposure and illumination with appropriate magnification. The exploratory incision is generally parallel to the long axis of the vessel on whose perforators the propeller flap is being planned. Exploratory incisions should be liberal to identify multiple perforators in the area of interest. It is fashioned in a manner so that if suitable perforators are not identified, it can be used to gain access to the underlying vessel for micro-anastomosis or the same incision can be used to design some local flap. It is desirable to avoid damage to the cutaneous nerves during the exploratory incision. For the lower limb, incisions must avoid transgression over the subcutaneous border of the tibia and the tendoachilles region^{12,13,22} (► Video 1).

Video 1

Technique of harvest of lower limb propeller flap on perforators of posterior tibial artery. Online content including video sequences viewable at: <https://www.thieme-connect.com/products/ejournals/html/10.1055/s-0041-1740529>.

For extremity harvest of propeller flaps, a partially exsanguinated limb gives the advantage of easy identification of the perforator and its venae comitantes.¹²

The approach to the perforator can be either subfascial or suprafascial. The authors prefer the subfascial approach because it is very convenient to identify the perforator. In the suprafascial approach, the dissection is a bit tedious, but

as there is no breach of fascia, the donor site morbidity is less conspicuous.^{20,22,28,35-37}

Assessment of the Perforator

More often than not, after handling and dissection of the perforator, the perforator goes into spasm. Therefore, the first sighting of the perforator is the best opportunity to assess the suitability of the perforator.

The good quality perforator should be of adequate caliber and associated with two venae comitantes to sustain the vascularity of the flap. Two venae comitantes are necessary because once the flap is axially rotated through 180 degrees, one of the veins gets kinked because of the twist, and the other one opens up. The surrounding fascia and the tissues must be non-contused and free of the zone of trauma.

The perforator must be assessed in terms of proximity to the defect. A perforator that is too near to the defect might be encased in scar tissue or granulation tissue and can be fragile. These perforators lack thromboresistant properties and are more likely to go into spasm even with a minimal amount of dissection.^{38,39} Perforators that are far away from the defect make the flap unnecessarily long and risky. Thus, the appropriate perforator must be selected accordingly. The course and orientation of the perforator into the flap must be assessed. The intraflap axially of the perforator must be along the long axis of the flap.

Technical tip: We should be ready to change our plan intraoperatively if a suitable perforator is not found in the exploratory incision and near the defect.

The pulsatility of the perforator is another important criterion to be assessed. However, because the flap is being dissected under a tourniquet, it is not possible to assess the pulsatility at this point of time. It must be assessed at the end of the dissection after the tourniquet is released. The beauty of propeller flaps is that we are not concerned with the underlying anatomical variations. If we have a good quality perforator, we can base our flap on it, irrespective of its source vessel.

Once the best perforator is identified intraoperatively, we commit to the flap design. It is generally accepted that the longer the pedicle, the wider is the safe arc of rotation.^{3,36,40} Wong et al^{29,41} reported that for better survival of the propeller flap, the perforator should be at least 1 mm in diameter and should be dissected for a length of at least 3 cm. However, excessive dissection to get a longer pedicle also increases the chance of traction injury and perforator going into spasm. In our experience, we feel that a perforator length of 1 to 1.5 cm is adequate, and one does not need to dissect the perforator to the source vessel. There is often a layer of loose connective tissue surrounding the perforator, and this layer can be easily freed from the surrounding tissue by blunt dissection.⁴²

The perforator dissection is performed meticulously in a non-traumatic fashion, with constant irrigation with lignocaine or papaverine solution to minimize the spasm. Particular attention must be paid to the fibrous strands around the venae comitantes, because the low-pressure venae comitantes are most susceptible to extrinsic compression.¹²

Bipolar cautery is used judiciously for absolute hemostasis. Excessive traction on the tiny perforator by an untrained assistant can lead to irreversible injury to the perforator and must be avoided at all costs.

Technical tip: Perforator can be gently dissected by traction and counter traction of the surrounding tissues, which minimizes the handling and thereby spasm of the perforator (►Video 1). As a general rule, all perforators that will not be used to axially rotate the flap must be transected away from the fascia. This can be of help if the need for supercharging arises. By the time the flap harvest is complete, the perforator has almost always gone into spasm. It is imperative that the spasm is relieved by irrigation with lignocaine/papaverine to produce vasorelaxation of the perforator.

Technical tip: While taking intraoperative photographs, due care must be taken that the weight of the flap does not drag on the perforator and cause injury (►Fig. 2).

Anesthesia alters the normal thermoregulatory mechanisms. If needed, to prevent hypothermia and subsequent spasm of the tiny perforators, the temperature of the operating theater should be raised. Warming blankets can be used, with intravenous fluids warmed prior to administration.⁴³

Once the flap harvest is complete, the tourniquet is released, and the flap is permitted to perfuse. Once the flap is perfused adequately for a period of 10 to 12 minutes, it is axially rotated into the defect.

Technical tip: The flap should not be axially rotated into the defect unless there is complete vasorelaxation and the perforator starts to pulsate.

The flap is rotated from the side, where minimal rotation is required. If flap rotation of 180 degrees is required, the flap is rotated from both directions, and the side which causes optimal and comfortable placement of the venae comitantes with favorable perfusion is finalised.^{12,30}

Technical tip: It is always prudent to note the direction of rotation in the operative notes in case postoperative derotation is required.

The first few sutures for closure are placed along the sides of the flap near the perforator entry point. This prevents traction on the perforator while suturing the rest of the flap.

It is advisable to take a few crucial sutures over the donor site before the tourniquet is released. After the tourniquet is released, edema sets in, and linear closure of the donor site becomes difficult.

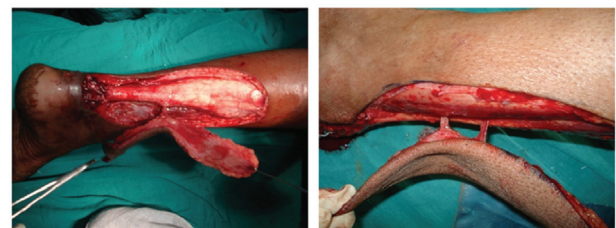

Fig. 2 Intraoperative photography tips.

Avoiding Complications in Postoperative Period

It is important to avoid tight circumferential bandaging proximal to, or over the flap. Window dressing to ensure visibility of the entire flap is important. Full exposure of the flap ensures early detection of marginal discoloration or underlying hematoma.

Postoperatively, all our flaps are monitored by experienced staff. We do not have experience with sophisticated flap monitoring devices; however, we believe that clinical observation with occasional needle scratches and Doppler monitoring are reliable methods of postoperative monitoring. For propeller flaps, the most common postoperative problem is venous congestion because of torsion-prone thin-walled veins. In the postoperative period, all propeller flaps have a tendency for minimal congestion, which gradually relieves over time as the veins adapt to torsional changes and flow is stabilized. It is important to differentiate between transient congestion and true venous insufficiency. True venous insufficiency must be promptly identified and managed to avoid compromise of the flap. If the color changes of venous congestion are limited to the terminal portion of the flap, its evolution and advancement are noted in the case of true venous insufficiency. If the entire flap appears to be minimally congested, as is almost always seen, it is prudent to observe the flap patiently for a few minutes. The increasing darkness of the color of blood and the increased briskness of the bleeding on pinprick are

pointers to true advancing venous insufficiency. In such cases, venous supercharging or temporary derotation of the flap can be considered. Leeches have also been used with limited success in propeller flaps.⁴⁴

Chen et al. demonstrated good outcomes with temporary derotation of a congested flap along with de-epithelization of skin and debulking of fat. It decreases metabolic demand on the vasculature.⁴⁵

Arterial insufficiency is rarely encountered in propeller flaps. If the flap remains pale in the postoperative period, it is almost always due to spasm of the perforator. All maneuvers to relieve the spasm are helpful in most cases. If the flap continues to remain pale, it can be derotated to its original position for a few days before rotating it again.⁴⁶⁻⁴⁸

Total flap necrosis is very rare. Partial flap necrosis is fairly common and is often limited to the skin.⁴⁶ Aggressive debridement is to be avoided, and even flaps that appear to be mottled in the initial postoperative period tend to settle well in due course of time (► **Video 1**). In the case of subfascial flap harvest, even if there is skin necrosis, the fascia almost always survives and can be grafted secondarily.

Advantages and Disadvantages of Propeller Flaps

Propeller flaps have their own set of advantages and disadvantages as compared with other conventional locoregional and free flaps, which are summarized in ► **Table 2**.

Table 2 Advantages and disadvantages of propeller flaps

Advantages	
1.	It has a unique versatile flap design.
2.	It can be raised as a long and narrow flap and is not limited by routine length-to-width ratios.
3.	Small-to-moderate size defects are reconstructed reliably in accordance with “like with like” principle.
4.	Flap harvest is simple, easy, and fast.
5.	Axial rotation of skin paddle gives better aesthetic outcomes without any dog ear.
6.	It is a single-stage microvascular procedure without the need of microvascular anastomosis.
7.	Anatomical variations of major source arteries does not interfere with harvest technique and final outcome of flap.
8.	By avoiding sacrifice of major vessels, cutaneous nerves, and muscles, donor site morbidity is reduced.
9.	Linear closure of donor site is possible in many cases.
10.	Positional comfort as opposed to distant flap.
Disadvantages	
1.	Patient selection along with good perforator identification is required, which is dependent on experience.
2.	Propeller flap has a tendency to remain congested in postoperative period and can be difficult to differentiate between temporary venous congestion and true venous insufficiency.
3.	Reconstruction of large skin defect and multi-dimensional reconstruction is not possible.
4.	Meticulous dissection is required.
5.	Pin cushion effect has been noted by some authors.
6.	Microvascular anastomosis might be needed for supercharging in case of persistent venous congestion.
7.	Donor sites of smaller defects can be closed primarily; however, many cases require skin graft for coverage of donor area.

Applications

The perforators from different areas of the body have differing characteristics. Although that does not greatly affect the technique of harvest or the outcomes, it is prudent to discuss various applications of propeller flaps in different conditions and anatomical areas.

Propeller Flaps for the Head, Neck, and Face

The head, neck, and face (HNF) is a favorable site for executing propeller flaps. This is particularly helped by its anatomical characteristics such as rich vascularity and extra mobility. The increased mobility in the area gives a great degree of freedom in the styling of propeller flaps and the placement of suture lines at strategic locations. Kannan et al⁴⁹ have noted that perforators closer to the facial artery origin are larger in size and the surrounding skin is laxer, and these flaps are more robust compared with other flaps on the face. Demirseren et al⁵⁰ have noted the propensity of propeller flaps over the face for “pin cushioning.” Therefore, they recommend maintaining an intact skin bridge wherever possible to minimize this effect. However, in our experience, if the propeller flaps over the face are planned slightly smaller than the defect and early postoperative scar care and massage is initiated, the pin cushioning effect is minimized to a great extent (►Fig. 3). Apart from the use of propeller flaps for cutaneous indications, mucosal and intraoral flaps can also be designed in a propeller fashion for increased reconstructive options and possibilities.^{46,51}

Propeller Flaps for the Upper Extremity (►Video 2)

Video 2

Technique of harvest and perforator dissection in upper extremity neurocutaneous propeller flap Online content including video sequences viewable at: <https://www.thieme-connect.com/products/ejournals/html/10.1055/s-0041-1740529>.

Due to aesthetic concerns, propeller flaps are not as popular for the upper extremity as they are for the lower extremity.¹⁸ Teo¹² feels that one of the potential limitations to wider application of propeller flaps, especially in the distal forearm, is the relatively short pedicle length, which might not be able to withstand a torsion of up to 180 degrees very well. D'Arpa et al⁴⁶ noted a high incidence of venous problems in upper extremity propeller flaps. That might be attributed to the predominance of the superficial venous system, leading to venous engorgement of the flap based on perforating veins alone. Therefore, they advocate routine venous supercharging in the forearm.^{46,48}

Our experience with upper extremity propeller flaps has been very encouraging. We feel that although the pedicle length and diameter of upper extremity perforators are less

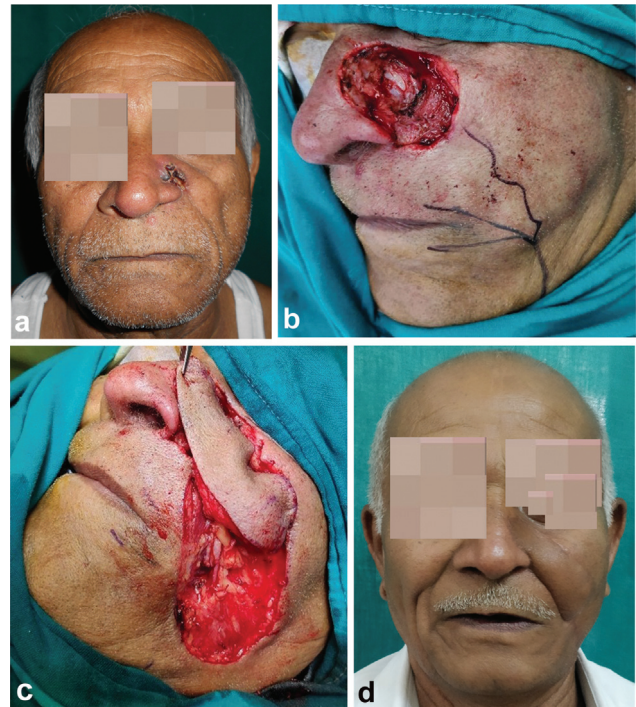

Fig. 3 (a) Malignant lesion. (b) Primary defect over the face. (c) Axial rotation of propeller flap based on facial artery perforators through 180°. (d) Well-settled propeller flap. (Note: absence or minimal pin cushioning effect).

as compared with those of the lower extremity, so is the thickness of skin and fascia, which is transferred to these perforators.¹⁸

Decision-making regarding suprafascial or subfascial flap harvest for the upper extremities deserves special mention. In patients with associated nerve and/or tendon injuries that might require secondary procedures, we prefer suprafascial flap harvest. This ensures a smooth subfascial gliding surface for a tendon transfer/graft if required¹⁸ (►Fig. 4).

Composite propeller flaps are rarely mentioned in the literature. We have limited experience with the neurocutaneous propeller flap (►Video 2) for upper extremity reconstruction. More studies and long-term follow-ups are needed to identify their shortcomings; however, our early results are encouraging.

Propeller Flaps for the Trunk

Despite having a large surface area and a significant number of perforators over that area, the literature on the use of propeller flaps for trunk reconstruction is sparse. Moshrefi et al conducted an in-depth review of propeller flap applications for the trunk with 21 studies and 365 flaps. Interestingly, none of the etiologies mentioned for the defects were traumatic. They noted no incidence of total flap necrosis.⁵² D'Arpa et al noted that the longer length of perforators over the trunk permits a greater range of movement, allowing an extensive arc of rotation with little concern about the torsion of the perforator and the blood supply. Studies have demonstrated that large flaps with an

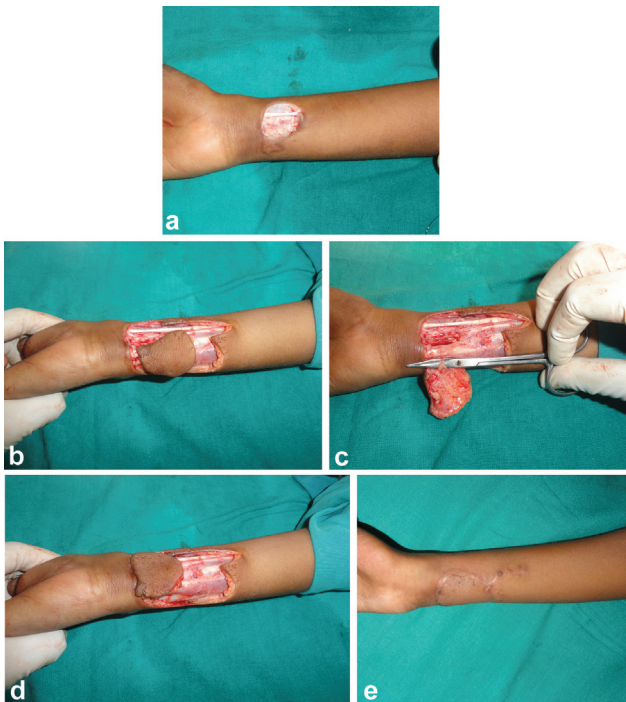


Fig. 4 (a) Soft tissue defect over the volar wrist. (b) Islanded flap. (c) Skeletonized perforator. (d) Flap propelled into the defect. (e) Well-settled flap with linear closure of donor site.

orientation perpendicular to the longitudinal axis of the cutaneous dermatomes can be successfully transferred to the trunk⁵³ (►Fig. 5).

Propeller Flaps for the Lower Extremity

Based on the vascular supply of the lower limbs, it has been observed that very long propeller flaps can be raised comfortably as compared with other anatomical areas.^{46,48,54} D'Arpa et al have observed that posterior tibial perforators seem to have an advantage over the perforators of the anterior tibial and the peroneal arteries by virtue of their large-caliber size and better veins.^{46,48} However, it has also been noted that the peroneal vessels are relatively resistant to atherosclerosis. Therefore, if a defect can be covered with a

propeller flap based on perforators of both posterior tibial as well as peroneal vessels, peroneal perforators should be the source perforator of choice in suspected atherosclerotic extremities^{55,55} (►Video 1).

Bajantri et al have described a propeller flap that can be designed from the contralateral side of the leg and thrown over the intervening skin bridge to cover the defect. They termed this as the “throwover propeller flap”.⁵⁶ We have proposed general guidelines regarding the safe limit of perforator flaps in lower limb reconstruction by stating the relationship between the length of the flap and the length of the leg. We found a six-times increased risk of flap necrosis if the flap is more than one-third of the leg length. However, this study has got its own set of limitations.⁴⁴

Propeller Flaps for Post-burn Reconstruction

The literature on the use of propeller flaps for post-burn reconstruction is sparse. Hyakusoku et al,⁵⁷ Aslaqn et al,⁵⁸ and Karki et al⁷ have shared their experience mainly with the use of subcutaneous pedicle propeller flaps for post burn reconstruction in various anatomical areas. Generally, it is considered that the local tissue is scarred and not suitable to be elevated as a flap for reconstructing the local area. Therefore, there might be a reluctance to use propeller flaps for post-burn reconstruction. However, it has been our experience that including the deep fascia and a known perforator in the flap makes the flap very reliable. In addition, the relatively less scarred or unscarred area of the flap goes into the defect, and the scarred area near the contracture goes into the proximal healthy area⁵⁹ (►Fig. 6). We feel that propeller flaps are an important reconstructive option for postburn contractures, and the full potential of their applications is yet untapped.

Propeller Flaps in the Pediatric Age Group

There is limited published literature on the use of propeller flaps in the pediatric age group. Ozalp et al³¹ have published their experience with propeller flaps for lower extremity reconstruction in the pediatric age group. They noted that perforator vessels in children are quite small in diameter as compared with adults and not easily seen. In their experience

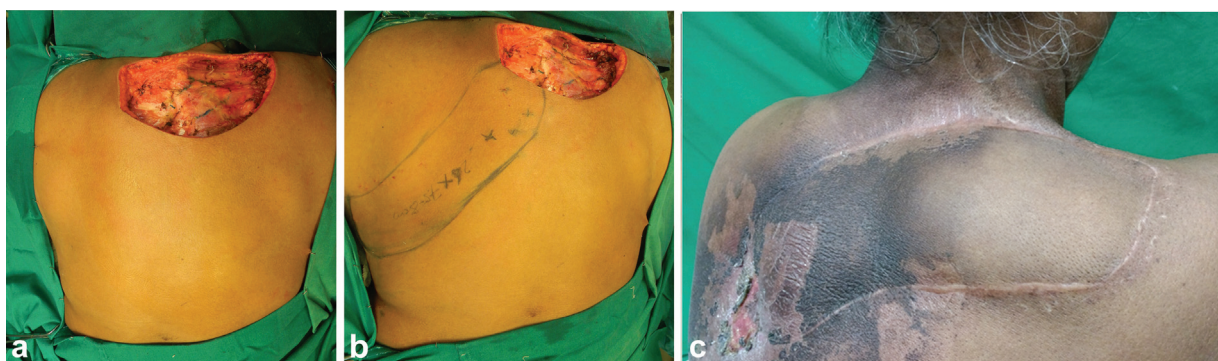


Fig. 5 (a) Defect over the back. (b) Planned free-style propeller flap. (c) Well-settled flap. (Courtesy: Dr. Dushyant Jaiswal, Consultant Plastic, Reconstructive and Microvascular Surgeon at Tata Memorial Hospital, Mumbai.)

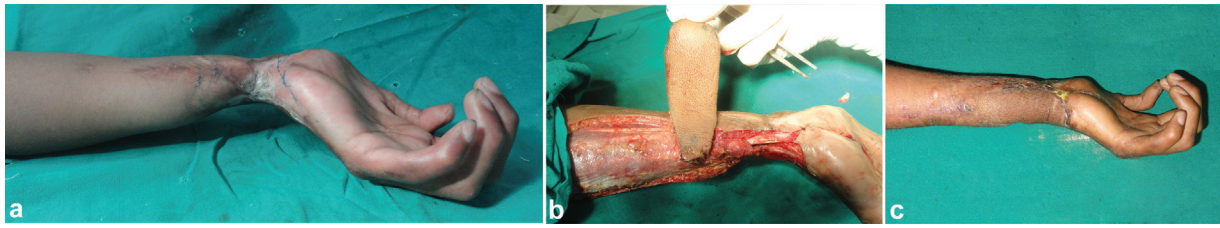


Fig. 6 (a) Post burn wrist contracture with tissue deficit. (b) Primary defect and perforator propeller flap based on ulnar artery perforator (note: suprafascial harvest of flap). (c) Well-settled flap with linear closure of donor site.

of seven patients, they did not skeletonize the perforators for fear of iatrogenic injury or vasospasm.³¹

Managing Complications

Most of the complications can be avoided by judicious planning and meticulous execution of the propeller flaps.

Where there is inappropriate patient selection, and haste in the execution of flaps with disregard to gentle tissue handling and hemostasis, results are proportionately unpredictable. All these factors have been discussed throughout the manuscript at appropriate places. Here, we will sum up avoiding and managing complications under three headings (► **Table 3**).

Table 3 Avoiding and managing complications of propeller Flaps

Failures	Factors leading to complications		Avoiding/Troubleshooting
Inappropriate planning	Patient-related systemic factors	Chronic tobacco consumers, PVD	Appropriate patient selection
	Defect-related factors	Large multidimensional defects, perforator in the zone of trauma and irradiation	Appropriate patient and defect selection. Avoid propeller flaps in patients with absent Doppler signals
Inappropriate execution	Surgeon-related factors	No or less experience in propeller flaps Inappropriate perforator selection Forceful tissue handling and traction on perforator Inadequate Hemostasis	Familiarize oneself with local anatomy, planning and execution of propeller flap. Good quality perforator free from the trauma zone with two venae comitantes. Gentle tissue handling with adequate exposure, illumination, and magnification. Judicious use of bipolar cautery
	Anesthesia-related factors	Hypothermia and hypotension	Warming of IV fluids Warming blankets Raising temperature of operation theatre Adequate fluid replacement
Inappropriate postoperative care	Dressing	Compressive dressing	Non-compressive dressing with window and splintage.
	Monitoring	Inexperienced staff Whole flap not seen Doppler over the cutaneous vein or at the wrong place	Training of staff on clinical flap evaluation. Large window to provide access to the entire flap Intraoperative marking of the perforator for postoperative Doppler position.
	Venous problem	Hematoma causing compression Transient venous congestion True venous insufficiency	Evacuate hematoma and achieve hemostasis Limb elevation and regular monitoring Derotation of the flap, venous supercharging, Leech application, De epithelization of flap.
	Arterial problem	Spasm Persistent spasm	Use of lignocaine, papaverine, warm saline, and correction of systemic and extrinsic factors if any Derotation of the flap
	Mottling	Partial necrosis of flap	Avoid aggressive debridement and manage conservatively. (► Video 1)
	Cosmesis	Pincushion effect	Early postoperative scar care and pressure garments

Conclusion

Propeller flaps probably are the latest version of pedicled flaps evolving over the decades from the original random pattern flaps, and their applications continue to evolve. Although propeller flaps have their fair share of advantages over other local flaps, they also have a steeper learning curve as compared with conventional fasciocutaneous flaps. Applications of propeller flaps in clinical practice are yet to be fully explored and continue to evolve in terms of appropriate patient selection, identification of a suitable perforator, and so on. Gentle tissue handling, attention to absolute hemostasis, and lots of patience are the key points to obtaining good success rates in propeller flaps.

Conflict of Interest

None declared.

Acknowledgments

We would like to sincerely thank Dr. Mukund Thatte for his valuable inputs.

References

- Ono S, Sebastin SJ, Yazaki N, Hyakusoku H, Chung KC. Clinical applications of perforator-based propeller flaps in upper limb soft tissue reconstruction. *J Hand Surg Am* 2011;36(05):853–863. Doi: 10.1016/j.jhsa.2010.12.021
- Hou C, Chang S, Lin J, Song D, et al. Pedicled perforator flaps. In: *Surgical Atlas of Perforator Flaps: A Microsurgical Dissection Technique*. Dordrecht: Springer Sciences + Business Media; 2015:15–26
- Innocenti M, Menichini G, Baldrighi C, Delcroix L, Vignini L, Tos P. Are there risk factors for complications of perforator-based propeller flaps for lower-extremity reconstruction? *Clin Orthop Relat Res* 2014;472(07):2276–2286. Doi: 10.1007/s11999-014-3537-6
- Katsaros J. Use of the island tensor fasciae latae flap to cover a chest-wall defect. *Plast Reconstr Surg* 1982;69(06):1007–1009
- Hyakusoku H, Yamamoto T, Fumiiri M. The propeller flap method. *Br J Plast Surg* 1991;44(01):53–54
- K T R, J V, M S. Propeller flaps and its outcomes - a prospective study of 15 cases over two-years. *J Clin Diagn Res* 2014;8(01): 87–89. Doi: 10.7860/JCDR/2014/6084.3947
- Karki D, Mehta N, Narayan RP. Subcutaneous pedicle propeller flap: an old technique revisited and modified!. *Indian J Plast Surg* 2016;49(02):220–224. Doi: 10.4103/0970-0358.191306
- Murakami M, Hyakusoku H, Ogawa R. The multilobed propeller flap method. *Plast Reconstr Surg* 2005;116(02):599–604
- Murakami M, Hyakusoku H, Ogawa R. The scar band rotation flap. *Burns* 2005;31(02):220–222
- Hallock GG. The propeller flap version of the adductor muscle perforator flap for coverage of ischial or trochanteric pressure sores. *Ann Plast Surg* 2006;56(05):540–542
- Teo TC. Perforator local flaps in lower limb reconstruction. *CirurgiaPlasticalbero-Latinoamericana* 2006;32(04):15–292
- Teo TC. The propeller flap concept. *Clin Plast Surg* 2010;37(04): 615–626, vi. Doi: 10.1016/j.cps.2010.06.003
- Georgescu AV. Propeller perforator flaps in distal lower leg: evolution and clinical applications. *Arch Plast Surg* 2012;39(02):94–105. Doi: 10.5999/aps.2012.39.2.94
- Pignatti M, Ogawa R, Hallock GG, et al. The “Tokyo” consensus on propeller flaps. *Plast Reconstr Surg* 2011;127(02):716–722. Doi: 10.1097/PRS.0b013e3181fed6b2
- Ayestaray B, Ogawa R, Ono S, Hyakusoku H. Propeller flaps: classification and clinical applications. *Ann Chir Plast Esthet* 2011;56(02):90–98. Doi: 10.1016/j.anplas.2010.11.004
- Quaba O, Quaba A. Pedicled perforator flaps for the lower limb. *Semin Plast Surg* 2006;20(02):103–111. Doi: 10.1055/s-2006-941717
- Jakubietz RG, Jakubietz MG, Gruenert JG, Kloss DF. The 180-degree perforator-based propeller flap for soft tissue coverage of the distal, lower extremity: a new method to achieve reliable coverage of the distal lower extremity with a local, fasciocutaneous perforator flap. *Ann Plast Surg* 2007;59(06):667–671. Doi: 10.1097/SAP.0b013e31803c9b66
- Panse N, Sahasrabudhe P. Free style perforator based propeller flaps: simple solutions for upper extremity reconstruction!. *Indian J Plast Surg* 2014;47(01):77–84. Doi: 10.4103/0970-0358.129628
- Bekara F, Herlin C, Mojallal A, et al. A systematic review and meta-analysis of perforator-pedicled propeller flaps in lower extremity defects: identification of risk factors for complications. *Plast Reconstr Surg* 2016;137(01):314–331
- Vitse J, Bekara F, Bertheuil N, Sinna R, Chaput B, Herlin C. Perforator-based propeller flaps reliability in upper extremity soft tissue reconstruction: a systematic review. *J Hand Surg Eur Vol* 2017;42(02):157–164. Doi: 10.1177/1753193416669262
- Chaput B, Bertheuil N, Gandolfi S, Grolleau JL, Herlin C. Perforator detection with a hand-held Doppler device: importance of the learning curve. *Burns* 2015a;41(01):197
- Lazzeri D, Huemer GM, Nicoli F, et al. Indications, outcomes, and complications of pedicled propeller perforator flaps for upper body defects: a systematic review. *Arch Plast Surg* 2013;40(01): 44–50. Doi: 10.5999/aps.2013.40.1.44
- Taylor GI, Pan WR. Angiosomes of the leg: anatomic study and clinical implications. *Plast Reconstr Surg* 1998;102(03):599–616, discussion 617–618
- Saint-Cyr M, Wong C, Schaverien M, Mojallal A, Rohrich RJ. The perforasome theory: vascular anatomy and clinical implications. *Plast Reconstr Surg* 2009;124(05):1529–1544
- Bhattacharya V, Deshpande SB, Watts RK, Reddy GR, Singh SK, Goyal S. Measurement of perfusion pressure of perforators and its correlation with their internal diameter. *Br J Plast Surg* 2005;58(06):759–764
- Hallock GG. Direct and indirect perforator flaps: the history and the controversy. *Plast Reconstr Surg* 2003;111(02):855–865, quiz 866. Doi: 10.1097/01.PRS.0000040462.38363.C7
- Tolhurst DE, Hallock GG. History of flap surgery. In: Blondeel PN, Morris SF, Hallock GG, Neligan PC, eds. *Perforator Flaps: Anatomy, Technique, and Clinical Application*. 1st ed., Vol. I St. Louis: QMP; 2006:3–11
- Taylor GI, Palmer JH. The vascular territories (angiosomes) of the body: experimental study and clinical applications. *Br J Plast Surg* 1987;40(02):113–141. Doi: 10.1016/0007-1226(87)90185-8
- Kneser U, Beier JP, Schmitz M, et al. Zonal perfusion patterns in pedicled free-style perforator flaps. *J Plast Reconstr Aesthet Surg* 2014;67(01):e9–e17. Doi: 10.1016/j.bjps.2013.09.006
- Schonauer F, La Rusca I, Di Monta G, Molea G, et al. Choosing the correct sense of rotation in 180 propeller flaps. *SURGICAL TIP*. British Association of Plastic, Reconstructive and Aesthetic Surgeons. Elsevier; 2008 Doi: 10.1016/j.bjps.2008.04.073
- Özalp B, Aydinol M. Perforator-based propeller flaps for leg reconstruction in pediatric patients. *J Plast Reconstr Aesthet Surg* 2016;69(10):e205–e211. Doi: 10.1016/j.bjps.2016.07.015
- Wu WC, Chang YP, So YC, Yip SF, Lam YL. The anatomic basis and clinical applications of flaps based on the posterior tibial vessels. *Br J Plast Surg* 1993;46(06):470–479
- Pignatti M, Pasqualini M, Governa M, Bruti M, Rigotti G. Propeller flaps for leg reconstruction. *J Plast Reconstr Aesthet Surg* 2008;61(07):777–783. Doi: 10.1016/j.bjps.2007.10.077

- 34 AskoSeljavaara S. Presented at: Abstracts of the Seventh Congress of the International Society of Reconstructive Microsurgery. June 19–30, 1983; New York, NY
- 35 Celik N, Wei FC. Technical tips in perforator flap harvest. *Clin Plast Surg* 2003;30(03):469–472
- 36 Bilgin SS, Topalan M, Ip WY, Chow SP. Effect of torsion on microvenous anastomotic patency in a rat model and early thrombotic phenomenon. *Microsurgery* 2003;23(04):381–386. Doi: 10.1002/micr.10150
- 37 Chaput B, Herlin C, Bekara F, Bertheuil N. Thinning: the difference between free and propeller perforator flaps. *Arch Plast Surg* 2015b;42(02):241–242
- 38 Bekara F, Herlin C, Somda S, de Runz A, Grolleau JL, Chaput B. Free versus perforator-pedicled propeller flaps in lower extremity reconstruction: what is the safest coverage? A meta-analysis. *Microsurgery* 2018;38(01):109–119. Doi: 10.1002/micr.30047
- 39 Shipkov H, Traikova N, Voinov P, Boucher F, Braye F, Mojallal A. Vascular loops in reconstructive microsurgery: a review of the literature [article in]. *Ann Chir Plast Esthet* 2014;59(01):1–8
- 40 Selvaggi G, Anicic S, Formaggia L. Mathematical explanation of the buckling of the vessels after twisting of the microanastomosis. *Microsurgery* 2006;26(07):524–528
- 41 Wong C-H, Cui F, Tan B-K, et al. Nonlinear finite element simulations to elucidate the determinants of perforator patency in propeller flaps. *Ann Plast Surg* 2007;59(06):672–678. Doi: 10.1097/SAP.0b013e31803df4e9
- 42 Blondeel PN, Neligan PC. Perforator flaps- Anatomy, technique and clinical application, Chapter 8- Avoiding complications. Quality Medical Publishing: St Louis, MI; 2013:163–178
- 43 Wilson JL, et al. Avoiding complications. In: *Flaps and Reconstructive Surgery* by Fu-Chan Wei and Samir Mardini. 2nd ed. Elsevier: Philadelphia, PA; 2016:117–124
- 44 Panse NS, Bhatt YC, Tandale MS. What is safe limit of the perforator flap in lower extremity reconstruction? Do we have answers yet?. *Plast Surg Int* 2011;2011:349357. Doi: 10.1155/2011/349357
- 45 Chen W, Heineman J. A modified vascular delay technique to keep a congested perforator-based propeller flap afloat. *Clin Surg* 2016;1:1037
- 46 D'Arpa S, Toia F, Pirrello R, Moschella F, Cordova A. Propeller flaps: a review of indications, technique, and results. *BioMed Res Int* 2014;2014:986829. Doi: 10.1155/2014/986829
- 47 Pignatti M, D'Arpa S, Cubison TCS. Novel fasciocutaneous flaps for the reconstruction of complicated lower extremity wounds. *Tech Orthop* 2009;24(02):88–95
- 48 D'Arpa S, Cordova A, Pignatti M, Moschella F. Freestyle pedicled perforator flaps: safety, prevention of complications, and management based on 85 consecutive cases. *Plast Reconstr Surg* 2011;128(04):892–906
- 49 Kannan RY, Mathur BS. Perforator flaps of the facial artery angiosome. *J Plast Reconstr Aesthet Surg* 2013;66(04):483–488. Doi: 10.1016/j.bjps.2012.11.027
- 50 Demirseren ME, Afandiyev K, Ceran C. Reconstruction of the perioral and perinasal defects with facial artery perforator flaps. *J Plast Reconstr Aesthet Surg* 2009;62(12):1616–1620
- 51 Cordova A. Apporto innovativo dei perforanti nella chirurgia del distretto testa-collo. In 62mo Congresso SICPRE; 2012:28
- 52 Moshrefi S, Lee GK. Current applications of propeller flaps in reconstruction of trunk wounds. *Plast Aesthet Res* 2017;4:204–208. Doi: 10.20517/2347-9264.2017.33
- 53 Arco G, Horch RE, Arkudas A, Dragu A, Bach AD, Kneser U. Double pedicled perforator flap to close flank defects: an alternative for closure of a large lumbar defect after basalioma excision—a case report and review of the literature. *Ann Plast Surg* 2009;63(04):422–424. Doi: 10.1097/SAP.0b013e318195361e
- 54 Lecours C, Saint-Cyr M, Wong C, et al. Freestyle pedicle perforator flaps: clinical results and vascular anatomy. *Plast Reconstr Surg* 2010;126(05):1589–1603
- 55 Hansen T, Wikström J, Johansson LO, Lind L, Ahlström H. The prevalence and quantification of atherosclerosis in an elderly population assessed by whole-body magnetic resonance angiography. *Arterioscler Thromb Vasc Biol* 2007;27(03):649–654
- 56 Bajantri B, Sabapathy SR, Burgess TM. The 'throw over flap': a modification of the propeller flap for reconstruction of non-adjacent soft tissue defects. *Indian J Plast Surg* 2011;44(03):525–526. Doi: 10.4103/0970-0358.90847
- 57 Hyakusoku H, Iwakiri I, Murakami M, Ogawa R. Central axis flap methods. *Burns* 2006;32(07):891–896
- 58 Aslan G, Tuncali D, Cigsar B, Barutcu AY, Terzioglu A. The propeller flap for postburn elbow contractures. *Burns* 2006;32(01):112–115
- 59 Panse N, Sahasrabudhe P, Bhatt Y. Use of local perforator flaps for post burn reconstruction. *World J Plast Surg* 2012;1(01):22–29