

# SARS-CoV-2: A potential trigger of dermatoneuro syndrome in a patient with scleromyxedema



Mike Fritz, BS,<sup>a</sup> Daniel Tinker, MD,<sup>b</sup> Alex W. Wessel, BS,<sup>c</sup> Gabriela M. Morris, MD,<sup>b</sup> Linda Goldenberg, MSN, RN,<sup>d</sup> Mark Fesler, MD,<sup>d</sup> Lokesh Rukmangadachar, MD, MS,<sup>e</sup> and M. Yadira Hurley, MD<sup>b</sup>  
Lexington, Kentucky and St. Louis, Missouri

**Key words:** COVID-19; dermatoneuro syndrome; epilepsy; IVIG; mucinosis; SARS-CoV-2; scleromyxedema.

## INTRODUCTION

Scleromyxedema (SMX) is characterized by excessive mucin deposition in connective tissues and skin.<sup>1</sup> It shares clinical features with other mucinosises, including generalized myxedema, pretibial myxedema, reticular erythematous mucinosis, and scleredema.<sup>1</sup> However, diagnosis of SMX is distinguished by the following criteria: absence of thyroid disease, presence of monoclonal gammopathy (classically IgG  $\lambda$ ), and cutaneous eruption of waxy papules and plaques, characterized histopathologically by increased dermal mucin, fibroblast proliferation, and fibrosis.<sup>2</sup> SMX also causes multi-system disease with approximately 20% fatality.<sup>3</sup>

Dermato-neuro syndrome (DNS), a potentially fatal complication of SMX, occurs in approximately 18% of the patients.<sup>4</sup> It presents with fever and neurologic disturbances including confusion, dysarthria, seizures, and coma. The pathogenesis of DNS remains uncertain; however, reports speculate that elevated levels of vasoactive cytokines (eg, interleukin 6) during viral infection may contribute by compromising the blood-brain-barrier.<sup>5,6</sup> Enhanced blood-brain-barrier permeability in the setting of monoclonal gammopathy may elevate IgG levels in the brain microvasculature, causing hyperviscosity, sludging, and neurologic abnormalities.<sup>7-9</sup> Available literature indicates that reported cases of DNS are frequently preceded by a flu-like prodrome<sup>3,4,9-18</sup> or other suspected upper respiratory tract infection.<sup>8,19</sup> Notably, 2 case studies identified influenza A

### Abbreviations used:

CSF: cerebrospinal fluid  
DNS: dermatoneuro syndrome  
IVIG: intravenous immunoglobulin  
SMX: scleromyxedema

infection in association with DNS.<sup>6,10</sup> Here, we describe a patient with SMX complicated by 2 episodes of DNS, each associated with different RNA virus infections: Influenza A or SARS-CoV-2.

## CASE REPORT

A 48-year-old man with a history of hypertension initially presented with 3 months of skin tightening, difficulty clenching his fists or opening his mouth, and mild shortness of breath. Physical examination revealed numerous waxy, 2 to 3-mm papules on the upper arms, chest, post-auricular scalp, and eyebrows. Histologic examination of lesional skin biopsy material revealed increased stromal fibroblast proliferation and mucin deposition in the upper dermis (Fig 1), consistent with SMX. Thyroid function tests were normal, and serum protein electrophoresis with immunofixation revealed IgG  $\lambda$  paraproteinemia, leading to a diagnosis of SMX. Initial treatment included prednisone and intravenous immunoglobulin (IVIG) administered every 4 weeks at 1 g/kg of ideal body weight. Within 3 months, cutaneous disease improved, and the

From the University of Kentucky College of Medicine, Lexington<sup>a</sup>; Washington University School of Medicine<sup>c</sup>; Department of Dermatology<sup>b</sup>, Division of Hematology, Oncology, & Cellular Therapy, Department of Internal Medicine<sup>d</sup>, and Department of Neurology<sup>e</sup>, Saint Louis University, St. Louis.

Funding sources: None.

IRB approval status: Not applicable.

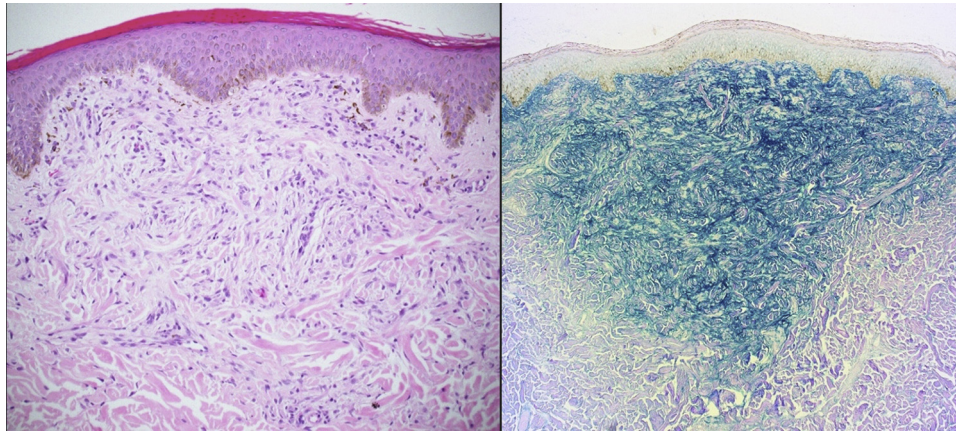
Correspondence to: Mike Fritz, BS, University of Kentucky College of Medicine, MN Building Room 150, 800 Rose Street, Lexington, KY 40506. E-mail: [mike.fritz@uky.edu](mailto:mike.fritz@uky.edu).

JAAD Case Reports 2021;18:99-102.

2352-5126

© 2021 by the American Academy of Dermatology, Inc. Published by Elsevier, Inc. This is an open access article under the CC BY-NC-ND license (<http://creativecommons.org/licenses/by-nc-nd/4.0/>).

<https://doi.org/10.1016/j.jidcr.2021.10.027>



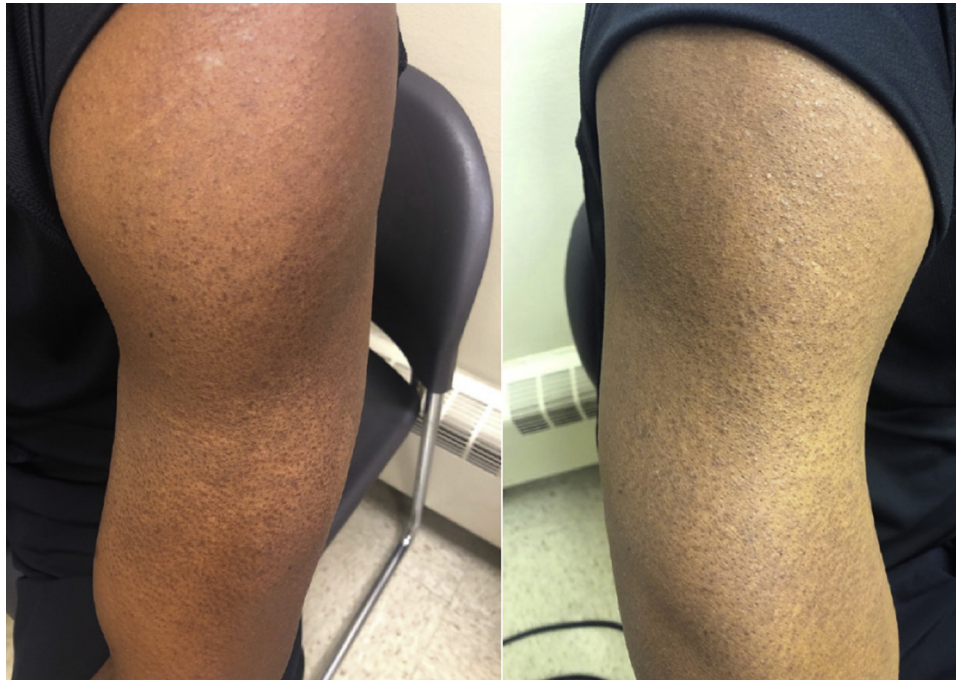**Fig 1.** Histology of lesional skin biopsy material revealing stromal hypercellularity in the upper dermis (left; hematoxylin-eosin stain, original magnification  $\times 60$ ) and increased interstitial mucin deposition (right; colloidal iron stain, original magnification  $\times 60$ ).

patient continued IVIG maintenance therapy at varying frequencies based on severity of cutaneous disease.

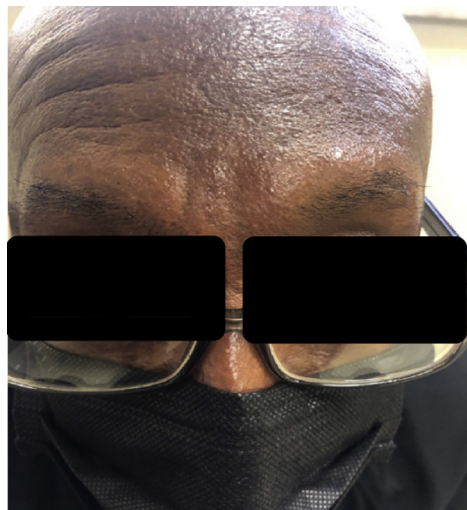Seven years after initial diagnosis, the patient developed several days of flu-like symptoms including fatigue, myalgia, sore throat, and cough. Chest X-ray revealed a small lung infiltrate, and the patient was treated empirically for community-acquired pneumonia with azithromycin. Days later, the patient presented with altered mental status, aphasia, and tonic-clonic movements in all extremities. After hospital admission, the patient developed fever and seizures confirmed to be status epilepticus on electroencephalography. The patient was transferred to the intensive care unit and intubated. Neurology consult noted left-sided motor weakness and right-sided gaze deviation. However, computed tomography and magnetic resonance imaging of the head were unremarkable. Analysis of cerebrospinal fluid (CSF) revealed mild pleocytosis (10 white blood cells/ $\mu\text{L}$ ; reference range, 0-5 cells/mL), mildly elevated protein (47 mg/dL; reference range, 15-45 mg/dL), and an opening pressure of 29 cm  $\text{H}_2\text{O}$ . CSF testing was negative for bacteria by culture, herpes simplex virus 1 and 2, and varicella zoster virus. A nasal swab polymerase chain reaction test confirmed influenza A infection. Complete blood count, comprehensive metabolic panel, urinalysis, chest X-ray, and blood cultures/flow cytometry were unremarkable. Status epilepticus was controlled with intravenous antiepileptics, and the patient improved over a 3-day course of IVIG (3 g/kg of ideal body weight), methylprednisolone, and broad-spectrum antibiotics (despite negative cultures). After consulting neurology, the patient was diagnosed with DNS

given findings of fever, status epilepticus, and encephalopathy without identifiable cause in the setting of SMX. Over the next 4 years, no progression occurred on a strict every-4-week IVIG (1 g/kg) dosing schedule.

Three years after the initial episode of DNS, the patient presented with anosmia and malaise 2 days prior to scheduled IVIG treatment. Physical examination showed no progression of cutaneous disease (Figs 2 and 3). Polymerase chain reaction testing of a nasopharyngeal swab, however, confirmed SARS-CoV-2 infection, precluding treatment at his regular outpatient infusion center. Consequently, he was admitted to the hospital to receive his scheduled IVIG. During IVIG infusion, he developed altered mental status, tonic-clonic movements, and fever (up to 39.4  $^{\circ}\text{C}$ ). Electroencephalography revealed status epilepticus. He was transferred to the intensive care unit, intubated, and treated with intravenous antiepileptics and broad-spectrum antibiotics. CSF analysis revealed mild pleocytosis (7 white blood cells/ $\mu\text{L}$ ), mildly elevated protein (63 mg/dL), and an opening pressure of 24 cm  $\text{H}_2\text{O}$ . CSF testing was negative for gram stain, *Cryptococcus* antigen, and herpes simplex virus 1 and 2. Complete blood count, comprehensive metabolic panel, urinalysis, chest X-ray, blood cultures, and brain computed tomography/magnetic resonance imaging were unremarkable. Neurology was consulted and could not identify underlying cause of the precipitous neurologic decline; thus, recurrent DNS was considered as the potential diagnosis. The patient was treated with a 3-day course of intravenous methylprednisolone and IVIG (3 g/kg of ideal body weight).



**Fig 2.** Scleromyxedema presenting as numerous 2 to 4-mm waxy, perfollicular papules on the upper extremities (left, right), face, trunk, and thighs. Some of the papules were arranged in a linear configuration over the chest, a classic finding in scleromyxedema.



**Fig 3.** Scleromyxedema with numerous waxy 2 to 3-mm papules on the brows and forehead. Induration of the glabella, an early finding in progression to leonine facies, can also be appreciated.

## DISCUSSION

We described 2 episodes of DNS in a patient with SMX who presented with classic findings (fever, confusion, and seizures) preceded by a flu-like prodrome, with confirmed viral infection (influenza A or SARS-CoV-2). Both episodes occurred despite regular IVIG therapy. Possibly, antecedent infections

that elicit hyperinflammatory states may increase the risk of developing DNS. Notably, recent infection or vaccination also is speculated to underlie increased risk of exacerbations in multiple sclerosis.<sup>20</sup> By limiting inflammation, low-dose glucocorticoids could potentially mitigate the risk of DNS in SMX. Indeed, some patients with SMX benefit from adjunct glucocorticoids when IVIG maintenance therapy fails to prevent progression of skin disease. Importantly, other causes of neurologic decline should be considered in the differential diagnosis for DNS, such as the possibility of occult central nervous system infection (despite equivocal CSF studies) or neurologic manifestations of SARS-CoV-2.

Evaluation for infection in DNS often focuses on ruling out neurotropic organisms (eg, herpes simplex virus), but fails to test for many respiratory tract or other systemic pathogens. To better understand the association of DNS with infection, modern techniques, such as BioFire, could be employed to evaluate large panels of viruses and bacteria in SMX patients acutely presenting with DNS.<sup>21</sup> Cytokine profiling of the serum and CSF of DNS patients also may elucidate potential immune-mediated pathology.

## Conflicts of interest

None disclosed.

## REFERENCES

- Hoffmann JHO, Enk AH. Scleromyxedema. *J Dtsch Dermatol Ges*. 2020;18(12):1449-1467. <https://doi.org/10.1111/ddg.14319>
- Hummers LK. Scleromyxedema. *Curr Opin Rheumatol*. 2014;26(6):658-662. <https://doi.org/10.1097/BOR.0000000000000118>
- Rongioletti F, Merlo G, Cinotti E, et al. Scleromyxedema: a multicenter study of characteristics, comorbidities, course, and therapy in 30 patients. *J Am Acad Dermatol*. 2013;69(1):66-72. <https://doi.org/10.1016/j.jaad.2013.01.007>
- Mahévas T, Arnulf B, Bouaziz JD, et al. Plasma cell-directed therapies in monoclonal gammopathy-associated scleromyxedema. *Blood*. 2020;135(14):1101-1110. <https://doi.org/10.1182/blood.2019002300>
- Johkura K, Susuki K, Hasegawa O, Kuroiwa Y, Komatsumoto S. Encephalopathy in scleromyxedema. *Neurology*. 1999;53(5):1138-1140. <https://doi.org/10.1212/wnl.53.5.1138>
- Bhoyrul B, Mughal AA, Paulus J, Salamat A, Howarth S. Does dermatoneuro syndrome have a viral aetiology? *Clin Exp Dermatol*. 2016;41(1):53-56. <https://doi.org/10.1111/ced.12698>
- Marshall K, Klepeiss SA, Ioffreda MD, Helm KF. Scleromyxedema presenting with neurologic symptoms: a case report and review of the literature. *Cutis*. 2010;85(3):137-140.
- River Y, Levy I, Gilead L, Orbach H, Almog Y. Fever, convulsions and coma in scleromyxedema: a "dermato-neuro syndrome". *Neurology*. 1996;46(6):1778-1779. <https://doi.org/10.1212/wnl.46.6.1778>
- Fleming KE, Virmani D, Sutton E, et al. Scleromyxedema and the dermato-neuro syndrome: case report and review of the literature. *J Cutan Pathol*. 2012;39(5):508-517. <https://doi.org/10.1111/j.1600-0560.2012.01882.x>
- Anguelova GV, Jellema K, Wagemakers S, Peters R. Two patients with dermatoneuro syndrome after influenza A infection. *Eur J Neurol*. 2021;28(8):e65-e66. <https://doi.org/10.1111/ene.14886>
- Devos T, Thiessen S, Cuyle PJ, Meersseman W, Delforge M. Long-term follow-up in a patient with the dermato-neuro syndrome treated with high-dose melphalan, thalidomide, and intravenous immunoglobulins for more than 7 years. *Ann Hematol*. 2014;93(11):1927-1928. <https://doi.org/10.1007/s00277-014-2065-5>
- Karaman B, Guler A, Ertam I, Celebisoy N. Dermato-neuro syndrome associated with scleromyxedema. *Indian J Dermatol Venereol Leprol*. 2015;81(5):519-521. <https://doi.org/10.4103/0378-6323.162344>
- Landais AF, Duchemin CM, Bourhis VM. Scleromyxedema (papular mucinosis) with dermato-neuro syndrome: a rare, potentially fatal complication. *Presse Med*. 2015;44(7-8):850-851. <https://doi.org/10.1016/j.lpm.2015.04.026>
- Larios JM, Ciuro J, Sam Varghese T, Lyons SE. Successful treatment of dermato-neuro syndrome with plasmapheresis. *BMJ Case Rep*. 2020;13(12):e237170. <https://doi.org/10.1136/bcr-2020-237170>
- Liu A, Suozzi K, Hwang DY, Moeller JJ, Lazova R, DiCapua D. Dermatoneuro syndrome: a full recovery after a second episode. *Neurol Clin Pract*. 2016;6(3):e27-e29. <https://doi.org/10.1212/CPJ.0000000000000221>
- Magira EE, Malouchou A, Karathanasi V, et al. Acute encephalitic syndrome induced by scleromyxedema. *Am J Med Sci*. 2020;360(2):192-195. <https://doi.org/10.1016/j.amjms.2020.05.018>
- Rey JB, Luria RB. Treatment of scleromyxedema and the dermatoneuro syndrome with intravenous immunoglobulin. *J Am Acad Dermatol*. 2009;60(6):1037-1041. <https://doi.org/10.1016/j.jaad.2008.11.013>
- Shams SR, Goldstein DA, Kaufman JL, MacKelfresh J, Flowers CR, Langston AA. Dermato-neuro syndrome in a patient treated with autologous stem cell transplant for scleromyxedema. *Clin Lymphoma Myeloma Leuk*. 2014;14(6):e213-e215. <https://doi.org/10.1016/j.clml.2014.06.018>
- Lister RK, Jolles S, Whittaker S, et al. Scleromyxedema: response to high-dose intravenous immunoglobulin (hdIVIg). *J Am Acad Dermatol*. 2000;43(2):403-408. <https://doi.org/10.1067/mjd.2000.104001>
- Steelman AJ. Infection as an environmental trigger of multiple sclerosis disease exacerbation. *Front Immunol*. 2015;6:520. <https://doi.org/10.3389/fimmu.2015.00520>
- Creager HM, Cabrera B, Schnaubelt A, et al. Clinical evaluation of the BioFire® Respiratory Panel 2.1 and detection of SARS-CoV-2. *J Clin Virol*. 2020;129:104538. <https://doi.org/10.1016/j.jcv.2020.104538>