

A STUDY OF THE FINE STRUCTURE OF THE KIDNEY IN CASEIN-INDUCED AMYLOIDOSIS IN RABBITS*

BY ALAN S. COHEN, M.D., AND EVAN CALKINS, M.D.

(From the Department of Medicine, Massachusetts General Hospital and
Harvard Medical School, Boston)

PLATES 40 TO 46

(Received for publication, March 5, 1960)

The experimental induction of amyloidosis in rabbits provides a tool for the study of serial morphologic and biochemical changes which precede and accompany the development of this disease. Previous studies, particularly of the spleen, have indicated that amyloid accumulates in close proximity to, but distinct from, the basement membrane, and that amyloid has a characteristic filamentous appearance when viewed in the electron microscope (1).

The present report concerns the light and electron microscopic appearance of the kidney during the induction of amyloidosis. The study was undertaken to define further the fine structure of amyloid, to determine its relationship to a more well defined basement membrane, and to study the effects of amyloid deposition upon glomerular endothelial and epithelial cells and the possible relationship of these cells to amyloid deposits.

Materials and Methods

Amyloidosis was produced in 7 New Zealand white rabbits by subcutaneous injections of 5 ml. of a 10 per cent casein suspension twice weekly. The rabbits were maintained on a diet of standard Purina rabbit chow and water. They were sacrificed at 2, 3, 5, 6, 7, and 10 months, along with untreated rabbits. Kidney was sectioned with razors to portions of 1 to 2 c. mm. and the latter were immediately fixed in buffered osmium acid at 0°C. Buffered sucrose osmium tetroxide and chrome-osmic solution were used for fixation (2, 3). The tissues were dehydrated in 60, 70, 80, 95 per cent and absolute ethyl alcohol, embedded at room temperature in a mixture of *n*-butyl and methyl methacrylate (90:10), and polymerized with benzoyl peroxide (15 mg. per ml. of methacrylate) at 60°C. overnight. Phosphotungstic acid, 1 per cent, in absolute ethyl alcohol was used as the final dehydrating solution in all but the first 2 animals. Portions of kidneys were also fixed in neutral formalin at the time of sacrifice and embedded in paraffin.

Sections of all kidneys were cut for light microscopy and stained with hematoxylin and

* This is Publication No. 278 of the Robert W. Lovett Memorial for the Study of Crippling Disease. Grants in support of these investigations have been received from the United States Public Health Service (Grant No. A-1064-(C-3)) and the Eli Lilly Company. This work was presented in part at the June, 1958, meeting of the American Rheumatism Association in San Francisco (*Arthritis and Rheumatism*, 1959, **2**, 70, abstract).

eosin, Congo red, crystal violet, van Gieson, and periodic acid-Schiff reagents (4). Successive thick ($\frac{1}{2}$ to 2 microns) and thin (250 to 500 angstroms) sections were cut on a Porter-Blum microtome. The thick sections were studied with a Zeiss phase microscope and also prepared for light microscopy by treatment with xylol overnight to remove the methacrylate, followed by staining with periodic acid-Schiff and hematoxylin. Thin sections were examined in an RCA-EMU-2D electron microscope. Original magnifications ranged from 1800 to 7400.

TABLE I
Summary of Renal Abnormalities and Serum* Findings in Control and Casein-Treated Rabbits

Rabbit	No. months of casein injections	Light microscopy†		Electron microscopy§ Renal finding	Serum hexosamine mg. per cent	Serum urea nitrogen mg. per cent	Serum cholesterol mg. per cent	Serum proteins				Total protein gm. per cent
		Splenic amyloid	Renal amyloid					Albumin gm. per cent	Globulin			
				alpha					beta	gamma		
Controls	0	0	0	0	75	18	82	3.6	0.8	0.9	1.0	6.3
2-04	2	+	0	? END	—	14	—	—	—	—	—	—
1-32	3	3+	0	BM	—	27	120	3.7	—	—	—	7.0
2-05	5	2+	1+	EPI, DEP	123	9	77	3.0	1.3	1.3	2.3	7.9
9-9	5	3+	2+	BM, EPI, END, DEP	100	35	71	1.2	0.6	0.6	4.2	6.6
8-7	6	4+	4+	BM, E ₁ I, END, DEP	116	30	—	3.2	0.9	1.1	2.3	7.5
1-52	7	3+	4+	BM, EPI, END, DEP	166	—	276	2.7	0.8	1.5	2.9	7.9
9-4	10	4+	2+	BM, EPI, END, DEP	110	29	156	1.9	1.0	0.8	2.5	6.2

* All serum values determined on blood specimens taken at the time of sacrifice or within 2 weeks prior.

† Amount of amyloid graded as follows: 0, no amyloid. 1+, 1 to 25 per cent replacement of the organ. 2+, 26 to 50 per cent replacement of the organ. 3+, 51 to 75 per cent replacement of the organ. 4+, 76 to 100 per cent replacement of the organ.

§ Abbreviations: 6 control kidneys examined by electron microscopy. BM, basement membrane abnormality. EPI, epithelial cell abnormality. END, endothelial cell abnormality. DEP, extracellular deposition.

|| Serum proteins represent mean values or results of analyses of sera of 34 rabbits. Normal urea nitrogen and cholesterol averages taken from Ellis, J. T., *J. Exp. Med.* 1956, **103**, 127.

The serum hexosamine levels in these rabbits were estimated by the Elson and Morgan reaction as modified by Boas (5); the total protein by the gradient density method (6); the blood urea nitrogen and cholesterol by standard methods (7). Serum electrophoresis was carried out on No. 1 Whatman paper at 22°C. at 100 volts, 1.5 ma., for 16 hours in veronal buffer (pH 8.6, 0.01 μ) (8).

The Findings with Light Microscopy

Sections of the formalin-fixed tissues demonstrated no renal amyloidosis until after 5 months of casein injections (Table I). Two rabbits, however, were found to have amyloid involvement of the spleen after 2 and 3 months of injections respectively. The renal accumulations were eosinophilic, metachro-

matic with crystal violet and bound Congo red. Although Bowman's capsule and the glomerular basement membrane were heavily stained with the periodic acid-Schiff (PAS) reagent, the amyloid gave only a pale purple color. The thick sections of the osmium-fixed material demonstrated these same tinctorial properties with the PAS stain (Figs. 1 and 2).

Amyloid appeared to accumulate on the endothelial side of basement membrane. It occasionally surrounded the endothelial cell, but was moderately well delineated from the basement membrane. In all rabbits with glomerular amyloid (with one exception, No. 2-05 with the smallest accumulations) all glomeruli in the tissue sections were involved.

The Findings with Electron Microscopy

The glomerulus is made up of a network of capillaries which branch off the afferent arteriole and which converge to form the efferent arteriole. The fine structure of the normal renal glomerulus has been well defined by Hall (9) (10), Pease (11), Mueller (12), Rhodin (13), and others. In brief, the wall of the glomerular loop has 3 elements; the visceral epithelial cell, the basement membrane, and the endothelial cell. The first (the podocyte) has a remarkable fine structure with a system of interdigitating foot processes (pedicels) that are applied to the basement membrane. The foot processes in the normal state are distinctly separated from one another. The pedicels of one epithelial cell may abut upon several glomerular loops. The basement membrane itself is a homogeneous structureless membrane which in the rabbit is about 800 Å thick. It consists of a central dense layer (lamina densa) and peripheral non-osmophilic layers. The endothelial cell is characterized by a nucleus that bulges into the capillary lumen, and attenuated cytoplasm which displays a large number of pores of a diameter of about 0.1 microns. Therefore, in areas, the basement membrane is the only structure separating capillary lumen from Bowman's space (Figs. 3 to 5).

In the rabbit given casein for 2 months, no renal amyloid was observed by any techniques, although minute amounts were found in its spleen. Several minor abnormalities were observed in the glomeruli of this animal; *i.e.*, endothelial cell cytoplasmic blebs extending into the capillary lumen and a slight increase in the number of vacuoles in the epithelial cell cytoplasm. The basement membrane was not thickened.

A 2nd rabbit which was given casein for 3 months also exhibited no renal amyloid although extensive amounts were present in its spleen. The glomeruli demonstrated a slight endothelial cell proliferation plus occasional local protrusions of the lamina densa of the basement membrane (similar to those seen in Figs. 6 and 7) thus producing small nodular masses that bulged towards the cavity of Bowman's capsule.

The earliest accumulation of renal amyloid was found in the 2 rabbits given

casein for 5 months. Successive thick and thin sections enabled localization of the amyloid in the electron micrographs. It manifested itself as small amounts of fibrillar material subjacent to the endothelial cell cytoplasm. The basement membrane was not altered. The foot processes of the podocytes were shorter and blunter and in several areas fused, presenting a continuous layer of cytoplasm applied to basement membrane. Occasionally, blebs extended out from the endothelial cytoplasm into the capillary lumen.

In the animals which had received casein for 6 or more months, larger and more clearly defined amyloid accumulations were recognized. All glomeruli visualized were involved and almost all the loops of each individual glomerulus. The deposit occasionally was focal and bulged into the capillary lumen (Figs. 3 and 5) while in other instances it partially occluded the capillary lumen (Fig. 4).

It was difficult to evaluate in all micrographs whether or not the basement membrane was thickened. The integrity of the lamina densa was almost invariably maintained in sections exposed to 1 per cent phosphotungstic acid in the dehydrating alcohol, but the non-osmophilic layers of the basement membrane were usually lost to sight as the latter coursed through the amyloid. Without phosphotungstic acid, the density of the basement membrane and of amyloid were such as to make it appear as though amyloid merged with the basement membrane. Where the plane of sectioning permitted good visualization, the lamina densa appeared to be about double its normal thickness (Fig. 4). The nodular thickenings protruding towards Bowman's space were also observed (Figs. 6 and 7).

When focal deposits of amyloid were observed, they were located between the endothelial cell cytoplasm and basement membrane. When the accumulation of amyloid was large, it appeared in small amounts on the epithelial side of the basement membrane as well. The amount on this outer aspect of basement membrane was never great.

The endothelial cell invariably appeared to separate the amyloid from the glomerular lumen (Figs. 3, 4, 5, and 8). Where the amyloid bulged into lumen, a distinct layer of continuous endothelial cell cytoplasm enveloped it. Although no endothelial pores were seen over the amyloid, the former could be easily discerned in adjacent areas where attenuated cytoplasm appeared in its usual close relationship to the basement membrane (Fig. 5). The amyloid fibrils in close approximation to the cell cytoplasm had a tendency to be arranged in bundles oriented parallel to the outer edge of the cell membrane (Figs. 8 to 10). Endothelial cell blebs, often seen in glomeruli of rabbits with small amounts of amyloid, were not observed in the animals with advanced disease.

Marked changes were observed in the epithelial cells. The most striking was the loss of foot processes and the fusion of cytoplasm contiguous to the basement membrane in areas where amyloid had appeared. The cytoplasm occa-

sionally was in direct contact with the amyloid when the latter surrounded the basement membrane (Figs. 5 and 8).

The epithelial cell cytoplasm continuous with the fused foot processes often was exceedingly thin and made up of many long tendrils which (depending upon the plane of sectioning) appeared as isolated filaments or circles of cytoplasm (Figs. 4 and 5). These thin processes were connected to the remainder of the epithelial cell which contained multiple small vacuoles. The epithelial cell nucleus remained unaltered in the distal portion of the cytoplasm.

Amyloid itself had a characteristic fine filamentous appearance. In areas the filaments appeared in random array (Fig. 5). In other areas, especially those adjacent to endothelial cell cytoplasm, the fibrils appeared to run in bands paralleling the endothelial cell surface (Figs. 8 to 10). The width of the fibrils in section was <300 A and the length up to 5000 A.

The Findings in the Serum

Observations of the serum constituents at the time of sacrifice of the rabbits demonstrated abnormalities comparable to those previously reported in casein-induced amyloidosis (Table I) (14). Serum hexosamine was elevated, serum albumin depressed, alpha and beta globulins moderately increased, and gamma globulin markedly elevated. The blood urea nitrogen was usually not significantly elevated. In the animals given casein for long periods, serum cholesterol was somewhat increased. Urinalyses, performed in several of the animals before sacrifice, disclosed moderate proteinuria. Thus, the animals with most severe renal involvement had several of the chemical characteristics of nephrosis; *i.e.*, decreased serum albumin, increased serum cholesterol, and proteinuria.

DISCUSSION

(a) *Amyloid Fibrils*.—Observations on the structure of amyloid indicate that at least a part of the material is a fibrous moiety. Although in studies of the amyloid rabbit spleen (1), the fibrils could be demonstrated only by unusual conditions of fixation, (*i.e.*, exposure to phthalic acid, then to phosphotungstic acid), the kidney material demonstrated them clearly. The fibrils to date have not been observed intracellularly.

Intracellular particles and extracellular elements which have been fixed, dehydrated, and embedded exhibit shrinkage when compared to material obtained after fragmentation. It is, however, of interest to examine the characteristics of the present fibrils in the light of what is known about other extracellular fibrous elements in tissue section. The three best known tissue fibers are collagen, elastin, and fibrin (15).

Collagen, the major extracellular fibril, varies in width, but shows a characteristic 640 A periodicity. Smaller collagen subunits can be observed under special conditions,

and occasionally the periodicity is not obvious (16) (17). The fibrils of amyloid on the other hand, are thin (<300 Å) and show no clear cut periodicity on tissue sections. Other indications of the lack of identity of amyloid fibrils with collagen are chemical analyses demonstrating low hydroxyproline content (18).

Elastin when viewed in the electron microscope has an amorphous structure of low electron density which in no way resembles the amyloid material. Fibrin consists of thin filaments with a typical 230 Å periodicity. Recently the existence of polysaccharide fibers in mammalian connective tissue has been suggested (19), but insufficient evidence is available to compare these elements with amyloid fibrils. Thus, the latter, to date, show no morphologic identity with known connective tissue elements on tissue section. Studies of *in vitro* membrane systems, on the other hand, often demonstrate ordered fine structure induced from solutions of large molecules. Polynucleotides (20), myelin forms from lipid and protein mixtures, from pure lipids (21), hyaluronic acid protein mixtures (22, 23), and others all demonstrate specific structure.

Further studies on the isolation and identification of the fibrous element of amyloid and their relationship to other fibers and membranes are now in progress.

(b) *Relationship of Amyloid to Basement Membrane.*—The earliest electron microscopic observations in experimental renal amyloidosis were carried out by Miller and Bohle (24). They produced amyloid in mice by means of multiple subcutaneous casein injections. The major abnormality observed was in the glomerular basement membrane. A significant thickening of the lamina densa to twice its normal width was found. In addition, nodular protrusions of the lamina densa were seen to bulge towards the cavity of Bowman's space. The authors did *not* believe, however, that this thickening of the osmiophilic layer of the basement membrane represented amyloid. This is in agreement with the present study, in which nodular excrescences of basement membrane were occasionally observed in rabbits given casein for several months which had not yet developed massive amyloid, as well as in those with clear cut amyloid. Apparently identical nodular thickenings of the basement membrane have been observed in experimental serum sickness nephritis by Feldman (25) and in the glomerular lesion produced with streptococci in mice by Sharp (26). All the animals exhibiting this lesion had proteinuria, and it was suggested by Miller and Bohle that the lesion was related to the passage of pathologic proteins through the lamina densa. However, experimental diseases with proteinuria and without these nodular excrescences have been observed (27).

The integrity of the lamina densa was well maintained in the material that was dehydrated with 1 per cent phosphotungstic acid in the absolute alcohol. The lamina rara interna and externa, non-osmiophilic layers of the basement membrane, could not be clearly delineated when the amyloid accumulated in large quantity on both sides of the basement membrane. It is the authors' opinion that amyloid is distinct from basement membrane.

(c) *Relationship of Amyloid to Endothelial and Visceral Epithelial Cells.*—In these animals it was virtually impossible to define any consistent and clear cut cellular changes that preceded the appearance of amyloid. Several animals displayed bleb-like protrusions of the endothelial cell into the capillary lumen. It sometimes appeared that endothelial cells were present in increased numbers but this finding is difficult to access accurately. The aforementioned excrescences of basement membrane occurred infrequently.

When amyloid was present in clearly discernible amounts, few abnormalities could be observed in the endothelial cells. The areas of cytoplasm over the amyloid showed a loss of endothelial fenestrations, while adjacent areas had normal pores. The intracellular organelles appeared to be normal.

Examination of the fine structure of their visceral epithelial cells (podocytes) demonstrated changes that seem to be consistently associated in man and animals with a nephrotic syndrome. This consists of the swelling, coalescence, and eventual obliteration of the foot processes. In most glomerular loops studied, the broad masses of cytoplasm were confluent subjacent to areas that amyloid occupied, while contiguous areas showed discrete foot processes. The epithelial cytoplasm contained increased numbers of small vacuoles but otherwise the intracellular inclusions appeared normal. The cytoplasm connecting to the swollen or confluent foot processes often was quite attenuated and in individual sections appeared as isolated vesicles; these could on serial sectioning be demonstrated to connect to both the cell proper and the foot process. The rabbits that were followed for 6 months and longer often showed clinical evidence of nephrosis.

(d) *Relationship of Experimental Amyloidosis to Other Experimental and Naturally Occurring Diseases*

The fine structure of the kidney in a number of human diseases (*i.e.* familial nephrosis, acute and subacute glomerulonephritis, toxemia of pregnancy, disseminated lupus erythematosus, diabetic glomerulosclerosis) and experimentally induced animal diseases (*i.e.* nephrotoxic serum nephritis, serum sickness nephritis, Schwartzman phenomenon, aminonucleoside nephrosis, saccharated iron oxide nephrosis) has recently been reported in detail (27).

Although end-stage renal disease of many etiologies seems to involve all 3 major components of the glomerular loop (endothelial cell, basement membrane, epithelial cell), there are some lesions that have a well defined morphologic pattern early in the disease. The nephrotic syndrome in the human and the lesion of aminonucleoside nephrosis and saccharated iron oxide nephrosis demonstrate primarily the epithelial cell lesion and basement membrane thickening noted earlier.

Basement membrane thickening and the accumulation of extracytoplasmic basement membrane-like deposits appear to be the primary abnormality in diabetic glomerulosclerosis (28, 29). This lesion is quite distinct from amyloid. In the Schwartz-

man phenomenon endothelial cell vesicles appear and there is the apparent precipitation of fibrinogen and formation of "fibrinoid" on the swollen surface of the endothelial cell (30, 31). The anatomic location of these fibrils and their axial period of 120 A make the lesion dissimilar to that of experimental amyloidosis, although the fibril diameter (200 to 300 A) is comparable to that of amyloid fibrils.

Human renal amyloidosis has been studied by a number of investigators (32-35). Geer and coworkers (34) examined renal biopsy material of a case of proven human amyloidosis. They found that the basement membrane was thickened $2\frac{1}{2}$ times its normal width, and that most of this consisted of the lamina densa. The amyloid appeared as nodular masses of less dense material continuous with the more dense basement membrane. Some increase and vacuolization of endothelial cells and shortening and widening and in places fusion of foot processes of the visceral epithelial cells were observed. Farquhar (35) similarly commented on the amyloid as a lighter foamy extension of basement membrane that was in places 20 times its normal thickness. At high magnification, she observed tiny vesicles and tubules in the amyloid. The present authors have studied the kidneys of 3 cases of human renal amyloidosis (2 primary) and found fibrillar material to be present in the amyloid in all 3. This finding was confirmed by Spiro (33) on biopsy of one of the authors' cases, and independently by Miller (36) and by Movat (37). Variation in techniques of fixation and dehydration may account for the different appearance of amyloid in the various laboratories.

In the present series of rabbits, the observation of continuity of endothelial cell cytoplasm over the amyloid and of the epithelial cell podocytes subjacent to it is of interest. If amyloid is a substance laid down from circulating plasma, it would either have to pass through endothelial pores which would then coalesce over it, or pass through the intact endothelial cell, accumulating on the other side. Furthermore, the parallel orientation of the fibrillar material contiguous to the cell membrane may possibly be compared to that of young collagen fibrils (38), which show orientation parallel to cell border of the fibroblast producing them.

Since the epithelial cell foot process fusion is seen largely over the masses of amyloid it is possible that this fusion is a reaction (*a*) to the amyloid itself or (*b*) to increased permeability of basement membrane to plasma proteins in that area due to the amyloid? No answer to this question is available at the present time. An understanding of the nature of the morphologic expression of proteinuria may assist us in our understanding of amyloid.

SUMMARY

Renal amyloidosis, produced in rabbits by subcutaneous casein injections, was studied by light and electron microscopy.

The earliest change before amyloid was detected was the appearance of endothelial cell blebs and mild endothelial cell proliferation.

Amyloid was deposited between the basement membrane and the endothelial

cell. The cytoplasm of the latter, when over amyloid, was devoid of fenestrations but otherwise had normal inclusions.

Basement membrane excrescences were observed both early and late in the development of the disease, while basement membrane thickening was common with advanced disease. The integrity of the lamina densa of the basement membrane appeared to be preserved through the amyloid deposit.

Epithelial cell foot process broadened and fused with advanced disease. The absence of the foot processes was particularly noticeable in areas adjacent to amyloid deposits.

Epithelial cell cytoplasm contained multiple vacuoles. The cytoplasmic strands connecting the foot processes to the body of the cell were significantly attenuated.

The substance of the amyloid consisted of fibrils that were oriented in parallel bundles in areas adjacent to the endothelial cell. The fibrils were <300 A wide and ranged in length up to 5000 A.

The authors would like to express their appreciation to Dr. Walter Bauer and Dr. Jerome Gross for their encouragement and support and to Orville Rodgers for invaluable technical assistance.

BIBLIOGRAPHY

1. Cohen, A. S., Weiss, L., and Calkins, E., Electron microscopic observations of the spleen during the induction of experimental amyloidosis in the rabbit, *Am. J. Path.*, *in press*.
2. Palade, G. E., A study of fixation for electron microscopy, *J. Exp. Med.*, 1952, **95**, 285.
3. Dalton, A. J., A chrome-osmium fixative for electron microscopy, *Anat. Rec.*, 1955, **121**, 281.
4. Cohen, A. S., Calkins, E., and Levene, C. I., Studies on experimental amyloidosis. I. Analysis of histology and staining reactions of casein induced amyloidosis in the rabbit, *Am. J. Path.*, 1959, **35**, 971.
5. Boas, N. F., Method for the determination of hexosamine in tissues, *J. Biol. Chem.*, 1953, **204**, 553.
6. Lowry, O. H., and Hunter, T. H., The determination of serum protein concentration with a gradient tube, *J. Biol. Chem.*, 1945, **159**, 465.
7. Case Records of the Massachusetts General Hospital, Normal laboratory values, (B. Castleman, editor), *New England J. Med.*, 1960, **262**, 84.
8. McDonald, H. J., Ionography: A new frontier in electrophoresis, *J. Chem. Educ.*, 1956, **29**, 428.
9. Hall, B. V., Studies of normal glomerular structure by electron microscopy, *Proc. 5th Ann. Conf. Nephrotic Syndrome*, (J. Metcoff, editor), 1953, 1.
10. Hall, B. V., Further studies of the normal structure of the renal glomerulus, *Proc. 6th Ann. Conf. Nephrotic Syndrome*, 1955, 1.
11. Pease, D. C., Fine structures of the kidney seen by electron microscopy, *J. Histochem. and Cytochem.*, 1955, **3**, 295.

12. Mueller, C. B., Mason, A. D., Jr., and Stout, D. G., Anatomy of the glomerulus, *Am. J. Med.*, 1955, **18**, 267.
13. Rhodin, J., Electron microscopy of the kidney, *Am. J. Med.*, 1958, **26**, 661.
14. Giles, R. B., Jr., and Calkins, E., The relationship of serum hexosamine, globulins and antibodies to experimental amyloidosis, *J. Clin. Inv.*, 1958, **3**, 846.
15. Jackson, D., Chemistry of the fibrous elements of the connective tissue, *in* Connective Tissue, Thrombosis, and Atherosclerosis, New York, Academic Press, Inc., 1959.
16. Glimcher, M., The macromolecular aggregation state of collagen and biological specificity in calcification, *in* Connective Tissue, Thrombosis, and Atherosclerosis, New York, Academic Press, Inc., 1959.
17. Gross, J., The behavior of collagen units as a model in morphogenesis, *J. Biophysic. and Biochem. Cytol.*, 1956, **2**, No. 4., suppl., 261.
18. Cohen, A. S., and Calkins, E., unpublished observations.
19. Cruise, A. J., and Jeffrey, J. W., Polysaccharide fibres in mammalian connective tissue, *Nature*, 1959, **183**, 677.
20. Hall, C. E., Electron microscopy of polynucleotides, *Ann. New York Acad. Sc.*, 1959, **81**, 723.
21. Revel, J. P., Ito, S., and Fawcett, D. W. Electron micrographs of myelin figures of phospholipide simulating intracellular membranes. *J. Biophysic. and Biochem. Cytol.*, 1958, **4**, 495.
22. Gross, J. A study of certain connective tissue constituents with the electron microscope, *Ann. New York Acad. Sc.*, 1950, **52**, 964.
23. Bettelheim, F. A., and Philpott, D. E., Electron microscopic studies of hyaluronic acid-protein gels, *Biochim. et Biophysica Acta.*, 1959, **34**, 124.
24. Miller, F., and Bohle, A., Vergleichende licht-und elektronmikroskopische untersuchungen an der basalmembran der glomerulumcapillaren der maus bei experimentellem nierenamyloid, *Klin. Woch.*, 1956, **34**, 1204.
25. Feldman, J. D., Electron microscopy of serum sickness nephritis, *J. Exp. Med.*, 1958, **108**, 957.
26. Sharp, J. T., Taft, E., and Cohen, A. S., The production of experimental renal disease in mice by streptococcal infection, *Clin. Research*, 1960, in press.
27. Proceedings of the 10th Annual Conference on the Nephrotic Syndrome, (J. Metcoff, editor), 1959.
28. Bergstrand, A., and Bucht, H., The glomerular lesions of diabetes mellitus and their electron microscopic appearances, *J. Path. and Bact.*, 1959, **77**, 231.
29. Farquhar, M. G., Hopper, J., Jr., and Moon, H. D., Diabetic glomerulosclerosis: Electron and light microscopic studies, *Am. J. Path.*, 1959, **35**, 721.
30. Bohle, A., Sitte, H., and Miller, F., Elektronenmikroskopische untersuchungen am glomerulum des Kaninchens beim generalisierten Shwartzman-Phänomen Verhand, *Deutsch. Ges. Path.*, 1957, **7**, 326.
31. Pappas, G. D., Ross, M. H., and Thomas, L., Studies on the generalized Shwartzman reaction, *J. Exp. Med.*, 1958, **107**, 333.
32. Cohen, A. S., and Calkins, E., Electron microscopic observations on a fibrous component in amyloid of diverse origins, *Nature*, 1959, **183**, 1202.

33. Spiro, D., Structural basis of proteinuria in man, *Am. J. Path.*, 1959, **35**, 47.
34. Geer, J. C., Strong, J. P., McGill, H. C., Jr., and Muslow, I., Electron microscopic observations on the localization of amyloid in the kidney in secondary amyloidosis, *Lab. Inv.*, 1958, **7**, 554.
35. Farquhar, M., Review of normal and pathologic glomerular ultrastructure, *Proc. 10th Ann. Conf. Nephrotic Syndrome*, (J. Metcoff, editor), 1959, 2.
36. Miller, F., personal communication.
37. Movat, H. Z., The fine structure of the glomerulus in amyloidosis, *Arch. Path.*, 1960, **69**, 323.
38. Jackson, S. F., and Smith, R. H., Fibrogenesis of connective and skeletal tissues in the embryonic fowl, Society for Experimental Biology Symposia No. IX, Fibrous proteins and their biologic significance, New York, Academic Press, Inc., 1955, 89.

EXPLANATION OF PLATES

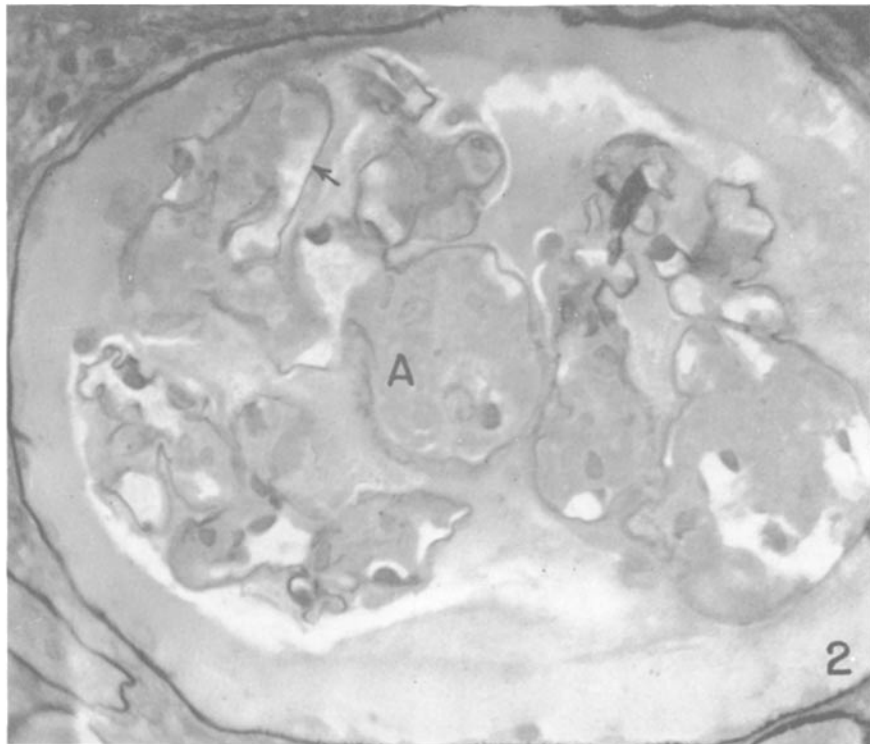
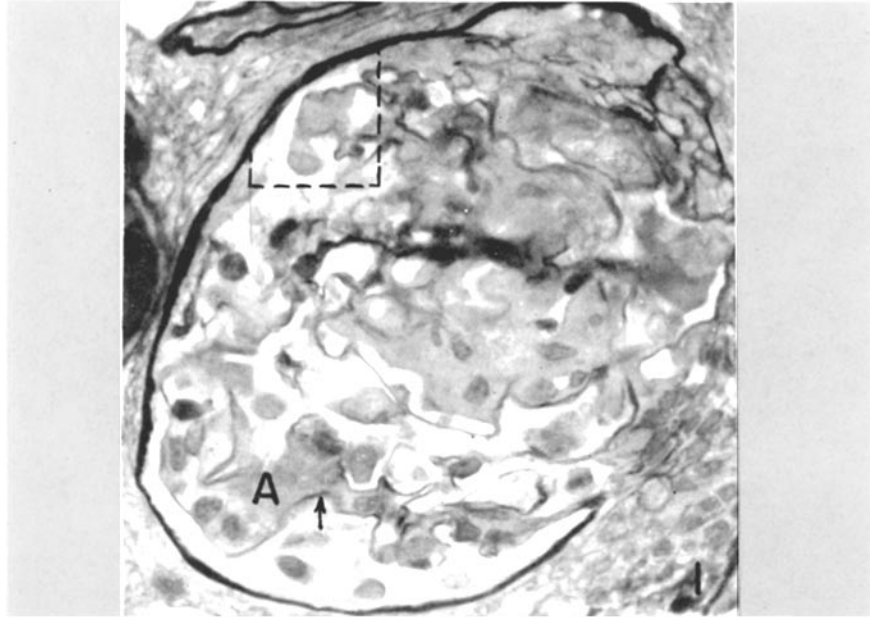
Sections illustrated in Figs. 1 and 2 are osmium-fixed, "thick" sections, cut on a Porter-Blum microtome and stained with periodic acid-Schiff (PAS) reagent. The remainder of the figures are electron micrographs serial to areas in which amyloid had been identified by light and phase microscopy. All material was osmium-fixed, dehydrated, and embedded as described in the text.

Key to Abbreviations

<i>A</i> , amyloid	<i>END</i> , endothelial cell
<i>BM</i> , basement membrane	<i>EPI</i> , epithelial cell
<i>BS</i> , Bowman's space	<i>FP</i> , foot process
<i>CL</i> , capillary lumen	<i>MIT</i> , mitochondria
<i>CP</i> , cytoplasmic processes	<i>N</i> , nucleus
<i>CYT</i> , cytoplasm	<i>RBC</i> , red blood cells
	<i>V</i> , vacuole

PLATE 40

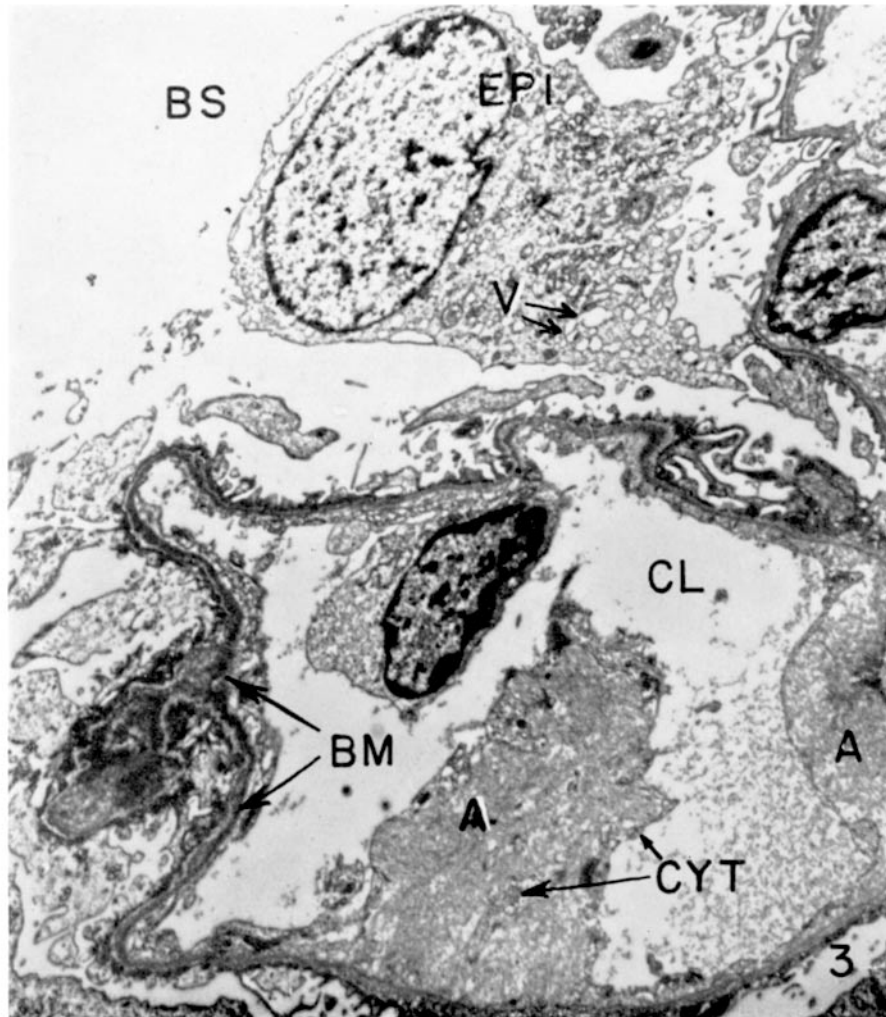
FIGS. 1 and 2. Light microscopic illustrations of the renal glomerulus in amyloidosis. Basement membrane (arrows) stains distinctly with PAS, while amyloid (*A*) is faintly positive. The amyloid appears to accumulate on the endothelial side of the capillary lumen and almost completely occludes it. Area enclosed by dotted lines is serial to electron micrograph in Fig. 3. $\times 500$.



(Cohen and Calkins: Structure of kidney in casein-induced amyloidosis)

PLATE 41

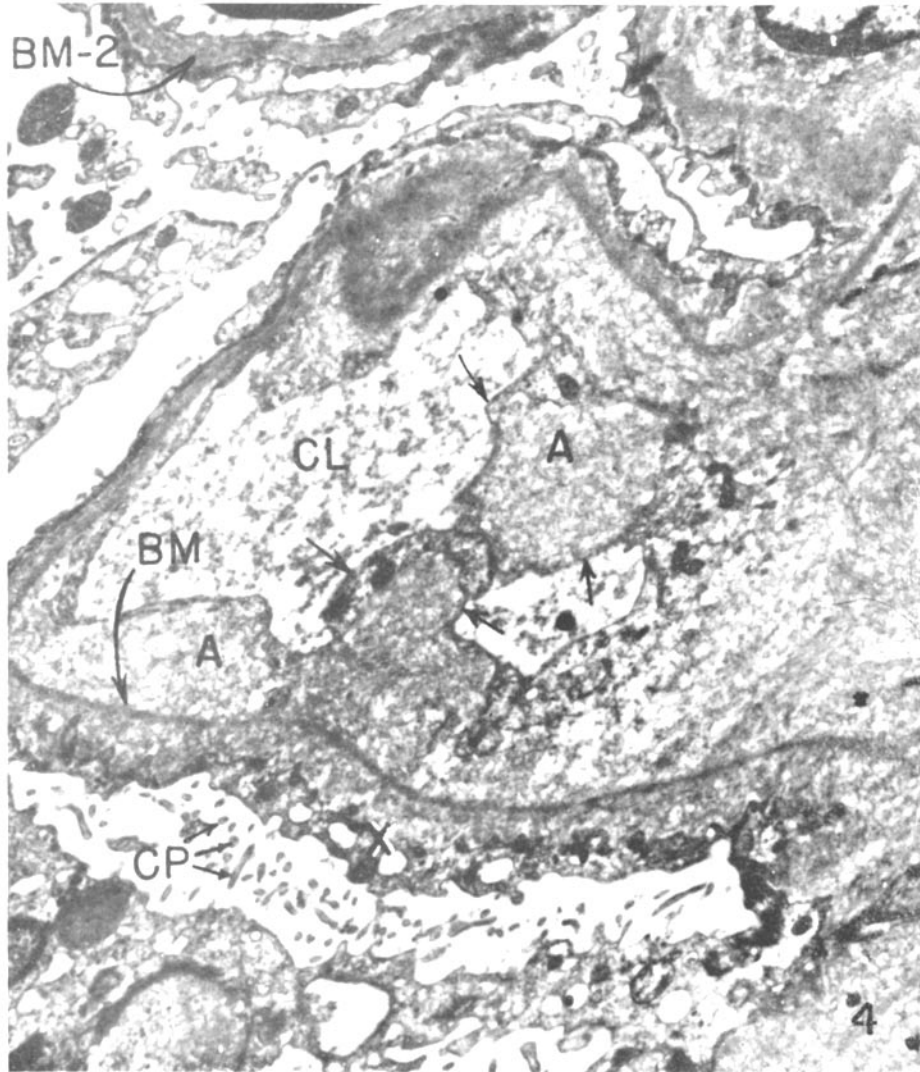
FIG. 3. Electron micrographs of glomerular loop serial to that enclosed in dotted lines in Fig. 1. Multiple small vacuoles (*V*) are present in the cytoplasm of the epithelial cell at the top of the micrograph. In the lower glomerular loop one large deposit of amyloid (*A*) can be observed, plus small amounts adjacent to the basement membrane on the right. The large amyloid deposit is broken up by cytoplasmic projections (*CYT*). Basement membrane is intact throughout, though cut somewhat tangentially near the upper arrow. $\times 4900$.



(Cohen and Calkins: Structure of kidney in casein-induced amyloidosis)

PLATE 42

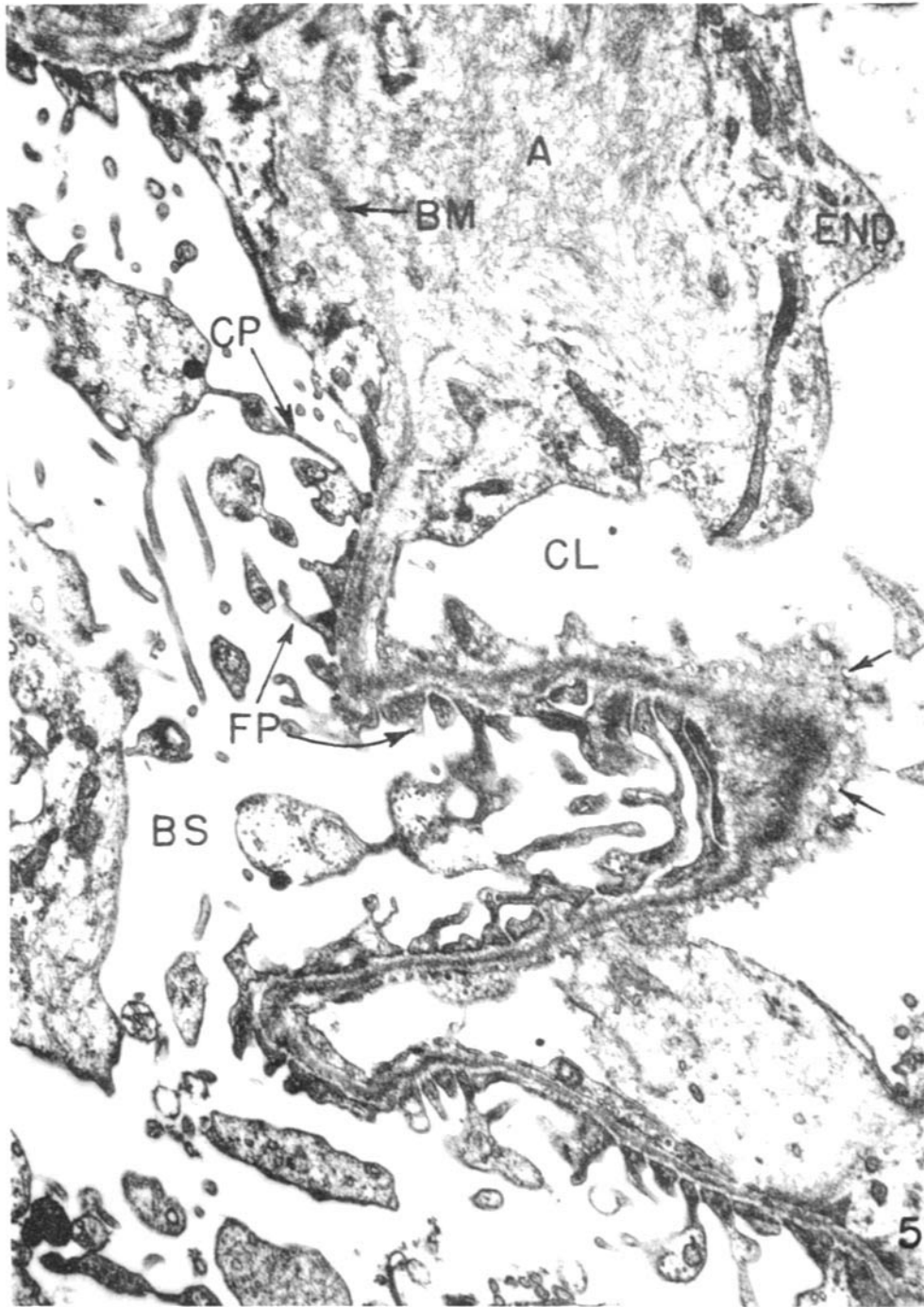
FIG. 4. Glomerular loop with diffuse accumulation of amyloid (*A*) on both sides of basement membrane (*BM*). The latter structure is continuous throughout the amyloid but lacks the lamina rara interna and externa. The epithelial cell foot processes are fused (*X*) and connect to the cell body by thin cytoplasmic processes (*CP*) seen in cross and longitudinal sections. The amyloid is finely fibrous and is separated from capillary lumen by a thin layer of endothelial cytoplasm (arrows). Thickening of basement membrane of upper glomerular loop to almost 3000 Å is apparent (*BM-2*).
× 10,100.



(Cohen and Calkins: Structure of kidney in casein-induced amyloidosis)

PLATE 43

FIG. 5. This portion of one glomerular loop is cut tangentially at the center of the illustration, where endothelial pores (arrows) are demonstrable. The endothelial cytoplasm above this area separates the capillary lumen on the right from the amyloid (*A*). The latter substance consists of fine fibrils in random array. Basement membrane runs through the amyloid. Epithelial cell foot processes (*FP*) retain their identity at the lower part of the illustration but are fused above in the area adjacent to the amyloid. The area cut tangentially shows normal appearing slit pores, while above it thin filamentous cytoplasmic processes (*CP*) connect the foot processes to epithelial cell body. $\times 19,500$.

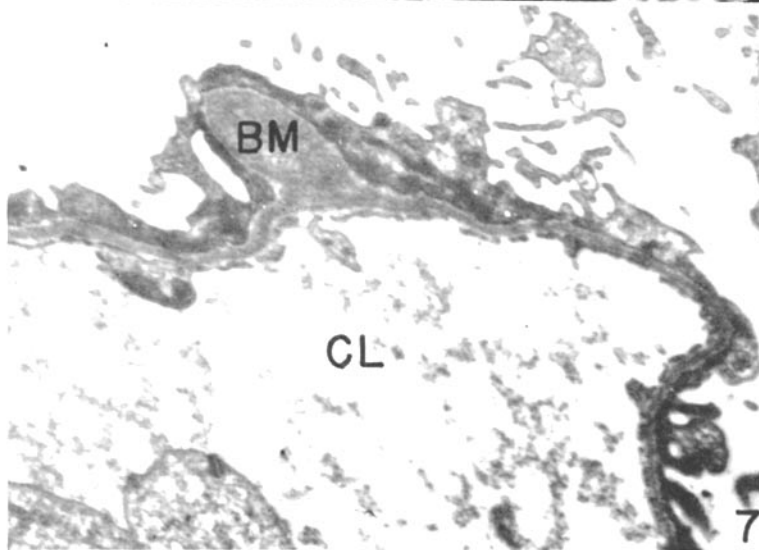
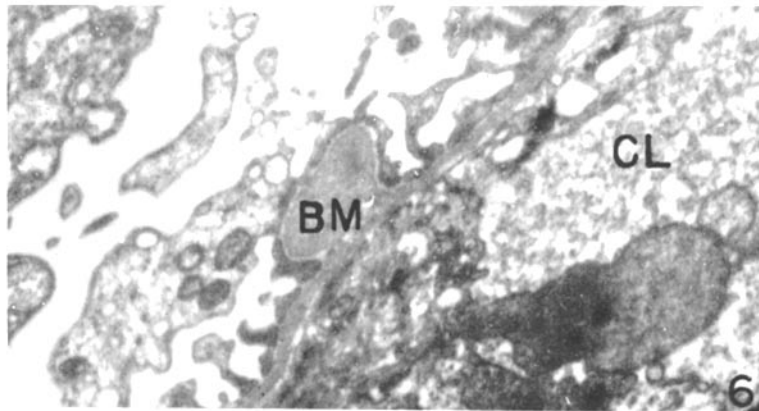


(Cohen and Calkins: Structure of kidney in casein-induced amyloidosis)

PLATE 44

FIG. 6. This portion of the glomerular loop demonstrates a protrusion of the basement membrane on the epithelial side. The rabbit had received casein injections for 10 months. $\times 12,600$.

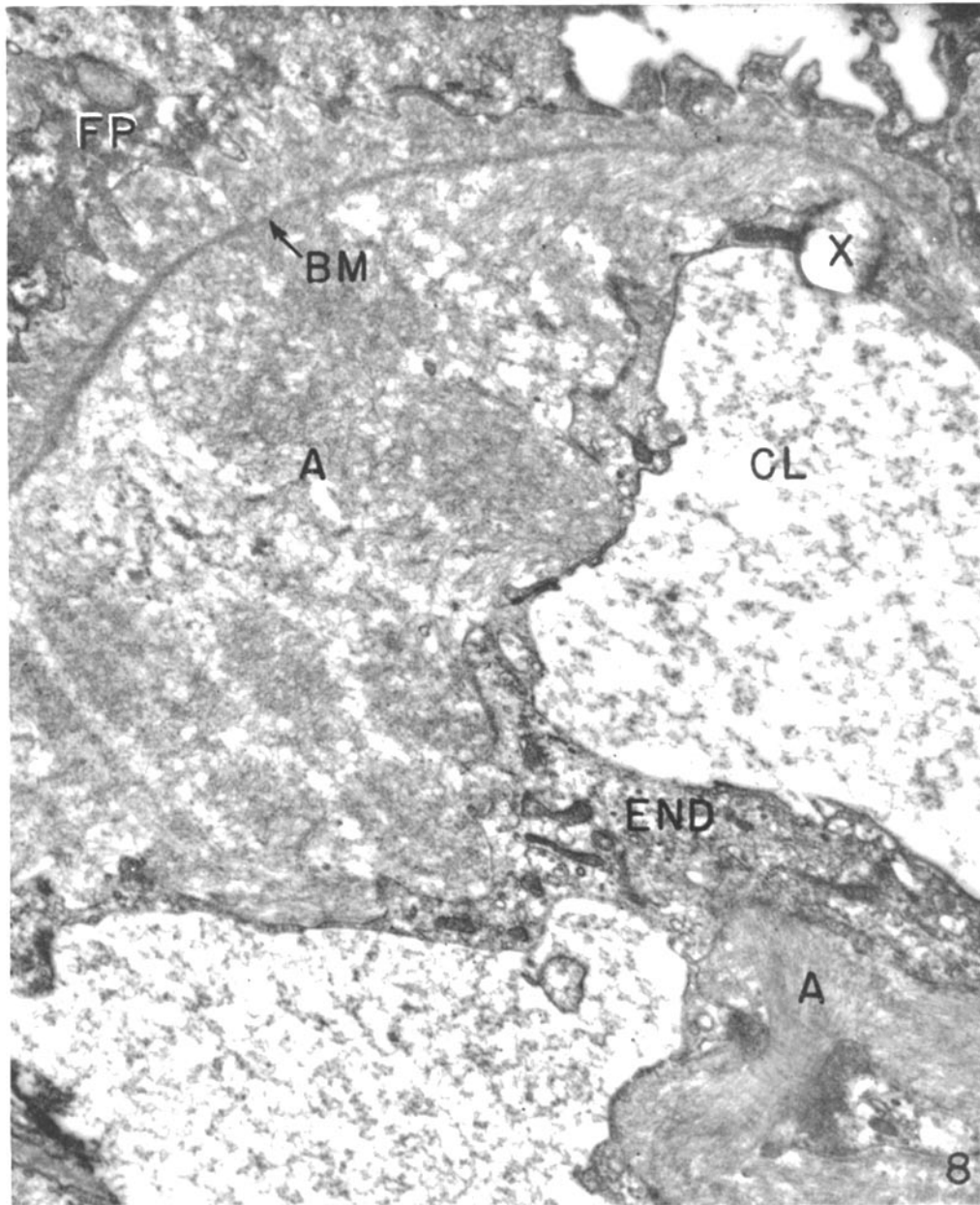
FIG. 7. Glomerular loop of a rabbit which received casein for 5 months. Thickening and protrusion (*BM*) into fused epithelial foot processes is noted. $\times 12,000$.



(Cohen and Calkins: Structure of kidney in casein-induced amyloidosis)

PLATE 45

FIG. 8. Amyloid (*A*)—laden glomerular loop with normal endothelial cytoplasm covering the fibrous material. The basement membrane seen clearly here has amyloid on epithelial side, abutting the fused foot processes. Area in lower right is enlarged in Fig. 9. The circle at *X* is an artifact. $\times 17,300$.

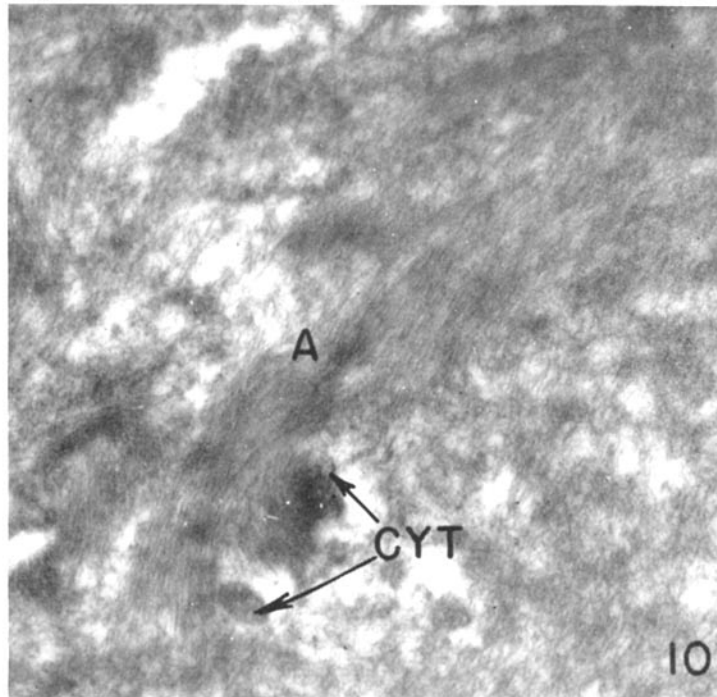
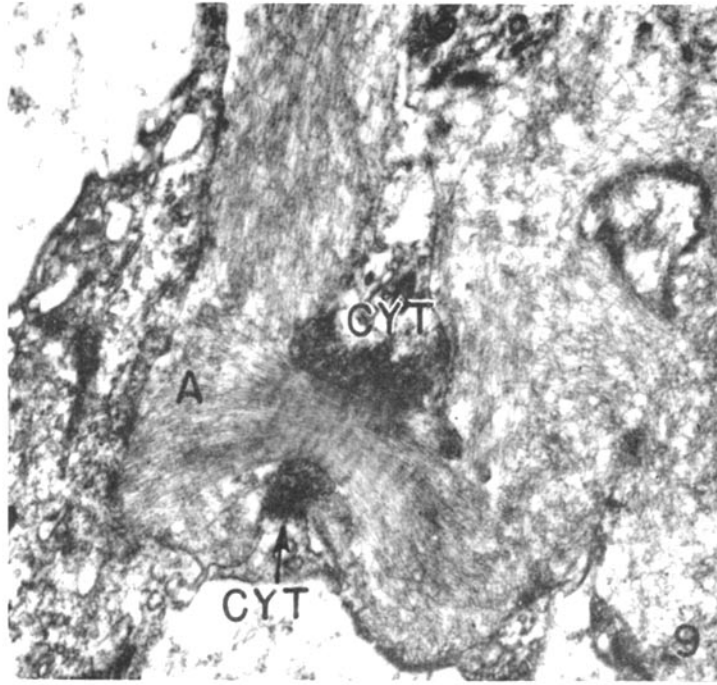


(Cohen and Calkins: Structure of kidney in casein-induced amyloidosis)

PLATE 46

FIG. 9. In this enlargement of a portion of the glomerular loop seen in Fig. 8, the amyloid fibrils are aligned in a bundle as they course between 2 projections of the endothelial cytoplasm. $\times 23,700$.

FIG. 10. Groups of amyloid fibrils (*A*) appear to be oriented about cytoplasmic projections of the endothelial cell (*CYT*). $\times 30,400$.



(Cohen and Calkins: Structure of kidney in casein-induced amyloidosis)