

## CASE REPORT

# A phototoxic drug reaction due to topical NSAIDs

Jakob Lillemoen Drivenes<sup>1</sup>  | Martin Berg-Jensen<sup>1</sup> | Anette Bygum<sup>2</sup>

<sup>1</sup>Emergency Department, Vestfold Hospital, Tonsberg, Norway

<sup>2</sup>Department of Clinical Genetics, Odense University Hospital and Clinical Institute, University of Southern Denmark, Odense, Denmark

**Correspondence**

Jakob Lillemoen Drivenes, Vestfold Hospital, Halfdan Wilhelmsens alle 17, 3103, Tonsberg, Norway.  
Email: jakobdrivenes@hotmail.com

**Funding information**

No funding was received

**Abstract**

We present a case with a phototoxic reaction following topical use of NSAID. The phototoxic reaction was initially mistaken for cellulitis which led to treatment with dicloxacillin, which led to an exanthematous drug eruption. The patient was treated with topical clobetasol propionate and oral non-sedating antihistamines. Follow-up revealed post-inflammatory hypopigmentation.

**KEYWORDS**

dicloxacillin, drug-induced photosensitivity, ketoprofen, photoreaction, photosensitivity, phototoxic reaction

## 1 | INTRODUCTION

Photosensitization is a skin hypersensitivity to light and is classified into photoallergic and phototoxic reactions. It manifests as an acute eczema-like reaction, similar to sunburn, characterized by erythema, edema, and blistering.<sup>1</sup> Photoallergic reactions are a delayed hypersensitivity reaction (type IV reaction) with a sensitization phase of 10–14 days.<sup>2</sup> However, when allergy has developed, eczema may manifest a few days after exposure. Phototoxic reactions, in contrast to the photoallergic, are more common and are initiated by damage to the skin that occurs by direct skin contact between an allergenic or irritant substance when irradiated with ultraviolet radiation.<sup>2</sup> Both types of photoreactions are most often triggered by long-wave ultraviolet sunlight (UV-A) but can also be triggered by short-wave ultraviolet sunlight (UV-B) and visible light. UV-A rays can penetrate window glass and thin textiles.<sup>3</sup> Therefore, photoreactions can occur indoors, when driving a car, and through lighter clothing. Photoreactions can also occur in cloudy weather, where only part of the ultraviolet radiation is reflected and scattered.<sup>3</sup> Agents that trigger photoreactions have a di- or tricyclic configuration

weighing between 300 and 500 g/mol.<sup>4</sup> When interacting with ultraviolet light, their molecular structure absorbs light leading to the molecules becoming excited and emit energy, causing cell damage in the skin.<sup>4</sup> The most common agents include antibiotics such as doxycycline and tetracycline, sulfonamides such as furosemide, and topical nonsteroidal anti-inflammatory drug (NSAIDs) such as naproxen and ketoprofen.<sup>5,6</sup>

## 2 | CASE PRESENTATION

A 52-year-old Caucasian man was admitted to the emergency department with a skin lesion on his right elbow. His medical history revealed a diagnosis of Addison's disease, requiring lifelong corticosteroid substitution. He was otherwise healthy, apart from difficulties with lateral epicondylitis during the past year. Seven days prior to admission, the patient developed severe redness around the right elbow with the sensation of intense burning and stinging. The redness materialized after working in his garden on a cloudy summer day. During the following days, his elbow began to swell and blisters developed and

This is an open access article under the terms of the Creative Commons Attribution-NonCommercial-NoDerivs License, which permits use and distribution in any medium, provided the original work is properly cited, the use is non-commercial and no modifications or adaptations are made.

© 2022 The Authors. *Clinical Case Reports* published by John Wiley & Sons Ltd.

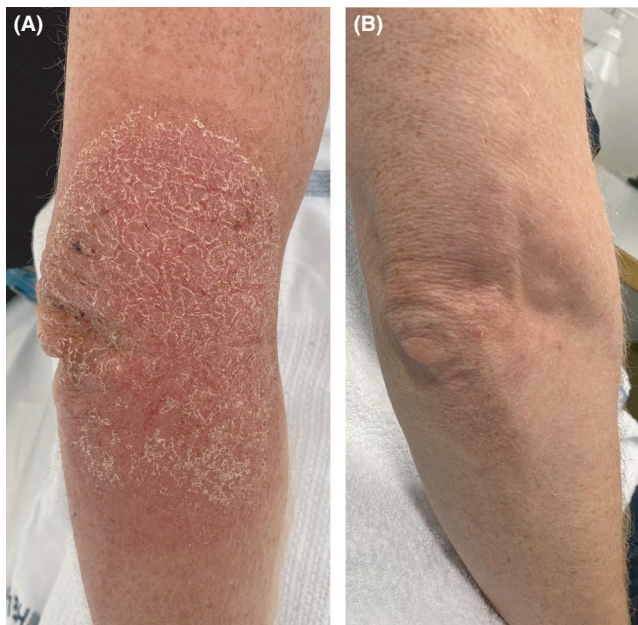
later ruptured and formed crusts. His general practitioner suspected cellulitis and prescribed dicloxacillin capsules. After 2 days, the patient developed generalized itchy skin and a rash on his chest and abdomen.

Physical examination in the emergency department revealed a bright red edematous and crusted erythema on the right elbow “Figure 1A.” An additional maculopapular rash was found on the trunk “Figure 2.” Laboratory analysis results including C-reactive protein and complete blood count were within normal ranges.

The patient had a phototoxic reaction caused by ketoprofen, an NSAID, and a drug rash caused by dicloxacillin. The phototoxic reaction developed at the elbow before dicloxacillin was administered. A thorough medical history revealed that the patient had applied topical ketoprofen on his right elbow due to his lateral epicondylitis. He had been gardening wearing a t-shirt on a cloudy summer day. The phototoxic reaction was initially mistaken for cellulitis which led to treatment with dicloxacillin, which led to an exanthematous drug eruption.

### 3 | OUTCOME AND FOLLOW-UP

The patient was instructed to discontinue the use of the topical NSAID and dicloxacillin and was treated with topical clobetasol propionate 0.05% and oral non-sedating antihistamines. He was advised against the use of topical NSAIDs and dicloxacillin in the future.



**FIGURE 1** (A) A bright red edematous and crusted erythema on the right elbow. (B) 6-week follow-up, there was post-inflammatory hypopigmentation in the area

At 6-week follow-up, the lesion on the right elbow was healed, with post-inflammatory hypopigmentation “Figure 1B.” Remarkably also his freckles in the area had disappeared. The truncal rash vanished after 1 week.

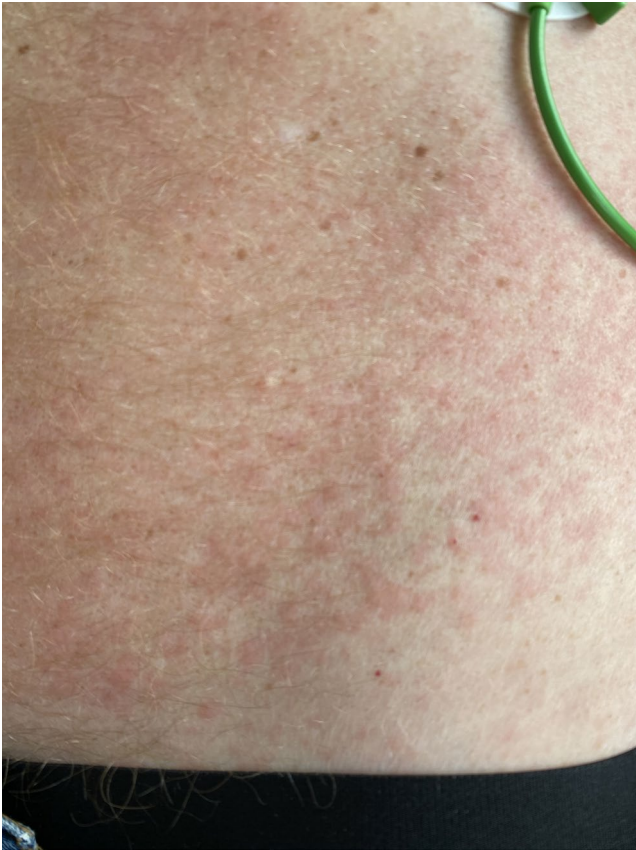### 4 | DIFFERENTIAL DIAGNOSIS, INVESTIGATIONS, AND TREATMENT

Differential diagnosis for phototoxic reactions should include all types of nonspecific dermatitis. Ways of approaching the diagnosis include noticing the distribution of the lesions, in that skin under the chin, nose, and other areas may be lesion-free due to protection from direct sun exposure. Phototoxic reactions are dose-dependent and predictable, in the sense that the severity of the reaction depends on the amount of ultraviolet radiation exposure as well as the drug dose. Furthermore, phototoxic reactions occur relatively shortly after acute intense sun exposure, in contrast to photoallergic reactions and some types of porphyrias. In some cases, leukocytoclastic vasculitis (LCV) can present with similar clinical findings such as bullae or plaques in addition to burning, stinging, and itching. LCV is a type of small vessel vasculitis, where the most common finding is palpable purpura. In our patient, no purpuric skin lesions were identified. A skin biopsy will confirm the diagnosis of LCV.<sup>7</sup> In contrast, the diagnosis of phototoxic reactions is often performed in a clinical setting by identifying the causative phototoxic agent. It may require a dermatological examination with photo tests in some cases, while photopatch tests in general have been contraindicated, and a skin biopsy is rarely needed.<sup>1</sup> Treatment consists of cessation of the offending agents and the use of a topical corticosteroid and cool moist wraps. In some cases, treatment with systemic glucocorticoids may be considered. Sequelae in the form of hyperpigmentation and milia can occur due to the erythema and blistering. In severe cases, scars and hypopigmentation may also occur.

### 5 | DISCUSSION

Photosensitivity disorders can be classified into four groups: chemical- and drug-induced photosensitivity, immunologically mediated photosensitivity, photoaggravated photosensitivity, and inherited disorders with chromosomal instability or defective DNA repair.

Causes of chemical- and drug-induced photosensitivity have already been mentioned, but it should be noted that endogenous agents such as uroporphyrin in porphyria cutanea tarda can contribute to this type of photosensitivity disorder. The immunologically mediated



**FIGURE 2** A maculopapular rash located on the trunk

photosensitivity disorders consist of actinic prurigo, chronic actinic dermatitis, polymorphous light eruption, and solar urticaria. They are called primary idiopathic photosensitivity disorders due to the fact that they are disorders composed of ultraviolet radiation-induced lesions with an unrecognized cause. Photoaggravated photosensitivity, on the other hand, are called secondary photosensitivity disorders since they arise from increased sensitivity to ultraviolet radiation coming from an underlying disease, such as bullous pemphigoid or systemic lupus erythematosus. Some of the inherited disorders with chromosomal instability or defective DNA repair include Bloom syndrome, trichothiodystrophy, and xeroderma pigmentosum.<sup>1</sup>

Although the incidence of photosensitivity is low, phototoxic reactions are more common than photoallergic reactions.<sup>8</sup> It seems that older persons are more prone to developing them. The prevalence is unknown.<sup>9</sup> The peculiarity of this case is that the phototoxic reaction the patient developed was wrongly diagnosed as a skin infection at first, which led to antibiotic therapy, which caused yet another problem and discomfort for the patient. Photosensitivity disorders can be a challenging diagnosis for patients and physicians alike, but they should be considered in cases where skin lesions arise following

sun exposure or exposure to known photosensitizing agents. The European Medicines Agency's Committee for Medicinal Products for Human Use concluded that although the adverse effect of skin photosensitivity reactions following use of topical ketoprofen are serious, the benefit-risk balance is favorable.<sup>10</sup>

This case report highlights the importance of properly educating patients that are prescribed medications that make them predisposed to drug-induced photosensitivity.

#### **ACKNOWLEDGEMENT**

None.

#### **CONFLICT OF INTEREST**

The authors declare no conflict of interest.

#### **AUTHOR CONTRIBUTIONS**

JLD wrote the first draft, edited the final version of the manuscript, and was involved in the care of the patient. MBJ commented the final version of the manuscript and was involved in the care of the patient. AB commented, co-wrote, and edited the first draft and the final version of the manuscript.

#### **ETHICAL APPROVAL**

The authors have not received any funding sources nor were they paid to write this case report. The patient has provided written informed consent for the publication of this case report.

#### **CONSENT**

Written consent for publication has been obtained from the patient.

#### **DATA AVAILABILITY STATEMENT**

Data sharing not applicable to this article as no datasets were generated or analysed during the current study.

#### **ORCID**

Jakob Lillemoen Drivenes  <https://orcid.org/0000-0001-8649-1434>

#### **REFERENCES**

1. Kutlubay Z, Sevim A, Engin B, Tüzün Y. Photodermatoses, including phototoxic and photoallergic reactions (internal and external). *Clin Dermatol*. 2014;32(1):73-79. doi:10.1016/j.clindermatol.2013.05.027
2. Blakely KM, Drucker AM, Rosen CF. Drug-induced photosensitivity-an update: culprit drugs, prevention and management. *Drug Saf*. 2019;42(7):827-847. doi:10.1007/s40264-019-00806-5
3. Dale Wilson B, Moon S, Armstrong F. Comprehensive review of ultraviolet radiation and the current status on sunscreens. *J Clin Aesthet Dermatol*. 2012;5(9):18-23. Accessed August 24, 2021

4. Glatz M, Hofbauer GF. Phototoxic and photoallergic cutaneous drug reactions. *Chem Immunol Allergy*. 2012;97:167-179. doi:10.1159/000335630
5. Monteiro AF, Rato M, Martins C. Drug-induced photosensitivity: photoallergic and phototoxic reactions. *Clin Dermatol*. 2016;34(5):571-581. doi:10.1016/j.clindermatol.2016.05.006
6. Kim WB, Shelley AJ, Novice K, Joo J, Lim HW, Glassman SJ. Drug-induced phototoxicity: a systematic review. *J Am Acad Dermatol*. 2018;79(6):1069-1075. doi:10.1016/j.jaad.2018.06.061
7. Fraticelli P, Benfaremo D, Gabrielli A. Diagnosis and management of leukocytoclastic vasculitis. *Intern Emerg Med*. 2021;16(4):831-841. doi:10.1007/s11739-021-02688-x
8. Lehmann P, Schwarz T. Photodermatoses: diagnosis and treatment. *Dtsch Arztebl Int*. 2011;108(9):135-141. doi:10.3238/arztebl.2011.0135
9. Korzeniowska K, Cieślęwicz A, Chmara E, Jablecka A, Pawlaczyk M. Photosensitivity reactions in the elderly population: questionnaire-based survey and literature review. *Ther Clin Risk Manag*. 2019;15:1111-1119. doi:10.2147/TCRM.S215308
10. European Medicines Agency. European medicines agency confirms positive benefit-risk balance of topical formulations of ketoprofen [Internet]. [https://www.ema.europa.eu/en/documents/press-release/european-medicines-agency-confirms-positive-benefit-risk-balance-topical-formulations-ketoprofen\\_en.pdf](https://www.ema.europa.eu/en/documents/press-release/european-medicines-agency-confirms-positive-benefit-risk-balance-topical-formulations-ketoprofen_en.pdf) Accessed August 24, 2021

**How to cite this article:** Drivenes JL, Berg-Jensen M, Bygum A. A phototoxic drug reaction due to topical NSAIDs. *Clin Case Rep*. 2022;10:e05251. doi:[10.1002/ccr3.5251](https://doi.org/10.1002/ccr3.5251)