

Available online at www.sciencedirect.com

ScienceDirect

Biomedical Journal

journal homepage: www.elsevier.com/locate/bj

Original Article

Two additional augmenting screws with posterior short-segment instrumentation without fusion for unstable thoracolumbar burst fracture – Comparisons with transpedicular grafting techniques



Yu-Chih Lin, Kuo-Fon Fan, Jen-Chung Liao*

Department of Orthopedic Surgery, Chang Gung Memorial Hospital at Linkou, Chang Gung University College of Medicine, Taoyuan, Taiwan

ARTICLE INFO

Article history:

Received 26 December 2014

Accepted 8 March 2016

Available online 21 December 2016

Keywords:

Thoracolumbar burst fracture

Posterior short-segment instrumentation

Transpedicular grafting

Augmenting screw

ABSTRACT

Background: Transpedicular grafting techniques with posterior short-segment instrumentation have demonstrated to prevent high implant failure in unstable thoracolumbar burst fractures. We tested our hypothesis that short-segment instrumentation with two additional augmenting screws in the injured vertebra could provide stability and was similar to those of the transpedicular grafting technique.

Methods: Twenty patients belonged to group A; treated with short-segment pedicle screw fixation and reinforced by two augmenting screws at the fractured vertebra. Group B had thirty-one patients; the fractured vertebra was augmented with transpedicular autogenous bone graft. Group C had twenty patients; the injured vertebra was strengthened with calcium sulfate cement. Clinical outcome and radiographic parameters were compared.

Results: Group A had the least blood loss (101.7 ± 72.5 vs. 600 ± 403.1 vs. 247.5 ± 164.2 ml, $p < 0.001$) and the least operation time (142.0 ± 57.2 vs. 227.2 ± 43.6 vs. 161.6 ± 28.5 min, $p < 0.001$). However, group A had the highest collapsed rate of the body height at the 18-month follow-up (10.5 ± 7.0 vs. 4.6 ± 4.8 vs. $7.2 \pm 8.5\%$, $p = 0.002$). The failure rate, include implant failure or loss of 10° or more of correction, group B had the lowest failure rate (10% vs. 3.2% vs. 10%, $p = 0.542$). The group A had the highest rate of return to their previous employment (50% vs. 38% vs. 35%, $p = 0.265$).

Conclusions: Compared with transpedicular grafting techniques, additional two “augmenting screws” in the fracture vertebra with short-segment instrumentation are sufficient for one-level thoracolumbar burst fracture.

* Corresponding author. Department of Orthopedic Surgery, Chang Gung Memorial Hospital at Linkou, 5, Fusing St., Gueishan, Taoyuan 333, Taiwan. Tel.: +886 3 3281200ext.2423; fax: +886 3 3278113.

E-mail address: jcl1265@adm.cgmh.org.tw (J.-C. Liao).

Peer review under responsibility of Chang Gung University.

<http://dx.doi.org/10.1016/j.bj.2016.11.005>

2319-4170/© 2016 Chang Gung University. Publishing services by Elsevier B.V. This is an open access article under the CC BY-NC-ND license (<http://creativecommons.org/licenses/by-nc-nd/4.0/>).

At a glance commentary

Scientific background on the subject

Unstable thoracolumbar burst fracture is usually treated by surgery. One above and one below posterior short-segment pedicle screw fixation is popular for thoracolumbar burst fracture but has possibility of early implant failure and loss of reduction. The injured vertebrae augmented by additional two screws or by transpedicular grafting are thought to be resolutions to prevent implant failure. In this study, we compared the differences between a six-screw construct and a four-screw construct with fractured body augmentation by iliac cancellous bone graft or by calcium sulfate cement.

What this study adds to the field

Compared with transpedicular grafting techniques, additional two "augmenting screws" in the fracture vertebra with short-segment instrumentation are also sufficient for most one-level thoracolumbar burst fracture. This technique is easy, spends less operation time, decreases blood loss, and obtains similar clinical result.

Burst fracture approximately accounts for 20% of thoracolumbar fractures and occurs due to an axial loading force that results in failure to support the anterior and middle column [1,2]. Surgery is usually indicated for a patient suffering from severe deformity, and/or neurologic deficit. Since the development of the pedicle screw, posterior short-segment instrumentation with fusion has been widely used for unstable thoracolumbar burst fracture. Pedicle instrumentation enables kyphosis correction, canal encroachment reduction indirectly, early mobilization, and early return to work. However, this method has been reported to have high implant failure and early loss of reduction because of loss of anterior support [3]. Liao et al. have demonstrated that posterior short-segment instrumentation and transpedicular grafting with autogenous cancellous bone could maintain better vertebral body height and local sagittal Cobb's angle, but donor-site complications could not be prevented [4]. Although injectable calcium sulfate cement is an alternative to autogenous bone for transpedicular body augmentation, the cost of this material is not covered by the National Health Insurance in Taiwan. To circumvent the difficulties we faced before in using transpedicular grafting with autogenous bone and calcium sulfate cement, we modified Wang's technique for treating thoracolumbar burst fracture [5]. In this study, we applied two more "augmenting screws" at both pedicles of the injured vertebra in addition to one-above one-below short-segment pedicle instrumentation. We hypothesized that these two additional pedicle screws at the fractured vertebra could augment construction of instrumentation and the spine could be maintained when the anterior and middle column achieved union, as in transpedicular grafting. In January 2010, we

began to use this method in patients with a single-level thoracolumbar burst fracture. The purpose of this study was to evaluate the efficacy of all pedicle screws without fusion used in patients with thoracolumbar burst fracture and to decide whether this technique could achieve clinical and radiographic results similar to those of short-segment instrumentation with transpedicular grafting for thoracolumbar burst fracture.

Methods

From January 2010 to June 2012, twenty patients with thoracolumbar burst fracture that underwent surgical treatment using posterior short-segment pedicle instrumentation without fusion were reviewed. These patients were enrolled because they met the following inclusion criteria: (a) a single-level fracture between T11 and L3; (b) only short-segment screws (one-above and one-below) were used and the fractured vertebra were augmented with two additional screws; (c) fracture caused by high energy trauma (fall from a height, motor vehicle accident, or direct strike by a heavy object); (d) a local kyphotic angle $>20^\circ$, or anterior height collapse $>50\%$, or spinal canal encroachment $>50\%$; (e) implants were removed after one year with union of the vertebrae proved by image; (h) follow-up radiographic and clinical data for at least 18 months were obtained.

Preoperative, immediate postoperative, and 18-month follow-up plain radiographs were analyzed. Sagittal local kyphosis was measured from the superior endplate of the cephalic intact vertebra to the inferior endplate of the caudal intact vertebra. The normal height of the fractured vertebrae on lateral radiographs was determined by averaging the heights of the adjacent cephalic and caudal vertebrae. The percentage of anterior height of the fractured vertebra was calculated as the anterior height of the injured vertebra/the estimated normal anterior height of the injured vertebra $\times 100\%$. The percentage of canal encroachment by the retropulsed fragment at the fractured level was calculated using the formula developed by Mumford et al. [6].

The American Spinal Injury Association (ASIA) impairment scale was used to evaluate patients' preoperative and final neurologic status. The final clinical results were assessed using the Denis scale, a 5-point scale that includes both work and pain scales [7]. The demographic data, including age, sex, injury level, estimated blood loss, operation time, duration of admission, time between injury and surgery, and associated injuries, were collected.

Grouping

The 20 patients that underwent posterior short-segment instrumentation with two additional "augmenting screws" were placed into Group A. The 31 patients that underwent posterior short-segment instrumentation and transpedicular grafting with autogenous cancellous bone were categorized as Group B, and the 20 patients that received posterior short-segment instrumentation and transpedicular grafting with calcium sulfate cement comprised Group C. The demographic data of Group B and Group C were the same as shown in Liao's

study [4]. However, the final cut-off point of radiographic assessment was at the 18-month follow-up, so the radiographic data of Groups B and C were re-calculated and analyzed in the current study.

Surgical procedure

All patients were placed in the prone position on the four-poster. Posture and manual reduction were applied first. After the skin was draped and prepared, a standard posterior midline approach was used to explore the spine. Pedicle screws were inserted into the vertebra one level above and one level below the fractured vertebra. Two additional pedicle screws were inserted into both pedicles of the injured vertebra for additional fixation. The rod was bent slightly, and being connected on the screws. The augmenting screws could push the fractured vertebra ventrally as the rod was connecting to it. Then a distraction force was applied by using the spreader forceps to correct local kyphosis and restore anterior body height [Fig. 1].

Transpedicular grafting with morcellized cancellous bone or injectable calcium sulfate cement has been demonstrated by Liao et al. [4] None of the patients in these three groups received posterior or posterolateral fusion. All patients were encouraged to sit and ambulate on the second or third post-operative day with a Taylor's brace protection.

All patients had undergone surgery to remove the implant and the implant's condition was examined. Surgery was considered a failure if screws or the rod was broken, or if radiographs obtained at final follow-up demonstrated an increase of 10° or more in sagittal local kyphosis compared to the local kyphotic angle measured immediately after surgery.

Statistics

We first used the ANOVA and the Wilcoxon rank-sum test to analyze numerical data between these three groups, the level of statistical significance was set at $p < 0.01$. Then, further analyzed with the paired t test for differences between pre-operative, postoperative, and 18-month follow-up radiographic data inside each group. Fisher's exact test was used for categorical variables. The level of statistical significance was set at $p < 0.05$.

Results

There were 20 patients in Group A, 31 in Group B, and 20 in Group C. Ten patients in Group A were female and ten were male; the average age at surgery was 43.0 ± 10.4 years. Four patients were injured in motor vehicle accidents, 15 were injured by falling from a height, and one was injured by being struck by a heavy object. Six patients in Group A had other associated injuries: two with hemothorax, two with pelvic fracture or sacral fracture, one with femur fracture, one with ocular and head injury, one with calcaneal fracture, and one with olecranon fracture. Most patients (11) in Group A were injured at the L1 level. The mean operation time was 142.0 ± 57.2 min. The mean estimated blood loss was 101.7 ± 72.5 ml. The mean hospital stay was 11.5 ± 3.8 days,

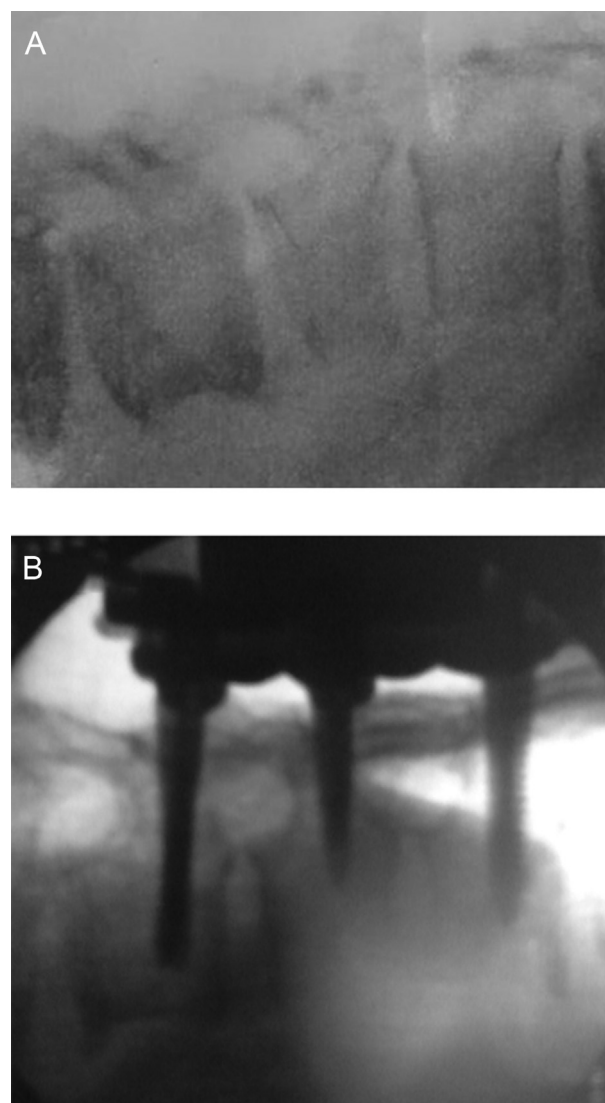


Fig. 1 – Intra-operative fluoroscopic images illustrate the surgical procedure. (A) Before skin incision, the injured vertebra was reduced by manual reduction. (B) The fractured vertebra was further corrected by indirect reduction and fixation with four pedicle screws applied one-above and one-below to the vertebra, and two augmenting screws on the injured vertebra.

and the average injury-surgery interval was 4.9 ± 2.7 days. Preoperative CT showed that the average spinal canal encroachment in Group A was $52.7\% \pm 12.5\%$. The average preoperative kyphosis angle was $22.3^\circ \pm 6.6^\circ$, which was corrected to $5.6^\circ \pm 4.8^\circ$ immediately after surgery ($p < 0.001$). At final follow-up, the mean local kyphosis angle was $10.3^\circ \pm 5.2^\circ$; loss of correction was $4.7^\circ \pm 2.7^\circ$ ($p < 0.001$). The average pre-operative anterior body height was $46.6\% \pm 12.5\%$, which improved to $85.7\% \pm 9.4\%$ immediately after surgery ($p < 0.001$). Anterior body height restored by surgery was $39.2\% \pm 13.3\%$. Anterior body height at 18-month follow-up was $74.9\% \pm 12.0\%$, and the average loss of body height correction was $10.8\% \pm 7.0\%$ ($p < 0.001$). No one in Group A had wound infection or developed neurologic deterioration due to

surgery, and no one was noted to have a broken rod or screws when performing implant removal surgery. However, two patients lost over 10 degrees of local kyphosis correction and were defined as failed surgery at the final follow-up. According to the ASIA scale, 18 patients were grade E and two were grade D before surgery. All patients in Group A were scaled as grade E finally. In terms of outcome, 65% of patients (13 patients) in Group A had no back pain, and the mean pain scale was 1.5 ± 0.8 at the final follow-up; 10 patients (50%) could return to their previous employment, and the mean work scale was 1.7 ± 0.9 . Fig. 2 demonstrates a typical case in Group A.

Comparisons between the three groups

The three groups were similar in age, sex, fracture levels, associated injuries, hospital stay, and preoperative neurologic status. Falling from a height was the major injury mechanism in these three groups. Estimated blood loss and operation time were significantly different between the groups. Group A had

the lowest estimated blood loss, and Group B had the most estimated blood loss (101.7 ± 72.5 vs. 600 ± 403.1 vs. 247.5 ± 164.2 ml, $p < 0.001$). Group A and Group C also demonstrated a significant difference in estimated blood loss ($p = 0.002$). In addition, Group A patients spent the least time in surgery of the three groups (142.0 ± 57.2 vs. 227.2 ± 43.6 vs. 161.6 ± 28.5 min, $p < 0.001$). There was also a significant difference in operation time between group A and group C ($p = 0.048$) [Table 1].

Preoperative radiographic parameters including spinal canal encroachment, local kyphosis, and anterior body height were similar for the three groups. Immediately after surgery, there were no differences in sagittal kyphosis and anterior body height between the three groups. The angle and body height correction obtained by these three techniques were similar. In the final radiographs, Group A revealed more local kyphosis ($10.3^\circ \pm 5.2^\circ$ vs. $6.4^\circ \pm 7.8^\circ$ vs. $7.0^\circ \pm 5.7^\circ$, $p = 0.239$) and sustained the lowest anterior body height ($74.9\% \pm 12.0\%$ vs. $82.2\% \pm 9.5\%$ vs. $79.4\% \pm 6.9\%$, $p = 0.058$). According to the

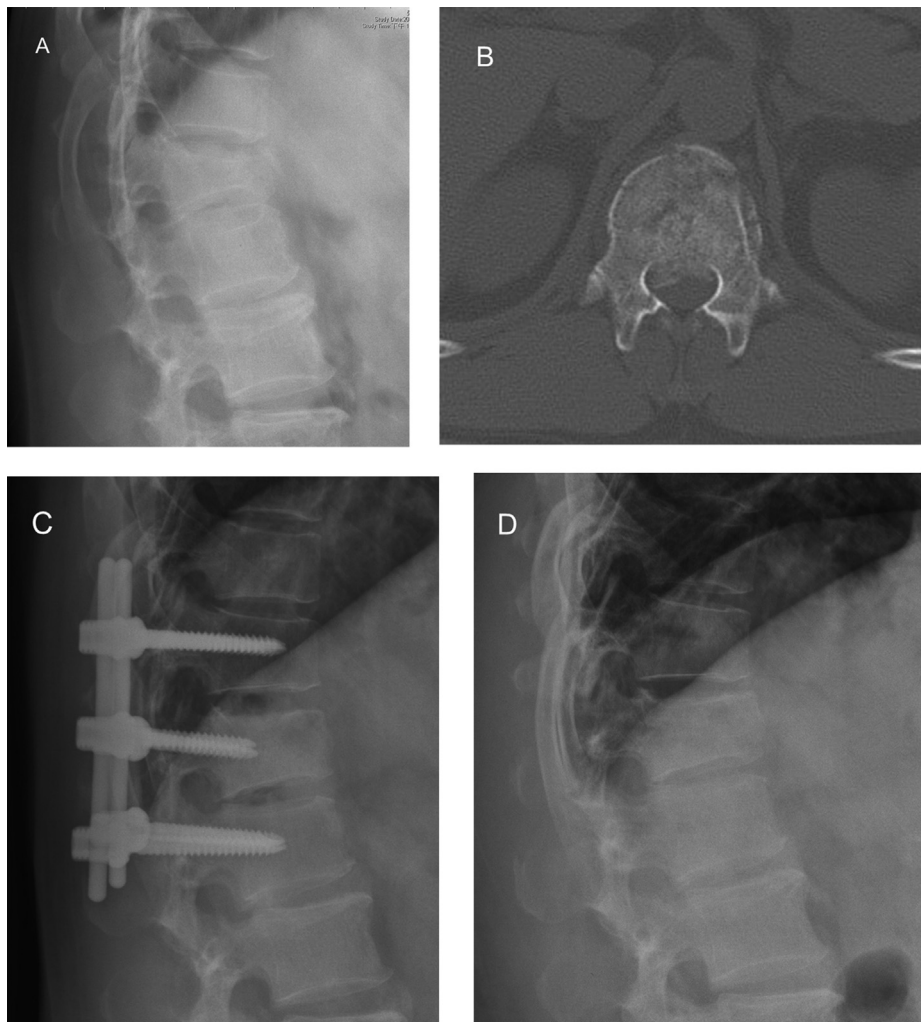


Fig. 2 – A 42-year-old male sustained L1 burst fracture in a motor vehicle accident. (A) Preoperative radiograph showed 27° local kyphosis and 49% anterior height collapse. (B) Preoperative axial computed tomography showed 52% canal encroachment. (C) Immediate postoperative radiograph revealed that the all-screws technique had corrected the deformity to 8° of local kyphosis and a 14% anterior body height collapse. (D) 18 months after surgery, the implants were removed and the radiograph showed the L1 body united. Local kyphosis deteriorated to 11° and anterior body height collapse increased to 17%.

Table 1 – Patient demographic data.

Characteristic	Group A (N = 20)	Group B (N = 31)	Group C (N = 20)	p value
Age (years)	43.0 ± 10.4	39.7 ± 11.8	40.8 ± 11.1	0.609
Gender				
Female	10	10	6	0.337
Male	10	21	14	
Level				
T11	0	1	0	0.706
T12	4	5	2	
L1	12	12	9	
L2	3	8	6	
L3	1	5	3	
Hospital stay (days)	11.5 ± 3.8	13.7 ± 3.9	13.7 ± 3.2	0.117
Injury-to-operation interval (days)	4.9 ± 2.7	3.5 ± 1.9	4.8 ± 3.4	0.216
Operative time (min)	142.0 ± 57.2	227.2 ± 43.6	161.7 ± 28.5	<0.001
A vs. B				<0.001
A vs. C				0.047
B vs. C				<0.001
Blood loss (c.c.)	101.7 ± 72.5	600.0 ± 403.1	247.5 ± 164.2	<0.001
A vs. B				<0.001
A vs. C				0.002
B vs. C				<0.001
Mechanism				
Fall	15	20	12	0.371
MVA	4	11	6	
Struck	1	0	2	
Associated injury				
Yes	6	12	8	0.766
No	14	19	12	

MVA = motor vehicle accident.

height loss data (final – immediately after surgery), Group A had the highest collapsed rate of the anterior body height (10.8% ± 7.0% vs. 4.6% ± 4.8% vs. 7.2% ± 8.5%, $p = 0.002$). With transpedicular bone grafting support, Group B had the greatest ability to resist angle loss (4.7° ± 2.7° vs. 2.7° ± 2.1° vs. 4.8° ± 2.4°, $p = 0.090$) [Table 2].

At the latest follow-up, all patients in Group A could walk without support and were ASIA grade E in neurologic status. There was no difference in ASIA grade distribution in these three groups. The average pain scale score was similar between the three groups (1.5 ± 0.8 vs. 1.7 ± 0.9 vs. 1.7 ± 1.0,

$p = 0.721$). The patients in Group A had the highest incidence of returning to their previous employment (50% vs. 39% vs. 35%, $p = 0.265$) [Table 3].

Discussion

Short-segment pedicle instrumentation has become popular for treating thoracolumbar burst fracture, but controversy still remains regarding the use of fusion or non-fusion with posterior short-segment instrumentation for thoracolumbar burst

Table 2 – Radiographic data of surgery.

Parameter	Group A (N = 20)	Group B (N = 31)	Group C (N = 20)	p value
Failure rate	2/20 (10%)	1/31 (3.2%)	2/20 (10%)	0.542
Preoperative canal encroachment (%)	52.7 ± 12.5	48.1 ± 16.5	53.5 ± 14.0	0.374
Local kyphosis degree				
Preoperative	22.3 ± 6.6	20.9 ± 9.2	21.7 ± 6.7	0.828
Postoperative	5.6 ± 4.8	3.7 ± 7.8	2.4 ± 5.1	0.208
18-month	10.3 ± 5.2	6.4 ± 7.8	7.1 ± 5.3	0.239
Correction by surgery	16.7 ± 4.1	17.2 ± 5.3	19.3 ± 4.9	0.224
Loss of correction at 18 months	4.7 ± 2.7	2.7 ± 2.1	4.8 ± 2.4	0.090
Anterior body height (%)				
Preoperative	46.6 ± 12.5	50.9 ± 11.2	50.3 ± 14.8	0.489
Postoperative	85.7 ± 9.4	86.9 ± 9.5	86.6 ± 7.5	0.777
18-month	75.5 ± 12.0	82.2 ± 9.5	79.2 ± 6.8	0.058
Correction by surgery	39.2 ± 13.3	35.9 ± 1.9	36.3 ± 14.6	0.834
Loss of correction at 18 months	10.5 ± 7.0	4.6 ± 4.8	7.2 ± 8.5	0.002
A vs. B				0.002
A vs. C				0.075
B vs. C				0.115

Table 3 – Clinical outcomes using Denis scale.

Parameter	Group A (N = 20)	Group B (N = 31)	Group C (N = 20)	p value
Pain scale				
1	13	18	11	0.721
2	5	7	5	
3	1	4	2	
4	1	2	2	
5	0	0	0	
Work scale				
1	10	12	7	0.265
2	7	9	5	
3	2	6	4	
4	1	1	0	
5	0	3	4	

fractures. The traditional reasons for additional posterior fusion include decreasing implant failure and long-term maintenance of alignment [8,9]. However, a few studies have demonstrated that non-fusion with posterior short-segment instrumentation obtained radiographic and clinical results similar to those of posterior short-segment instrumentation with fusion for thoracolumbar burst fractures [5,10,11]. The additional advantages of the non-fusion method include prevention of donor-site morbidity and a decrease in operation time and blood loss. Despite these advantages, hardware failure cannot be prevented. Sanderson et al. studied 24 patients who had undergone posterior short-segment fixation without fusion for thoracolumbar burst fractures; four implant failures due to screw breakage (14%) were noted during an average 3.1 years of follow-up [12]. Yang et al. examined 64 patients treated with posterior short-segment instrumentation without fusion for thoracolumbar burst fractures; four broken screws were found in four patients at the final follow-up, and the hardware failure rate was 4.7% [13]. Wang et al. compared the results of patients with thoracolumbar and lumbar burst fracture who underwent posterior short-segment instrumentation with or without fusion; the authors claimed that three patients in the non-fusion group had screw breakage (8.3%) [5]. A large anterior defect created during the application of distraction force and the subsequent disc degeneration contributed to high levels of stress on the posterior instrumentation. Without anterior support, posterior instrumentation might fail, although modern pedicle screws have high pull-out and cut-out strength and can resist high levels of stress. Transpedicular augmentation of the fractured vertebra seems to be an ideal method to maintain alignment and vertebra height, and prevent implant failure. Materials for transpedicular augmentation include autogenous iliac bone and bone substitutes. However, with the 10% breakage rate and a loss of correction of more than 10° in 40% of their patients, Alanay et al. did not support transpedicular bone grafting for patients with thoracolumbar burst fractures [14]. In contrast, Liao et al. supported transpedicular bone graft for thoracolumbar burst fractures; their data showed only one patient (3%) had implant failure because of severe posterior element injury [4]. They suggested that posterior fusion should be done in this situation. Transpedicular bone substitutes augmentation with posterior short-segment instrumentation is another alternative for such patients. Marco et al. and Korovessis et al. used

posterior short-segment instrumentation plus calcium phosphate cement for patients with burst fractures or compression fractures [15,16]. Shen et al. and Liao et al. successfully used posterior short-segment instrumentation plus injectable calcium sulfate cement for thoracolumbar burst fractures [4,17].

Wang et al. applied only one “lordosing screw” at one side of the fractured vertebra because they wanted to preserve the other side for decompression by the anterior approach in the future if the neurologic status did not improve or there was deterioration [5]. In our study, all 20 patients in Group A were neurologically intact or only had minor neurologic deficits (ASIA grades E and D) before surgery, so anterior decompression procedures were not considered for our cases. In our institute, ASIA grades A, B, and C, who will be performed anterior surgery. We believe that applying two augmenting screws, one through either side of the pedicle of the vertebra, can provide better immediate stability and enhance final vertebra union. The results also showed that there were no implant failures or neurologic deterioration in these 20 patients.

Hwang et al. reported 15 patients with thoracolumbar burst fractures that underwent posterior short-segment pedicle instrumentation without fusion [18]. These 15 patients also had two augmenting screws at the fractured vertebra; the results showed no implant-related complication and the mean loss of correction angle was 6.1° at the 12-month follow-up. In the present study, the Group A patients underwent a technique for burst fractures similar to that of Hwang et al.; our results also showed no implant failure and the mean loss of correction was 4.7° at the 18-month examination. All pre-operative and immediate postoperative radiographic parameters were similar in the three groups, which meant that an ideal local alignment and body height could be restored in all three groups. However, compared to Group B and Group C, Group A had more body height loss at 18-month follow-up. This phenomenon meant that the space in the fractured body created after distraction force could be maintained better by augmentation with autogenous bone or bone substitute. So the main role of the pedicle screw in augmenting the fractured vertebra was to provide more stability, not to stimulate fracture healing inside the injured vertebra. Although Group A could not achieve the most ideal radiographic results, satisfied quality of life with good functional score and work ability was noted in Group A. The main reason might be the associated injury. Group A had less associated injury compared with other groups, although there was no significant difference between 3 Groups. Emphasis should be made about the surgical techniques. The techniques used in Group A took the least operative time and led to the least blood loss of the three groups. This distinguishing feature was important because all these patients with thoracolumbar burst fractures were injured due to high energy trauma and might have had associated injuries. Less blood loss and less operative time mean less blood transfusion and a lesser anesthesia requirement, and might prevent surgical complications.

Conclusion

The outcomes of this study confirmed that the use of two additional augmenting screws in the fractured body with

short-segment pedicle screws is sufficient for most thoracolumbar burst fractures, to attain fracture reduction and maintain alignment. Compared to the transpedicular grafting technique, the all-screws method is easy, requires less operative time, involves less blood loss, and has similar clinical results. With appropriate patient selection, this procedure is thought to be a good surgical choice. In the future, this method can be extended to a different approach (the para-median approach) or modified to a minimally-invasive technique for thoracolumbar burst fractures.

Conflicts of interest

No funds were received in support of this work. No benefits in any form have been or will be received from a commercial party related directly or indirectly to the subject of this manuscript.

REFERENCES

- [1] Benson DR, Burkus JK, Montesano PX, Sutherland TB, McLain RF. Unstable thoracolumbar and lumbar burst fractures treated with the AO fixateur interne. *J Spinal Disord* 1992;5:335–43.
- [2] Crawford NR, Dickman CA. Construction of local vertebral coordinate systems using a digitizing probe. Technical note. *Spine* 1997;22:559–63.
- [3] Müller U, Berlemann U, Sledge J, Schwarzenbach O. Treatment of thoracolumbar burst fractures without neurologic deficit by indirect reduction and posterior instrumentation: bisegmental stabilization with monosegmental fusion. *Eur Spine J* 1999;8:284–9.
- [4] Liao JC, Fan KF, Keorochana G, Chen WJ, Chen LH. Transpedicular grafting after short-segment pedicle instrumentation for thoracolumbar burst fracture: calcium sulfate cement versus autogenous iliac bone graft. *Spine* 2010;35:1482–8.
- [5] Wang ST, Ma HL, Liu CL, Yu WK, Chang MC, Chen TH. Is fusion necessary for surgically treated burst fractures of the thoracolumbar and lumbar spine?: a prospective, randomized study. *Spine* 2006;31:2646–52.
- [6] Mumford J, Weinstein JN, Spratt KF, Goel VK. Thoracolumbar burst fractures. The clinical efficacy and outcome of nonoperative management. *Spine* 1993;18:955–70.
- [7] Denis F, Armstrong GW, Searls K, Matta L. Acute thoracolumbar burst fractures in the absence of neurologic deficit. A comparison between operative and nonoperative treatment. *Clin Orthop Relat Res* 1984;189:142–9.
- [8] Parker JW, Lane JR, Karaikovic EE, Gaines RW. Successful short-segment instrumentation and fusion for thoracolumbar spine fractures: a consecutive 41/2-year series. *Spine* 2000;25:1157–70.
- [9] Qian BP, Qiu Y, Wang B, Yu Y, Zhu ZZ. Effect of posterolateral fusion on thoracolumbar burst fractures. *Chin J Traumatol* 2006;9:349–55.
- [10] Dai LY, Jiang LS, Jiang SD. Posterior short-segment fixation with or without fusion for thoracolumbar burst fractures. a five to seven-year prospective randomized study. *J Bone Joint Surg Am* 2009;91:1033–41.
- [11] Jindal N, Sankhala SS, Bachhal V. The role of fusion in the management of burst fractures of the thoracolumbar spine treated by short segment pedicle screw fixation: a prospective randomised trial. *J Bone Joint Surg Br* 2012;94:1101–6.
- [12] Sanderson PL, Fraser RD, Hall DJ, Cain CM, Osti OL, Potter GR. Short segment fixation of thoracolumbar burst fractures without fusion. *Eur Spine J* 1999;8:495–500.
- [13] Yang H, Shi JH, Ebraheim M, Liu X, Konrad J, Husain I, et al. Outcome of thoracolumbar burst fractures treated with indirect reduction and fixation without fusion. *Eur Spine J* 2011;20:380–6.
- [14] Alanay A, Acaroglu E, Yazici M, Oznur A, Surat A. Short-segment pedicle instrumentation of thoracolumbar burst fractures: does transpedicular intracorporeal grafting prevent early failure? *Spine* 2001;26:213–7.
- [15] Marco RA, Meyer BC, Kushwaha VP. Thoracolumbar burst fractures treated with posterior decompression and pedicle screw instrumentation supplemented with balloon-assisted vertebroplasty and calcium phosphate reconstruction. Surgical technique. *J Bone Joint Surg Am* 2010;92(Suppl. 1 Pt 1):67–76.
- [16] Korovessis P, Hadjipavlou A, Repantis T. Minimal invasive short posterior instrumentation plus balloon kyphoplasty with calcium phosphate for burst and severe compression lumbar fractures. *Spine* 2008;33:658–67.
- [17] Shen YX, Zhang P, Zhao JG, Xu W, Fan ZH, Lu ZF, et al. Pedicle screw instrumentation plus augmentation vertebroplasty using calcium sulfate for thoracolumbar burst fractures without neurologic deficits. *Orthop Surg* 2011;3:1–6.
- [18] Hwang JU, Hur JW, Lee JW, Kwon KY, Lee HK. Comparison of posterior fixation alone and supplementation with posterolateral fusion in thoracolumbar burst fractures. *J Korean Neurosurg Soc* 2012;52:346–52.