

Perianal pseudoverrucous papules and nodules

Ameet Dandale, Rachita Dhurat, Smita Ghate

Department of Dermatology, Lokmanya Tilak Municipal Medical College and Hospital, Mumbai, India

Address for correspondence:

Dr. Ameet Dandale, Lokmanya Tilak Municipal, Medical College and Hospital, Mumbai, Maharashtra, India.

E-mail: ameeddandale@gmail.com

Abstract

Perianal pseudoverrucous papules and nodules (PPPN) is a rare entity attributed to chronic irritation. We came across this entity in a case of spina bifida. A 14 year old girl having spina bifida at L3 presented with complaints of multiple asymptomatic whitish lesions on the inner aspect of thighs and labia majora since early childhood. She had incontinence of stool and urine since birth. Cutaneous examination revealed multiple 3-12 mm flat topped moist papules, few verrucous nodules, some of these lesions coalesced to form plaques at the perianal area extending upto the labia majora. On histology marked epidermal hyperplasia and pale keratinocytes in the epidermis was seen. This confirmed the diagnosis of PPPN. This rare condition can be mistaken with sexually transmitted diseases leading to unnecessary investigations and treatment.

Key words: Condyloma accuminata, condyloma lata, perianal pseudoverrucous papules and nodules

INTRODUCTION

Perianal pseudoverrucous papules and nodules (PPPN) is a rare entity, first described in patients with urostomies. It was attributed to chronic irritation from leakage of urine. These lesions appear to be uncommon and sometimes can be misdiagnosed, even leading to their surgical removal. There are only a few case reports of pseudo verrucous lesions occurring on the perianal skin or around colostomies.

CASE REPORT

A 14-year-old girl inmate of an orphanage with spina bifida at L3 level presented with complaints of multiple asymptomatic whitish-raised lesions on the inner aspect of thighs and labia majora since infancy. She had incontinence stool and urine excretion since birth. She had a history of using

diapers since childhood, due to incontinency. She did not have any rash or constitutional symptoms. The patient was not sexually active. In the past, she had received topical antifungals, corticosteroids, and systemic antibiotics, without any improvement.

Systemic examination, blood, and biochemical investigations were normal.

Cutaneous examination revealed multiple, flat-topped moist papules, 3-12 mm in size, few verrucous nodules; some of these lesions coalescing to form plaques at the perianal area, extending up to the labia majora [Figures 1 and 2]. Enzyme-linked immunosorbent assay (ELISA) for HIV, Venereal Disease Research Laboratory Test, and *Treponema pallidum* hemagglutination (TPHA) tests were negative/non-reactive. Polymerase chain reaction did not detect human papillomavirus.

The histopathological examination of a papule revealed irregular epidermal hyperplasia. There was marked acanthosis with pale keratinocytes in the upper epidermis. A mild lymphocytic infiltrate can be seen in upper dermis [Figure 3].

Access this article online

Quick Response Code:



Website:

www.ijstd.org

DOI:

10.4103/0253-7184.112939

How to cite this article:

Dandale A, Dhurat R, Ghate S. Perianal pseudoverrucous papules and nodules. Indian J Sex Transm Dis 2013;34:44-6.

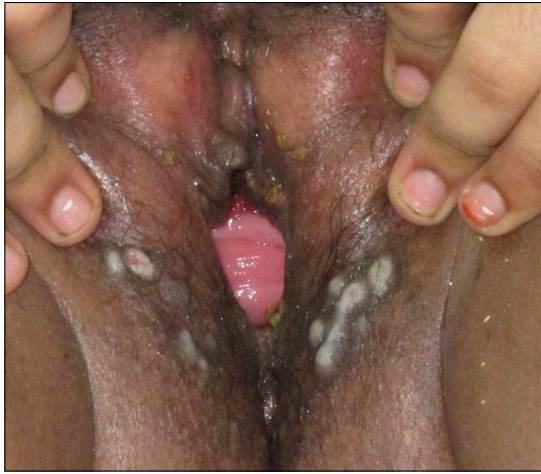

Figure 1: Multiple 3-12 mm, flat-topped moist papules, few verrucous nodules, some of these lesions coalesced to form plaques at the labia majora, soiling with fecal matter to be noted

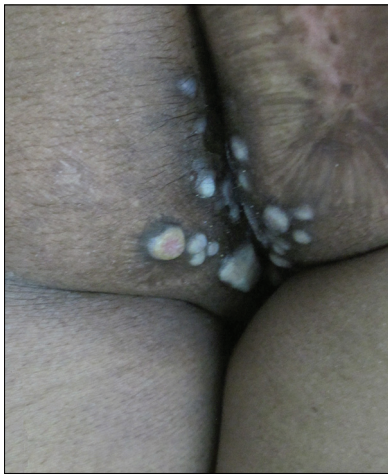


Figure 2: Multiple 3-12 mm, flat-topped moist papules, few verrucous nodules, some of these lesions coalesced to form plaques at the perianal area

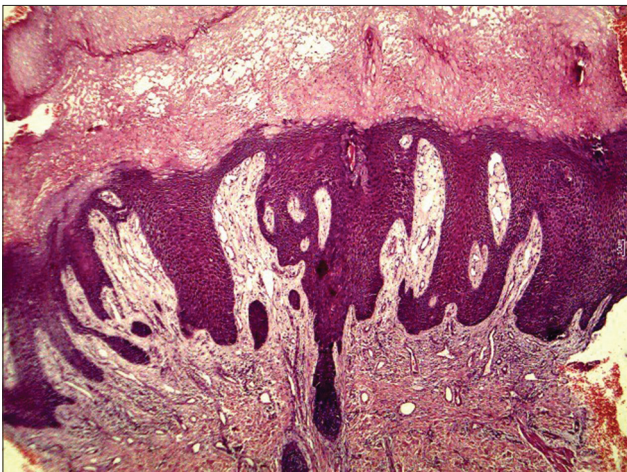


Figure 3: H and E staining of skin biopsy shows irregular epidermal hyperplasia and marked acanthosis with pale keratinocytes in the upper epidermis. A mild lymphocytic infiltrate can be seen in upper dermis (×10)

DISCUSSION

There are a few case reports of pseudoverrucous lesions occurring on the perianal skin or around colostomies in literature. PPPN occur in the diaper and perianal area, in patients of any age, with a predisposition to prolonged wetness. Children who wear diapers due to chronic urinary incontinence are prone to this type of dermatitis.^[1]

PPPN is a peculiar and striking reaction to irritation that has been described commonly with urostomies, near colostomies, and on perianal area. This reaction has been given various names: Chronic papillomatous dermatitis, granulomas, hyperkeratosis, hyperplasia, pseudoepitheliomatous hyperplasia, and reactive acanthosis. The term PPPN is preferred because it is clinically descriptive. It is an irritant reaction to urine, few reports have shown irritation due to stool as well.^[2]

Encopresis exposes the perianal skin to liquid stool for prolonged periods, increasing maceration of the skin in this area and making it more sensitive to the damaging effects of irritant/contact dermatitis and overzealous hygiene. It has been also suggested to be a special form of irritant contact dermatitis that occurs where alkaline urine, particularly one infected with urea-splitting bacteria, is in chronic contact with the skin.

PPPN can occur in the setting of chronic irritation such as severe intractable diarrhea from any cause, short gut syndrome, following surgical colonic re-anastomosis in patients with Hirshprung's disease,^[3] chronic fecal incontinence secondary to occult spinal dysraphism.^[4]

PPPN usually occurs in infants rather than newborns. It presents clinically as multiple well-demarcated, dome-shaped papules, 2-10 mm in size, with a shiny smooth surface, over the perianal region, buttocks, vulvar, and scrotal area or around entero-stomal region. The lesions may become ulcerated or friable and there is a risk of secondary infection. Histopathology of a lesion shows epidermal hyperplasia and hyperkeratosis with mild to moderate dermal infiltrate.^[5]

PPPN clinically may mimic bacterial infection, candidiasis, granuloma gluteale infantum, condylomata acuminata, cutaneous Crohn's disease, and histiocytosis X.^[6,7] It should be clinically differentiated from verrucous condylomata lata.^[8] The closest differential diagnosis in our patient was condyloma lata, as some of the lesions were moist flat topped papules.

Some authors are of the opinion that granuloma gluteale infantum, Jacquet's erosive dermatitis, and PPPN are same entity resulting from a local response to chronic irritation,^[9] while some are of the opinion that PPPN represent a peculiar form of primary irritant diaper dermatitis, distinct from Jacquet's erosive diaper dermatitis, and granuloma gluteale infantum.^[3]

Histopathological examination in PPPN shows epidermal hyperplasia with marked acanthosis and altered cornification with parakeratosis, hypogranulosis, and pale keratinocytes in the epidermis.^[10]

Treatment should be aimed at reducing the irritation and prevention of secondary infection by removal of precipitating factor and recovery of skin barrier function. The peristomal skin should be swabbed in all cases for microbiological examination because treatable primary and secondary infections are relatively common.^[11]

Topical application of potato protease inhibitors has been promoted as a novel approach in preventing protease-induced perianal dermatitis.^[12]

REFERENCES

1. Chang MW, Orlow S. Neonatal, Pediatric, and Adolescent Dermatology. In: Wolff K, editor. Fitzpatrick's dermatology in general medicine. 7th ed. vol. 943. New York: Mc Graw Hill publication; 2008.
2. Goldberg NS, Esterly NB, Rothman KE, Fallon JD, Cropley TG, Szaniawski W, *et al.* Perianal pseudoverrucous papules and nodules in children. Arch Dermatol 1992;128:240-2.
3. Rodriguez CI, Garcia-patos BV, Pedragosa JR, Castells RA. Perianal pseudoverrucous papules and nodules after surgery for Hirschsprung disease. J Pediatr 1994;125:914-6.
4. Frasier LD. The anogenital exam: Diagnostic dilemmas, Mimics of abuse. In: Finkel MA, editor. Medical evaluation of child sexual abuse: A practical guide. 2nd ed. vol. 168. California: Sage publication; 2002.
5. Banney LA, Sterling JC. Dermatological conditions of female genitalia. In: Balen AH, editor. Paediatric and adolescent gynaecology: A multidisciplinary approach. 1st ed. vol. 453. Cambridge: Cambridge University press; 2004.
6. Amiry SA, Pride HB, Tyler WB. Perianal pseudoverrucous papules and nodules mimicking condylomata acuminata and child sexual abuse. Cutis 2001;67:335-8.
7. Coppo P, Salomone R. Pseudoverrucous papules: An aspect of incontinence in children. J Eur Acad Dermatol Venereol 2002;16:409-10.
8. Deshpande DJ, Nayak CS, Mishra SN, Dhurat RS. Verrucous condyloma lata mimicking condyloma acuminata: An unusual presentation. Indian J Sex Transm Dis 2009;30:100-2.
9. Robson KJ, Maughan JA, Purcell SD, Petersen MJ, Haefner HK, Lowe LJ. Erosive papulonodular dermatosis associated with topical benzocaine: A report of two cases and evidence that granuloma gluteale, pseudoverrucous papules, and Jacquet's erosive dermatitis are a disease spectrum. Am Acad Dermatol 2006;55:S74-80.
10. Garrido-Ruiz MC, Rosales B, Luis Rodríguez-Peralto J. Vulvar pseudoverrucous papules and nodules secondary to a urethral-vaginal fistula. Am J Dermatopathol 2011;33:410-2.
11. Lyon CC, Smith AJ, Griffiths CE, Beck MH. The spectrum of skin disorders in abdominal stoma patients. Br J Dermatol 2000;143:1248-60.
12. Ruseler-van Embden JG, van Lieshout LM, Smits SA, van Kessel I, Laman JD. Potato tuber proteins efficiently inhibit human faecal proteolytic activity: Implications for treatment of peri-anal dermatitis. Eur J Clin Invest 2004;34:303-11.

Source of Support: Nil. Conflict of Interest: None declared.

SUBMIT A PAPER AND BE A POTENTIAL AWARDEE.....

Every year following award are given for the articles published in IJSTD and AIDS

(including 2 issues of the year)

1. Sardarilal memorial award for best original article

Awardee gets an opportunity to present his/her paper in National Conference of STD & AIDS(ASTICON) and he/she is awarded a medal and a certificate.

2. Editor's prize for best case report/photo feature

Rs. 1000 cash prize and a certificate is given to the awardee.