

# Personalized 3D Printed Tooth-Supported Template as a Novel Strategy for Radiofrequency Thermocoagulation for Trigeminal Neuralgia After the Failure of CT-Guided Puncture

Shaohua You<sup>1,\*</sup>, Xiaoyan Qin<sup>2,\*</sup>, Guoli Zhao<sup>1</sup>, Zeguo Feng<sup>1</sup>

<sup>1</sup>Department of Pain Medicine, The First Medical Center of Chinese PLA General Hospital, Beijing, 100853, People's Republic of China; <sup>2</sup>Department of Clinical Laboratory, Shijingshan Teaching Hospital of Capital Medical University, Beijing Shijingshan Hospital, Beijing, 100049, People's Republic of China

\*These authors contributed equally to this work

Correspondence: Zeguo Feng; Guoli Zhao, Department of Pain Medicine, The First Medical Center of Chinese PLA General Hospital, Beijing, 100853, People's Republic of China, Email BEIJING301@yeah.net; 2497391298@qq.com

**Background:** Trigeminal neuralgia (TN) is a common form of craniofacial pain, and Radiofrequency thermocoagulation (RFT) has become a commonly utilized treatment modality for TN. However, the complex anatomical configuration of the maxillofacial region and the difficulties inherent in positioning the neck in a hyperextended manner can present challenges for CT-guided punctures.

**Aim:** The objective of this study is to assess the effectiveness and safety of 3D printed tooth-supported template(3D-PTST) guided RFT in patients who have previously undergone unsuccessful CT-guided puncture.

**Methods:** Patients with TN undergoing RFT at the Department of Pain Medicine, PLA General Hospital, from January 2018 to January 2023, were assessed. 3D-PTST guided RFT was employed as an alternative when percutaneous puncture failed. Clinical, demographic, and follow-up data were collected. The duration of the procedure was determined by subtracting the time of anesthesia administration from the time of surgical drape removal. Pain intensity was assessed using the Numerical Rating Scale-11 scale. Treatment effects were evaluated utilizing the Barrow Neurological Institute scale. Incidences of complications related to RFA were documented.

**Results:** Six TN patients underwent 3D-PTST guided RFT. With tooth-supported template guidance, five patients achieved therapeutic target puncture in one attempt with one CT scan. One patient required two attempts with two CT scans. Operation duration ranged from 18 to 46 mins (mean 30 mins). All completed 3D-PTST-guided RFT without difficulty, significantly improving pain symptoms. Four patients had no pain recurrence at 12, 18, 36 and 37 months follow-up, respectively. Recurrence occurred in two patients (at 1 and 13 months). No serious treatment-related complications were observed.

**Conclusion:** 3D-PTST guided RFT is an effective, repeatable, safe, and minimally invasive treatment method for patients with TN who have failed due to difficulty in puncture.

**Keywords:** trigeminal neuralgia, radiofrequency thermocoagulation, tooth-supported template, 3D printing technology

## Introduction

Trigeminal neuralgia (TN) is one of the most common forms of craniofacial pain, with an annual incidence of approximately 4.3–27 per 100,000 people.<sup>1</sup> In the face, trigeminal neuralgia appears as sudden, intense, and stabbing pain. This is a chronic, debilitating neuropathy.<sup>2</sup> This pain is often intolerable and hard to be alleviated, greatly undermining the patient's quality of life.<sup>3</sup> Carbamazepine remains the best supported standard medical treatment for TN but may have a 50% failure rate for long-term (5–10 years) pain control.<sup>4</sup> Quintessentially, in cases refractory to treatment using these drugs, invasive treatments including surgery, gamma knife radiosurgery, and interventional therapies treatment is often considered.<sup>4</sup> With the development of minimally invasive treatment technology, radiofrequency thermocoagulation (RFT) has become a popular treatment

method for TN.<sup>5,6</sup> This method shows great advantages in precise ablation, but accurate localization of the ablation zone is the first step so the puncture of RFT requires familiarity with the anatomic structure and complete technical support.

A conventional CT scan is currently used for CT-guided percutaneous interventions.<sup>7</sup> However, the complex anatomy of the maxillofacial region or the difficulty in adjusting the neck in a hyperextended position may lead to difficulty of CT-guided punctures. The direction and depth of puncture may need to be adjusted, and the puncture target needs repeated explorations, thus leading to more surgical manipulations, larger trauma, and longer exposure to X-ray. And it was a very painful process for the patient and may cause CT-guided punctures to fail. Precise location and puncture, therefore, are of great significance in RFT.

In today's world, 3D printing is an emerging technology.<sup>8</sup> With three-dimensional (3D) reconstruction technology, the location, route and depth of the puncture can be precisely set. Subsequently, an individualized tooth-supported template is created with 3D printing technology. With personalized 3D printed tooth-supported template(3D-PTST), the stability and accuracy of the puncture during RFT could be guaranteed. Normally, at our medical institution, 3D-PTST is recommended in the event of failure of CT-guided RFT for TN.

We therefore decided to perform a retrospective analysis of our single-center patients with TN who had undergone 3D-PTST-guided RFT when CT-guided puncture have failed. The aim of this retrospective study is to describe the technical details, the feasibility, safety and efficacy of 3D-PTST-guided RFT for TN.

## Methods

### Patients

Clinical data was collected through electronic medical records. We reviewed the demographic information, age, sex, and history records of Patients with TN received RFT at the department of Pain Medicine of the First Medical Center, PLA General Hospital between January 2018 and January 2023. Percutaneous puncture failure was defined as the incapacity to successfully execute CT guided RFT procedure, attributable to the radiofrequency needle tip's inability to attain the intended target region. Normally, at our medical institution, a 3D-PTST guided RFT is recommended in the event of failure of CT-guided RFT for TN. In this study, Patients with Percutaneous puncture failure was followed up by telephone interview. These data were not collected or used for another study and have not been previously published. This study was approved and waived the requirement for informed consent by the Ethics Committee of the First Medical Center (approval number: S2024-191-01), PLA General Hospital. This study was risk free and all information of individuals was anonymized. The study was conducted following the Declaration of Helsinki (WMA Declaration of Helsinki, 2013). A single-group retrospective pretest and posttest design was adopted for this study. The diagnosis of Trigeminal Neuralgia was based on the International Classification of Headache Disorders (ICHD)-3 beta criteria.<sup>3</sup> All these patients underwent a preoperative evaluation, including maxillofacial region CT of and brain magnetic resonance imaging (MRI). All procedures were performed by one operator (GL ZHAO) in the CT room. The demographic information of patients is depicted in Table 1.

**Table 1** Patient Demographic and Clinical Data

Patient	Sex	Age (Year)	Comorbidities	Side	Branches Affected	Pain Duration (Month)	Pre-OP Medication and Dose (mg/d)	Side Effects of Medication	Reasons for Puncture Failure
1	F	34	None	R	V3	6	CBZ (400)	None	Difficulty in anatomic identification
2	M	69	Hypertension, CHD	L	V2	72	CBZ (800)	Drowsiness, dizziness	Limited neck movement
3	F	30	None	R	V2	72	CBZ (600)	Dizziness	Difficulty in anatomic identification
4	F	55	Hypertension	R	V2	96	CBZ (600), PGB (300)	Dizziness, poor coordination	Limited neck movement
5	F	34	None	L	V3	8	CBZ (400)	Dizziness	No ideal puncture path
6	M	41	None	L	V2	36	GBP (600)	None	Intolerant of multiple needle adjustments

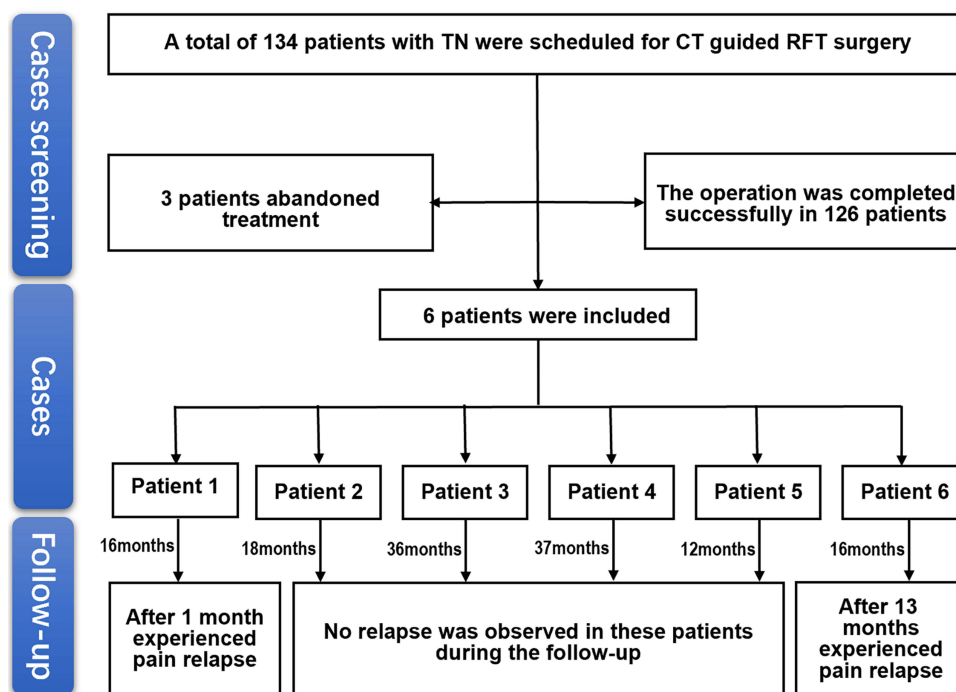
**Abbreviations:** F, female M; male; CBZ, Carbamazepine; PGB: Pregabalin; GBP, gabapentin; CHD, coronary heart disease; R, right; L, left; pre-OP, Preoperative.

## Manufacture of Personalized 3D Printed Tooth-Supported Template

Manufacture of a 3D-printed tooth-supported template requires slice CT (Brilliance TM CT, Phillip) scanning of the maxillofacial region (upper supraorbital arch to the chin, thickness as 1 mm). The 3D CT data (DICOM format) of the patient was imported to the Mimics Innovation Suite, a medical image analysis software. 3D models of head bones, teeth and skin were established and imported to the Materialize 3-matic software. Trigeminal neuralgia, which involves one or more branches of the trigeminal nerve, requires a collaborative approach with the patient to determine the most appropriate surgical method, considering their comprehensive understanding of the associated advantages and disadvantages. Given the range of surgical techniques available, our suggested puncture sites are the foramen ovale or foramen rotundum.<sup>6</sup> To confirm the puncture route, a slice of adjustment was required to avoid bony structures or other critical tissues. The intersection point of the puncture route and the skin was decided as the insertion point. Surface morphology data of upper and lower teeth were extracted and analyzed for generating the individualized digital tooth-supported template for RFT. The template consists of two parts: a tooth-supported template and a guide cannula. The tooth-supported template was individually designed to fit patient's occlusal surfaces of teeth perfectly to ensure stability. The guide cannula was designed along a confirmed trajectory with an inner diameter slightly larger than the puncture needle. The distance between the target point and the insertion point was measured. The template was then imported to the laser rapid prototyping (LRP) to generate the real tooth-supported template, which was disinfected for clinical use (Figure 1).

## Clinical Application

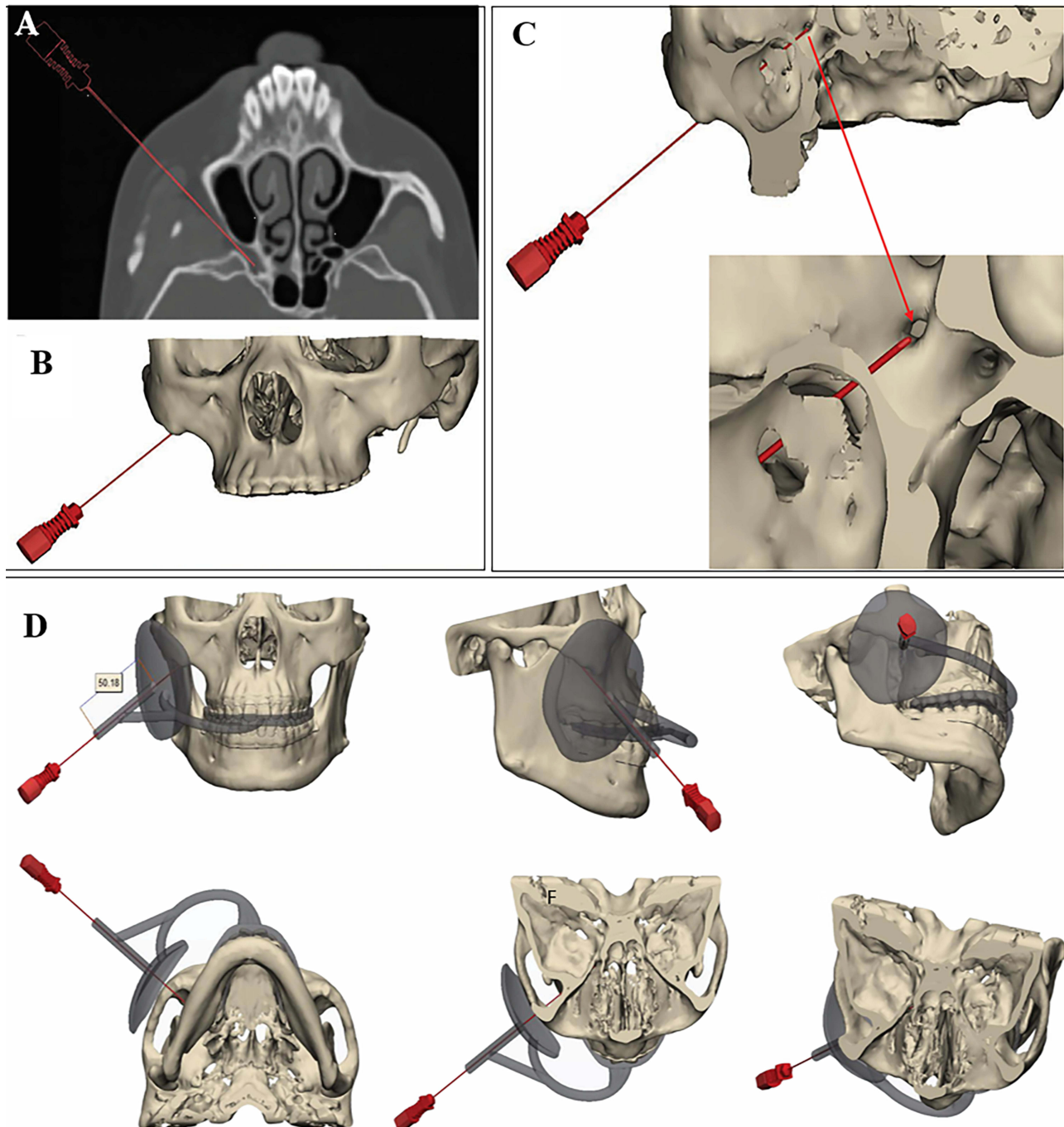
RFT was performed in the CT Room, where the patient lied on a scanner table in a supine position with the neck hyperextended. After vascular access, ECG and blood oxygen saturation were monitored. RFT was performed using the RFP-100A RF Puncture Generator (Baylis Medical, Canada). In brief, facial skin, including bilateral auricle skin, was routinely disinfected. The printed tooth-supported template was precisely placed between the upper and lower incisors to maintain a close occlusion of the bite plate, and a close contact between the skin and the soft-tissue-supporting plate. Through the introducer channel, 1% lidocaine was injected into the facial puncture site for infiltration anesthesia. A radiofrequency needle measuring 10 cm in length, with a 0.5 cm exposed front-end, was inserted to a predetermined depth. Correct position of needle tip was reconfirmed by sensory stimulation. Sensory threshold was tested with electrical stimulation of 0.1–0.2 V at



**Figure 1** Study Flow Chart.

**Abbreviations:** TN, Trigeminal neuralgia; RFT, Radiofrequency thermocoagulation.

50 Hz, and motor threshold was tested with electrical stimulation at 2 Hz. In order to ensure accurate puncture, the depth and direction of the trocar were adjusted in accordance with facial pain in the trigeminal nerve distribution and mandibular movements. It is recommended to conduct a CT scan prior to the routine treatment procedure in order to verify the accurate positioning of the needle tip target. Once the target was confirmed, 1 mL of 2% lidocaine was injected through the ablation needle. After successful local anesthesia, the trigeminal nerve was ablated at 65°C, 75°C and 75°C, with 90s per cycle. The surgery ended up with needle removal, disinfection and dressing of the puncture site. The patient returned to the ward safely. Postoperative clinical symptoms and neurological signs were monitored (Figure 2).



**Figure 2** Digitization of maxillofacial bones and puncture path. (A) Patients' preoperative CT image and the puncture route from the right maxillofacial region to the foramen rotundum; (B and C) The 3D models of head bones and the puncture route from the right maxillofacial region to the foramen rotundum; (D) The skull model with the digital tooth-supported template and the puncture path viewed from a different angle.

## Outcome Assessment

Clinical and demographic data, and laboratory results and follow-up records of these patients were obtained from the clinical information system.

The procedure duration was calculated by subtracting the recorded time when anesthesia was administered from the time of surgical drape removal. Numerical Rating Scale-11 (NRS-11): The NRS-11 is a self-report 11-point scale that assesses pain intensity. Treatment effect were evaluated using the Barrow Neurological Institute scale (BNI; class I: no pain, no medication; II: occasional pain, not requiring medication; IIIa: no pain, continued medication; IIIb: controlled with medication; IV: some pain, not adequately controlled with medication; V: severe pain, no pain relief).<sup>9,10</sup> Complications about RFA like facial hematomas, numbness, leakage of cerebrospinal fluid, and masseter muscle weakness were recorded. In order to improve medical quality, we routinely performed follow-up for these TN patients via telephone and all data were recorded in electronic records.

## Statistical Analysis

No statistical power calculation was conducted prior to the study and sample sizes were based on the available data. No additional statistical tests were conducted.

## Results

### Demographic and Clinical Data

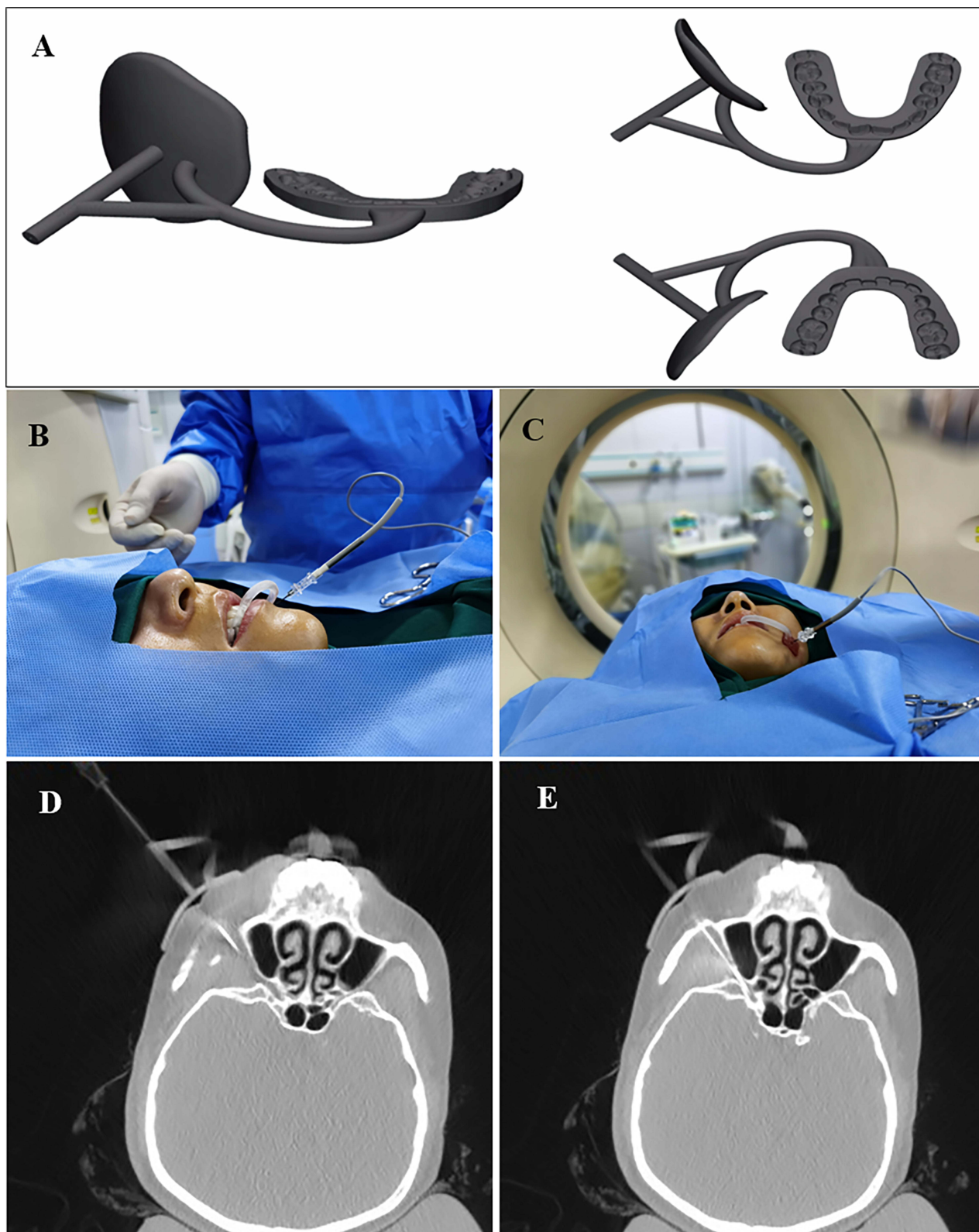
Between January 2018 and June 2022, a total of 134 patients with trigeminal neuralgia were scheduled for CT guided RFT surgery at the department of Pain Medicine of the First Medical Center, PLA General Hospital. 126(94.0%) patients successfully complete the procedure. There were 9 (6.7%) cases of failure of the percutaneous puncture. Among them, 1 patient recovered after MVD, 1 patient had a second CT guided RFT treatment failure in other medical institutions and sought MVD treatment and recovered, 1 patient continued their treatment with oral carbamazepine. Therefore, 6 patients with trigeminal neuralgia underwent 3D-PTST guided RFT (Figure 3). Demographic and Clinical data of patients are presented in Table 1. A total of 2males and 4 females were included, with a mean age of 43.8years (range 30–69 years). The median (IQR) duration of pain in these patients was 48.3 months (range 6–96 months). In all, 3 patients had left TN, and 3 had right TN. One patient had coronary heart disease and hypertension as added co-morbidities. One patient was accompanied by hypertension. All patients were treated with oral analgesic drugs and 4 of them present with symptoms such as poor coordination, headaches or drowsiness that might be caused by side effect of analgesic drugs (Table 1).

### Intraoperative Data

Among 6 patients treated with 3D-PTST guided RFT, foramen ovale was the puncture target in 2 patients and foramen rotundum in 4 patients. Under the guidance of a tooth-supported template, five patients completed the puncture of the therapeutic target with one attempt and had only one CT scan. One patient took two tries to finish the puncture process, and has twice CT scans. The duration of operation was 30 mins (range 18–46 mins). After treatment, one patient complained of postoperative nausea, which disappeared within five hours. All patients experienced postoperative facial numbness. Two patients experienced postoperative masseter weakness. There were no complications like cardiac arrhythmia, hematoma, corneal ulcers, or death (Table 2).

### Treatment Effect and Post-Operative Complications

All patients completed the 3D-PTST-guided RFT without difficulty, and their pain symptoms were significantly improved after the operation. In four of the patients, there were no recurrences of pain in 12 months, 18 months, 36 months, and 37 months of follow-up, respectively. The pain was well controlled. One patient was followed up for 13 months and at 16 months, the pain recurred, accompanied by numbness and masseter weakness. Currently, carbamazepine is used to control the pain in this patient. After 16 months of follow-up, another patient experienced a recurrence one month after discharge despite a decrease in pain intensity from IV on the BNI to III b, and from 6 to 2 on the NRS-11, following the 3D-PTST-guided RFT treatment. This patient used oral carbamazepine and gabapentin to control pain (Figure 3).



**Figure 3** Clinical application of the 3D-PTST. **(A)** The 3D-PTST viewed from a different angle; **(B and C)** Use of a 3D-PTST on a patient in a clinical setting; **(D and E)** The tip of the radiofrequency needle was confirmed by CT. Abbreviations: 3D-PTST, 3D printed Tooth-supported Template.

**Table 2** Surgical Data

Patient	Target Point	Punctures Numbers	CT scans Numbers	Procedure Length (mins)	Pain pre-OP (BNI/NRS)	Pain Post-OP (BNI/NRS)	Complications	Recurrence Time (Month)	Follow-Up Period (Month)
1	Foramen ovale	2	2	46	IIIb/5	II/2	Numbness, masseter weakness	13	16
2	Foramen rotundum	1	1	18	IV/7	III/1	Numbness	None	18
3	Foramen rotundum	1	1	25	IV/7	IIIa/1	Numbness	None	36
4	Foramen rotundum	1	1	27	IV/7	II/2	Numbness	None	37
5	Foramen ovale	1	1	42	IV/6	III/1	Numbness, masseter weakness	None	12
6	Foramen rotundum	1	1	22	IV/6	IIIb/2	Numbness	1	16

**Abbreviations:** BNI, Barrow Neurological Institute scale; NRS, numeric rating scale; pre-OP, Preoperative; post-OP, post-operative.

## Complications

All patients reported different degrees of numbness post-surgery. Ecchymotic lesions developed around the needle puncture site in two patients and resolved within 10 days. No patient experienced difficulty in mouth opening, or reduced sensory function in ipsilateral buccal mucosa and lateral side of the tongue. Two patients developed weakness in masticatory muscles. No serious treatment-related Complications occurred in this study.

## Discussion

The occurrence of surgical failure resulting from puncture difficulty during CT-guided RFT surgery in patients with TN is exceedingly uncommon. Between January 2018 and January 2022, Department of Pain Medicine of the First Medical Center at the PLA General Hospital encountered a total of 9 instances of puncture failure. Among these cases, 6 patients underwent 3D-PTST guided RFT. The utilization of 3D-PTST demonstrated a substantial enhancement in the likelihood of achieving successful puncture. The utilization of multiple CT scans is no longer necessary in the surgical procedure. The perioperative period did not witness any serious surgical complications. Subsequent to an extended period of observation, patients suffering from TN have experienced diverse levels of amelioration and alleviation.

TN damages one's life quality.<sup>11</sup> The utilization of radiofrequency (RF) has proven to be a dependable approach in managing neuropathic pain among patients who have not responded positively to conservative treatment options.<sup>12–14</sup> The utilization of imaging tools, such as CT or C-arm, is often necessary to achieve accurate localization during radiofrequency therapy for trigeminal neuralgia. Currently, the utilization of imaging tools such as CT or C-arm has made radiofrequency treatment of the trigeminal nerve a prevalent approach in the existing treatment modalities for this nerve. Nevertheless, instances where there are deviations in the patient's skull base anatomy or the patient's positioning fails to meet the surgical prerequisites are more prone to result in surgical failure.

The skull base is an area of significant anatomical complexity and functional importance. The ossification of the pterygospinous and pterygoalar ligaments, which are located at the cranial base, can result in the development of complete or incomplete bony bars in relation to the foramen ovale.<sup>15</sup> The occurrence of ossification may result in puncture failure and impede the effective execution of TN thermocoagulation. Certain patients may experience cervical spine rigidity or degenerative alterations, leading to challenges in extending the cervical region. Consequently, conventional CT guidance can make it difficult to achieve an ideal puncture path. The CT-guided RFT surgery was unable to be conducted in one patient as a result of challenges in maintaining the cervical hyperextension position in this study. In the course of 3D-PTST production, the examination of the puncture pathway prior to surgery enables the identification and avoidance of the bone structure as well as crucial blood vessels and nerves within said pathway. The utilization of 3D-PTST for puncture obviates the need for stringent patient posture prerequisites. In the course of the surgical procedure,

complete visualization of the puncture path via CT scanning is not imperative. Merely employing 3D-PTST puncture suffices for the purpose of verification, in conjunction with CT.

Unlike routine RFT, we used a tooth-supported template printed by a 3D LRP<sup>16</sup> to aid the puncture to the foramen rotundum or oval foramen, thus achieving accurate procedures, short duration and less exposure to X-ray (only one time of exposure). According to a particular study,<sup>17</sup> it was estimated that if all the additional occurrences of brain cancer following brain CT scans were solely attributed to the imaging procedure itself, approximately 1 in 4000 brain CT scans conducted on children would lead to the development of a malignancy. Additional research has documented that CT scans have been associated with an elevated likelihood of tumor formation in the cranial region, thyroid, and integumentary system, alongside an increased susceptibility to cataract development in ocular structures.<sup>18</sup>

3D printing technology has been extensively applied in maxillofacial surgery.<sup>19,20</sup> The 3D template is printed with the digital data of a patient<sup>21</sup>. The application of 3D printing technology in the treatment of TN is rarely reported. Zhang et al<sup>22</sup> previously reported the application of a 3D-printed mask template to aid RFT in the treatment of V<sub>2</sub> TN. Compared with control group, the experimental group showed higher success rate of the first puncture, shorter surgery time and less postoperative subcutaneous congestion and hematoma. Notably, our tooth-supported template was superb in the stability and accuracy,<sup>23</sup> compared with the mask template used in Zhang's study. The process of tooth development necessitates complex genetic and molecular regulations to establish precise tooth number, accurate tooth location, appropriate tooth size, morphology, and composition for each individual tooth.<sup>24</sup> Wear facets can be observed on mammalian molars, resulting from the interactions between teeth and from the contact with abrasive food particles.<sup>25</sup> The aforementioned factors contribute to the distinctiveness of the occlusal surface height among individuals' teeth. The tooth-supported template is produced with biomechanics of occlusion a technology that mimics the biomechanics of dental occlusion to provide a highly accurate contact between teeth and a huge compression force.<sup>26</sup>

This study possesses both merits and limitations that necessitate elucidation. To the best of our knowledge, this study is the first report documenting the application of 3D-PTST assisted RFT as an alternative treatment for TN in cases where CT guided puncture proves unsuccessful. The medical records of the six patients included in this study exhibit a high degree of comprehensiveness, and the corresponding data spans a continuous period of five years. One limitation of this study pertains to its retrospective research design. Furthermore, the investigation is further constrained by its narrow focus on clinical cases occurring within specific and uncommon clinical conditions, resulting in a limited sample size. The exploratory nature of the study precludes the ability to establish causal inferences. Furthermore, it should be noted that in the case of the two V<sub>3</sub> TN patients, both experienced weakness in masticatory muscles. While potential factors such as inappropriate radiofrequency temperature during operation or inaccurate selection of the trigeminal ganglion target may contribute to this outcome, the absence of a control group limits our ability to draw definitive conclusions regarding the specific reasons for the observed weakness. This study is conducted at a single center, thus caution should be exercised when generalizing the findings to other hospitals. The study encompassed patients experiencing maxillary and mandibular neuralgia, with our puncture targets being the foramen ovale and foramen rotundum. Due to the limited number of cases in these patient groups and the consistent outcomes observed, a separate analysis was not conducted.

## Conclusion

The individualized tooth-supported template was 3D-printed to assist RFT in puncturing the foramen rotundum or oval foramen in the treatment of TN. An individualized tooth-supported template is beneficial to aid an accurate puncture, shorten the surgery time and reduce the exposure to X-ray during RFT. 3D-PTST guided RFT is an effective, repeatable, safe, and minimally invasive treatment method for patients with TN who have failed due to difficulty in puncture.

## Data Sharing Statement

All data extracted or analyzed during this study are included in this article.

## Acknowledgments

We thank Xiaoyan Qin for polishing the English.



## Author Contributions

All authors made a significant contribution to the work reported, whether that is in the conception, study design, execution, acquisition of data, analysis and interpretation, or in all these areas; took part in drafting, revising or critically reviewing the article; gave final approval of the version to be published; have agreed on the journal to which the article has been submitted; and agree to be accountable for all aspects of the work.

## Disclosure

The authors report no conflicts of interest in this work.

## References

1. Li M, Yan J, Wen H, et al. Cortical thickness, gyrification and sulcal depth in trigeminal neuralgia. *Sci Rep*. 2021;11(1):16322. doi:10.1038/s41598-021-95811-z
2. Vasavda C, Xu R, Liew J, et al. Identification of the NRF2 transcriptional network as a therapeutic target for trigeminal neuropathic pain. *Sci Adv*. 2022;8(31):eabo5633. doi:10.1126/sciadv.abo5633
3. International Headache Society. Headache Classification Committee of the International Headache Society (IHS) the international classification of headache disorders, 3rd edition. *Cephalalgia*. 2018;38(1):1–211. doi:10.1177/0333102417738202
4. Bendtsen L, Zakrzewska JM, Abbott J, et al. European Academy of neurology guideline on trigeminal neuralgia. *Eur J Neurol*. 2019;26(6):831–849. doi:10.1111/ene.13950
5. Edvinsson JCA, Warfvinge K, Krause DN, et al. C-fibers may modulate adjacent Adelta-fibers through axon-axon CGRP signaling at nodes of Ranvier in the trigeminal system. *J Headache Pain*. 2019;20(1):105. doi:10.1186/s10194-019-1055-3
6. Wan Q, Zhang D, Cao X, et al. CT-guided selective percutaneous radiofrequency thermocoagulation via the foramen rotundum for isolated maxillary nerve idiopathic trigeminal neuralgia. *J Neurosurg*. 2018;128(1):211–214. doi:10.3171/2016.9.JNS152520
7. Wagner MG, Hinshaw JL, Li Y, et al. Ultra-low radiation dose CT fluoroscopy for percutaneous interventions: a porcine feasibility study. *Radiology*. 2019;291(1):241–249. doi:10.1148/radiol.2019181362
8. Wang M, Liu T, Xu C, et al. 3D-printed hemipelvic prosthesis combined with a dual mobility bearing in patients with primary malignant neoplasm involving the acetabulum: clinical outcomes and finite element analysis. *BMC Surg*. 2022;22(1):357. doi:10.1186/s12893-022-01804-8
9. Pommier B, Touzet G, Lucas C, et al. Glossopharyngeal neuralgia treated by Gamma Knife radiosurgery: safety and efficacy through long-term follow-up. *J Neurosurg*. 2018;128(5):1372–1379. doi:10.3171/2017.3.JNS162542
10. Rogers CL, Shetter AG, Fiedler JA, et al. Gamma knife radiosurgery for trigeminal neuralgia: the initial experience of the Barrow Neurological Institute. *Int J Radiat Oncol Biol Phys*. 2000;47(4):1013–1019. doi:10.1016/S0360-3016(00)00513-7
11. Zakrzewska JM, Wu J, Mon-Williams M, et al. Evaluating the impact of trigeminal neuralgia. *Pain*. 2017;158(6):1166–1174. doi:10.1097/j.pain.0000000000000853
12. Wu H, Zhou J, Chen J, et al. Therapeutic efficacy and safety of radiofrequency ablation for the treatment of trigeminal neuralgia: a systematic review and meta-analysis. *J Pain Res*. 2019;12:423–441. doi:10.2147/JPR.S176960
13. Wang R, Han Y, Lu L. Computer-assisted design template guided percutaneous radiofrequency thermocoagulation through foramen rotundum for treatment of isolated V2 trigeminal neuralgia: a retrospective case-control study. *Pain Res Manag*. 2019;2019:9784020. doi:10.1155/2019/9784020
14. Zhang H, Ni H, Liu S, et al. Supraorbital nerve radiofrequency for severe neuralgia caused by herpes zoster ophthalmicus. *Pain Res Manag*. 2020;2020:1–7.
15. Hug EB, Pelak M, Frank SJ, et al. A review of particle therapy for skull base tumors: modern considerations and future directions. *Int J Part Ther*. 2021;8(1):168–178. doi:10.14338/IJPT-20-00083
16. Bencharit S, Staffen A, Yeung M, et al. In vivo tooth-supported implant surgical guides fabricated with desktop stereolithographic printers: fully guided surgery is more accurate than partially guided surgery. *J Oral Maxillofac Surg*. 2018;76(7):1431–1439. doi:10.1016/j.joms.2018.02.010
17. Mathews JD, Forsythe AV, Brady Z, et al. Cancer risk in 680 000 people exposed to computed tomography scans in childhood or adolescence: data linkage study of 11 million Australians. *BMJ*. 2013;346(1):f2360–f2360. doi:10.1136/bmj.f2360
18. Schmitz-Feuerhake I, Pflugbeil S, Pflugbeil C. Röntgenrisiko: abschätzung der strahleninduzierten Meningeome und anderer Spätschäden bei Exposition des Schädels. *Das Gesundheitsw*. 2009;72(04):246–254. doi:10.1055/s-0029-1215570
19. Rybicki FJ. Medical 3D printing and the physician-artist. *Lancet*. 2018;391(10121):651–652. doi:10.1016/S0140-6736(18)30212-5
20. Louvrier A, Marty P, Barrabe A, et al. How useful is 3D printing in maxillofacial surgery? *J Stomatol Oral Maxillofac Surg*. 2017;118(4):206–212. doi:10.1016/j.jormas.2017.07.002
21. Chu H, Yang W, Sun L, et al. 4D Printing: a review on recent progresses. *Micromachines*. 2020;11(9):796. doi:10.3390/mi11090796
22. Zhang LG, Deng MH, Long X, et al. 3D 打印导板辅助射频频温控热凝术治疗第2支三叉神经痛的临床研究 [3D printing navigation template-guided percutaneous radiofrequency thermocoagulation for V2 trigeminal neuralgia treatment]. *Hua Xi Kou Qiang Yi Xue Za Zhi*. 2018;36(6):662–666. Chinese. doi:10.7518/hxkq.2018.06.015
23. Valdec S, Schiefersteiner M, Rucker M, et al. Guided biopsy of osseous pathologies in the jaw bone using a 3D-printed, tooth-supported drilling template. *Int J Oral Maxillofac Surg*. 2019;48(8):1028–1031. doi:10.1016/j.ijom.2019.04.007
24. Wang Y-L, Pan -H-H, Chang -H-H, et al. Concomitant hypo-hyperdontia: a rare entity. *J Dent Sci*. 2018;13(1):60–67. doi:10.1016/j.jds.2018.01.001
25. Winkler DE, Schulz-Kornas E, Kaiser TM, et al. Dental microwear texture reflects dietary tendencies in extant Lepidosauria despite their limited use of oral food processing. *Proc R Soc B*. 2019;1903:286.
26. Peck CC. Biomechanics of occlusion--implications for oral rehabilitation. *J Oral Rehabil*. 2016;43(3):205–214. doi:10.1111/joor.12345

Journal of Pain Research

Dovepress

### Publish your work in this journal

The Journal of Pain Research is an international, peer reviewed, open access, online journal that welcomes laboratory and clinical findings in the fields of pain research and the prevention and management of pain. Original research, reviews, symposium reports, hypothesis formation and commentaries are all considered for publication. The manuscript management system is completely online and includes a very quick and fair peer-review system, which is all easy to use. Visit <http://www.dovepress.com/testimonials.php> to read real quotes from published authors.

Submit your manuscript here: <https://www.dovepress.com/journal-of-pain-research-journal>