



Case report

Diffuse alveolar hemorrhage, a rare presentation of polymyositis

Sharoon Samuel^{a,*}, Brent Brown^c, Nita Mason^b, Tony Abdo^c^a Department of Internal Medicine, University of South Dakota Sanford School of Medicine, USA^b Department of Radiological Sciences, Oklahoma University Health Sciences Center, Oklahoma City, OK, USA^c Department of Pulmonary & Critical Care, Oklahoma University Health Sciences Center, Oklahoma City, OK, USA

ARTICLE INFO

Keywords:

Polymyositis
Diffuse alveolar hemorrhage
Pulmonary capillaritis
Pulmonary hemorrhage
Bronchioalveolar lavage

ABSTRACT

Background: Diffuse alveolar hemorrhage is a medical emergency caused by persistent and recurrent pulmonary hemorrhage [1]. It is an uncommon presentation of polymyositis. Symptoms of polymyositis include fatigue, muscle pains, proximal muscle weakness, and joint pains [2].

Case presentation: A 44-year-old male presented with new onset shortness of breath and productive cough with white sputum and occasional hemoptysis. The patient was diagnosed with diffuse alveolar hemorrhage (DAH) via bronchoscopy and discharged initially on prednisone. The patient's laboratory work indicated positive titers of ANA & anti-Jo-1 antibody with low complement levels. These results pointed towards the diagnosis of polymyositis [3]. DAH can also be caused by systemic lupus erythematosus, Goodpasture's syndrome, Sjogren syndrome, anticoagulant therapy, and antiphospholipid antibody syndrome [4]. However, the possibility of these potential causes was excluded.

Conclusion: This case of diffuse alveolar hemorrhage was most likely due to polymyositis.

1. Introduction

Diffuse alveolar hemorrhage (DAH) is a persistent and severe pulmonary hemorrhage principally due to the inflammation of pulmonary capillaries [5]. DAH is classified as originating from immune or non-immune causes. It is a common complication seen in a majority of autoimmune diseases. Over 30–40% cases of DAH are secondary to autoimmune etiologies but it is a rare presentation of polymyositis [6] [ref. Severe DAH autoimmune, Mirouse]. Around 12% of ICU admissions in patients with autoimmune diseases are attributed to DAH [7]

DAH may also result from coagulation disorders, inhaled toxins, or infections. These factors result in widespread inflammation of pulmonary capillaries also known as pulmonary capillaritis. This extensive inflammatory response causes leakage of blood through the capillaries which leads to the collection of blood within the alveoli [8]. There are three distinct histopathological patterns for diffuse alveolar hemorrhage [5,10]:

1. Pulmonary capillaritis: This pattern results from pulmonary capillary inflammation and neutrophil infiltration leading to necrosis and leakage of blood into the alveolar space.

2. Bland pulmonary hemorrhage: This pathological pattern results from bleeding disorders and anticoagulant therapy. There is no damage to alveolar walls.
3. Diffuse alveolar damage: Massive destruction of alveolar septa with formation of a hyaline membrane is seen in this type.

Another rare cause of diffuse alveolar hemorrhage is negative pressure pulmonary edema (NPPE). NPPE is seen in upper airway obstruction. Repeated inspiratory pressure against a closed glottis leads to negative intrathoracic and subsequently negative intra pulmonary pressure leading to leakage of blood from pulmonary vasculature [9].

The most common presenting symptom of DAH is hemoptysis. However, it can also present with dyspnea, cough, and fever. In severe cases of DAH, acute respiratory failure might occur leading to death. Polymyositis is an autoimmune disorder that results in inflammation of muscle tissue. It mostly presents with fatigue, myalgias, and proximal myopathy. It is diagnosed with electromyography (EMG), positive anti jo 1 antibodies, and clinical signs and symptoms. Treatment involves steroids and immunomodulatory agents.

* Corresponding author. University of South Dakota Sanford School of Medicine, 1400 W 22nd St Sioux Falls, SD, 57104, USA.

E-mail addresses: sharoon.samuel@usd.edu (S. Samuel), Brent-Brown@ouhsc.edu (B. Brown), nita-mason@ouhsc.edu (N. Mason), tony-abdo@ouhsc.edu (T. Abdo).

<https://doi.org/10.1016/j.rmcr.2020.101261>

Received 11 July 2020; Received in revised form 15 September 2020; Accepted 10 October 2020

Available online 17 October 2020

2213-0071/© 2020 Published by Elsevier Ltd. This is an open access article under the CC BY-NC-ND license (<http://creativecommons.org/licenses/by-nc-nd/4.0/>).

2. Case presentation

A 44-year-old Hispanic male with no significant past medical history presented with new onset of dyspnea and hemoptysis. He was treated for community-acquired pneumonia (CAP) with levofloxacin and albuterol inhaler as needed, owing to patchy alveolar opacities on chest x-ray (10). There was no history of smoking, alcohol intake, illicit drug intake, and additional medications. The patient was observed for two weeks on this treatment regimen and showed no further improvement.

A CT scan was performed which showed multifocal ground-glass opacities. There was worsening hemoptysis and dyspnea with no improvement in the patient's condition. He underwent bronchoscopy which revealed diffuse hemorrhage. Consequently, the ongoing treatment for CAP was stopped. The treatment plan was changed to prednisone. The patient's symptoms resolved during the steroid intake and the patient was discharged on a steroid taper. A week after the steroid course was completed, he presented with a fever (104F), shortness of breath, chills, and lost 20 pounds (lbs) of weight. The patient was then admitted to the hospital. On physical examination, the patient was in visible distress with tachycardia, regular heart rhythm, scattered crackles throughout the chest and trace edema on the left lower extremity.

Upon performing lab studies, his blood counts showed an elevation of WBCs to 13.05k/mm³, with a low Hgb of 11.2g/dL and low RBCs of 3.91k/mm³. Moreover, the patient had a significant elevation of LDH levels to 324U/L and D-dimer levels to 393ng/mL DDU. His blood gases were at a pH of 7.47 and pCO₂, pO₂ pressures were 30 mmHg and 64 mmHg, sequentially. The patient had an O₂ saturation of 94% on 12L nasal cannula. A CT angiogram was performed, and it excluded pulmonary embolism showing multi-lobar ground glass opacities. These opacities can be due to pulmonary edema, diffuse alveolar hemorrhage or pneumonia [11]. Given the patient's high WBC count, a sputum culture was tested, and he was started on empiric antibiotics. The sputum culture tested positive for a moderate number of gram-positive cocci in chains and pairs, and a few gram-positive cocci in clusters. Creatine phosphokinase (CPK) levels were normal at 87 and 98U/L on two different occasions. Aldolase was elevated at 10.5U/L. Additionally, complement levels were done revealing reduced C3, C4 levels. Also, the patient's ANA titer was 1:1080, eliciting an autoimmune etiology. In response to these results, the Rheumatology Department was consulted, and an autoimmune panel was ordered for the patient. The panel results were positive for anti pl-7 antibodies, negative anti pl-12, anti ej, anti oj, anti-mi-2, p- ANCA, c-ANCA and anti srp antibodies. Keeping in view the above results of the autoimmune panel with a lack of other possible causes including, drugs, toxins, congestive cardiac failure, anticoagulant use, HIV or hepatitis C virus causing cryoglobulinemia, a final diagnosis of polymyositis was made.

Following these tests, the patient was discharged on 2 L of home oxygen and prolonged steroid taper. Upon follow-up, the patient's health and respiratory status improved. However, the patient still complained of cough and yellow sputum with no complaint of hemoptysis. Upon further inquiry, an acne-form rash on the arms and back of the trunk of the patient was discovered. These symptoms were most likely attributed to glucocorticoid-induced acne. On the other hand, there was no evidence of joint pain or stiffness. After a subsequent follow-up, the patient's oxygen requirements at home dropped to 1 L with improved cough and decreased sputum. He was given an additional dose of rituximab. Low dose azathioprine was also administered to the patient and he was started on a steroid taper. The patient reported significant improvement in symptoms while being treated with this regimen.

3. Discussion

Diffuse alveolar hemorrhage (DAH) is a potentially life-threatening condition presenting with hemoptysis, cough, shortness of breath, anemia and acute respiratory failure. This condition is generally diagnosed through bronchoalveolar lavage or bronchoscopy. DAH commonly affects a diffuse area of the lung parenchyma, however, in some cases, focal involvement is also seen. DAH is a common complication of certain autoimmune diseases such as SLE, Goodpasture's syndrome, dermatomyositis, polymyositis and infections including hantavirus (6). The pathophysiology of DAH in autoimmune diseases and infectious etiologies is postulated to be due to diffuse damage to the alveolar lining resulting in inflammation of the pulmonary capillaries and the alveolar lining. This inflammation leads to widespread damage of the capillaries i.e. pulmonary capillaritis causing hemorrhage involving multiple lobes of the lung. There are 3 histopathological patterns [5, 12]

1. **Pulmonary capillaritis:** It is the most common feature in 80–90% of the patients. It involves vasculitis, in which the walls of the capillaries are infiltrated by neutrophils causing necrosis and resulting in leakage of blood from the vessels into the alveolar space.
2. **Bland pulmonary hemorrhage:** This involves frank hemorrhage in the alveolar spaces without any damage to the walls. Most common causes are bleeding disorders and anticoagulant therapy
3. **Diffuse alveolar damage:** Results in massive destruction of the alveolar septa with the formation of a hyaline membrane. All causes of ARDS can be included in this.

DAH is commonly seen as a complication of autoimmune diseases but patients with polymyositis presenting with DAH without significant symptoms of fatigue, muscle aches, and proximal myopathy are relatively rare, making this case worth noting. There have been at least 2 case reports in the past with patients presenting with fatigue, muscle pains with unclear diagnosis who are admitted to the hospital. These patients developed acute respiratory failure and were found to have diffuse alveolar hemorrhage as well as bronchiolitis obliterans-organizing pneumonia. In one of these cases the patient had positive anti Jo-1 antibodies. In the other case the patient had negative autoimmune work up but was diagnosed with polymyositis through muscle biopsy [6]. There have been other cases of patient with established diagnosis of polymyositis presenting with diffuse alveolar hemorrhage and respiratory failure. Because the clinical presentation of DAH is highly variable the diagnosis can be hard to establish in certain cases requiring clinician's ability to recognize the pattern of presentation combined with lab results, imaging, pathology, and antibody panels [13].

DAH has a poor prognosis, with mortality ranging from 25% to 50% [13]. Given the high morbidity and mortality associated with DAH early recognition by the clinician provides prognostic benefit to the patient and helps to establish the etiology behind diffuse alveolar hemorrhage. The diagnosis is based on clinical, laboratory, radiological, pathological and bronchoalveolar lavage findings (4) [10]. The diagnosis can be confirmed by biopsy which shows hemosiderin-laden macrophages, RBCs, and fibrin. Hemosiderin is an important component as it differentiates it from surgical trauma [4].

The x-ray findings are mostly nonspecific [13] these include consolidation in 43% of the patients [14] and alveolar opacities like in our patient, based on which he was treated on the lines of community-acquired pneumonia with levofloxacin and albuterol. When there was no improvement, he underwent more extensive tests, including a CT scan, and laboratory assays.

The CT scan findings include ground glass opacities in 55% of the patients including our reported case [14]. Hence, the CT was followed by a bronchoscopy to demarcate the etiology of the imaging results. The bronchoalveolar lavage has significant diagnostic value in DAH. Increasing RBC count in sequential BALs with bloody or pink lavage fluid is diagnostic of DAH [4,15].

Polymyositis (PM) is an autoimmune disease mainly targeting the skeletal muscle tissue [16]. Other organs can also be involved such as the heart, skin, gastrointestinal tract and lungs (16). PM can affect individuals of any age group, mostly between 50 and 70 years and is a very rare disease, often misdiagnosed. The overall prevalence is 1: 100,000. PM can be classified as:

1. Primary Idiopathic PM
2. PM associated with malignancy
3. Childhood PM [17].

The presenting complaints of polymyositis are relatively slow to develop and include fatigue, muscle aches and proximal myopathy with the most characteristic feature of difficulty in climbing stairs or getting up from a chair [16,17]. The diagnosis is established with abnormalities in electromyography (EMG), positive anti jo 1 antibodies and clinical picture. The most important diagnostic test is a muscle biopsy which shows inflammatory changes with T lymphocyte and macrophage infiltration [17].

The pathophysiological mechanisms by which Polymyositis causes damage to muscles includes direct effect of inflammatory cell infiltrates, indirect effect of cytokines, and direct damage of microvasculature which includes endothelial changes leading to increased inflammatory infiltrate through the vessel wall. The histopathological changes in polymyositis exhibit the presence of a mono nuclear inflammatory

infiltrate. The hallmark of polymyositis is endomysial inflammatory infiltrate with atrophy of muscle fibers.

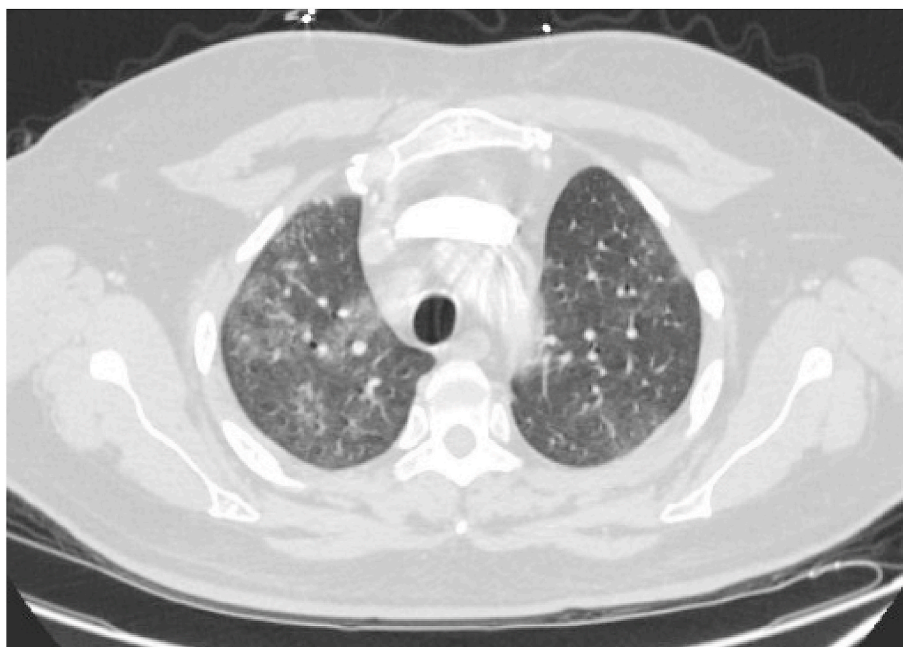
This case points out that some patients may present with a late complication of an autoimmune disease without an established diagnosis. As shown by the lab results and the exclusion of all other causes on history, physical exam, and imaging this patient most likely had a DAH secondary to a newly diagnosed polymyositis.

4. Conclusion

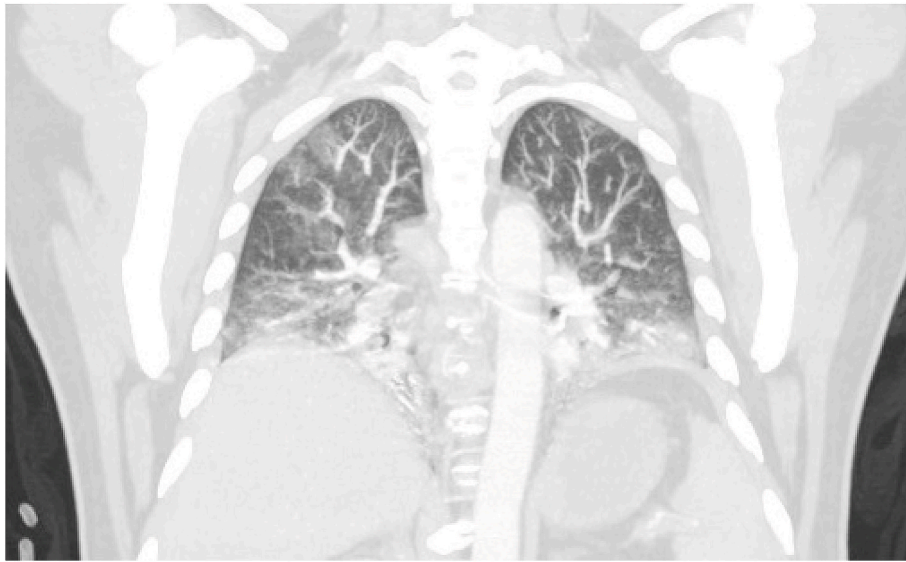
This patient with sudden onset dyspnea, diffuse hemorrhaging on bronchoscopy and positive antibodies for autoimmune muscle disease most likely had polymyositis. Studies revealing the percentage of autoimmune diseases presenting with severe complications like DAH can help the physician in making a clinical diagnosis in patients presenting with such rare presentations.

Sr. No	Antibody	Associated Disease(s)	Result in reported patient
1	ANA	Most autoimmune diseases	Positive 1:1080
2	Anti pl-7	Anti-synthetase syndrome	Positive
3	Anti pl-12	Interstitial Lung disease (ILD), less often autoimmune arthritis and myositis	Negative
4	Anti oj	Anti-synthetase syndrome/ILD	Negative
5	Anti-mi-2	Idiopathic inflammatory myopathies	Negative
6	Anti srp	Immune mediated necrotizing myopathy	Negative
7	c-ANCA	Granulomatosis with polyangiitis	Negative

6. Figures



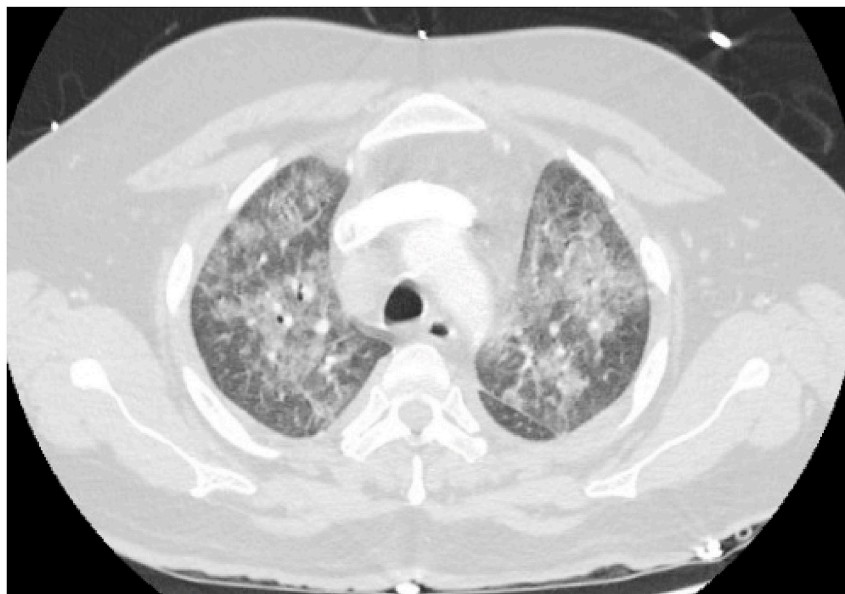6.1



6.2

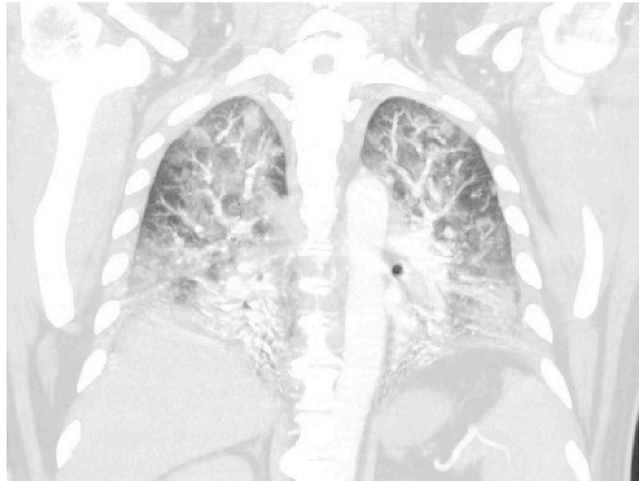
Axial (6.1) and Coronal maximum intensity projection (MIP) (6.2) of the chest on initial presentation shows multifocal ground-glass airspace

opacities, most pronounced in the right upper lobe. These opacities are nonspecific and top differential considerations would include infection, pulmonary edema, and alveolar hemorrhage.



6.3

6.5: Increasing RBC count in sequential BALs with bloody or pink lavage fluid is diagnostic of DAH.




6.4

Axial (6.3) and Coronal MIP (6.4) of the chest 3 weeks later show progression of multifocal ground-glass airspace opacities.

Funding source

Authors have no relevant financial relationships to disclose.
Signed:



Sharoon Samuel MD 07/11/2020 Brent Brown MD November 07, 2020 Nita Mason DO 07/11/2020 Tony Abdo MD November 07, 2020.

Declaration of competing interest

Authors declare no conflict of interest with this manuscript.

References

- [1] J.P. Lichtenberger, S.R. Digumarthy, G.F. Abbott, J.-A.O. Shepard, A. Sharma, Diffuse pulmonary hemorrhage: clues to the diagnosis, *Curr. Probl. Diagn. Radiol.* 43 (3) (2014) 128–139.
- [2] M.C. Dalakas, R. Hohlfield, Polymyositis and dermatomyositis, *Lancet (London, England)* 362 (9388) (2003) 971–982.
- [3] L.M. Miletic, M.E. Strek, T.B. Niewold, J.J. Curran, N.J. Sweiss, Clinical characteristics of patients with anti-Jo-1 antibodies: a single center experience, *J. Clin. Rheumatol. : practical reports on rheumatic & musculoskeletal diseases* 15 (5) (2009) 254–255.
- [4] M.S. Park, Diffuse alveolar hemorrhage, *Tuberc. Respir. Dis.* 74 (4) (2013) 151–162.
- [5] H.R. Collard, M.I. Schwarz, Diffuse alveolar hemorrhage, *Clin. Chest Med.* 25 (3) (2004) 583–592.
- [6] M.I. Schwarz, J.M. Sutarik, J.A. Nick, J.A. Leff, J.W. Emlen, R.M. Tuder, Pulmonary capillaritis and diffuse alveolar hemorrhage. A primary manifestation of polymyositis, *Am. J. Respir. Crit. Care Med.* 151 (6) (1995) 2037–2040.
- [7] A. Mirouse, A. Parrot, V. Audigier, A. Demoule, J. Mayaux, G. Géri, et al., Severe diffuse alveolar hemorrhage related to autoimmune disease: a multicenter study, *Crit. Care* 24 (1) (2020) 231.
- [8] M.L. Krause, R. Cartin-Ceba, U. Specks, T. Peikert, Update on diffuse alveolar hemorrhage and pulmonary vasculitis, *Immunol. Allergy Clin.* 32 (4) (2012) 587–600.
- [9] W.K. Choi, J.M. Lee, J.B. Kim, K.S. Im, B.H. Park, S.B. Yoo, et al., Diffuse alveolar hemorrhage following sugammadex and remifentanyl administration: a case report, *Medicine (Baltim.)* 98 (8) (2019), e14626.
- [10] A.M. Noreddin, W.F. Elkhatib, K.M. Cunliffe, G.G. Zhanel, Cumulative clinical experience from over a decade of use of levofloxacin in community-acquired pneumonia: critical appraisal and role in therapy, *Drug Healthc. Patient Saf.* 3 (2011) 59–68.
- [11] M. Nishino, H. Itoh, H. Hatabu, A practical approach to high-resolution CT of diffuse lung disease, *Eur. J. Radiol.* 83 (1) (2014) 6–19.
- [12] T. Onuk, G. İpek, M.B. Karataş, R. Hacı, N. Çam, Diffuse alveolar hemorrhage after clopidogrel use, *Balkan Med. J.* 33 (6) (2016) 719–720.
- [13] V. Scollo, L. Zanolli, E. Russo, G. Distefano, F. Rapisarda, A case of rare diffuse alveolar hemorrhage and review of literature, *Clin. Med. Insights Case Rep.* 10 (2017), 1179547617726077.
- [14] R. Lazor, L. Bigay-Gamé, V. Cottin, J. Cadranet, O. Decaux, J.-M. Fellrath, et al., Alveolar hemorrhage in anti-basement membrane antibody disease: a series of 28 cases, *Medicine* 86 (3) (2007) 181–193.
- [15] N. de Prost, A. Parrot, C. Picard, P.-Y. Ancel, C. Mayaud, M. Fartoukh, et al., Diffuse alveolar haemorrhage: factors associated with in-hospital and long-term mortality, *Eur. Respir. J.* 35 (6) (2010) 1303–1311.
- [16] A.R. Findlay, N.A. Goyal, T. Mozaffar, An overview of polymyositis and dermatomyositis, *Muscle Nerve* 51 (5) (2015) 638–656.
- [17] K. Hunter, M.G. Lyon, Evaluation and management of polymyositis, *Indian J. Dermatol.* 57 (5) (2012) 371–374.