



**Original Article**

**Diagnostic Performance and Safety of Bronchoalveolar Lavage in Thrombocytopenic Haematological Patients for Invasive Fungal Infections Diagnosis: A Monocentric, Retrospective Experience**

Mariagiovanna Cefalo<sup>1,\*</sup>, Ermanno Puxeddu<sup>2</sup>, Loredana Sarmati<sup>3</sup>, Giovangiaco Paterno<sup>1</sup>, Carla Fontana<sup>4</sup>, Daniela Nasso<sup>1</sup>, Gloria Pane<sup>2</sup>, Eleonora De Bellis<sup>1</sup>, Raffaele Palmieri<sup>1</sup>, Elisa Buzzati<sup>1</sup>, Federico Meconi<sup>1</sup>, Roberta Laureana<sup>1</sup>, Paola Casciani<sup>1</sup>, Anna Giulia Zizzari<sup>1</sup>, Paola Rogliani<sup>2</sup>, Paolo de Fabritiis<sup>1</sup>, Luca Maurillo<sup>1</sup>, Francesco Buccisano<sup>1</sup>, Maria Cantonetti<sup>1</sup>, William Arcese<sup>1</sup>, Adriano Venditti<sup>1</sup> and Maria Ilaria Del Principe<sup>1</sup>.

<sup>1</sup> Hematology, Department of Biomedicine and Prevention, University of Rome "Tor Vergata", Rome, Italy.

<sup>2</sup> Division of Respiratory Medicine, Department of Experimental Medicine and Surgery, University of Rome "Tor Vergata", Rome, Italy.

<sup>3</sup> Clinical Infectious Diseases, Department of Systems Medicine, University of Rome "Tor Vergata", Rome, Italy.

<sup>4</sup> Clinical Microbiology Laboratories, Department of Experimental Medicine, Tor Vergata University of Rome, Rome, Italy.

**Competing interests:** The authors declare no conflict of Interest.

**Abstract. Background:** Although bronchoalveolar lavage (BAL) measurements of galactomannan antigen (GM) seems to be more sensitive than serum testing to detect invasive fungal infection (IFI), a consensus on the most appropriate diagnostic threshold of the BAL GM test is still unclear. Moreover, there is uncertainty as to whether BAL is a safe procedure in patients with hematological malignancies (HM) and thrombocytopenia.

**Objectives:** Based on this background, 102 adult patients with HM and associated thrombocytopenia were retrospectively analyzed with the dual aim of 1) determining whether BAL is a safe and feasible procedure; and, 2) identifying the most appropriate threshold for GM positivity in the diagnosis of IFI.

**Patients/Methods:** each BAL was considered as one case/patient. One hundred twelve BALs were carried out in 102 HM patients: at the time of the BAL, the median platelet count (PLTs) in all patients was  $47 \times 10^9/L$  (1-476), and 31 patients (27%) had  $PLTs < 20 \times 10^9/L$ .

**Results:** complications from the BAL were infrequent (3.5%) and mild. No bleeding was reported. The BAL GM cut off of  $>0.8$  was associated with the best diagnostic accuracy (sensitivity 72.97% and specificity 80%). Antifungal treatment of patients with BAL GM  $>0.8$  resulted in a clinical-radiological improvement in 35/41 patients (85%).

**Conclusions:** BAL was a safe procedure also in thrombocytopenic patients, permitting an IFI diagnosis not otherwise identifiable using EORTC/MSG criteria. Our data suggest that a BAL GM value of  $>0.8$  represents the most useful cut-off in terms of sensibility and specificity. Further prospective studies on a more significant number of patients are needed to confirm these results.

**Keywords:** Bronchoalveolar lavage; Galactomannan antigen; Pulmonary aspergillosis; Hematologic malignancies; Thrombocytopenia.

**Citation:** Cefalo M., Puxeddu E., Sarmati L., Paterno G., Fontana C., Nasso D., Pane G., De Bellis E., Palmieri R., Buzzati E., Meconi F., Laureana R., Casciani P., Zizzari A.G., Rogliani P., de Fabritiis P., Maurillo L., Buccisano F., Cantonetti M., Arcese W., Venditti A., Del Principe M.I. Diagnostic performance and safety of bronchoalveolar lavage in thrombocytopenic haematological patients for invasive fungal infections diagnosis: a monocentric, retrospective experience. *Mediterr J Hematol Infect Dis* 2019, 11(1): e2019065, DOI: <http://dx.doi.org/10.4084/MJHD.2019.065>

Published: November 1, 2019

Received: July 24, 2019

Accepted: October 14, 2019

Correspondence to: Dr. Mariagiovanna Cefalo, Hematology, Department of Biomedicine and Prevention, University of Rome "Tor Vergata", Viale Oxford, 81, 00133 Rome, Italy. Tel. +39 0620903236/ Fax. +39 0620903221. E-mail: [mariagiovanna.cefalo@hotmail.it](mailto:mariagiovanna.cefalo@hotmail.it)

**Introduction.** Patients affected by hematological malignancies (HM) have an increased risk of invasive fungal infections (IFI) due to prolonged neutropenia, severe immunosuppression, and chemotherapy-induced damage to mucosal barriers.<sup>1,2</sup> Considering that IFI remains a major cause of morbidity and mortality in these patients, timely diagnosis and treatment are required.<sup>3</sup> The diagnosis of IFI relies on clinical, radiological and microbiological criteria.<sup>4</sup> Among microbiological tests, detection of galactomannan (GM), a polysaccharide component of the cell wall of *Aspergillus spp.*, has proven to be more sensitive than culture for an IFI diagnosis.<sup>5</sup> GM is measurable in peripheral blood (serum and plasma) and other biological fluids, such as bronchoalveolar lavage (BAL),<sup>3</sup> and may be released into the blood and other body fluids in the early stages of fungal infections, even before clinical and radiological evidence.<sup>4</sup> However, false-positive results of GM detection may occur because of co-medications and/or host factors. In addition, the sensitivity of serum GM tests may decrease in case of antifungal prophylaxis or empirical/preventive therapy.<sup>3,6,7</sup> For a diagnosis of IFI, the GM test sensitivity is higher with BAL samples than blood samples because airway *Aspergillus* invasion always precedes fungal migration into blood vessels followed by vascular dissemination, resulting in higher quantities of GM in the bronchial fluid.<sup>4</sup> Current European guidelines<sup>5</sup> establish the optimal cut off for GM positivity assay using BAL samples as between 0.5 and 1, yet the best value within this range has not yet been further defined.

BAL is considered an accurate and safe procedure;<sup>8,9</sup> however, complications such as significant bleeding, pneumothorax, and respiratory distress, although infrequent, have been reported.<sup>1,10-15</sup> For this reason, the routine use of BAL in patients with HM, who often present with severe neutropenia and thrombocytopenia, is still a matter of debate.

The aims of the current study were: 1) to demonstrate the feasibility and safety of BAL in HM patients; and, 2) to identify a more specific GM BAL value between 0.5 and 1 that significantly correlates with a diagnosis of IFI.

**Patients and Methods. Study Population.** This retrospective study was conducted between January 2013 and December 2017 in the Department of Hematology of Fondazione Policlinico Tor Vergata of Rome, Italy. All consecutive BAL procedures, performed in adult patients affected by HM, were

reported. Each BAL procedure was considered as one case/patient. BAL was performed within 48-72 hours following a High-Resolution Computerized Tomography (HRCT) scan of the chest. HRCT was routinely performed as initial evaluation before the start of chemotherapy, in the case of a fever persisting more than 72 hours from antibiotic therapy initiation or in the presence of respiratory signs/chest pains not otherwise explained. Patients records were analyzed for the following variables: age, gender, hematological disease, smoking and complications after BAL. BAL complications were defined as the occurrence of any of the following adverse events during the procedure and up to 48 hours post-procedure: dyspnea, new or increased oxygen requirement, fever, hemoptysis, stridor, and pneumothorax or hemothorax.<sup>16</sup>

White blood cells (WBC), absolute neutrophil count (ANC), lymphocytes count, platelets values (PLTs), transfusions, antifungal prophylaxis, diagnostic microbiology (GM assay in serum and in BAL), imaging, antifungal therapy and date of death were also recorded. Radiological experts reviewed all radiological images. Patients were classified as having *possible, probable, proven, or no* IFI, based on the revised European Organization for Research and Treatment of Cancer/Invasive Fungal Infections Cooperative Group and the National Institute of Allergy and Infectious Diseases Mycoses Study Group (EORTC/MSG) criteria.<sup>17,18</sup>

The efficacy of antifungal treatments, based on clinical evaluation and imaging studies,<sup>5</sup> was evaluated on day 30. Mortality was ascribed to IFI (AMR) if the patient died within 30 days after microbiological, clinical or imaging evidence of AMR and if all other alternative causes were excluded.

All personal information was treated secretly, and all clinical data were analyzed anonymously.

**Bronchoscopy. Pre-Procedure Preparation:** In patients with suspected IFI, electrocardiogram (ECG), coagulation studies, platelet count, and hemoglobin concentration were performed and evaluated prior to BAL. Informed consent was obtained from each patient before BAL execution. BAL was performed according to the British Thoracic Society guidelines.<sup>19</sup> Patients with a PLTs count <20x10<sup>9</sup>/L received pooled PLTs transfusion immediately before the procedure. The BAL target site was chosen based on chest HRCT images acquired before the procedure.

**BAL Procedure:** BAL was performed using a flexible

fiber-optic bronchoscope (Olympus BF 1T 180; Olympus, Hamburg, Germany), according to the American Thoracic Society guidelines.<sup>20</sup> A small amount of lidocaine (<200 mg) was used for topical anesthesia. The bronchoscope was placed in a wedge position within the selected bronchopulmonary segment, and a volume of 100 ml in 20 ml aliquots of pre-warmed normal saline solution (at room temperature) was instilled through the bronchoscope and gently aspirated with negative suction pressure of less than 100 mm Hg. A minimal sample volume of 5 ml of pooled BAL fluid was used for BAL microbiological analysis and the GM assay.

**GM detection:** BAL fluid and serum specimens were sent to the microbiology laboratory of Fondazione Policlinico Tor Vergata of Rome for GM assessment, which was performed using a double-sandwich ELISA test known as Platelia *Aspergillus* kit (Bio-Rad Laboratories, CA, USA). The test was run according to the manufacturer's instructions. The absorbance (optical density units) of specimens and controls was determined with a spectrophotometer set at 450 and 620/630 nm wavelength. The whole process was automated using Evolis Twin Plus (Bio-Rad Laboratories, Mississauga, ON).

The presence or absence of GM antigen in each sample was determined using an index value. The index value is the optical density value (ODI) of the specimen divided by the mean optical density of the wells containing Cut-off Control Serum:  $ODI = ODI_{\text{experimental sample}} / \text{Mean Cut-off Control ODI}$ .

Sera with an  $ODI < 0.50$  were qualified negative for GM antigen detection, while sera with an  $ODI \geq 0.50$  were qualified positive for GM antigen.<sup>21</sup> The manufacturer's most optimal BAL GM cut-off value for positivity is considered between 0.5 to 1.0.<sup>5</sup>

**Statistical analysis.** A comparison of dichotomous variables used the chi-square or Fisher exact test; the independent test or Mann-Whitney test was used for continuous variables as appropriate. A p-value less than 0.05 was considered significant.

Diagnostic performance was expressed as sensitivity and specificity, diagnostic odds ratio, and error odds ratio relative to ODI cutoff values using two-way contingency tables. A 95% confidence interval (CI) was calculated for each value. The area under the receiver operating characteristics (ROC) curve was constructed to assess how changes in the ODI cutoff for the GM EIA assay altered the sensitivity and the value of 1-minus specificity. All analyses were performed using the GraphPad Prism 6.0 (GraphPad Software, San Diego, CA, USA) software package.

**Results.** One hundred twelve BALs were performed in 102 HM patients, of which 73 (82%) were male

(median age, 48 years; range 18-78). The most common hematological diagnosis was acute myeloid leukemia (AML; 45%), followed by non-Hodgkin lymphoma (NHL; 33%). Fifty-four patients (53%) were smokers. Of the 35 patients (31%) who underwent BAL before induction course of chemotherapy, 19 (54%) were affected by AML. At the time of BAL, 39 (35%) patients had severe neutropenia ( $ANC < 0.5 \times 10^9/L$ ).<sup>16</sup> Forty-four (39%) patients had a lymphocytes count  $< 1 \times 10^9/L$  (Table 1). The median platelet count of all patients was  $47 \times 10^9/L$  (range 1-476), 51 (45%) and 30 (27%) patients had a PLTS count  $< 40 \times 10^9/L$  and  $< 20 \times 10^9/L$ , respectively.

Twenty-nine patients (26%) underwent BAL while receiving primary or secondary antifungal prophylaxis (6 posaconazole, 6 voriconazole, 16 fluconazole, 2

**Table 1.** Clinical characteristics of patients at time of BAL.

<b>Total patients</b>	<b>112</b>
Median age (range)	48 (18-78)
<b>Gender</b>	<b>n (%)</b>
Male	82 (73)
Female	30 (27)
<b>Diagnosis</b>	<b>n (%)</b>
Acute Myeloid Leukemia (AML)	51 (46)
Non Hodgkin Lymphoma (NHL)	33 (29)
Multiple Myeloma (MM)	7 (6)
Myelodysplastic Syndrome (MDS)	8 (7)
Hodgkin Lymphoma (HL)	2 (2)
Acute Lymphoid Leukemia (ALL)	7 (6)
Aplastic anemia (AA)	4 (4)
<b>Chemotherapy lines</b>	<b>n (%)</b>
0	35 (31)
1-2	54 (48)
>3	23 (21)
Median lymphocytes count (ANC), $\times 10^9/L$ (range)	2.0 (0-14)
<b>Neutropenia</b>	<b>n (%)</b>
Yes	39 (35)
No	73 (65)
Median neutrophils count, $\times 10^9/L$ (range)	1.1 (0.03-25.56)
<b>Lymphopenia</b>	<b>n (%)</b>
Yes	44 (39%)
No	52 (46%)
<b>Symptoms</b>	<b>n (%)</b>
Fever	40 (36)
Dyspnea	21 (19)
<b>Chest HRCT scan diagnosis of IPA (according to EORTC/MSG criteria)</b>	<b>n (%)</b>
Probable	40 (36)
Possible	60(53)
No	12 (11)

HRCT: High-resolution computed tomography.

liposomal B-amphotericin (L-Amb); 1 caspofungin). Nine patients underwent multiple BAL procedures in different periods of their clinical history.

All patients had positive radiological findings. Forty (36%) patients had an HRCT-fulfilling EORTC/MSG criteria of probable IFI diagnosis, 60 (53%) a possible IFI diagnosis, and 12 (11%) had lung infiltrates not classifiable by EORTC/MSG criteria (**Table 1**). Of the 112 BAL procedures, GM was found at a value of > 0.5 in 64 patients (57%). Forty-one of these patients had a GM ODI >0.8 and 37/41 had a GM ODI >1. A serum GM assay was performed in 90/112 cases (80%). The median number of serum GM tests was 16.5 (range 3-48). Among the 90 cases in which both serum and BAL GM were tested, the number of BAL with a GM >0.5 was significantly higher compared to the number of serum GM > 0.5 [55/90 (61%) vs 36/90 (40%) p=.004]. The number of BAL GM positive remained significantly higher than number of serum GM also when we selected the group of patients with an ODI>0.8 [(37/41(90%) vs. 14/37(37%) p<.0001].

It is important to note that among the 31 patients who received antifungal prophylaxis, 20 (65%) had a positive BAL GM, while only 13 (42%) had a positive serum GM.

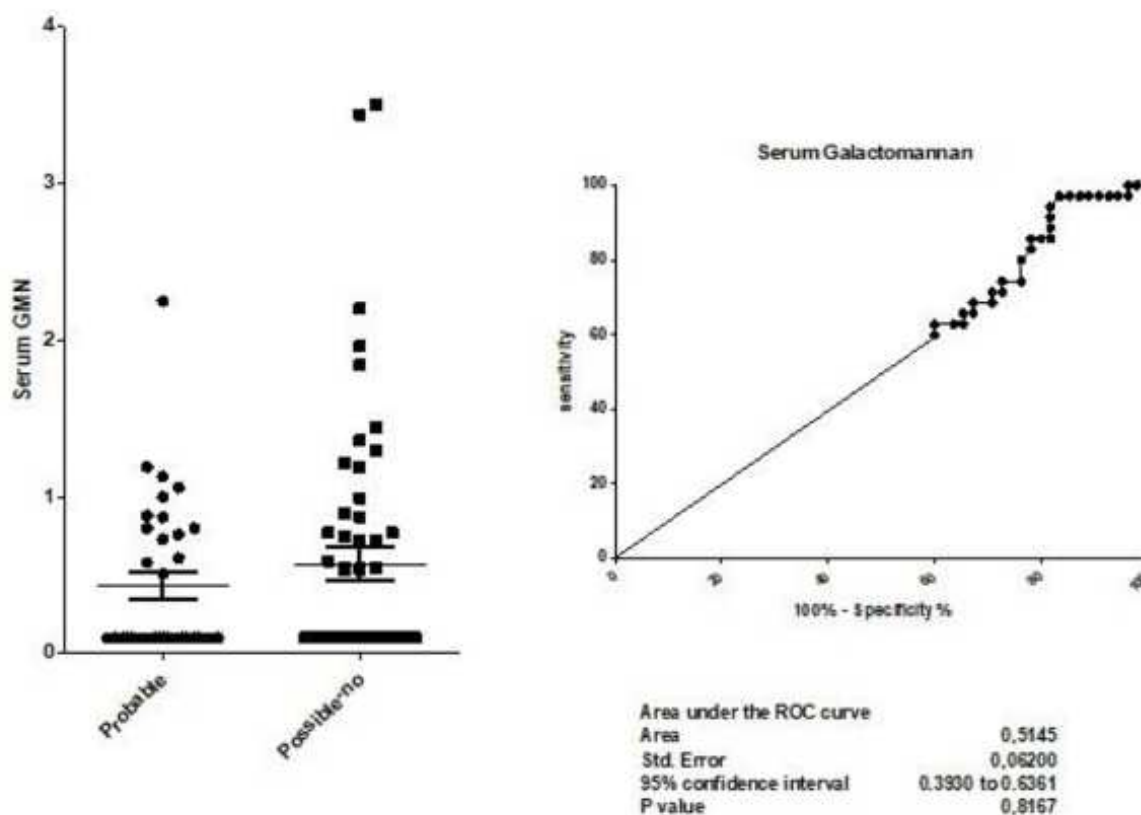
**BAL Safety.** BAL-related complications were observed in 4/112 patients (3.5%); one patient (0.9%) presented fever after the procedure, while 3 (2.6%) developed a

grade 2 hypoxia requiring intermittent supplemental oxygen. All complications occurred within 4-6 hours after the procedure. Regardless of the PLT count, no bleeding was observed.

**Correlation of GM levels with radiological diagnosis of fungal infection.** To evaluate the diagnostic performance of GM levels in the serum and BAL fluid, ROCs were generated as a tool to predict a chest HRCT pattern that fulfilled the EORTC/MSG criteria of probable or possible IFI.<sup>17</sup>

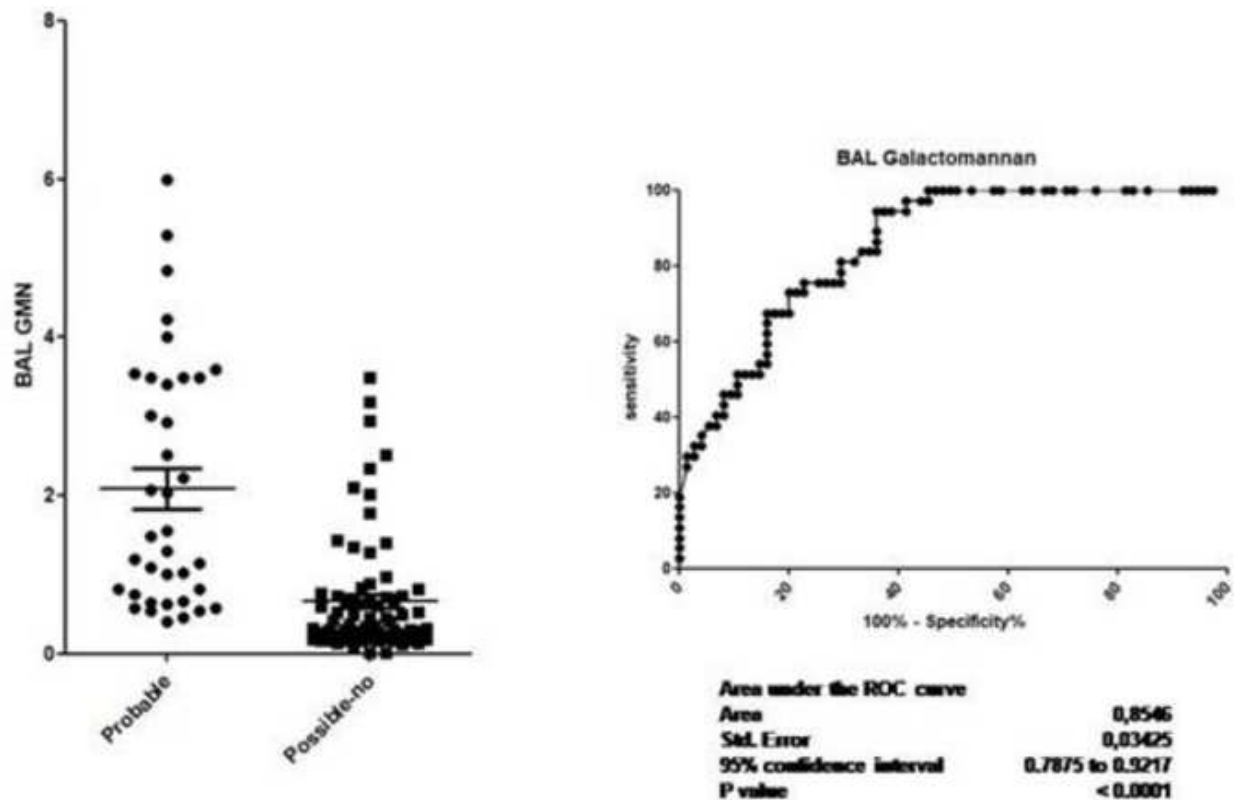
Median serum GM levels were 0.42 (range 0.1 – 0.5) in patients with a radiological pattern of a probable infection, and 0.51 (range 0.43 – 0.62) in those with a radiological pattern of possible infection or inconsistent with IFI in according with EORTC/MSG criteria. The ROC curve analysis resulted in an area under the curve of 0.51 (0.39 – 0.64, p=0.82) (**Figure 1 A and B**).

Median BAL GM levels were 2.12 (range 1.35 – 2.72) in patients with a radiological pattern of probable infection, and 0.48 (range 0.43 – 1.03) in those with a radiological pattern of possible infection or inconsistent with IFI, according with EORTC/MSG criteria. The ROC curve analysis resulted in an area under the curve of 0.85 (0.79 – 0.92, p<0.0001) (**Figure 2 A and B**). The sensibility and specificity of the different cut-offs in serum and BAL GM values are shown in **Tables 2 and 3**.



**Figure 1A, 1B.** Diagnostic performance of serum galactomannan antigen predicts a chest HRCT pattern that fulfills the EORTC/MSG criteria of probable or possible IFI.





**Figure 2A, 2B.** Diagnostic performance of galactomannan in bronchoalveolar lavage fluid predicts a chest HRCT pattern that fulfills the EORTC/MSG criteria of probable or possible IFI.

**Table 2.** Correlation between different cut off values of serum galactomannan antigen and chest HRCT patterns that fulfill the EORTC/MSG criteria of probable/possible or no fungal infection.

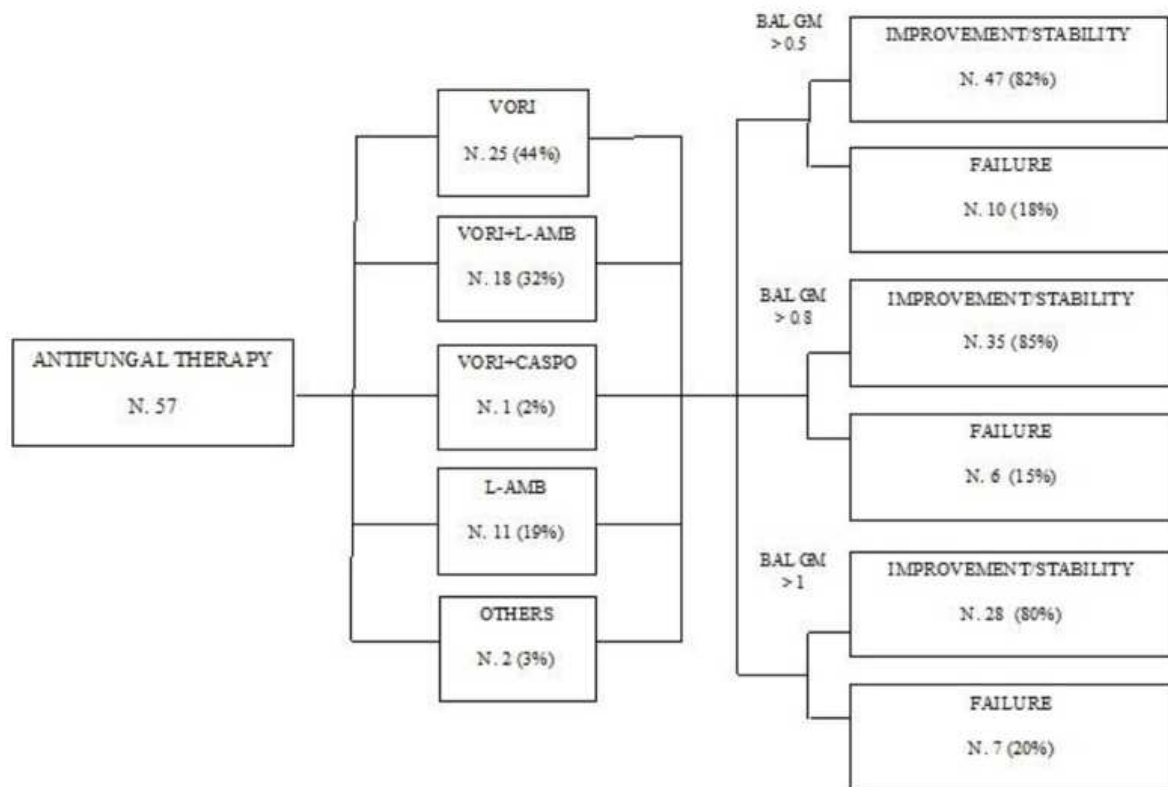
Cut-off	Sensitivity %	95% CI	Specificity %	95%
>0.3	60	42.11% to 76.13%	40	27.02% to 54.09%
>0.5	62.86	44.92% to 78.53%	40	27.02% to 54.09%
>0.8	74.29	56.74% to 87.51%	23.64	13.23% to 37.02%
>1	85.71	69.74% to 95.19%	18.18	9.079% to 30.91%
>1.5	97.14	85.08% to 99.93%	10.91	4.110% to 22.25%

**Table 3.** Correlation between different cut off values of galactomannan antigen in bronchoalveolar lavage fluid and chest HRCT patterns that fulfill the EORTC/MSG criteria of probable/possible or no fungal infection.

Cut-off	Sensitivity %	95% CI	Specificity %	95%
>0.3	100	90.51% to 100.0%	42.67	31.31% to 54.62%
>0.5	94.59	81.81% to 99.34%	61.33	49.38% to 72.36%
>0.8	72.97	55.88% to 86.21%	80	69.17% to 88.35%
>1	67.57	50.21% to 81.99%	84	73.72% to 91.45%
>1.5	48.65	31.92% to 65.60%	89.33	80.06% to 95.28%

**Utility.** Based on the results of BAL GM, 57/64 (89%) patients with an ODI >0.5 started anti-fungal therapy. Voriconazole or liposomal amphotericin B (L-Amb) were used in 44 (77%) and 29 (51%) patients, respectively. Voriconazole was used alone in 25 patients (57%), combined with L-Amb in 18 patients (41%) or caspofungin in 1 patient (2%). L-Amb was used alone in 10 patients (18%). Posaconazole and itraconazole were the other reported options and were utilized in a minority of patients.

Among the 57 patients who received a BAL GM-driven antifungal therapy, the HRCT performed after 30 days of treatment showed an improvement in 35 (61%) cases and stability in 12 (21%) cases. All 41 patients with BAL GM ODI > 0.8 received antifungal therapy, which was voriconazole in 18 (44%), L-Amb in 10 (24%), and a combination of the two agents in 13 (32%). In this group of patients, the HRCT after 30 days of treatment showed an improvement in 21 (51%) cases and stability in 14 (34%) cases. All 35 patients



**Figure 3.** Antifungal therapy (VORI= Voriconazole, L-AMB= liposomal amphotericin B, CASPO= caspofungin) in patients with Bronchoalveolar Lavage (BAL) galactomannan (GM) positive, and evaluation of radiological response after 30 days of treatment in patients with BAL GM>0.5, BAL GM >0.8 and BAL GM>1.

with BAL GM ODI>1 received antifungal therapy, which was voriconazole in 16 (46%), L-Amb in 7 (20%), and voriconazole plus L-Amb in 12 (34%). An improvement upon radiological examination performed on day 30 was observed in 17 (48%) cases, stability 11 (31%). Finally, we have combined radiological improvement and stability data assessed by HRCT on day 30 in patients with a BAL GM value > 0.8, as compared to those with a BAL GM value > 0.5 (85% vs 82%, p=ns) (**Figure 3**). On day 30, overall mortality rate was 14% (16/112), while the AMR rate was 9% (10/112).

**Discussion.** This retrospective study focused on the safety and utility of BAL in patients with HM and on the diagnostic performance of BAL GM assay. In a recent observational study of 1949 bronchoscopies performed in a series of non-HM patients, mild adverse events were reported in 7.2% of the cases, while moderate adverse events, such as hypoxemia and bleeding, were described in 4.9% and in 2.1%, respectively. Furthermore, the rate of severe adverse events requiring additional intervention was 0.5% (pneumothorax, 0.4%, severe bleeding with patient death, 0.1%).<sup>11</sup>

Our study included a small but homogeneous set of cases characterized by the prevalence of patients with thrombocytopenia. Similar to other reports,<sup>1,22</sup> BAL was well tolerated and its complications, observed in

3.5% of patients, were mild and manageable. In patients with PLTs count <20x10<sup>9</sup>/L, BAL was performed only by expert operators after prophylactic PLTs transfusion to minimize the risk of major bleedings and, as a result, no instances of bleeding were observed.

Our results demonstrated an improved sensitivity of the BAL GM assay compared to serum GM evaluation. We also observed a statistically significant correlation between BAL GM values and radiological patterns. Our findings are consistent with previously reported results and confirm that BAL GM assay is a more helpful diagnostic tool than serum GM assay, especially in patients with HM.<sup>4,23-25</sup>

BAL GM positivity was assumed applying the recommended cut-offs, ranging between 0.5 and 1.0.<sup>5,26</sup> The data presented here suggests that an ODI value of >0.8 is the best predictor of a positive IFI diagnosis (sensitivity 72.97% and specificity 80%; **Table 3**).

Several BAL procedures were performed in patients with AML before the start of induction course of chemotherapy based on radiological picture suggesting fungal infection. Among non-transplanted patients, those with AML who underwent remission-induction therapy were at the highest risk to develop IFI.<sup>27</sup> This risk was amplified in presence of additional risk factors such as severe baseline neutropenia, a low complete remission rate of haematological disease, or an age greater than 65.<sup>28</sup> The European Conference on

Infections in Leukaemia (ECIL) recommendations considered this category of patients for primary mold prophylaxis at an A1 level of evidence.<sup>29</sup> However, the use of antifungals, such as triazoles, in this setting is usually considered to significantly decrease the sensitivity of serum GM assay.<sup>30</sup> In this study, 31 (28%) patients undergoing BAL for GM detection received antifungal prophylaxis. Of these, 20 (65%) patients showed BAL GM positivity and 13 (42%) serum GM positivity.

The practical utility of BAL GM testing is confirmed by the observation that the majority of patients who started an antifungal treatment based on BAL GM positivity showed radiological improvement or stability after 30 days from the start of treatment. Furthermore, a better, although not significant,

radiological result was observed in patients with BAL GM value > 0.8 respect to those patients with BAL GM value > 0.5. This observation seems to suggest a higher specificity of the BAL GM value of 0.8 ODI compared to 0.5 ODI, although more significant sample size is required to confirm this very preliminary result.

**Conclusions.** Our data suggest that BAL can be safely utilized in HM patients with severe thrombocytopenia and is able to identify IFI that is not otherwise classifiable with EORTC/MSG criteria, in line with other experiences.<sup>31-32</sup> Moreover, a BAL GM ODI value of >0.8 may represent the most appropriate cut off in terms of sensibility and specificity.<sup>25</sup> Further prospective studies on larger series of patients with a longer follow up are needed to confirm these results.

## References:

- Svensson T, Lundström KL, Höglund M, Cherif H. Utility of bronchoalveolar lavage in diagnosing respiratory tract infections in patients with hematological malignancies: are invasive diagnostics still needed? *Ups J Med Sci.* 2017;122(1):56-60. <https://doi.org/10.1080/03009734.2016.1237595> PMID:27739337 PMCID:PMC5361433
- Baddley JW. Clinical risk factors for invasive aspergillosis. *Med Mycol.* 2011;49 Suppl1:S7-S12. <https://doi.org/10.3109/13693786.2010.505204> PMID:20718606
- Eigl S, Hoenigl M, Spiess B, Heldt S, Prattes J, Neumeister P, Wolfner A, Rabensteiner J, Pruessner F, Krause R, Reinwald M, Flick H, Buchheidt D, Boch T. Galactomannan testing and Aspergillus PCR in same-day bronchoalveolar lavage and blood samples for diagnosis of invasive aspergillosis. *Med Mycol.* 2017;55(5):528-534. <https://doi.org/10.1093/mmy/myw102> PMID:27744310
- Gupta A, Capoor MR, Shende T, Sharma B, Mohindra R, Suri JC, Gupta DK. Comparative evaluation of galactomannan test with bronchoalveolar lavage and serum for the diagnosis of invasive aspergillosis in patients with hematological malignancies. *J Lab Physicians.* 2017;9(4):234-238. [https://doi.org/10.4103/JLP.JLP\\_127\\_16](https://doi.org/10.4103/JLP.JLP_127_16) PMID:28966482 PMCID:PMC5607749
- Ullmann AJ, Aguado JM, Arikan-Akdagli S, Denning DW, Groll AH, Lagrou K, Lass-Flörl C, Lewis RE, Muñoz P, Verweij PE, Warris A, Ader F, Akova M, Arendrup MC, Barnes RA, Beigelman-Aubry C, Blot S, Bouza E, Brüggemann R, Buchheidt D, Cadranet J, Castagnola E, Chakrabarti A, Cuenca-Estrella M, Dimopoulos G, Fortun J, Gangneux JP, Garbino J, Heinz WJ, Herbrecht R, Heussel CP, Kibbler CC, Klimko N, Kullberg BJ, Lange C, Lehrnbecher T, Löffler J, Lortholary O, Maertens J, Marchetti O, Meis JF, Pagano L, Ribaud P, Richardson M, Roilides E, Ruhnke M, Sanguinetti M, Sheppard DC, Sinkó J, Skiada A, Vehreschild MJGT, Viscoli C, Cornely OA. Diagnosis and management of Aspergillus diseases: executive summary of the 2017 ESCMID-ECMM-ERS guideline. *Clin Microbiol Infect.* 2018; 24, e1-e38. <https://doi.org/10.1016/j.cmi.2018.01.002> PMID:29544767
- Hoenigl M, Seeber K, Koidl C, Buzina W, Wölfler A, Duettmann W, Wagner J, Strenger V, Krause R. Sensitivity of galactomannan enzyme immunoassay for diagnosing breakthrough invasive aspergillosis under antifungal prophylaxis and empirical therapy. *Mycoses.* 2013;56(4):471-6. <https://doi.org/10.1111/myc.12060> PMID:23432536
- Marr KA, Laverdiere M, Gugel A, Leisenring W. Antifungal therapy decreases sensitivity of the Aspergillus galactomannan enzyme immunoassay. *Clin Infect Dis.* 2005;40(12):1762-9. <https://doi.org/10.1086/429921> PMID:15909264
- Forslöw U, Remberger M, Nordlander A, Mattsson J. The clinical importance of bronchoalveolar lavage in allogeneic SCT patients with pneumonia. *Bone Marrow Transplant.* 2010; 45(5):945-50. <https://doi.org/10.1038/bmt.2009.268> PMID:19784077
- Shannon VR, Andersson BS, Lei X, Champlin RE, Kontoyiannis DP. Utility of early versus late fiberoptic bronchoscopy in the evaluation of new pulmonary infiltrates following hematopoietic stem cell transplantation. *Bone Marrow Transplant.* 2010;45(4):647-55. <https://doi.org/10.1038/bmt.2009.203> PMID:19684637
- Hummel M, Rudert S, Hof H, Hehlmann R, Buchheidt D. Diagnostic yield of bronchoscopy with bronchoalveolar lavage in febrile patients with hematologic malignancies and pulmonary infiltrates. *Ann Hematol.* 2008;87(4):291-7. <https://doi.org/10.1007/s00277-007-0391-6> PMID:17932672
- Costa ADS Jr, Scordamaglio PR, Suzuki I, Palomino ALM, Jacomelli M. Indications, clinical outcomes and complications of 1,949 flexible bronchoscopies. *Einstein (Sao Paulo).* 2018;16(4):eAO4380 [https://doi.org/10.31744/einstein\\_journal/2018AO4380](https://doi.org/10.31744/einstein_journal/2018AO4380) PMID:30427487 PMCID:PMC6223942
- Elston WJ, Whittaker AJ, Khan LN, Flood-Page P, Ramsay C, Jeffery PK, Barnes NC. Safety of research bronchoscopy, biopsy and bronchoalveolar lavage in asthma. *Eur Respir J.* 2004;24(3):375-7. <https://doi.org/10.1183/09031936.04.00063003> PMID:15358694
- Hofmeister CC, Czerlanis C, Forsythe S, Stiff PJ. Retrospective utility of bronchoscopy after hematopoietic stem cell transplant. *Bone Marrow Transplant.* 2006;38:693-8. <https://doi.org/10.1038/sj.bmt.1705505> PMID:16980989
- Feinstein MB, Mokhtari M, Ferreira R, Stover DE, Jakubowski A. Fiberoptic bronchoscopy in allogeneic bone marrow transplantation: findings in the era of serum cytomegalovirus antigen surveillance. *Chest.* 2001;120:1094-100. <https://doi.org/10.1378/chest.120.4.1094> PMID:11591544
- Jain P, Sandur S, Meli Y, Arroliga AC, Stoller JK, Mehta AC. Role of flexible bronchoscopy in immunocompromised patients with lung infiltrates. *Chest.* 2004;125:712-22. <https://doi.org/10.1378/chest.125.2.712> PMID:14769756
- Common Terminology Criteria for Adverse Events (CTCAE) v4.03: June 14, 2010
- De Pauw B, Walsh TJ, Donnelly JP, Stevens DA, Edwards JE, Calandra T, Pappas PG, Maertens J, Lortholary O, Kauffman CA, Denning DW, Patterson TF, Maschmeyer G, Bille J, Dismukes WE, Herbrecht R, Hope WW, Kibbler CC, Kullberg BJ, Marr KA, Muñoz P, Odds FC, Perfect JR, Restrepo A, Ruhnke M, Segal BH, Sobel JD, Sorrell TC, Viscoli C, Wingard JR, Zaoutis T, Bennett JE; European Organization for Research and Treatment of Cancer/Invasive Fungal Infections

- Cooperative Group; National Institute of Allergy and Infectious Diseases Mycoses Study Group (EORTC/MSG) Consensus Group. Revised definitions of invasive fungal disease from the European Organization for Research and Treatment of Cancer/Invasive Fungal Infections Cooperative Group and the National Institute of Allergy and Infectious Diseases Mycoses Study Group (EORTC/MSG) Consensus Group. *Clin Infect Dis* 2008;46:1813-21.  
<https://doi.org/10.1086/588660>  
PMid:18462102 PMCID:PMC2671227
18. Tsitsikas DA, Morin A, Araf S, Murtagh B, Johnson G, Vinnicombe S, Ellis S, Suaris T, Wilks M, Doffman S, Agrawal SG. Impact of the revised (2008) EORTC/MSG definitions for invasive fungal disease on the rates of diagnosis of invasive aspergillosis. *Med Mycol*. 2012;50(5):538-42  
<https://doi.org/10.3109/13693786.2011.630040>  
PMid:22074309
  19. Du Rand IA, Blaikley J, Booton R, Chaudhuri N, Gupta V, Khalid S, Mandal S, Martin J, Mills J, Navani N, Rahman NM, Wrightson JM, Munavvar M; British Thoracic Society Bronchoscopy Guideline Group. British Thoracic Society guideline for diagnostic flexible bronchoscopy in adults: accredited by NICE. *Thorax*. 2013;68 Suppl1:i1-i44.  
<https://doi.org/10.1136/thoraxjnl-2013-203618>  
PMid:23860341
  20. Meyer KC, Raghu G, Baughman RP, Brown KK, Costabel U, du Bois RM, Drent M, Haslam PL, Kim DS, Nagai S, Rottoli P, Saltini C, Selman M, Strange C, Wood B; American Thoracic Society Committee on BAL in Interstitial Lung Disease. An official American Thoracic Society clinical practice guideline: the clinical utility of bronchoalveolar lavage cellular analysis in interstitial lung disease. *Am J Respir Crit Care Med*. 2012;185(9):1004-14.  
<https://doi.org/10.1164/rccm.201202-0320ST>  
PMid:22550210
  21. Wei Zhou, Hongxing Li, Yan Zhang, Huang M, He Q, Li P, Zhang F, Shi Y, Su X. Diagnostic Value of Galactomannan Antigen Test in Serum and Bronchoalveolar Lavage Fluid Samples from Patients with Non neutropenic Invasive Pulmonary Aspergillosis. *J Clin Microbiol*.2017;55(7):2153-2161.  
<https://doi.org/10.1128/JCM.00345-17>  
PMid:28446576 PMCID:PMC5483917
  22. Boersma WG, Erjavec Z, van der Werf TS, de Vries-Hosper HG, Gouw AS, Manson WL. Bronchoscopic diagnosis of pulmonary infiltrates in granulocytopenic patients with hematologic malignancies: BAL versus PSB and PBAL. *Respir Med*. 2007;101(2):317-25.  
<https://doi.org/10.1016/j.rmed.2006.04.021>  
PMid:16774815
  23. Guo YL, Chen YQ, Wang K, Qin SM, Wu C, Kong JL. Accuracy of BAL galactomannan in diagnosing invasive aspergillosis: a bivariate metaanalysis and systematic review. *Chest* 2010;138:817-24.  
<https://doi.org/10.1378/chest.10-0488>  
PMid:20453070
  24. Maertens J, Maertens V, Theunissen K, Meersseman W, Meersseman P, Meers S, Verbeken E, Verhoef G, Van Eldere J, Lagrou K.. Bronchoalveolar lavage fluid galactomannan for the diagnosis of invasive pulmonary aspergillosis in patients with hematologic diseases. *Clin Infect Dis*. 2009;49(11):1688-93  
<https://doi.org/10.1086/647935>  
PMid:19886801
  25. D'Haese J, Theunissen K, Vermeulen E, Schoemans H, De Vlieger G, Lammertijn L, Meersseman P, Meersseman W, Lagrou K, Maertens J. Detection of galactomannan in bronchoalveolar lavage fluid samples of patients at risk for invasive pulmonary aspergillosis: analytical and clinical validity. *J Clin Microbiol*. 2012;50(4):1258-63  
<https://doi.org/10.1086/647935>  
PMid:19886801
  26. Maertens JA, Klont R, Masson C, Theunissen K, Meersseman W, Lagrou K, Heinen C, Crépin B, Van Eldere J, Tabouret M, Donnelly JP, Verweij PE. Optimization of the cutoff value for the Aspergillus double-sandwich enzyme immunoassay. *Clin Infect Dis* 2007;44:1329-36.  
<https://doi.org/10.1086/514349>  
PMid:17443470
  27. Pagano L, Caira M, Candoni A, Offidani M, Martino B, Specchia G, Pastore D, Stanzani M, Cattaneo C, Fanci R, Caramatti C, Rossini F, Luppi M, Potenza L, Ferrara F, Mitra ME, Fadda RM, Invernizzi R, Aloisi T, Picardi M, Bonini A, Vacca A, Chierichini A, Melillo L, de Waure C, Fianchi L, Riva M, Leone G, Aversa F, Nosari A.. Invasive aspergillosis in patients with acute myeloid leukemia: a SEIFEM-2008 registry study. *Haematologica*. 2010;95(4):644-50.  
<https://doi.org/10.3324/haematol.2009.012054>  
PMid:19850903 PMCID:PMC2857195
  28. Nucci M, Nouér SA, Cappone D, Anaissie E. Early diagnosis of invasive pulmonary aspergillosis in hematologic patients: an opportunity to improve the outcome. *Haematologica*. 2013;98(11):1657-60.  
<https://doi.org/10.3324/haematol.2013.094359>  
PMid:24186309 PMCID:PMC3815162
  29. Maertens JA, Girmenia C, Brüggemann RJ, Duarte RF, Kibbler CC, Ljungman P, Racil Z, Ribaud P, Slavin MA, Cornely OA, Peter Donnelly J, Cordonnier C; European Conference on Infections in Leukaemia (ECIL), a joint venture of the European Group for Blood and Marrow Transplantation (EBMT), the European Organization for Research and Treatment of Cancer (EORTC), the Immunocompromised Host Society (ICHS) and; European Conference on Infections in Leukaemia (ECIL), a joint venture of the European Group for Blood and Marrow Transplantation (EBMT), the European Organization for Research and Treatment of Cancer (EORTC), the Immunocompromised Host Society (ICHS) and the European Leukemia Net (ELN). European guidelines for primary antifungal prophylaxis in adult haematology patients: summary of the updated recommendations from the European Conference on Infections in Leukaemia. *J Antimicrob Chemother*. 2018;73(12):3221-3230.  
<https://doi.org/10.1093/jac/dky286>
  30. McCulloch E, Ramage G, Rajendran R, Lappin DF, Jones B, Warn P, Shrief R, Kirkpatrick WR, Patterson TF, Williams C. Antifungal treatment affects the laboratory diagnosis of invasive aspergillosis. *J Clin Pathol*. 2012;65(1):83-6.  
<https://doi.org/10.1136/jcp.2011.090464>  
PMid:22049217
  31. Maccioni F, Vetere S, De Felici C, Al Ansari N, Micozzi A, Gentile G, Foà R, Girmenia C. Pulmonary fungal infections in patients with acute myeloid leukemia: is it the time to revise the radiological diagnostic criteria? *Mycoses*. 2016; 59(6): 357-64.  
<https://doi.org/10.1111/myc.12480>  
PMid:26865204
  32. Marchesi F, Cattaneo C, Criscuolo M, Delia M, Dargenio M, Del Principe MI, Spadea A, Fracchiolla NS, Melillo L, Perruccio K, Alati C, Russo D, Garzia M, Brociner M, Cefalo M, Armiento D, Cesaro S, Decembrino N, Mengarelli A, Tumbarello M, Busca A, Pagano L on behalf of the Sorveglianza Epidemiologica Infezioni nelle Emopatie (SEIFEM) Group. A bronchoalveolar lavage-driven antimicrobial treatment improves survival in hematologic malignancy patients with detected lung infiltrates: A prospective multicenter study of the SEIFEM group. *Am J Hematol*. 2019; 94(10): 1104-1112.  
<https://doi.org/10.1002/ajh.25585>  
PMid:31321791