

Case Report

Dentigerous Cyst Associated with a Mesiodens: A Case Report

Sepideh Vosough Hosseini¹ • Monir Moradzadeh² • Mehrdad Lotfi³ • Amir Ala Aghbali² • Shirin Fattahi^{4*}

¹Associate Professor, Department of Oral and Maxillofacial Pathology, Faculty of Dentistry, Tabriz University of Medical Sciences, Tabriz, Iran

²Assistant Professor, Department of Oral and Maxillofacial Pathology, Faculty of Dentistry, Tabriz University of Medical Sciences, Tabriz, Iran

³Associate Professor, Department of Endodontics, Faculty of Dentistry, Tabriz University of Medical Sciences, Tabriz, Iran

⁴Postgraduate Student, Department of Oral and Maxillofacial Pathology, Faculty of Dentistry, Tabriz University of Medical Sciences, Tabriz, Iran

*Corresponding Author; E-mail: Shirin_Fattahi@yahoo.com

Received: 22 February 2010; Accepted: 24 April 2011

J Dent Res Dent Clin Dent Prospects 2011; 5(2):76-78

This article is available from: <http://dentistry.tbzmed.ac.ir/joddd>

© 2011 The Authors; Tabriz University of Medical Sciences

This is an Open Access article distributed under the terms of the Creative Commons Attribution License (<http://creativecommons.org/licenses/by/3.0>), which permits unrestricted use, distribution, and reproduction in any medium, provided the original work is properly cited.

Abstract

Dentigerous cysts are the second most common odontogenic cysts after radicular cysts and are most commonly seen in association with third molars and maxillary canines. Only 5% of dentigerous cysts involve supernumerary teeth, of which mesiodens is the most frequent type. This paper presents a case of dentigerous cyst associated with a mesiodens that caused a painless swelling in the upper lip of an 18-year-old female. The patient was treated surgically by enucleation of total cyst and surgical extraction of mesiodens under local anesthesia.

Key words: Cholesterol cleft, dentigerous cyst, mesiodens, supernumerary tooth.

Introduction

Dentigerous or follicular cysts are the second most common type of odontogenic cysts, and the most common developmental cysts of the jaws.¹ The dentigerous cyst is defined as a cyst that originates by the separation of the follicle from around the crown of an unerupted tooth.² Dental follicle associated with unerupted or impacted teeth shows fibrous connective tissue with remnants of reduced enamel epithelium. Dentigerous cysts are caused by expansion of dental follicles resulting from accumulation of fluid between tooth crowns and epithelial components.³

This cyst most frequently occurs in patients between 10 and 30 years of ages and there is a greater incidence in males with a 1.6:1 ratio.^{1,2} The cysts most often involve impacted mandibular third molars, followed by maxillary canines, mandibular premolars, and occasionally supernumerary teeth or odontomas.^{2,4}

The clinical examination reveals a missing tooth or

teeth and occasionally a hard swelling, sometimes resulting in facial asymmetry and possible pathologic fracture. Dentigerous cysts are tentatively diagnosed on routine dental radiographs.⁵ Radiographically, the cyst appears as a unilocular radiolucent shadow with a well-defined sclerotic border associated with the crown of an unerupted tooth, but an infected cyst will show ill-defined borders.⁶

Only 5% of dentigerous cysts are associated with supernumerary teeth. The usual age of clinical presentation of dentigerous cyst due to supernumerary tooth is in the first four decades of life.⁷

Supernumerary teeth are most common in the maxilla with a strong predilection for the anterior region, in which case the supernumerary tooth is termed a mesiodens.^{1,2}

This paper presents a case of dentigerous cyst associated with a mesiodens in an 18-year-old female.

Case Report

An 18-year-old female patient presented to the De-

partment of Oral and Maxillofacial Surgery, Faculty of Dentistry at Tabriz University of Medical Sciences, Tabriz, Iran, with the chief complaint of a painless swelling in the upper jaw, which had been gradually increasing in size for the one year. At the time of her presenting, the patient had no systemic disease.

The intraoral clinical examination detected a firm labial and palatal swelling in the maxillary anterior region, on the both sides of the midline.

The panoramic radiograph showed a large, well-defined radiolucent lesion with sclerotic borders. The lesion extended from the right canine to the left lateral incisor region. A supernumerary tooth was visible in the left aspect of the cyst, resulting in resorption of cortical bone at this region. Divergence of the roots of the central incisors was also noted on the radiograph. The supernumerary tooth had a cone-shaped crown and a shortened root (Figure 1).

The lesion was totally enucleated together with the supernumerary tooth under local anesthesia, and specimens were sent to the Department of Oral and Maxillofacial Pathology, with the differential diagnoses of periapical cyst, odontogenic keratocyst, and adenomatoid odontogenic tumor. The submitted specimens consisted of two fragments of soft tissue, the largest measuring approximately 21 mm × 13 mm × 3 mm.

Histological sections of both specimens revealed cyst walls composed of loosely arranged fibrovascular connective tissue, lined by 2-4 layers of flattened non-keratinizing stratified squamous epithelium (Figure 2). The epithelium and the connective tissue interface was flat. Numerous cholesterol clefts and few chronic inflammatory cells infiltration were noted. No evidence of malignant changes was noted.

The clinical, radiographic and histopathological features led to the final diagnosis of dentigerous cyst associated with a mesiodens.

The patient was followed up for six months. The post-operative period was uneventful.

Discussion

Swelling of the upper lip may result from different conditions including infections, allergic diseases, neoplasms (especially of salivary origin), granulomatous diseases, and different types of cysts.⁸

Dentigerous cyst is a common oral lesion caused by fluid accumulation between the reduced enamel epithelium and the crown of an unerupted tooth.² Most reports have shown a peak incidence of dentigerous cysts in the second and third decades of life, with a slightly higher predilection for males. This

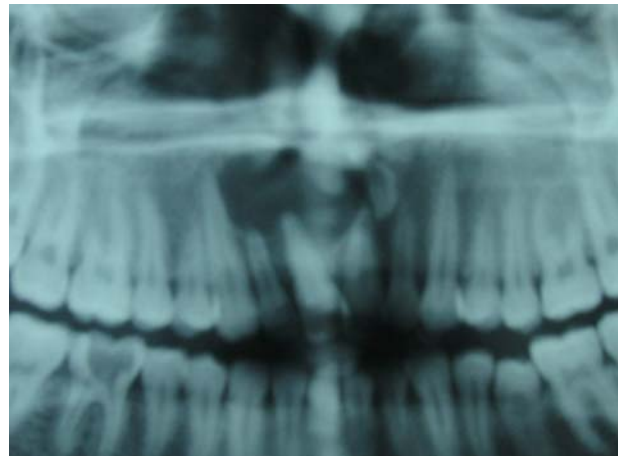


Figure 1. Panoramic radiograph shows a large unilocular radiolucency in the anterior maxilla and the mesiodens in the left aspect of the lesion.

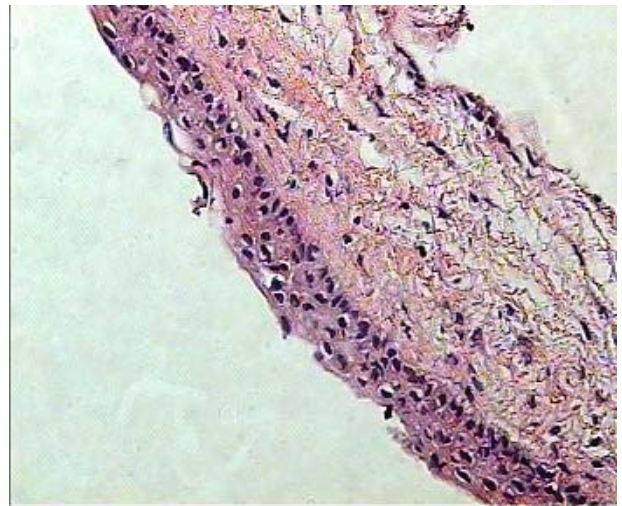


Figure 2. Photomicrograph showing cystic wall with non-keratinizing squamous epithelium (haematoxylin-eosin staining, ×20)

gender preference might be related to a smaller jaw size and a greater tendency for prophylactic extraction of third molars in females.⁹

A panoramic radiograph of a patient with dentigerous cyst reveals a unilocular radiolucency enclosing the crown of an unerupted tooth. The radiolucency usually arises in the cemento-enamel junction of the tooth.⁹ If a follicular space on the radiograph is more than 5 mm, an odontogenic cyst can be suspected. Differential diagnoses of such radiolucency include radicular cyst, odontogenic keratocyst, and odontogenic tumors such as ameloblastoma, Pindborg tumor, odontoma, odontogenic fibroma, and cementomas.¹⁰

Although dentigerous cyst is a common developmental cyst, its association with supernumerary teeth is rare and estimated to constitute 5-6% of all den-

tigerous cysts.⁴ First named by Bolk in 1917, mesiodens is the most frequent type of supernumerary teeth and situated in the maxillary anterior incisors region. It is a rare entity with a prevalence of 0.15-1.9% in general population and a slight male predilection.^{2,8,11} Mesiodens may be single or multiple, erupted or impacted and is rarely seen associated with a dentigerous cyst.¹² Scolozzi et al⁸ reported an unusual case of a large dentigerous cyst associated with an impacted mesiodens, resulting in a slow-growing swelling in the upper lip. Khan et al¹³ also described an upper lip swelling caused by a large dentigerous cyst associated with mesiodens. Dinkar et al¹⁴ described an unusually early presentation of multiple mesiodens with associated dentigerous cyst. Large dentigerous cysts arising from unerupted mesiodens should be kept in mind in the differential diagnosis of upper lip swellings, particularly if associated with dental anomalies of the maxillary incisors such as malposition and diastema.

Sharma et al¹⁵ reported the case of a dentigerous cyst associated with an impacted inverted mesiodens that developed secondary to trauma to its predecessor, a non-vital permanent maxillary central incisor. As a consequence of trauma, the central incisor's root development was prematurely arrested and the open apex lied close to the follicle of the underlying inverted mesiodens.

The presence of mesiodens causes complications such as delayed eruption of permanent teeth, rotations, retention, root resorption, pulp necrosis, and diastema as well as formation of dentigerous and primordial cysts.¹⁶

Therefore, to prevent the development of a dentigerous cyst and to avoid unwanted effects on neighboring teeth, early diagnosis and treatment of mesiodens are crucial.

References

1. Regezi AJ, Sciubba JJ, Jordan RCK. *Oral Pathology: Clinical-Pathologic Correlations*, 5th ed. St. Louis: Saunders; 2008:242-4.

2. Neville BW, Damm DD, Allen CM, Bouquot JE. *Oral and Maxillofacial Pathology*, 3rd ed. St. Louis: Saunders; 2008:679-81.
3. Edamatsu M, Kumamoto H, Ooya K, Echigo S. Apoptosis related factors in the epithelial components of dental follicles and dentigerous cysts associated with impacted third molars of the mandible. *Oral Surg Oral Med Oral Pathol Oral Radiol Endod* 2005;99:17-23.
4. Kumar N, Rama Devi M, Vanaki S, Puranik S. Dentigerous cyst occurring in maxilla associated with supernumerary tooth showing cholesterol clefts—a case report. *Int J Dent Clin* 2010;2:39-42.
5. McCrea S. Adjacent dentigerous cysts with the ectopic displacement of a third mandibular molar and supernumerary (forth) molar: a rare occurrence. *Oral Surg Oral Med Oral Pathol Oral Radiol Endod* 2009;107:e15-20.
6. Wood NK, Goaz PW. *Differential Diagnosis of Oral Lesions*, 5th ed. St. Louis: Mosby; 1997:283-8.
7. Grover SB, Singh P, Venkatachalam VP, Hekha N. Mesiodens presenting as a dentigerous cyst: case report. *Indian J Radiol Imaging* 2005;15:69-72.
8. Scolozzi P, Lombardi T, Richter M. Upper lip swelling caused by a large dentigerous cyst. *Eur Arch Otorhinolaryngol* 2005;262:246-9.
9. Zhang LL, Yang R, Zhang L, Li W, MacDonald-Jankowski D, Poh CF. Dentigerous cyst: a retrospective clinicopathological analysis of 2082 dentigerous cysts in British Columbia, Canada. *Int J Oral Maxillofac Surg* 2010;39:878-82.
10. Ustuner E, Fitoz S, Atasoy C, Erden I, Akyar S. Bilateral maxillary dentigerous cysts: a case report. *Oral Surg Oral Med Oral Pathol Oral Radiol Endod* 2003;95:632-5.
11. Montenegro P, Castellón E, Aytés L, Escoda C. Retrospective study of 145 supernumerary teeth. *Med Oral Patol Oral Cir Bucal* 2006;11:E339-44.
12. von Arx T. Anterior maxillary supernumerary teeth—A clinical and radiographic study. *Aust Dent J* 1992;37:189-95.
13. Khan MH, Alam MT, Haque S, Khan SH, Fatema CN, Tahsin T, et al. Upper lip swelling caused by a large dentigerous cyst with mesiodens. *Mymensingh Med J* 2008;17:S100-3.
14. Dinkar AD, Dawasaz AA, Shenoy S. Dentigerous cyst associated with multiple mesiodens: a case report. *J Indian Soc Pedod Prev Dent* 2007;25:56-9.
15. Sharma D, Garg S, Singh G, Swami S. Trauma-induced dentigerous cyst involving an inverted impacted mesiodens: case report. *Dent Traumatol* 2010;26:289-91.
16. Alacam A, Bani M. Mesiodens as a risk factor in treatment of trauma cases. *Dent Traumatol* 2009;25:e25-31.