

## Case Report

# TLE1 Positive Clear Cell Sarcoma of the Kidney: A Case Report and Review of the Literature

Rana Naous 

Department of Pathology, SUNY Upstate Medical University, 750 East Adams Street, Syracuse, NY 13210, USA

Correspondence should be addressed to Rana Naous; [naousr@upstate.edu](mailto:naousr@upstate.edu)

Received 1 June 2018; Accepted 4 October 2018; Published 16 October 2018

Academic Editor: Janina Kulka

Copyright © 2018 Rana Naous. This is an open access article distributed under the Creative Commons Attribution License, which permits unrestricted use, distribution, and reproduction in any medium, provided the original work is properly cited.

Clear cell sarcoma of the kidney (CCSK) is an uncommon malignant tumor of uncertain histogenesis that occurs most commonly in childhood. Histologically, CCSK can mimic myxoid variant of synovial sarcoma (SS); however, the double positivity for CD99 and TLE1 in SS helps in excluding CCSK. Herein, we report a rare case of CCSK arising in the left kidney of a 3-year-old girl. The mass grossly measured 9.5 cm in maximum dimension and histologically showed the classic arborizing fibrovascular septae and background myxoid matrix that is usually seen in CCSK. The tumor however was double positive for CD99 and TLE1 which made it difficult to discriminate it from the myxoid variant of SS based on histopathological examination and immunophenotype alone, and genetic analysis for SYT gene rearrangement was required to reach a definitive diagnosis. Although there have been previous case reports of CCSK with positive expression of CD99 and negative TLE1, to our knowledge, this is the first case of CCSK expressing both CD99 and TLE1.

## 1. Introduction

Clear cell sarcoma of the kidney (CCSK) is an uncommon malignant tumor of uncertain histogenesis that occurs most commonly in childhood [1]. Only rare cases have been reported in adults [2]. It represents 4-5% of primary renal neoplasms and is known for its aggressive behavior, tendency for recurrence, and metastasis to bone [3–6]. It is also the second most common pediatric renal tumor after Wilms' tumor [7, 8]. Histologically, CCSK can mimic myxoid variant of synovial sarcoma (SS); however, the double positivity for CD99 and TLE1 in SS helps in excluding CCSK. Herein, we report a rare case of CCSK with double positivity for CD99 and TLE1 whereby it was difficult to discriminate CCSK from the myxoid variant of SS based on histopathological examination and immunophenotype alone, and genetic analysis for SYT gene rearrangement was required to reach a definitive diagnosis. Although there have been previous case reports of CCSK with positive expression of CD99 and negative TLE1, to our knowledge, this is the first case of CCSK expressing both CD99 and TLE1.

## 2. Case Presentation

A 3-year-old girl presented to the emergency department with eye pain and was found to be hypertensive with a blood pressure measurement of 162/126. Further workup with renal ultrasound demonstrated a heterogeneous mass measuring 9.5 x 9.1 x 8.6 cm occupying the location of the left renal fossa. Surgical resection of the left renal mass revealed a 577.9 gram, 12.0 x 10.2 x 8.0 cm grossly distorted kidney with a 12.0 x 10.0 x 8.3 cm encapsulated, fleshy, pink-gray lesion which appeared grossly to have replaced the majority of the renal parenchyma. Microscopic examination revealed a cellular proliferation of neoplastic cells arranged haphazardly, in cords (Figure 1), occasional nests, and focally palisading (Figure 2) and separated by regularly spaced arborizing fibrovascular septa within an extracellular myxoid matrix (Figure 3) with occasional myxoid pool formation (Figure 4). Necrotic foci were noted focally within the tumor. Immunohistochemical stains were positive for vimentin (Figure 5), cyclin D1 (Figure 6), CD99 (Figure 7), TLE1 (Figure 8), and focally positive for Bcl-2 (Figure 9) in the tumor cells. SMA, desmin, CD34, cytokeratin AE1/AE3, EMA, WT-1,

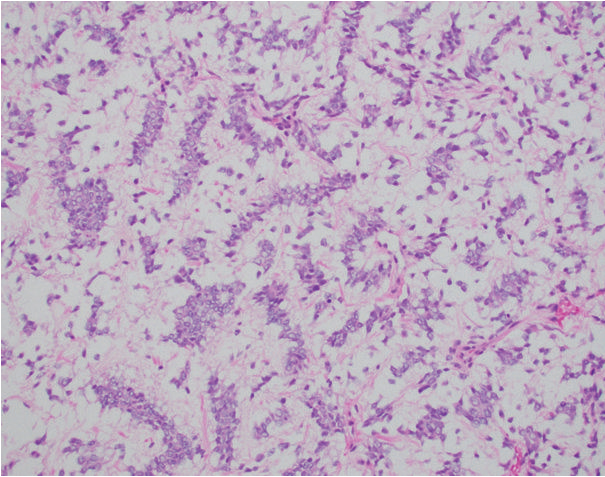


FIGURE 1: The neoplastic tumor cells are arranged in nests within a myxoid background (H&E, 200x).

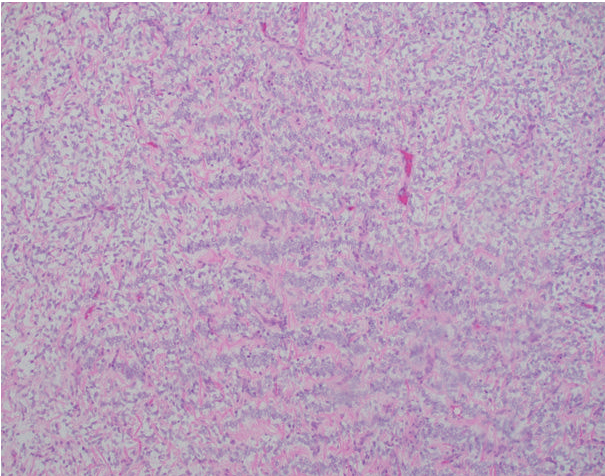


FIGURE 2: Focal areas with palisading are identified within the tumor (H&E, 100x).

myogenin, and S100 were negative. The overall morphology and immunopositivity for vimentin, Bcl-2, and cyclinD1 were suggestive of clear cell sarcoma of the kidney. However, given the histologic findings and the tumor immunopositivity for CD99 and TLE1, myxoid variant of synovial sarcoma entered the differential diagnosis. FISH for SYT gene rearrangement (Figure 10) was performed and was negative, ruling out a synovial sarcoma. The final diagnosis was clear cell sarcoma of the kidney, COG Stage III.

### 3. Discussion

Mirkovic et al. have demonstrated in their study that Cyclin D1 is a sensitive marker for CCSK [9, 10]. SATB2 [11], vimentin, and Bcl-2 are also well recognized immunostains that often label CCSK, while other immunomarkers such as TLE1, CD34, S100, desmin, CD99, and cytokeratin are often reported to be negative [12, 13]. Additionally, TLE1 immunostain had not been previously studied in CCSK.

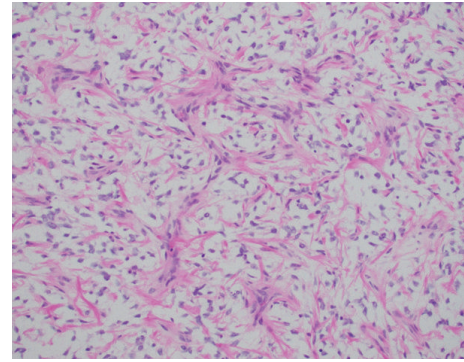


FIGURE 3: The arborizing fibrovascular septae classic of CCSK are easily seen (H&E, 200x).

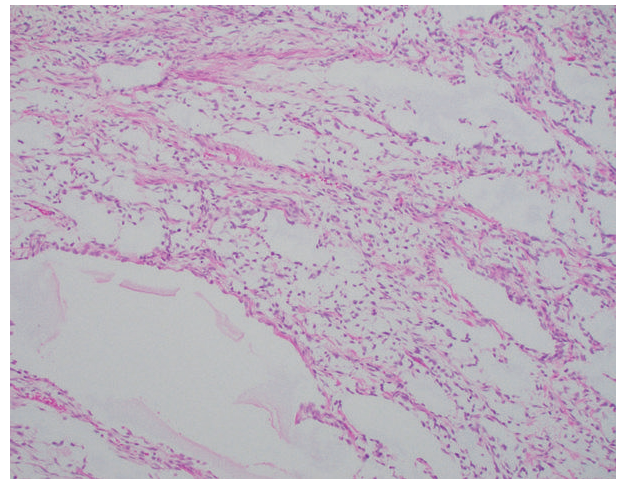


FIGURE 4: Myxoid pool formation is noted occasionally throughout the tumor (H&E, 200x).

A clinicopathologic study performed by He L. et al. [14] on 45 pediatric cases of CCSK showed the classic arborizing fibrovascular stroma in all the CCSK cases with variable myxoid, spindle, palisading, epithelioid, sclerosing, cellular, cystic, and angiectatic change. Immunohistochemically, all cases were positive for vimentin but negative for CD99, EMA, CK, desmin, actin, S-100, NSE, CD34, and LCA. TLE1 immunostain was not performed by the authors.

A review of 351 cases of CCSK from the National Wilms Tumor Study Group Pathology Center by Argani P. et al. [15] whereby immunohistochemical stains were performed on 45 out of the 351 cases showed that only vimentin was consistently immunoreactive in all the 45 CCSK cases, while CD99 was consistently negative and TLE1 immunostain was never performed.

It is well known that primary renal synovial sarcomas also express CD99, cyclin D1, and TLE1 which creates a potential overlap with CCSK in some cases. Usually, genetic analysis for SS18 -SSX gene fusions helps in resolving the differential diagnosis of CCSK and primary renal synovial sarcoma.

Hirose M. et al. [16] reported a case of CCSK that was positive for CD-99, vimentin, Bcl-2, and CD-56, and negative

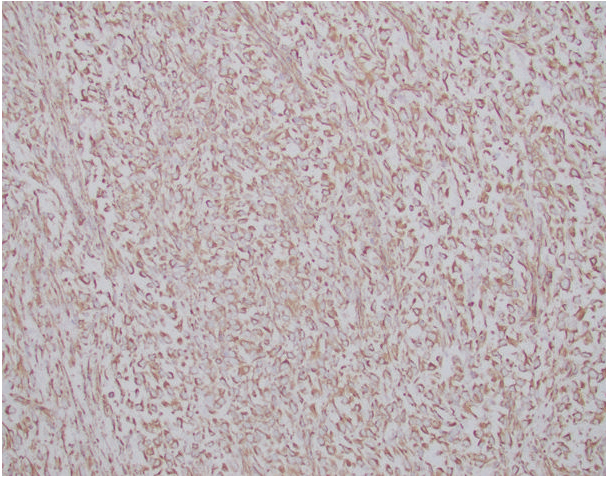


FIGURE 5: The tumor cells are strongly and diffusely positive for vimentin.

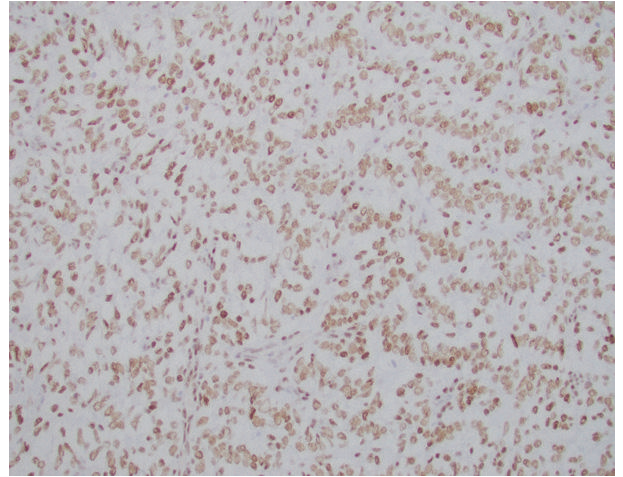


FIGURE 8: TLE1 has strong and diffuse nuclear positivity in the tumor cells.

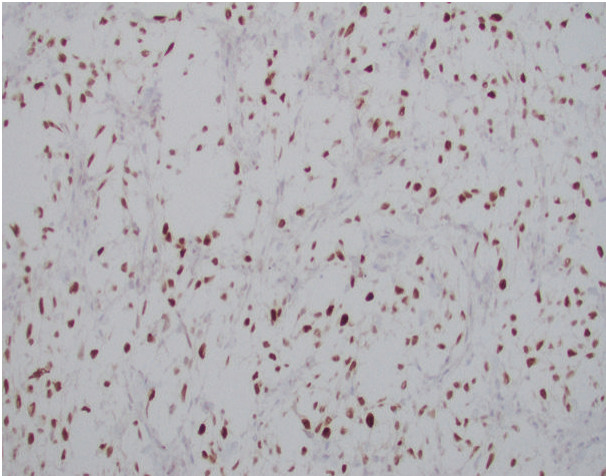


FIGURE 6: Positive nuclear staining for Cyclin D1 in the tumor cells.

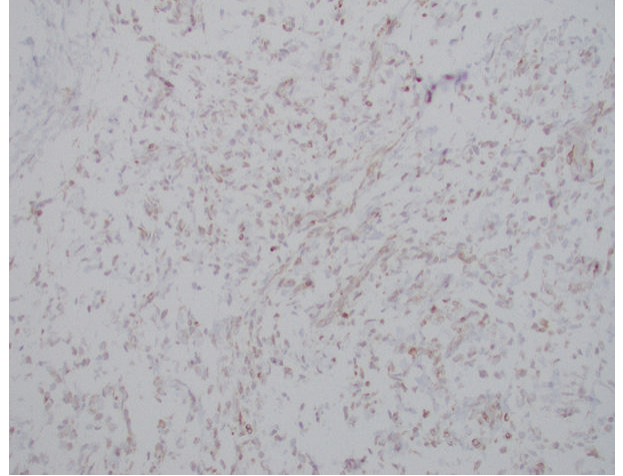


FIGURE 9: BCL-2 is highlighting focal areas within the tumor.

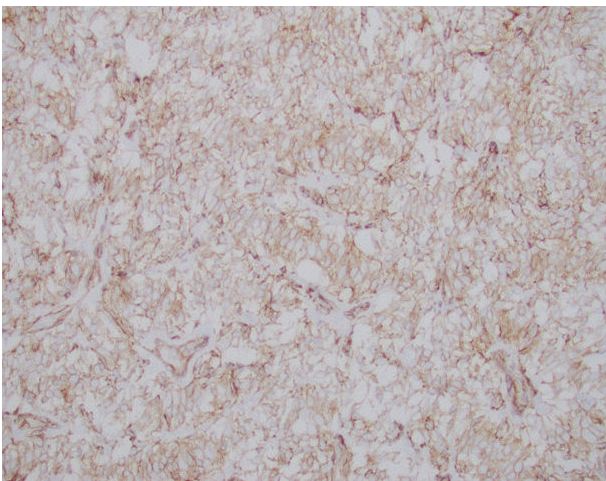


FIGURE 7: CD99 is diffusely and strongly staining the tumor cells in a membranous pattern.

for TLE1. Their differential diagnosis suggested CCSK or SSK; however, a final diagnosis of spindle cell pattern CCSK was made based on the absence of the SYT-SSX fusion gene by polymerase chain reaction.

At the genetic level, the majority of CCSKs have internal tandem duplications (ITDs) of the BCOR gene, whereas a minority has the YWHAE-NUTM2 or YWHAE-FAM22 [9] gene fusion, and a third category [17] comprises CCSKs with double negativity for BCOR ITDs, YWHAE-NUTM2, and YWHAE-FAM22 fusion.

Argani P. et al. [18] reported 2 primary renal sarcomas demonstrating BCOR-CCNB3 gene fusions with histologic overlap with CCSK and positive immunoreactivity for BCOR, cyclin D1, TLE1, and SATB2 in the neoplastic cells. They concluded that renal sarcomas with BCOR-CCNB3 gene fusion overlap with CCSK and are in keeping with a “BCOR alteration family” of renal and extrarenal neoplasms which includes CCSK and undifferentiated round cell sarcomas of

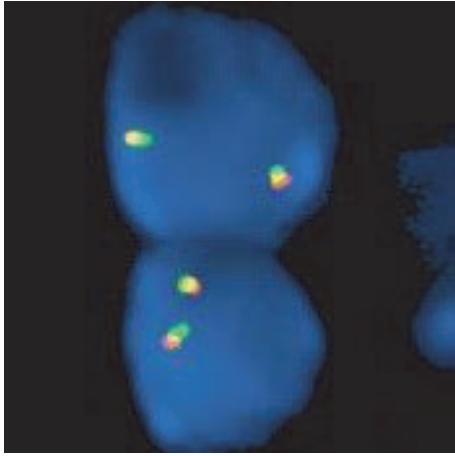


FIGURE 10: Absent *SSI8* (*SYT*) gene break-apart rearrangement on chromosome 18q11.2 by FISH (fluorescence in situ hybridization).

soft tissue and bone/soft tissue sarcomas with *BCOR-CCNB3* gene fusion, all of which are driven by *BCOR* overexpression and have overlapping clinicopathologic features. Although both cases in Argani's article were positive for *BCOR*, *TLE1*, cyclin D1, and *SATB2* immunostains, and *TLE1* was also positive in the typical CCSK in their control group, they were negative for *CD99*, desmin, cytokeratin, *S100*, and *CD34* in the tumor cells. This is in contrast to our case that labeled positive for both *CD99* and *TLE1*, and thus marking it as the first case of CCSK to have double positivity for these two markers.

*TLE1* or "transducin-like enhancer of split 1," is one of 4 *TLE* genes [19] that is located at chromosome 9q21.32 [20]. It is a transcriptional corepressor that affects signaling pathways and is also involved in modulating differentiation through inhibition of the Wnt / beta catenin signaling cascade [21].

*TLE1* was previously regarded as both highly sensitive and specific for synovial sarcoma with expected intense, diffuse nuclear staining in the tumor cells [22]. However, further studies have shown its positivity in many other nonsynovial sarcoma entities including endometrial stromal sarcoma which has been reported to manifest limited *TLE1* immunoreactivity [23]. *TLE1* immunoreactivity has also been demonstrated in soft tissue or bone sarcomas with *BCOR-CCNB3* gene fusion [24]. Given all that, we are uncertain of the mechanism behind the *TLE1* immunopositivity in our CCSK case; however, we postulate that the presence of the *YWHAE-FAM22* rearrangement, identical to that in endometrial stromal sarcoma, in a minority of CCSK cases [9] or the recent demonstration of *BCOR-CCNB3* gene fusions [18] in rare cases of CCSK may play a role in this finding.

In conclusion, we report a rare case of CCSK with double positivity for *CD99* and *TLE1* whereby it was difficult to discriminate CCSK from the myxoid variant of SS based on histopathological examination and immunophenotype alone, and genetic analysis for *SYT* gene rearrangement was required to reach a definitive diagnosis. Our case adds to the list of non-SS entities with *TLE1* immunopositivity and

emphasizes the role of genetic testing as a more specific method of diagnosis.

## Conflicts of Interest

The author declares that there are no conflicts of interest regarding the publication of this paper.

## References

- [1] P. A. Humphrey, T. M. Ulbright, and V. E. Reuter, *WHO Classification of Tumors of the Urinary System and Male Genital Organs*, IARC, Lyon, France, 4th edition, 2016.
- [2] A. R. Kural, B. Onal, H. Ozkara, C. Cakarir, I. Ayan, and F. Y. Agaoglu, "Adult clear cell sarcoma of the kidney: A case report," *BMC Urology*, vol. 6, 2006.
- [3] X. W. Xu, "Investigation of relationship between phlegm-dampness constitution and hyperlipidemia," *Modern Health Preservation*, vol. 4, p. 40, 2016.
- [4] R. Y. Namaoui, M. P. Castex, J. Vial et al., "Clear-cell sarcoma of the kidney: About a paediatric case," *Progrès en Urologie*, vol. 20, no. 6, pp. 465–468, 2010.
- [5] D. Nag, A. Nandi, P. Mandal, and P. Biswas, "Clear cell sarcoma of the kidney: A case report," *Journal of Cancer Research and Therapeutics*, vol. 10, no. 4, pp. 1104–1106, 2014.
- [6] S. L. M. Gooskens, R. Furtwängler, G. M. Vujanic, J. S. Dome, N. Graf, and M. M. Van Den Heuvel-Eibrink, "Clear cell sarcoma of the kidney: A review," *European Journal of Cancer*, vol. 48, no. 14, pp. 2219–2226, 2012.
- [7] C. Sotelo-Avila, F. Gonzalez-Crussi, S. Sadowinski, W. M. Gooch III, and R. Pena, "Clear cell sarcoma of the kidney: A clinicopathologic study of 21 patients with long-term follow-up evaluation," *Human Pathology*, vol. 16, no. 12, pp. 1219–1230, 1985.
- [8] C.-C. Huang, C. Cutcliffe, C. Coffin, P. H. B. Sorensen, J. B. Beckwith, and E. J. Perlman, "Classification of malignant pediatric renal tumors by gene expression," *Pediatric Blood & Cancer*, vol. 46, no. 7, pp. 728–738, 2006.
- [9] J. Mirkovic, M. Calicchio, C. D. Fletcher, and A. R. Perez-Atayde, "Diffuse and strong cyclin D1 immunoreactivity in clear cell sarcoma of the kidney," *Histopathology*, vol. 67, no. 3, pp. 306–312, 2015.
- [10] S. J. Aw, C. H. Kuick, M. H. Yong et al., "Novel karyotypes and cyclin D1 Immunoreactivity in clear cell sarcoma of the kidney," *Pediatric and Developmental Pathology*, vol. 18, no. 4, pp. 297–304, 2015.
- [11] Y.-C. Kao, Y.-S. Sung, L. Zhang et al., "BCOR overexpression is a highly sensitive marker in round cell sarcomas with BCOR genetic abnormalities," *The American Journal of Surgical Pathology*, vol. 40, no. 12, pp. 1670–1678, 2016.
- [12] N. J. Sebire and G. M. Vujanic, "Paediatric renal tumours: Recent developments, new entities and pathological features," *Histopathology*, vol. 54, no. 5, pp. 516–528, 2009.
- [13] F. S. Balarezo and V. V. Joshi, "Clear cell sarcoma of the pediatric kidney: Detailed description and analysis of variant histologic patterns of a tumor with many faces," *Advances in Anatomic Pathology*, vol. 8, no. 2, pp. 98–108, 2001.
- [14] L. He, L. Fu, L. Wang et al., "A clinicopathological study of clear cell sarcoma of the kidney," *Chinese Journal of Pathology*, vol. 30, no. 6, pp. 422–425, 2001.

- [15] P. Argani, E. J. Perlman, N. E. Breslow et al., "Clear cell sarcoma of the kidney: A review of 351 cases from the National Wilms Tumor Study Group pathology center," *The American Journal of Surgical Pathology*, vol. 24, no. 1, pp. 4–18, 2000.
- [16] M. Hirose, K. Mizuno, H. Kamisawa et al., "Clear cell sarcoma of the kidney distinguished from synovial sarcoma using genetic analysis: A case report," *BMC Research Notes*, vol. 8, article 129, 2015.
- [17] M. K. Wong, C. C. Ng, C. H. Kuick et al., "Clear cell sarcomas of the kidney are characterised by," *Histopathology*, vol. 72, no. 2, pp. 320–329, 2018.
- [18] P. Argani, Y. Kao, L. Zhang et al., "Primary renal sarcomas With BCOR-CCNB3 gene fusion," *The American Journal of Surgical Pathology*, vol. 41, no. 12, pp. 1702–1712, 2017.
- [19] B. Rekhi, R. Basak, S. B. Desai, and N. A. Jambhekar, "Immunohistochemical validation of TLE1, a novel marker, for synovial sarcomas," *Indian Journal of Medical Research*, vol. 136, no. 5, pp. 766–775, 2012.
- [20] A. L. Valente, J. Tull, and S. Zhang, "Specificity of TLE1 expression in unclassified high-grade sarcomas for the diagnosis of synovial sarcoma," *Applied Immunohistochemistry & Molecular Morphology*, vol. 21, no. 5, pp. 408–413, 2013.
- [21] J. Terry, T. Saito, and S. Subramanian, "TLE1 as a diagnostic for synovial from gene expression profiling studies," *The American Journal of Surgical Pathology*, vol. 31, no. 2, pp. 240–246, 2007.
- [22] A. Jagdis, B. P. Rubin, R. R. Tubbs, M. Pacheco, and T. O. Nielsen, "Prospective evaluation of TLE1 as a diagnostic immunohistochemical marker in synovial sarcoma," *The American Journal of Surgical Pathology*, vol. 33, no. 12, pp. 1743–1751, 2009.
- [23] K. Kosemehmetoglu, J. A. Vrana, and A. L. Folpe, "TLE1 expression is not specific for synovial sarcoma: A whole section study of 163 soft tissue and bone neoplasms," *Modern Pathology*, vol. 22, no. 7, pp. 872–878, 2009.
- [24] A. Matsuyama, E. Shiba, Y. Umekita et al., "Clinicopathologic diversity of undifferentiated sarcoma With BCOR-CCNB3 fusion," *The American Journal of Surgical Pathology*, vol. 41, no. 12, pp. 1713–1721, 2017.