

## Original Article

# Results and limits of posterior cranial vault expansion by osteotomy and internal distractors

Federico Di Rocco, Kenichi Usami, Tatiana Protzenko, Corinne Collet<sup>1</sup>, Kim Giraudat, Eric ArnaudCraniofacial Unit, Department of Pediatric Neurosurgery, Hôpital Necker-Enfants Malades, <sup>1</sup>Department of Biochemistry, Hôpital Lariboisière, APHP, Paris, FranceE-mail: \*Federico Di Rocco - [federicodirocco@gmail.com](mailto:federicodirocco@gmail.com); Kenichi Usami - [usaken-tyk@umin.ac.jp](mailto:usaken-tyk@umin.ac.jp); Tatiana Protzenko - [tatianaprotzenko@gmail.com](mailto:tatianaprotzenko@gmail.com); Corinne Collet - [corinne.collet@aphp.fr](mailto:corinne.collet@aphp.fr); Kim Giraudat - [kim.giraudat@aphp.fr](mailto:kim.giraudat@aphp.fr); Eric Arnaud - [eric.arnaud@aphp.fr](mailto:eric.arnaud@aphp.fr)

\*Corresponding author:

Received: 05 December 17 Accepted: 07 December 17 Published: 30 October 18

## Abstract

**Background:** Expanding the posterior cranial vault has become a common procedure in the treatment of complex craniosynostosis. Several techniques are available to remodel the posterior vault. Aim of this study was to analyze the posterior vault distraction osteogenesis.

**Methods:** Between 2011 and 2014, 21 children (12 boys) were operated on for a posterior distraction of the cranial vault. The mean age was 8.6 months (minimum, 3 months; maximum, 15 years). Thirteen patients presented a craniofacial syndrome. Five had already been operated on (two anterior cranial surgery, two suboccipital decompression, and one craniotomy for sagittal synostosis). Raised intracranial pressure (ICP) was present in 6 patients. Seven patients had symptomatic cerebellar tonsils herniation (TH).

**Results:** In 17 children, 2 lateral distractors were placed, in 3 a 3<sup>rd</sup> medial distractor was placed, and in 1 child 4 distractors were implanted. Volumetric analysis based on computed tomography showed a mean increase of volume of 13.9% 117 days later. After the distraction, symptoms related to raised ICP or TH were improved in all patients, however, radiologically TH was improved at the last follow-up in 54% of the cases.

**Conclusion:** Posterior cranial vault distraction is an efficacious technique to enlarge the posterior skull vault and treat increased ICP. Moreover, it appears to be efficacious in treating TH-related symptoms.

**Key Words:** Chiari, craniosynostosis, outcome, posterior cranial vault, skull remodeling, syndromic craniosynostosis

### Access this article online

**Website:**[www.surgicalneurologyint.com](http://www.surgicalneurologyint.com)**DOI:**

10.4103/sni.sni\_465\_17

**Quick Response Code:**

## INTRODUCTION

Distraction osteogenesis of the craniofacial skeleton has several applications in the treatment of craniofacial malformations.<sup>[1,8-10]</sup> Distraction osteosynthesis is based on gradual, controlled separation of bone fragments at a rate that allows for progressive bone formation in the distraction gap created by an osteotomy. The standard distraction protocol, originally introduced by Ilizarov

This is an open access journal, and articles are distributed under the terms of the Creative Commons Attribution-NonCommercial-ShareAlike 4.0 License, which allows others to remix, tweak, and build upon the work non-commercially, as long as appropriate credit is given and the new creations are licensed under the identical terms.

**For reprints contact:** [reprints@medknow.com](mailto:reprints@medknow.com)

**How to cite this article:** Rocco FD, Usami K, Protzenko T, Collet C, Giraudat K, Arnaud E. Results and limits of posterior cranial vault expansion by osteotomy and internal distractors. *Surg Neurol Int* 2018;9:217.

<http://surgicalneurologyint.com/Results-and-limits-of-posterior-cranial-vault-expansion-by-osteotomy-and-internal-distractors/>

for extension of tubal bones, entails a latency phase of 5–7 days, a 1-mm/day distraction rate, and consolidation periods of one to several months.<sup>[6]</sup> This technology has the potential to generate bone in areas of skeletal hypoplasia such as the mandible and middle face. Further, it has been demonstrated to achieve larger bone advancements and a reduced rate of relapse compared to conventional techniques based on one-stage, immediate advancement, and osteosynthesis.<sup>[18]</sup>

The use of distraction osteogenesis involving the cranial vault was originally described for the frontal calvarium as part of monobloc advancements.<sup>[4]</sup> It has since been introduced as a technique to expand the posterior cranial vault.<sup>[10,21]</sup>

The purpose of this study is to review the current surgical technique and results of posterior cranial vault distraction in patients with craniosynostosis.

## PATIENTS AND METHODS

### Patients

Children submitted to posterior cranial vault expansion with distractors at the Craniofacial Unit, Necker Enfants Malades Hospital, over the period between September 2011 and July 2014, were included.

### Surgical technique

The preoperative preparation, skin incision, and exposure of the skull were performed, as described in the previous article.<sup>[10]</sup> Two types of craniotomy were adopted – one was a supratentorial parieto-occipital craniotomy (supratentorial) and the other was an infratorcular craniotomy below the venous torcular (infratorcular), which were determined depending on the crowding of the posterior fossa, presence of tonsillar prolapse, preoperative assessment of the venous anatomy, and perioperative surgical findings. The osteotomy was performed with a motor drill or bone rongeur without elevating the cranial bone from the dura matter. Two to four distractors were applied depending on the age of the patient and the vector direction of the bone flap. If the patient had had a ventriculoperitoneal (VP) shunt implanted, the shunt was rerouted perioperatively. After surgery, the child was placed supine. Prolonged pressure of the skin over the distractors was avoided to reduce the risk of skin opening. The external part of the distractor was cut at the end of the skull expansion to avoid any risk of dislocation.

### Psychological assessment

The level of anxiety of the parents generated by posterior distraction osteogenesis was also evaluated. Specific questionnaires were designed to measure at different time points of the postoperative period through ordinal scales parental anxiety related to (1) the surgery itself,

(2) the use of the distractors and the distraction (the view of the latter, the ability to hold his child in the arms, the pain expressed by the child, etc.), (3) the return home and to school (the care of the scars, the way people look at the child, etc.), and (4) the morphological change (one week after surgery and few weeks after surgery). The questionnaires were given to the parents according to the date of surgery, and the answers were analyzed both quantitatively and qualitatively.

### Data analysis

#### *Volumetric analysis*

Intracranial volume was calculated from computed tomography (CT) using Volume Viewer 2 medical imaging software (G.E. Healthcare, U.S.A) before and after distraction.

#### *Evaluation of ossification*

The degree of ossification of the bone defect on the osteotomy line after cranial vault expansion was evaluated clinically and on the CT performed at the time of removal of distractors. We divided the circle of the osteotomy defect into 10 parts. When more than half of one part was filled by new bone, we considered it as ossified. Therefore, the degree of ossification was counted by 10%, ranging from 0 to 100 percent.<sup>[12]</sup> Patients were classified into four groups as follows: “Absent” consisted of patients with 0–25% ossification, “poor” 26–50%, “fair” 51–75%, and “good” 76–100%.

#### *Evaluation of tonsillar herniation*

Cerebellar tonsillar herniation (TH) was evaluated in all patients according to sagittal MRI images or reconstructed CT. Patients were diagnosed as TH when cerebellar TH was more than 5 mm through the foramen magnum. Clinical symptoms before and after distraction and at the latest follow-up were noted.

#### *Group classification*

Patients were classified according to their underlying syndrome and genetic condition. They were divided into three groups as follows – (1) Group “CAP,” patients with Crouzon syndrome, Apert syndrome, and Pfeiffer syndrome. (2) Group “Other syndromes,” patients with Saethre–Chötzen syndrome, Muenke syndrome, and craniofrontal nasal dysplasia (CFND). (3) Group “complex,” patients without any genetic mutation in *FGFRs*, *TWIST*, or *EFGN1*.

## RESULTS

### Patient population

A posterior vault distraction was originally intended in 22 cases. However, in a child with a *FGFR3*-related Crouzon with acanthosis nigricans, because of a severe bleeding from emissary veins during the osteotomy, distractors were not inserted. This child was not included

in the analysis. Thus, posterior distractors were implanted in a total of 21 patients.

Twelve of the patients were boys and 9 were girls. Signs of raised intracranial pressure were present in 6 patients. Distribution of age at surgery was from 3 months to 15 years; median age was 8.6 months. Two patients had a previous anterior craniotomy, 2 had suboccipital decompression for Chiari malformation, 1 had craniotomy for sagittal synostosis, and 16 patients had no previous craniotomy. Concerning the group 1, there were 7 patients (4 Crouzon, 2 Pfeiffer, and 1 Apert, syndrome), in group 2, 6 patients (3 Saethre-Chötzen syndrome, 2 Muenke syndrome, and 1 CFND), and in group 3, 8 patients. One patient of group “CAP” had a VP shunt implanted 12 years before occipital distraction that needed to be rerouted during surgery [Figure 1].

### Surgical procedure and complications

Thirteen of the 21 patients underwent supratentorial craniotomy and 8 infratentorial. The number of distractors was 2 in 17 patients, 3 in 3 patients, and 4 in 1 patient. One patient needed re-installation of distractors in the right side because of distractor malfunction. One patient needed to resuture the surgical wound 3 days after the ablation of distractors because of wound disruption. One patient had pneumonia postoperatively.

### Distraction

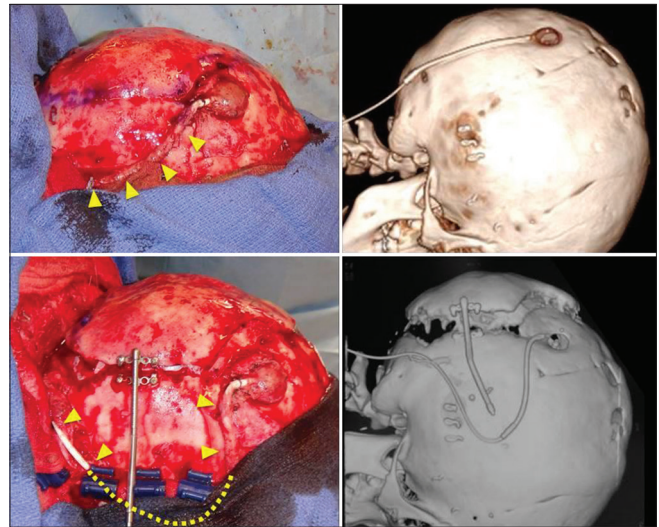
Distraction started 3 days after implantation, 0.5–1.0 mm a day for 10–15 days. Mean duration between installation and ablation of distractors was  $107 \pm 32$  days. Duration between installation of distractors and the CT evaluation was  $117 \pm 58$  days.

### Intracranial volume [Figure 2]

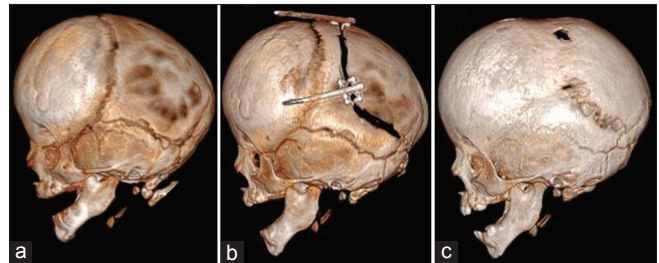
The increase in intracranial volume was  $132 \pm 86$  cc after distraction. The percentage of increase was  $13.9 \pm 11.9\%$ . The earlier the surgery was performed, the more the intracranial volume augmented. According to symptomatic groups, median value of augmentation was 9.8% in the group “CAP,” 9.1% in the group “Others,” and 13.5% in the group “complex.” There were no significant differences among these groups. Between supratentorial and infratentorial craniotomy, there was no significant difference but there was a tendency of better expansion in infratentorial craniotomy [Figure 3].

### Ossification

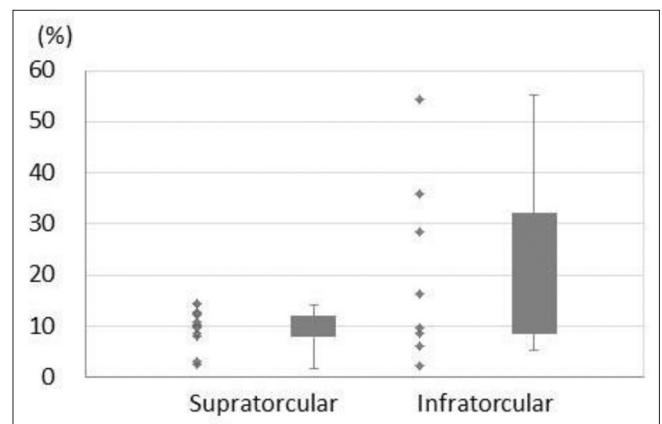
An accurate evaluation of ossification could not be done clinically. However, CT scan analysis allowed us to precisely divide patients into four groups as follows – “absent,” 8 patients (0–25% ossification), “poor” (26–50% ossification) 5 patients, “fair” (51–75% ossification) 5 patients, and “good” (76–100% ossification) 2 patients. The age at installation of distractors was 30.2 months in the group “absent,” 73.3 months in “poor,” 7.7 months in “fair,” and 21.8 in “good.” As



**Figure 1:** Rerouting the shunt tube (Yellow triangles and a dotted line indicate the route of shunt tube). Upper figures are before rerouting, and lowers are after rerouting

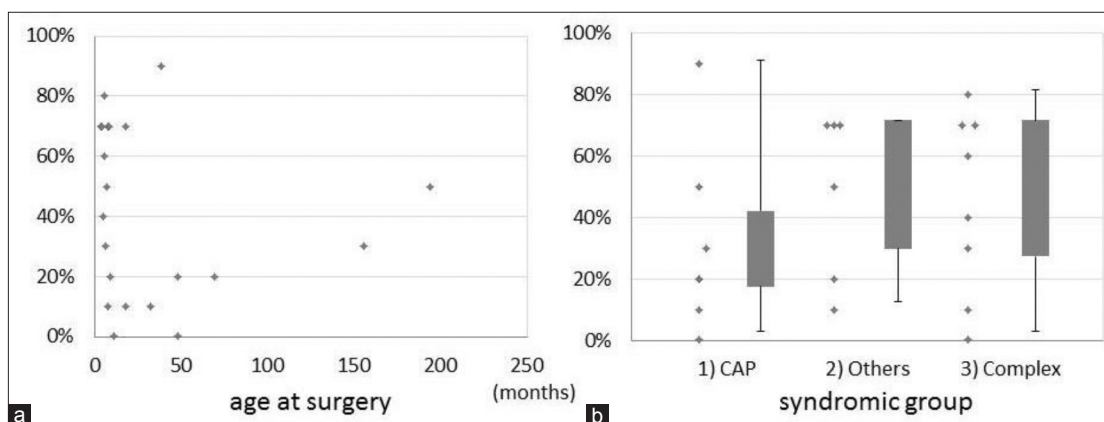


**Figure 2:** Typical images on 3-dimensional reconstruction CT preoperatively (a), immediately after implantation of distractors (b), and 6 months after implantation (c)

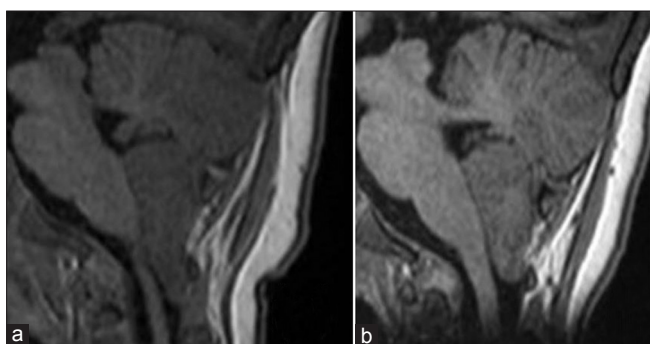


**Figure 3:** Augmentation of intracranial volume comparing between different craniotomies. The vertical axis indicates the percentage of augmentation of intracranial volume after the distraction

expected, there was a tendency to ossify more in longer duration from installation of distractors to CT evaluation. However, surprisingly, there was no significant correlation between ossification and age at distraction [Figure 4a]. According to symptomatic groups, median rate of ossification was 20% in “CAP,” 60% in “others,” and 50% in “complex.” This indicated that the group “CAP”



**Figure 4: Evaluation of ossification of the bone defect on the osteotomy line. The vertical axis indicates the degree of ossification in each image. (a) Correlation between the age at surgery and the degree of the ossification (b) Comparison among syndromic groups**



**Figure 5: Typical images of TH on MRI of T1-weighted image, preoperative (a) and 14 months after distraction (b)**

was less ossified than the other 2 groups [Figure 4b]. Patients who underwent supratentorial craniotomy were less ossified than patients who underwent infratentorial craniotomy (20% supratentorial vs. 60% infratentorial).

### Evolution of tonsillar herniation

Thirteen of 21 patients were diagnosed as TH preoperatively. Two of 13 patients with TH had already undergone posterior decompression prior to distraction, but in 1 of 2 patients, the symptom had recurred. Seven patients had some symptoms preoperatively as follows – sleep apnea in 4, headache in 2, papilloedema in 4, and paresthesia in 1. The average value of TH was 8.3 mm before distraction and 8.1 mm at first control after distraction [Figure 5]. Though there was no modification in the average measured TH, all patients were improved in their symptoms after distraction, regardless of their radiological change in TH [Table 1]. Nevertheless, at last follow-up, TH was reduced in 7 of 13 patients (54%). There was no significant difference between supratentorial and infratentorial craniotomy. Two children with TH (17%) also had a cervical syrinx, which improved in both cases after distraction.

### Psychological assessment

Eighteen parents agreed to answer the questionnaires. All parents, as expected, feared the surgical operation, the

distraction, and their return home with the child having the distractors implanted. All parents were pleased to see that the children did not suffer during distraction. At first, they were all surprised by the aspect of the distractors on the head of their children and they needed some time to get used to them. One-third were in the beginning uncomfortable in handling their child, but they were finally at ease with the distractors in a few days. All parents could appreciate the morphological change induced by the distraction osteogenesis, and the return home and to school went well in all cases.

The concerns reported by some of the parents were mainly due to their feeling of lack of information concerning the distraction devices; only one-third of the parents felt completely satisfied with the information given ahead of surgery. Few parents reported that they would have liked to have had further details on the characteristics of the distractors, to know the recommended sleeping positions, and to know children's reactions to distractors.

## DISCUSSION

Expansion of the posterior cranial vault was suggested to adequately increase the intracranial volume, avoid intracranial hypertension, and at the same time redirect the cerebral expansion posteriorly to prevent turricephaly.<sup>[21]</sup>

Initially practiced techniques for posterior cranial vault expansion were formal cranioplasty, with rearrangement and fixation of bone segments, either in the posterior aspect of the skull alone or as part of a combined anterior and posterior cranial vault expansion.<sup>[9,13,14,17]</sup> These techniques require complete separation of bone segments from the underlying dura mater, which is associated with risks for dural tears and hemorrhage from venous sinuses in the posterior cranial fossa. These risks have stimulated the development of less invasive techniques based on gradual posterior expansion without the need for extensive separation of bone segments from the dura mater. Sgouros

**Table 1: Evolution of symptoms and TH**

Pt. No.	Preoperative symptom	Result	TH pre OP (mm)	TH last f/u (mm)	Craniotomy
3	Central apnea	Apnea reduced	10.0	<b>7.8</b>	Supratorcular
4	Central apnea papilloedema	Apnea reduced no papilloedema	7.2	7.2	Infratorcular
5	Asymptomatic		8.0	8.0	Infratorcular
6	Asymptomatic		7.8	7.8	Supratorcular
8	Asymptomatic		6.0	<b>4.5</b>	Supratorcular
10	Central apnea	No central apnea	10.5	10.5	Infratorcular
14	Papilloedema	Asymptomatic	6.0	6.0	Supratorcular
16	Headache, papilloedema	Headache reduced no papilloedema	8.0	<b>7.0</b>	Supratorcular
18	Mild apnea, papilloedema	Asymptomatic	7.5	<b>6.0</b>	Supratorcular
19	Asymptomatic		5.5	<b>3.5</b>	Supratorcular
20	Asymptomatic		6.0	6.0	Infratorcular
21	Asymptomatic		15	<b>7</b>	Supratorcular
22	Occipital headache, paresthesia	Asymptomatic	11.0	<b>10.0</b>	Supratorcular

Bold and italic letters indicates the patients whose TH was reduced at the last follow-up

*et al.* described the free-floating occipital release.<sup>[10]</sup> Subsequently, springs and internal distractors have been used for gradual expansion of the posterior cranial vault.<sup>[5,21]</sup>

Several techniques are available nowadays including<sup>[10]</sup> free-floating bone flap, fixed elevated bone flap without hardware, translambdaoid springs, nonelevated bone flap, and hardware (spring or distractors).

The use of distraction osteogenesis involving the cranial vault was first described for the monobloc advancements,<sup>[4]</sup> and was subsequently used to expand other regions of the cranial vault.<sup>[2]</sup>

White *et al.* first described posterior cranial expansion with internal distractors in 2009.<sup>[8]</sup> Since then, other groups have confirmed the feasibility of this technique.<sup>[11,16,19]</sup>

Compared to springs, internal distractors share some risks of device-related complications.<sup>[10,18,22,23]</sup> (i) device loosening or breakdown and (ii) injury of the underlying dura mater by pins or screws. However, they also carry a potential infective risk due to the percutaneous components of the distractor. Because of the need of the osteotomy, they are associated to a greater hemorrhagic risk than translambdaoid springs. Nevertheless, the morbidity of internal distractors was limited in our series to 1 child in whom the bleeding was severe, and distractors were finally not implanted and a free bone flap was performed.

Compared to translambdaoid springs the distractor techniques allow obtaining a good control of the vectors depending on their placement and design of the craniotomy. The design of the craniotomy will decide the size of the bone flap and consequently affect the gain in intracranial volume as well as the change in posterior cranial shape. As for springs, there is a risk of hardware dislocation or dysfunction. Such complication occurred in one of our children leading to reoperation.

Though in the original description of this procedure the horizontal craniotomy was placed below the level of the torcula,<sup>[21]</sup> because of the risk for bleeding from venous sinuses in the posterior cranial fossa, we performed craniotomies above the torcula, as described by other authors<sup>[16,19,21]</sup> in 13 cases. The comparison of these two types of craniotomy shows differences in terms of size of bone flap as expected as well as in terms of volumetric gain but no significant differences in term of clinical or radiological efficacy.

The number of distractors used for posterior cranial vault expansion has varied from 2 to 4.<sup>[11,16,19,21]</sup> White *et al.* used 3 distractors in their case series, however, the authors discussed a modification of their protocol, reinforcing the distraction construct by adding a 4<sup>th</sup> distractor, with the aim of enhancing the stability of the distraction construct and thereby reducing the rate of device-related complications.<sup>[21]</sup> However, use of multiple distractors is costly and increases the complexity of both distractor placement and removal. Indeed, the use of multiple distractors may increase the risk for introducing conflicting distraction vectors. Moreover, it could be argued that the risk for dural tears, infections, and other device-related complications would increase with the number of pins placed. In most cases, 2 distractors were sufficient to allow good expansion. We used a medial third when a caudal translation of the bone flap was also necessary to correct the shape of the skull vault. However, independent of the number of distractors used, in our series, no case of dural tear with CSF collection was found. The implantation of the third distractor on the midline over the sagittal suture resulted in a slightly more difficult procedure at the time of removal related to its relationship with the underlying superior sagittal sinus, but without increased morbidity.

## Cerebral tonsils' prolapse and posterior fossa crowding

Posterior cranial vault expansion has the potential to relieve any local compression on the brain in the posterior cranial fossa. In patients with progressive hydrocephalus, decompression of the subtentorial compartment should theoretically enhance CSF flow in the compressed cerebral aqueduct. Cinalli *et al.* reported that, in their experience, occipital remodelling and suboccipital decompression may fail to sufficiently restore normal CSF circulation.<sup>[3]</sup> Others reported improved CSF flow after cranial vault expanding procedures.<sup>[7,20]</sup> In our experience, posterior distraction resulted in the resolution of clinical symptomatology during the immediate postoperative period already within the first days of distraction even in cases where the osteotomy line remained over the torcula. Radiological evidence of syrinx regression and/or cerebellar tonsils' upward displacement was also found but only in 17% of children, though the number of patients is too little to draw definitive conclusions.

## Indications and timing

Posterior cranial vault expansion is indicated in infants with syndromic and nonsyndromic craniosynostosis with a posterior flatness of the skull. In fact, though the posterior cranial flatness is usually less severe in nonsyndromic patients compared to complex multiple suture synostosis, bicoronal synostosis is still associated with an increased risk for raised intracranial pressure.<sup>[15]</sup> Thus, the strategy of first expanding the posterior cranial vault, before performing a fronto-orbital advancement at a later stage, is also a valid option for this group of patients.<sup>[10]</sup>

The procedure should be done early enough to prevent negative effects on brain development and further progression towards brachy-turricephaly. In most cases, a correction of the frontal region will be needed at a later stage.

Conversely, posterior expansion can also be used in old children, already operated on for the frontal region, who present with recurrent raised ICP or symptoms related to the posterior fossa crowding and descent of cerebellar tonsils. Because of the age of the patient and the limited effect that could be anticipated, we used internal distractors in old children. Though translambdaoid springs are not used in our institution in children over 18 months, we can assume, by extrapolation of the volumetric effect according to age, that such springs cannot achieve an increase in volume as important as internal distractors. With this latter technique, we could obtain a resolution of the symptomatology (either raised ICP or brainstem compression) in all children of our series independent of age.

## CONCLUSION

Surgical procedures aiming to expand the posterior cranial vault may be considered both in nonsyndromic

and syndromic forms of bicoronal synostosis. Posterior cranial vault expansion offers large increase in intracranial volume, which may be needed to prevent intracranial hypertension in such patients. Further, by expanding the posterior cranial vault, local compression of the brain in the posterior cranial fossa may be relieved and progression of cranial dysmorphology towards turricephaly may be prevented. Moreover, an effect on the prolapse of the tonsils can be observed in some patients.

## Financial support and sponsorship

Nil.

## Conflicts of interest

There are no conflicts of interest.

## REFERENCES

1. Arnaud E, Di Rocco F. Faciocraniosynostosis: Monobloc frontofacial osteotomy replacing the two-stage strategy? *Childs Nerv Syst* 2012;28:1557-64.
2. Choi JW, Ra YS, Hong SH, Kim H, Shin HW, Chung IW, *et al.* Use of distraction osteogenesis to change endocranial morphology in unilateral coronal craniosynostosis patients. *Plast Reconstr Surg* 2010;126:995-1004.
3. Cinalli G, Chumas P, Arnaud E, Sainte-Rose C, Renier D. Occipital remodeling and suboccipital decompression in severe craniosynostosis associated with tonsillar herniation. *Neurosurgery* 1998;42:66-71; discussion 71-63.
4. Cohen SR, Boydston W, Hudgins R, Burstein FD. Monobloc and facial bipartition distraction with internal devices. *J Craniofac Surg* 1999;10:244-51.
5. Davis C, MacFarlane MR, Wickremesekera A. Occipital expansion without osteotomies in Apert syndrome. *Childs Nerv Syst* 2010;26:1543-8.
6. Ilizarov GA. Clinical application of the tension-stress effect for limb lengthening. *Clin Orthop Relat Res* 1990;8:26.
7. Levitt MR, Niazi TN, Hopper RA, Ellenbogen RG, Ojemann JG. Resolution of syndromic craniosynostosis-associated Chiari malformation Type I without suboccipital decompression after posterior cranial vault release. *J Neurosurg Pediatr* 2012;9:111-5.
8. McCarthy JG, Schreiber J, Karp N, Thorne CH, Grayson BH. Lengthening the human mandible by gradual distraction. *Plast Reconstr Surg* 1992;89:1-8; discussion 9-10.
9. Mofid MM, Manson PN, Robertson BC, Tufaro AP, Elias JJ, Vander Kolk CA. Craniofacial distraction osteogenesis: A review of 3278 cases. *Plast Reconstr Surg* 2001;108:1103-14; discussion 1115-1107.
10. Nowinski D, Di Rocco F, Renier D, SainteRose C, Leikola J, Arnaud E. Posterior cranial vault expansion in the treatment of craniosynostosis. Comparison of current techniques. *Childs Nerv Syst* 2012;28:1537-44.
11. Nowinski D, Saiepour D, Leikola J, Messo E, Nilsson P, Enblad P. Posterior cranial vault expansion performed with rapid distraction and time-reduced consolidation in infants with syndromic craniosynostosis. *Childs Nerv Syst* 2011;27:1999-2003.
12. Oyama A, Arnaud E, Marchac D, Renier D. Reossification of cranium and zygomatic arch after monobloc frontofacial distraction advancement for syndromic craniosynostosis. *J Craniofac Surg* 2009;20(Suppl 2):1905-9.
13. Persing JA, Jane JA, Delashaw JB. Treatment of bilateral coronal synostosis in infancy: A holistic approach. *J Neurosurg* 1990;72:171-5.
14. Pollack IF, Losken HW, Hurwitz DJ. A combined frontoorbital and occipital advancement technique for use in total calvarial reconstruction. *J Neurosurg* 1996;84:424-9.
15. Renier D, Lajeunie E, Arnaud E, Marchac D. Management of craniosynostoses. *Childs Nerv Syst* 2000;16:645-58.
16. Serlo WS, Ylikontiola LP, Lahdesluoma N, Lappalainen OP, Korpi J, Verkasalo J, *et al.* Posterior cranial vault distraction osteogenesis in craniosynostosis: Estimated increases in intracranial volume. *Childs Nerv Syst* 2011;27:627-33.
17. Sgouros S, Goldin JH, Hockley AD, Wake MJ. Posterior skull surgery in craniosynostosis. *Childs Nerv Syst* 1996;12:727-33.
18. Shetye PR, Davidson EH, Sorkin M, Grayson BH, McCarthy JG. Evaluation of

- three surgical techniques for advancement of the midface in growing children with syndromic craniosynostosis. *Plast Reconstr Surg* 2010;126:982-94.
19. Steinbacher DM, Skirpan J, Puchala J, Bartlett SP. Expansion of the posterior cranial vault using distraction osteogenesis. *Plast Reconstr Surg* 2011;127:792-801.
  20. Strahle J, Muraszko KM, Buchman SR, Kapurch J, Garton HJ, Maher CO. Chiari malformation associated with craniosynostosis. *Neurosurg Focus* 2011;31:E2.
  21. White N, Evans M, Dover MS, Noons P, Solanki G, Nishikawa H. Posterior calvarial vault expansion using distraction osteogenesis. *Childs Nerv Syst* 2009;25:231-6.
  22. Yonehara Y, Hirabayashi S, Sugawara Y, Sakurai A, Harii K. Complications associated with gradual cranial vault distraction osteogenesis for the treatment of craniofacial synostosis. *J Craniofac Surg* 2003;14:526-8.
  23. Yu JC, Fearon J, Havlik RJ, Buchman SR, Polley JW. Distraction Osteogenesis of the Craniofacial Skeleton. *Plast Reconstr Surg* 2004;114:1E-20E.