

Received: 2010.11.10
Accepted: 2011.02.06
Published: 2011.08.01

Authors' Contribution:

- A** Study Design
- B** Data Collection
- C** Statistical Analysis
- D** Data Interpretation
- E** Manuscript Preparation
- F** Literature Search
- G** Funds Collection

Effectiveness of nucleoplasty applied for chronic radicular pain

**Haktan Karaman^{1ABCDEF}, Adnan Tüfek^{2BCDE}, Gönül Ölmez Kavak^{2DEF},
 Zeynep Baysal Yildirim^{2DEF}, Vildan Temel^{3GD}, Feyzi Çelik^{2DE},
 Mehmet Salim Akdemir^{2BG}, Sedat Kaya^{4AG}**

¹ Department of Anesthesiology, Pain Management Center, Dicle University, Diyarbakir, Turkey

² Department of Anesthesiology, Dicle University, Diyarbakir, Turkey

³ Department of Anesthesiology, State Hospital of Gynecology and Obstetrics, Diyarbakir, Turkey

⁴ Department of Anesthesiology, Diyarbakir Training and Research Hospital, Diyarbakir, Turkey

Source of support: Departmental sources

Summary

Background:

Over the last several decades there has been a general trend toward reduction and minimalization in surgical treatment of chronic back pain, since open surgery brings complications in small and contained disc herniations instead of achieving expected success. Attention has been focussed on percutaneous nucleoplasty due to the limited success of other minimally invasive methods, as well due to their associated complications. However, there have been few studies in the English literature with a follow-up period of more than 1 year.

Material/Methods:

Patients with chronic disc herniations having more significant radicular leg pain, who did not respond to non-invasive treatment methods and for whom open surgery was not an option were selected for percutaneous nucleoplasty application. Upon intervention, patients were prospectively questioned by an independent physician regarding pain, physical improvement, and operation satisfaction at 1, 6, 12 and 24 months. Pain was evaluated with VAS, and physical improvement was evaluated based on the Oswestry Disability Index.

Results:

Mean VAS that was 8.7 ± 1.1 before the procedure was determined to be 3.4 ± 1.9 at 24 months follow-up. At the latest follow-up, 87.5% of the patients reported a 30% or higher decrease in their pain. While Oswestry scores were 76.1 ± 10.2 in the beginning, they went down to 33.9 ± 14.9 at the end of 2 years. The percent of those stating "good" and "excellent" satisfaction was 66% (23 persons) on the last follow-up.

Conclusions:

While it is once more shown that nucleoplasty is a safe method, it is also shown that its effectiveness continues at the end of 2 years.

key words:

percutaneous nucleoplasty • chronic back pain • radiculopathy • disc decompression

Full-text PDF:

<http://www.medscimonit.com/fulltxt.php?ICID=881908>

Word count:

3118

Tables:

2

Figures:

2

References:

40

Author's address:

Haktan Karaman, Department of Anesthesiology, Pain Management Center, Dicle University, A.D. 21280 Diyarbakir, Turkey, e-mail: haktan72@yahoo.com

BACKGROUND

Low back pain, which causes severe morbidity in society, is one of the primary reasons for contacting a doctor [1,2]. In industrialized societies, 80% of individuals experience an attack of low back pain at least once in their lifetime [3–5]. While most of these attacks get better with moderate rest, medical treatment, and exercise, 10% become chronic [6,7]. Low back pain which becomes chronic is an important health problem that creates a heavy economic burden, as it causes workforce loss along with high treatment expenses [8]. Accordingly, health professionals make serious efforts to solve this issue.

Even though there are several areas in the lumbar region which might cause pain, one of the most common causes of pain is a herniated intervertebral disc that compresses nerve roots and causes the pain [9]. Even though the actual reason is not known, it is believed that mechanical and inflammatory mechanisms play a role in the situation [10]. Mixer and Barr [11] described the relationship between disc herniation and sciatica clearly in their article published in 1934. Successful results recorded in conventional discectomy applied through the open surgery method also confirmed this relationship. Unfortunately, along with its success, several complications have been reported for the open surgery method [12–16]. Complications include recurrent herniation, failed back surgery syndrome that results in epidural fibrosis, general problems such as prolonged hospital stay, complications related to general anesthesia, and infections. In 1987, Williams reported in his study publishing microdiscectomy series that clinically successful results are independent of the disc material removed [7]. Carragee et al [17] stated that the success ratio in small, unfragmented contained disc herniations with open surgery is lower when compared to large, fragmented uncontained disc herniations. Successful results were observed to be independent of the amount of removed disc material, which directed researchers to minimally invasive methods such as percutaneous disc decompression [10,18]. Peul et al showed no difference after 1 year between microdiscectomy and conservative management [19].

Percutaneous disc decompression methods rely on the principle that small amounts removed from the disc will result in disproportionately significant relief in the intradiscal pressure [18]. Therefore, pressure on the nerve will be removed and radicular leg pain will be eliminated [3,18,20]. Percutaneous disc decompression methods, such as chemonucleolysis, manual disc decompression, automatic disc decompression and laser discectomy, have aroused interest for the last 40 years and have seriously evolved. Implementation of these methods was limited since some of them are cumbersome, expensive, and require full equipment, along with having inconsistent results and various complications [21–23].

Percutaneous nucleoplasty (PN) is a method in which disc decompression is provided through controlled evaporation of nucleus pulposus using radiofrequency energy [24]. It is supposed that the mechanism of clinical efficacy of the PN procedure is that PN alters the expression of inflammatory cytokines such as IL-3, which may be related to the mechanisms of pain relief and repair response within the disc [25,26]. The most important advantage of this method

is its ease, short application period, relatively lower cost, and safety. Although PN is commonly applied, few studies have demonstrated the long-term efficiency of this method.

The purpose of this prospective study with 2-year follow-up was to prove the hypothesis that PN is effective in relieving pain in patients with chronic radicular pain. There are a few studies with a follow-up period of more than 1 year in the English literature.

MATERIAL AND METHODS

Design and participants

Upon obtaining Institutional Review Board approval, the study was conducted with outpatients in the Pain Center of the University Hospital between June 2005 and December 2008. After all patients were informed orally and in writing on the PN application and the study, their written consent for accepting the application and participating in the study was obtained. The study design was prospective, non-controlled and non-randomized, with a 2-year follow-up period. Patients' inclusion and exclusion criteria were determined mainly according to the instructions by Sharps and Isaac [7].

The following were used as the patients inclusion criteria: 1) age younger than 60 years, accepting PN practice and study participation; 2) had lumbar disc hernia with mostly single-side leg pain; 3) not responding to non-invasive conservative treatment methods such as medical treatment, rest, physical therapy applied at least for 6 weeks within the last 6 months; 4) preserved disc height of more than 70%; and 5) having single-level herniation smaller than 6 mm, and smaller than one-third of the sagittal radius of the spinal canal in MR imaging (MRI) taken within the last 6 months.

The following were the exclusion criteria: 1) patients not giving consent to take part in the study and the intervention; 2) having back pain more than leg pain; 3) having previous open surgery or percutaneous intervention on PN planned level; 4) having more than 1 herniation with different levels; 5) having uncontained extruded or sequestered herniations larger than 6 mm in MRI; 6) having tumor, spondylolisthesis and spinal instability; and 7) presence of general contraindications preventing invasive process application, such as bleeding diathesis, known allergy history for materials used, psychological disorder, or systemic infection or local infection in the intervention area.

Procedure

All procedures were performed by local anesthesia with C-arm fluoroscopy guidance. After single-dose 1 gr cefazolin sodium was given intravenously as prophylactic, patients were laid on the fluoroscopy table in the prone position under standard monitorization. After placing a pillow under the stomach in order to straighten lumbar lordosis, the intervention area was cleaned with iodine antiseptic solution and draped in accordance with sterility rules. The target point was reached by putting the C-arm in the oblique position. After vertebral end-plates were drawn in 1 line, the target disc was penetrated with a 17 G 6-inch Crawford type introducer needle (ArthroCare, Sunnyvale, CA, USA). Through anterior-posterior and lateral imaging,

Table 1. Demographic characteristics of patients.

Age (years)	Mean \pm SD	40 \pm 10.7
	Range	18–59
Gender	Total	56
	Female N(%)	30 (53.6%)
	Male N(%)	26 (46.4%)
Duration of pain (months)	Mean \pm SD	14.6 \pm 8.5
	Range	6–36
Side	Right N(%)	22 (39.3%)
	Left N(%)	34 (60.7%)
Treated levels	L1-L2 N(%)	1 (1.8%)
	L2-L3 N(%)	3 (5.4%)
	L3-L4 N(%)	9 (16.1%)
	L4-L5 N(%)	33 (58.9%)
	L5-S1 N(%)	10 (17.8%)

SD – standard deviation.

the needle tip was kept at the junction of the annulus fibrosus and nucleus pulposus. Then, the Perc-DLE SpineWand (ArthroCare, Sunnyvale, CA, USA) was placed into the introducer needle, and advanced until the inner surface of the annulus was on the opposite side. The process was completed by creating a total of 6 channels at the 12, 2, 4, 6, 8, and 10 o'clock positions through ablation-coagulation in the nucleus with circular movements. Patients were sent to the recovery room after the operation, where they would stay for 4 hours. Patients who were evaluated only in terms of early complications at this stage were then discharged with recommendations. In the postoperative period the patients were permitted to walk, sit and stand without restriction, and to return to light to moderate work 3 or 4 days later. Patients were asked not to carry more than 4 kilograms for 2 weeks. They were told that they could also start gentle stretching exercises at home 2 weeks later.

Outcome measures

Patients were asked questions by an independent doctor, who did not take part in the study, about their pain, physical functional status and patient satisfaction in the preoperative period and postoperatively at 1, 6, 12 and 24 months. While pain was evaluated through VAS (visual analog scale, with 0 being no pain and 10 being the most severe pain), physical condition was evaluated in accordance with the Oswestry Disability Index (ODI) [27]. Patient satisfaction was graded as the following: 1 – not satisfied 2 – average, 3 – good, and 4 – excellent. Furthermore, information on age, sex, herniation level and side, and duration of pain were collected for analysis.

A positive post-therapeutic outcome for the patient was defined as a reduction in the pre-operative VAS and ODI scores of at least 30%.

Statistical analysis

All data were analyzed using the statistical package SPSS version 15.0 for Windows and Medcalc Version 10.3.0.0 for Windows. Repeated Measurements ANOVA parametric test for repeated measurements was used to evaluate the improvements in VAS and ODI scores both before and after the procedure. When the Repeated Measurements ANOVA test showed a statistical difference, we used a paired samples t-test with Bonferonni's correction to perform pairwise comparisons. We used the independent t-test to study the effects of sex and side of body treated on the outcomes, and used the correlation and regression analysis to analyze correlation between changes in VAS scores and duration of pain and between changes in VAS scores and age. $P<0.05$ was considered statistically significant in all analyses. The data were expressed as mean \pm standard deviation.

RESULTS

Patient characteristics

A total of 56 patients were treated consecutively with PN. Two of these patients did not benefit from nucleoplasty despite technically successful procedures, and 1 of these patients was taken into open microdiscectomy after follow-up on the 6th month. The other patient was taken into the same operation after follow-up on the 12th month. Four out of 56 patients were lost from the study during the follow-up period. One of these patients was lost at the 6th month after PN, 1 after the 12th month, and another 2 were lost to follow-up after the 24th month. The average age was 40 \pm 10.7 years (range 18–59), and 30 patients (53.6%) were female. In all patients, leg pain was stronger than back pain. The average pain period was 14.6 \pm 8.5 months (range 6–36), and decompression was mostly applied at the L4-L5 level (58.9%). Demographic data are given in Table 1.

Leg pain severity

The mean VAS score of the patients before the operation was 8.7 \pm 1.1, and decreased to 3.5 \pm 1.7 at 1 month ($P<0.001$). VAS scores at 6, 12 and 24 months were 4.7 \pm 1.9 ($P<0.001$), 4.6 \pm 1.7 ($P<0.001$), and 3.4 \pm 1.9 ($P<0.001$), respectively (Figure 1 and Table 2). At 24 months 87.5% of patients reported pain relief greater than 30% (Figure 2). We calculated the percentage of improvement in VAS from baseline to 2 years as 60.9%. Factors such as age ($P=0.501$), sex ($P=0.526$), and side ($P=0.839$) did not have significant effect on VAS at 24 months, but a negative correlation was observed with the duration of pain (correlation coefficient $r=-0.4741$, $P=0.0005$). Furthermore, we found a positive correlation among patients in the decreases in VAS and ODI scores in the 24th month compared to the baseline period (correlation coefficient $r=0.9088$, $P<0.0001$).

Physical function

Improvement in physical function was evaluated with the ODI. The average initial score was 76.1 \pm 10.2, and it was determined to be 34.1 \pm 14.8 at the first control after the procedure ($P<0.001$). Average ODI scores were 40.8 \pm 15.2 ($P<0.001$), 41.4 \pm 13.5 ($P<0.001$), and 33.9 \pm 14.9 ($P<0.001$) at 6, 12, and 24 months, respectively (Figure 1 and Table

Table 2. Pairwise comparisons of VAS and ODI scores.

	Factors	Mean difference	Std. Error	P*	95% CI*
VAS _{baseline}	– VAS _{1 month}	5.2	0.2	<0.0001	4.8–5.6
	– VAS _{6 months}	4.0	0.2	<0.0001	3.5–4.5
	– VAS _{12 months}	4.1	0.3	<0.0001	3.5–4.6
	– VAS _{24 months}	5.4	0.3	<0.0001	4.8–6.0
ODI _{baseline}	– ODI _{1 month}	42.0	15.7	<0.0001	37.8–46.2
	– ODI _{6 months}	35.6	15.6	<0.0001	31.4–39.8
	– ODI _{12 months}	35.1	16.7	<0.0001	30.5–39.7
	– ODI _{24 months}	43.4	18.0	<0.0001	38.3–48.5

* Bonferroni corrected. VAS – visual analog scale; ODI – oswestry disability index.

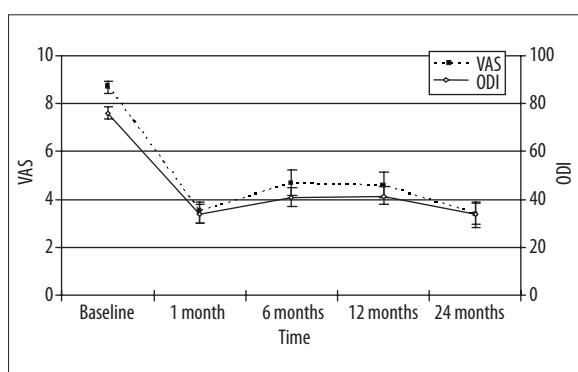


Figure 1. Changes in mean VAS and ODI scores during follow-up periods. VAS, visual analog scale; ODI, oswestry disability index. * Statistically significant decrease for VAS and ODI.

2). The percentages of patients reporting greater than 30% improvement in ODI scores were 82.1% at 24 months (Figure 2). We calculated the percentage of improvement for ODI from baseline to 2 years as 55.4%. When the follow-up at 24 months was taken as a reference, 48 out of 56 patients (85.7%) had improvement in their physical function when compared to the baseline value.

Patient satisfaction

When patient satisfaction levels were examined in accordance with the 4-point patient satisfaction scale, the percent of those stating “good” and “excellent” was 66% (23 persons) at the last follow-up.

Complications

All applications were successfully implemented without any difficulties. No early or late complications such as discitis, nerve damage, or bleeding caused by PN applications were observed in the patients.

DISCUSSION

One of the most important structures that cause back pain is the intervertebral discs located between the 2 vertebral corpes. Intervertebral discs, which play an important role

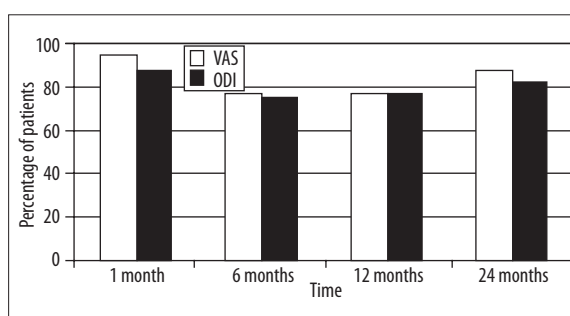


Figure 2. A graph showing percentage of patients reporting ≥30% decrease in VAS and ODI scores at 1, 6, 12 and 24 months follow-up. VAS, visual analog scale; ODI, oswestry disability index.

in carrying the load on the low back mechanically, are made up of 2 parts. The outer part with a thick structure is called the annulus fibrosus, and the inner part of the structure with gel consistency is called the nucleus pulposus. The nucleus pulposus, responsible for carrying 72% of the axial load on the disc, is comprised of 70–90% water. Here, the most important support is the proteoglycan in the nucleus pulposus [1]. Durability of the intervertebral disc depends on the fluid exchange and balance of proteoglycan synthesis and breakdown in the matrix. When these components decrease, axial load is transferred to the annulus fibrosus and posterior elements of the vertebra. Accordingly, annulus fissures and herniations are inevitable in this situation [28].

Herniations may be in the form of bulging, protrusion, extrusion and sequestration. While open surgery is the best option for extrusion and sequestration, it has been observed that open surgery is not a good option for contained protrusions [17]. When complications that develop due to open surgery have been taken into consideration, the general trend has been toward reductionism and minimalism in spinal surgery. Many factors play a role, such as the surgeon’s desire to decrease operation-related complications, the patient’s awareness about new treatment methods, and the development of new technologies [29].

All percutaneous decompression techniques are based on the principle that a small volume decrease in the disc, which

is a closed area, will result in great pressure decrease in the disc. Percutaneous disc decompression methods were first used in 1963 with the chemonucleolysis developed by Smith. In this method, chymopapain, which is a proteolytic enzyme, is percutaneously injected into the disc, and the nucleus melts in an enzymatic fashion. Unfortunately, severe complications were revealed for chemonucleolysis, the success rate of which was initially shown to be around 80% through double-blind, randomized studies. Anaphylactic shock, and paresis and plegia that develop due to uncontrolled distribution of the enzyme given to the spinal cord, dural sac and spinal roots, are the most important complications. This method has been abandoned, since the damage caused outweighs the benefit [7,18,21,30].

Percutaneous discectomy was performed by Hijikata for the first time in 1975. This method, with a 68% reported success rate, was followed by percutaneous automatic lumbar discectomy developed by Onik and Maron in 1984; however, this latter application was not in demand due to its high cost and cumbersome equipment [7,29,31].

Discectomy through disc laser application was first used by Choy in 1987, and 75% successful results were reported. However, it has several disadvantages such as costly equipment, inability to visualize the tip of the light beam under fluoroscopy, possibility of spinal damage, severe intraoperative pain, and postoperative low back pain and spasm [7,21,31].

The PN method introduced in year 2000 is a relatively new method, in which a volume decrease is provided through evaporation depending on molecular degradation in the disc by using radiofrequency energy. Through this application, which is defined as controlled ablation (coblation), only 1 ml volume reduction in the disc occurs [32]. Tissue removed through conventional methods actually also results in a slight downgrade in disc bulging, yet it results in height loss in the disc and triggers disc degeneration, whereas removing only a small part from the disc via PN prevents the development of progressive disc degeneration [10]. Studies conducted on pig cadavers reveal that PN does not cause a clear thermal injury in surrounding annulus fibrosus, vertebral end plates, and spinal cord or nerve roots [33]. In 2007; however, it was reported to develop epidural fibrosis following nucleoplasty [34]. Another study conducted on human cadavers demonstrated that lethal thermal damage might develop outside the nucleus pulposus due to misplacement of the radio frequency probe [35], but other studies showed that PN was safe, with very little complication risk [33–36].

In many studies [7,10,18,21,28,31] researchers have investigated the impact of PN on discogenic pain, whether or not accompanied by radicular pain. A critical question that needs to be addressed at this point is for what type of back pain PN would provide an effective treatment. A systematic review, published in 2009, illustrated Level II-3 evidence for PN in treatment of leg pain. However, this review also demonstrated that there was no evidence available for PN in managing axial low back pain [37]. Mirzai et al. [38] supported the same opinion and asserted that open surgery in discogenic pain would be a better option.

PN application causes nearly 1 ml volume loss in nucleus pulposus due to tissue destruction, collagen denaturation and

contraction. It is believed that regression develops in bulging and protrusion due to the abovementioned volume loss. Yet a study published by Calisanelier et al. [39] in 2007 demonstrated that no change, positive or negative, was shown in MRIs repeated 24 hours after the PN. However, Masala et al. [31] emphasized that improvement was recorded in parallel with clinical recovery in 80% of control MRIs repeated 1 year after PN.

Patients with isolated discogenic back pain not accompanied by radicular leg pain were excluded from the study. We believe that PN is more effective in radicular pain, therefore only patients with disc herniations accompanying radicular pain were included to the study. Patients over 60 years of age were not included in our study since old age causes vulnerability for disc degeneration, and could decrease the possibility of benefiting from PN. Because of our strict exclusion and inclusion criteria, the average VAS scores of our patients dropped from 8.7 ± 1.1 to 3.4 ± 1.9 at 24 months. Furthermore, the ratio of our patients reporting $\geq 30\%$ decrease in their pain was 87.5% at the latest follow-up. Statistically significant results were also recorded in ODI scores used to evaluate physical recovery. While the average ODI score of our patients before the procedure was 76.1 ± 10.2 , it dropped to 33.9 ± 14.9 at the end of 2 years. During the last control 48 out of 56 patients (85.7%) recorded improvement in their physical functions when compared to the initial values.

In a study comparing percutaneous endoscopic laser discectomy (PELD) with chemonucleolysis (CN) and automated percutaneous lumbar discectomy (APLD), 300 patients were followed postoperatively for 1 year, with physical examination, postoperative plain lumbosacral radiography, CT, MRI and a self-assessment questionnaire. Of the patients in the PELD group, 68% of considered the outcome as excellent or good and 23% as fair; the corresponding figures were 55% and 27% in the CN group, and 48% and 32% in the APLD group. Nine percent of the patients in the PELD group underwent open microdiscectomy or were suffering from back pain with sciatica, compared with 18% in the CN group and 20% in the APLD group. In our study, the percentage of patients stating “good” and “excellent” was 66% (23 persons) on the last follow-up [40]. PN may be as effective as PELD, but more than CN and APLD. Future studies should aim to compare the long-term results of different percutaneous decompression methods, including PN.

Limitations of this study include that it was not RCT, it included a relatively small number of patients, and the latest follow-up was not conducted with a control MRI. However, we believe that it is an advantage for this study to have a long follow-up period.

CONCLUSIONS

PN is a safe method and its effectiveness continues at the end of 2 years. At the same time, more RCTs are warranted.

REFERENCES:

1. Singh V: Intradiscal Electrothermal Therapy: A Preliminary Report. *Pain Physician*, 2000; 3: 367–73
2. Akdag B, Cavlak U, Cimbiz A, Camdeviren H: Determination of pain intensity risk factors among school children with nonspecific low back pain. *Med Sci Monit*, 2011; 17(2): PH12–15

3. Long MD: Decision making in lumbar disc disease. *Clin Neurosurg*, 1992; 39: 36-51
4. Olmarker K, Rydebik B: Pathophysiology of sciatica. *Orthop Clin North Am*, 1991; 22: 223-34
5. Kirkald-Willis WH: Pathology and pathogenesis of the low back pain. In: Bernard T Jr (ed) *Managing low back pain*, 4th edn. Churchill Livingstone, Philadelphia, 1999; 65-95
6. Nachemson AL: Newest knowledge of low back pain: A critical look. *Clin Orthop*, 1992; 279: 8-20
7. Sharps LS, Isaac Z: Percutaneous disc decompression using nucleoplasty. *Pain Physician*, 2002; 5: 121-26
8. Luo X, Pietrobon R, Sun SX et al: Estimates and patterns of direct health care expenditures among individuals with back pain in the United States. *Spine*, 2004; 29: 79-86
9. Kuslich SD, Ulstrom CL, Michael CJ: The tissue origin of low back pain and sciatica: a report of pain response to tissue stimulation during operations on the lumbar spine using local anaesthesia. *Orthop Clin North Am*, 1991; 22: 181-87
10. Al-Zain F, Lemcke J, Killeen T et al: Minimally invasive spinal surgery using nucleoplasty: a 1-year follow-up study. *Acta Neurochir*, 2008; 150: 1257-62
11. Mixter WJ, Barr JS: Rupture of the intervertebral disc with involvement of the spinal canal. *New Engl J Med*, 1934; 211: 210-15
12. Connolly ES: Surgery for recurrent lumbar disc herniation. *Clin Neurosurg*, 1992; 39: 211-16
13. North RB, Campbell JN, James CS et al: Failed back surgery syndrome: 5-year follow-up in 102 patients undergoing repeated operation. *Neurosurgery*, 1991; 28: 685-91
14. Ramirez LF, Thisted R: Complications and demographic characteristics of patients undergoing lumbar discectomy in community hospitals. *Neurosurgery*, 1989; 25: 226-31
15. Stolte D, Sollmann WP, Seifert V: Intra- and postoperative complications in lumbar disc surgery. *Spine*, 1989; 14: 56-59
16. Yorimitsu YE, Chiba K, Yoyama Y, Hirabayashi K: Long-term outcomes of standard discectomy for lumbar disc herniation: a follow-up study of more than 10 years. *Spine*, 2001; 26: 652-57
17. Carragee EJ, Han MY, Suen PW, Kim D: Clinical outcomes after lumbar discectomy for sciatica: the effects of fragment type and anular competence. *J Bone Joint Surg Am*, 2003; 85-A: 102-8
18. Singh V, Piriyani C, Liao K, Nieschulz S: Percutaneous Disc Decompression Using Coblation (Nucleoplasty™) in the Treatment of Chronic Discogenic Pain. *Pain Physician*, 2002; 5: 250-59
19. Peul WC, Arts MP, Brand R, Koes BW: Timing of surgery for sciatica: subgroup analysis alongside a randomized trial. *Eur Spine J*, 2009; 18: 538-45
20. Singh V, Derby R: Percutaneous lumbar disc decompression. *Pain Physician*, 2006; 9: 139-46
21. Yakovlev A, Tamimi MA, Liang H, Eristavi M: Outcomes of percutaneous disc decompression utilising nucleoplasty for the treatment of chronic discogenic pain. *Pain Physician*, 2007; 10: 319-28
22. Sherk HH, Black JD, Prodoehl JA, Cummings RS: Laser diskectomy. *Orthopedics* 1993; 16: 573-76
23. Birnbaum K: Percutaneous cervical disc decompression. *Surg Radiol Anat*, 2009; 31: 379-87
24. Puenteadura EJ, Brooksby CL, Wallmann HW, Landers MR: Rehabilitation following lumbosacral percutaneous nucleoplasty: a case report. *Orthop Sports Phys Ther*, 2010; 40: 214-24
25. Bokov A, Skorodumov A, Isrelov A et al: Differential treatment of nerve root compression pain caused by lumbar disc herniation applying nucleoplasty. *Pain Physician*, 2010; 13: 469-80
26. O'Neill CW, Liu JJ, Leibenberg E et al: Percutaneous plasma decompression alters cytokine expression in injured porcine intervertebral discs. *Spine J*, 2004; 4: 88-98
27. Feise RJ, Menke JM: Functional Rating Index: literature review. *Med Sci Monit*, 2010; 16(2): RA25-36
28. Singh V, Piriyani C, Liao K: Evaluation of Percutaneous Disc Decompression Using Coblation in Chronic Back Pain With or Without Leg Pain. *Pain Physician*, 2003; 6: 273-80
29. Gerszten PC, Welch WC, King JT Jr: Quality of life assessment in patients undergoing nucleoplasty-based percutaneous discectomy. *J Neurosurg Spine*, 2006; 4: 36-42
30. Brown MD: Update on chemonucleolysis. *Spine*, 1996; 21(24 Suppl.): 62S-68S
31. Masala S, Massari F, Fabiano S et al: Nucleoplasty in the Treatment of Lumbar Diskogenic Back Pain: One Year Follow-Up. *Cardiovasc Intervent Radiol*, 2007; 30: 426-32
32. Chou R, Atlas SJ, Stanos SP, Rosenquist RW: Nonsurgical interventional therapies for low back pain: a review of the evidence for an American Pain Society clinical practice guideline. *Spine*, 2009; 34: 1078-93
33. Chen YC, Lee SH, Saenz Y, Lehman NL: Histologic findings of disc, end plate and neural elements after coblation of nucleus pulposus: an experimental nucleoplasty study. *Spine J*, 2003; 3: 466-70
34. Smuck M, Benny B, Han A, Levin J: Epidural fibrosis following percutaneous disc decompression with coblation technology. *Pain Physician*, 2007; 10: 691-96
35. Nau WH, Diederich CJ: Evaluation of temperature distributions in cadaveric lumbar spine during nucleoplasty. *Phys Med Biol*, 2004; 21; 49: 1583-94
36. Yan D, Li J, Zhu H et al: Percutaneous cervical nucleoplasty and percutaneous cervical discectomy treatments of the contained cervical disc herniation. *Arch Orthop Trauma Surg*, 2010; 130: 1371-76
37. Manchikanti L, Derby R, Benyamin RM et al: A Systematic Review of Mechanical Lumbar Disc Decompression with Nucleoplasty. *Pain Physician*, 2009; 12: 561-72
38. Mirzai H, Tekin I, Yaman O, Bursali A: The results of nucleoplasty in patients with lumbar herniated disc: a prospective clinical study of 52 consecutive patients. *Spine J*, 2007; 7: 88-92
39. Calisaneller T, Ozdemir O, Karadeli E, Altinors N: Six months post-operative clinical and 24 hour post-operative MRI examinations after nucleoplasty with radiofrequency energy. *Acta Neurochir*, 2007; 149: 495-500
40. Lee SH, Lee SJ, Park KH et al: Comparison of percutaneous manual and endoscopic laser diskectomy with chemonucleolysis and automated nucleotomy. *Orthopade*, 1996; 25: 49-55