

Popliteal artery entrapment syndrome treated by a posterior approach in a 15-year-old athlete

Lili Sadri, MD, Robert L. Myers, MD, Casey Paterson, MD, Quynh-Diem Lam, MD, and Danielle M. Pineda, MD, FACS, Abington, PA

ABSTRACT

Popliteal artery entrapment syndrome is a rare source of claudication in young people. We present the case of a 15-year-old male athlete who presented with intermittent numbness of his right foot with exertion. Imaging revealed classic compression from a right type III popliteal artery entrapment. The left popliteal artery was chronically occluded with a large collateral vessel. He underwent release of the accessory bands of the gastrocnemius muscle with significant arteriolysis on the right side via a posterior approach. Chronic popliteal artery entrapment can be treated from a posterior approach, resulting in arterial occlusion and will be asymptomatic if well collateralized. (*J Vasc Surg Cases Innov Tech* 2022;8:248-50.)

Keywords: Atypical arterial disease; Popliteal entrapment syndrome; Young claudicant

Popliteal artery entrapment syndrome is a rare source of claudication in young patients without other etiologies of atherosclerosis.^{1,2} It results from aberrant positioning of the popliteal artery with respect to the surrounding musculature in the popliteal fossa. Six known types have been reported.³ We present the case of an adolescent male athlete with bilateral popliteal entrapment syndrome but only one symptomatic side. He underwent successful open treatment via a posterior approach of a type III popliteal artery entrapment syndrome. The patient and his mother provided written informed consent for the report of his case details and imaging studies.

CASE REPORT

A healthy 15-year-old male lacrosse player had presented with a chief complaint of right foot numbness and tingling with exercise but not with routine activity. He reported that during times of intense running, his right foot would turn pale white and become numb and painful. He denied similar symptoms in the left foot. On examination, he was found to have a weak pulse in the right foot and nonpalpable pulses in the left foot. Noninvasive imaging studies revealed a right ankle brachial index of 0.91 with monophasic waveforms isolated at the popliteal level and a left ankle brachial index of 0.86 with monophonic

waveforms from the popliteal artery distally. The Doppler waveforms on the right side became more monophasic at the ankle with dorsiflexion but the left side did not change with position. Magnetic resonance angiography (MRA) was performed of the bilateral lower extremities and revealed a focal popliteal artery stenosis in the right leg with three-vessel runoff to the foot. In the left leg, the patient had a long segment occlusion of his popliteal artery with a large collateral vessel present (Fig 1). On MRA, the popliteal artery appeared to be in the correct anatomic location but showed obvious compression and stenosis. It appeared that the compression was immediately behind the knee joint. Thus, we elected to perform the release from a posterior approach. He was well collateralized on the left side and was asymptomatic. Because the artery was already chronically occluded, we did not elect to perform a left-sided gastrocnemius release.

The procedure was performed with the patient in the prone position. To minimize scar retraction after surgery, exposure was achieved through an S-shaped incision from the lateral thigh, through the popliteal crease, and then down the medial calf. The lesser saphenous vein and sural nerve were encountered and retracted laterally. The gastrocnemius muscle was then identified, and the heads were split to identify the popliteal bundle. Doppler ultrasound examination confirmed the diminished signal of the distal popliteal artery with dorsal flexion of the ankle. We visualized a clear external stenosis of the popliteal artery secondary to dense bands. Arteriolytic of the adhesions encasing the popliteal artery was performed, and several fibrous bands directly compressing the popliteal artery were ligated. Medially, accessory tendinous extensions of the gastrocnemius muscle that were compressing the popliteal artery were divided. On release of these bands, the artery was inspected and was large in caliber without any evidence of damage to the wall (Fig 2). Doppler ultrasound examination was repeated and revealed a strong signal in the distal popliteal artery with flexion and extension of the ankle. Postoperatively, he had strongly palpable pulses in the right foot. He was admitted for pain

From the Department of Surgery, Abington-Jefferson Health.

Author conflict of interest: none.

Correspondence: Danielle M. Pineda, MD, FACS, Department of Surgery, Abington-Jefferson Health, 1200 Old York Rd, Abington, PA 19001 (e-mail: Danielle.pineda@jefferson.edu).

The editors and reviewers of this article have no relevant financial relationships to disclose per the Journal policy that requires reviewers to decline review of any manuscript for which they may have a conflict of interest.

2468-4287

© 2022 The Authors. Published by Elsevier Inc. on behalf of Society for Vascular Surgery. This is an open access article under the CC BY-NC-ND license (<http://creativecommons.org/licenses/by-nc-nd/4.0/>).

<https://doi.org/10.1016/j.jvscit.2022.03.009>

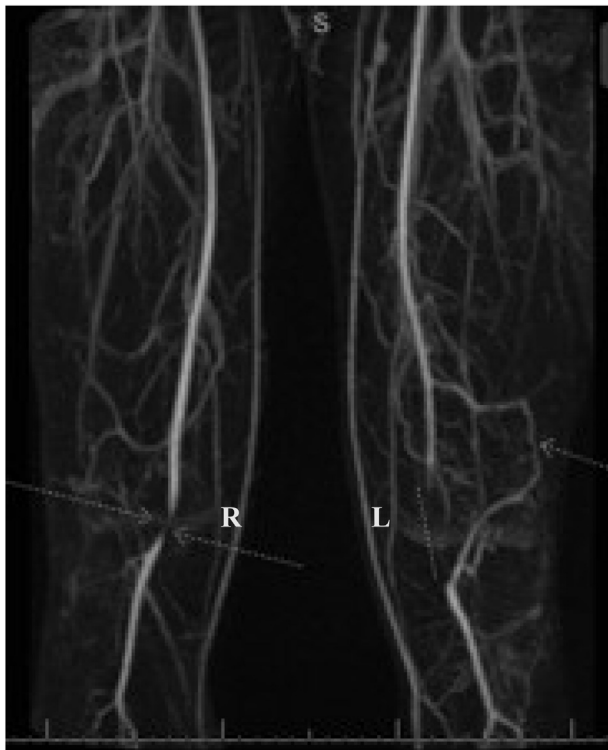

Fig 1. Magnetic resonance angiography (MRA) of bilateral lower extremities showing popliteal artery entrapment. The right (R) side shows compression, and the left (L) popliteal artery was occluded with a large collateral vessel.

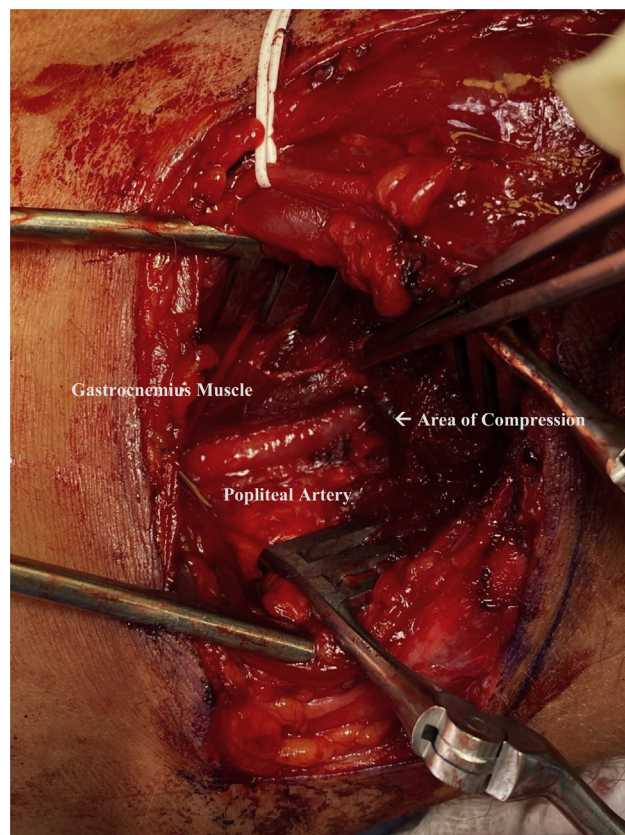


Fig 2. Intraoperative photograph showing the popliteal artery and vein after gastrocnemius release in a posterior approach.

control with anti-inflammatory medications and was encouraged to perform right leg exercises to prevent contracture. He was discharged on postoperative day 1 without issues. Two weeks after surgery, the patient had resumed light jogging. Six weeks later, he was fully functional to his baseline high level athletic activity and was asymptomatic in the right leg. He continued to have strong palpable pulses in his right foot. He was selected for a college level lacrosse team in preparation for a college career. He was scheduled for follow-up duplex ultrasound at 3 months after the procedure.

DISCUSSION

We have reported a case of a type III popliteal entrapment syndrome resulting from arterial compression secondary to excessive fibrous scarring and abnormal bands of the gastrocnemius muscle. Popliteal entrapment syndrome has been noted to disproportionately affect men in $\leq 80\%$ of cases, with a predominance in patients aged 20 to 40 years.³ Younger children can also be affected. Therefore, it has become increasingly important to achieve an early diagnosis and prompt treatment for preservation of function and limb salvage. The most common presenting symptom in patients with popliteal entrapment syndrome is calf claudication, which can be a challenging to evaluate in the pediatric population. Our patient was aged 15 years and, given his aptitude for

athletics, his inability to perform at his optimal level led to the correct diagnosis algorithm and prompt treatment. An accurate diagnosis is especially important to decrease the need for more extensive surgery and morbidity.⁴ Another vascular cause of claudication in healthy patients is adventitial cystic disease. Musculoskeletal and orthopedic causes should also be considered. In general, for this age group, the mainstay of treatment of popliteal entrapment syndrome is surgical intervention, with most patients requiring resection of the musculotendinous structures causing the entrapment.⁵ We would encourage the consideration of this rare, but debilitating, pathology in the differential diagnosis for claudication.

Two variations of this syndrome have been described. The first and most common type is anatomic entrapment, which results from an aberrant embryologic origin of the gastrocnemius muscle and its surrounding structures with respect to the popliteal neurovascular bundle. The next is functional entrapment, which is a sequela of abnormal arterial compression with movement in the setting of normal anatomy behind the knee. Of the former, five abnormalities have been described.^{3,6} Our patient had type III, which is an abnormal accessory slip of muscle from the gastrocnemius head. His

gastrocnemius muscle was otherwise in the correct anatomic location.

For the diagnosis of popliteal entrapment syndrome, the literature supports the use of both duplex ultrasound and MRA. Patients can present with both claudication and palpable pulses. In these patients, dorsiflexion and plantar flexion can be performed while palpating for pulses or listening for Doppler signals. A change in pedal pulses with provocative maneuvers would be a positive physical examination finding. Exercise treadmill testing with ankle brachial pressure measurements before and after exercise can also be used. Duplex ultrasound with calf muscle contraction and relaxation can be used. MRA can accurately identify this pathology. Provocative maneuvers can be used with magnetic resonance imaging and MRA to illicit the diagnosis. Also, invasive angiography with dorsiflexion and plantar flexion can be used to make the diagnosis, with compression of the popliteal artery seen with plantar flexion and complete occlusion of the artery found in $\leq 50\%$ of patients at the initial presentation.⁷ Our patient had compression on the right side and chronic complete occlusion on the left side. He was asymptomatic on the left side, despite the absence of normal pulses.

In symptomatic individuals, the Society for Vascular Surgery has recommended open surgical intervention for maintenance of quality of life and long-term limb salvage. Both medial and posterior approaches have been used in the treatment of this pathology—our approach posteriorly had the advantage of allowing for an enface and unobstructed view of the popliteal fossa and the opportunity to use the lesser saphenous vein as a patch if reconstruction would be necessary and is preferred in patients with types III and IV popliteal artery entrapment syndrome.⁸⁻¹⁰ The medial approach is more limited in exposure but affords a less invasive alternative and is used for types I and II popliteal artery entrapment syndrome. With this approach, younger patients are able to return to regular athletic activity with less associated morbidity.¹¹ Despite undergoing a posterior approach, our patient returned to normal activity very quickly without any functional limitations from the surgery. He did not develop left sided symptoms even after treatment of the right side. He has been undergoing

continued surveillance of the left side because no indication exists to treat a chronically occluded artery that is not causing symptoms.

Finally, Doppler confirmation of the return of pulsatility with and without compression of the involved artery was key to determining the adequacy of arteriolysis. Because the muscle slips were not the whole muscle, it was imperative to completely divide all these bands to achieve normal flow. Ultrasound should be used intraoperatively when available. Finally, arteriography can be used with foot maneuvers to ensure that the compressive bands have been completely released.

CONCLUSIONS

We have presented the case of a 15-year-old male athlete with bilateral popliteal artery entrapment syndrome who underwent open arteriolysis and accessory gastrocnemius release from a posterior approach for right foot pain and numbness on exertion.

REFERENCES

1. Cokkus K, Sagtas E, Bakalim T, Taskaya E, Aydin AT. Popliteal entrapment syndrome: a systematic review of the literature and case presentation. *Muscles Ligaments Tendons J* 2014;4:141-8.
2. Igari K, Sugano N, Kudo T, Toyofuku T, Jibiki M, Inoue Y, et al. Surgical treatment for popliteal artery entrapment syndrome. *Ann Vasc Dis* 2014;7:28-33.
3. Insua JA, Young JR, Humphries AW. Popliteal artery entrapment syndrome. *Arch Surg* 1970;101:771-5.
4. Politano AD, Bhamidipati CM, Tracci MC, Upchurch GR Jr, Cherry KJ. Anatomic popliteal entrapment syndrome is often a difficult diagnosis. *Vasc Endovascular Surg* 2012;46:542-5.
5. Settembre N, Bouziane Z, Bartoli MA, Nabokov V, Venermo M, Feugier P, et al. Popliteal artery entrapment syndrome in children: experience with four cases of acute ischaemia and review of the literature. *Eur J Vasc Endovasc Surg* 2017;53:576-82.
6. Bouhoutos J, Daskalakis E. Muscular abnormalities affecting the popliteal vessels. *Br J Surg* 1981;68:501-6.
7. Goh BKP, Tay K-H, Tan S-C. Diagnosis and surgical management of popliteal artery entrapment syndrome. *ANZ J Surg* 2005;75:869-73.
8. Colborn GL, Lumsden AB, Taylor BS, Skandalakis JE. The surgical anatomy of the popliteal artery. *Am Surg* 1994;60:238-46.
9. Levien LJ. Popliteal vascular entrapment syndrome a cause of leg pain to be considered in young athletes. *S Afr J Sports Med* 2001;8: 18-25.
10. Beseth BD, Moore WS. The posterior approach for repair of popliteal artery aneurysms. *J Vasc Surg* 2006;43:940-4; discussion: 944-5.
11. Levien LJ, Veller MG. Popliteal artery entrapment syndrome: more common than previously recognized. *J Vasc Surg* 1999;30:587-98.

Submitted Dec 8, 2021; accepted Mar 15, 2022.