



# Atrial fibrosis: an obligatory component of arrhythmia mechanisms in atrial fibrillation?

Pyotr G Platonov

Department of Cardiology, Lund University; Arrhythmia Clinic, Skåne University Hospital, SE-22185 Lund, Sweden. E-mail: pyotr.platonov@med.lu.se

*J Geriatr Cardiol* 2017; 14: 174–178. doi:10.11909/j.issn.1671-5411.2017.03.009

**Keywords:** Atrial fibrillation; Fibrosis; Remodeling

## 1 Introduction

Advances in clinical and fundamental research, which have been promoted over last decades have led to a well-established understanding of atrial fibrillation (AF) as an epiphenomenon that despite similar manifestations may have different underlying mechanisms and thus require individualized treatments.<sup>[1]</sup> With rare exceptions of AF caused by mutations in genes coding ion channels in patients with structurally normal atria, fibrotic replacement of atrial myocardium remains the corner stone of atrial pathology in patients with AF. However, we are still struggling trying to understand the mechanisms underlying the structural abnormalities in atrial walls observed in patients with the arrhythmia and its relationship to the arrhythmia mechanisms.

The common perception of AF being a result of interplay between the structural changes in the atrial myocardium induced by the well-described cardiovascular risk factors and structural remodelling induced by the arrhythmia itself has recently been challenged by observations of progressive structural abnormalities in the atrial walls that occur independently from the cardiovascular comorbidities and persistency of AF.<sup>[2]</sup> It is also well known that lone AF is not an uncommon clinical entity that may manifest early in life without any apparent risk factors, which would explain development of atrial fibrosis in patients with structurally normal hearts.<sup>[3]</sup> To what extent this fibrotic atrial cardiomyopathy represents a “common cause” of AF or a mechanism responsible for arrhythmia development in a subgroup of patients with AF phenotype remains however uncertain.

## 2 Atrial fibrosis and arrhythmogenesis

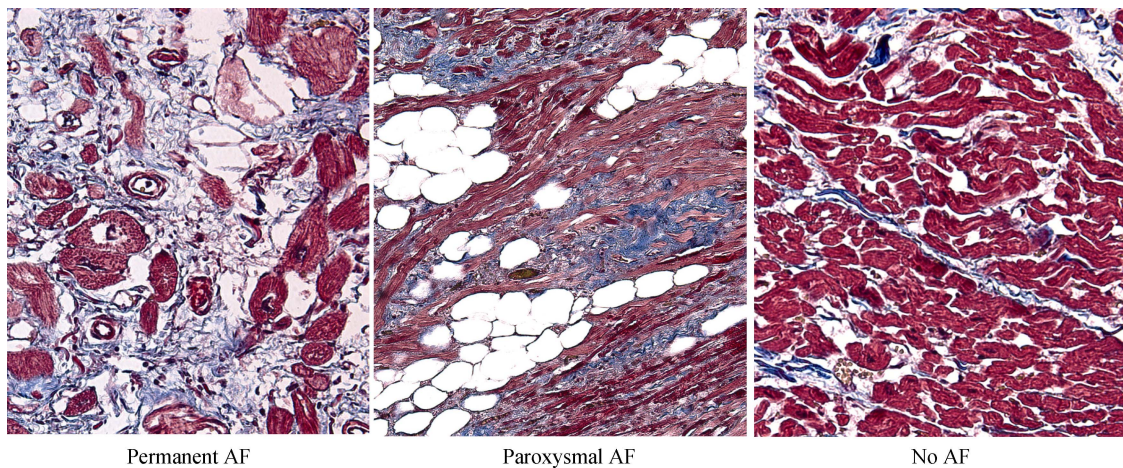
Fibroblasts represent an integral part of functioning myocardium by providing a cellular scaffold, maintaining a proper three-dimensional network required for normal me-

chanical function and contributing to the uniformity of the excitable substrate and to the uninterrupted and rapid propagation of electrical activation through myocardium.<sup>[4]</sup> In addition to that, fibroblasts play role in the regulation of cardiomyocyte function by slowing down conduction in response to mechanical stretch,<sup>[5]</sup> and in pathological conditions may proliferate, differentiate to myofibroblasts and increase production of extracellular matrix.

In the pathological conditions associated with development of fibrosis in patients with AF, fibroblasts may proliferate, increase production of extracellular matrix and differentiate to myofibroblasts that may directly slow down conduction.<sup>[6]</sup> As a result of fibrosis development, the architecture of fibrotic myocardial tissue becomes heterogeneous, thereby affecting intercellular conduction,<sup>[7,8]</sup> increasing its anisotropy and leading to conduction slowing, development of functional and structural block, thus creating the arrhythmic substrate.

Whether or not fibrosis itself may serve as an arrhythmia-initiating mechanism in the settings of clinical AF is not clear. The impact of the structural changes in the myocardium associated with fibrosis development, however, does not seem to be limited to the arrhythmia maintenance mechanisms related exclusively to the conduction slowing and creation of boundaries needed for perpetuation of AF. Computational modelling studies suggest that fibrosis-induced disorganisation of electrotonic coupling<sup>[9]</sup> may also lead to increased automaticity and atrial ectopy, thus potentiating arrhythmia triggering mechanisms.<sup>[10]</sup>

Despite the tremendous progress in the field that increased our understanding of the fine mechanisms involved in development of fibrosis in atrial walls, our knowledge of the role fibrosis plays in the development of AF remains limited. While fibrosis is beyond doubt, the most consistently reported structural abnormality of atrial walls in patients with AF, large number of patients with accumulation



**Figure 1. Light microscopy of myocardial specimens collected at post mortem from patients with history of permanent, paroxysmal and no AF (staining trichrome Mason,  $\times 200$ ). AF: atrial fibrillation.**

of fibrosis-causing clinical risk factors, such as advanced congestive heart failure, hypertension or diabetes, remain arrhythmia free as shown in the studies utilizing implantable rhythm monitoring technology.<sup>[11]</sup>

### 3 Atrial fibrosis in experimental models of AF

A number of experimental studies addressed the issue of structural remodelling of atrial myocardium in animals with AF induced by either prolonged rapid atrial pacing without directly affecting the ventricles,<sup>[12–14]</sup> or mediated by induction of congestive heart failure (CHF) by pacing right ventricle at a high rate.<sup>[12,15–17]</sup> The principal difference between these two experimental setups is related to their respective propensity to induce structural abnormalities of atrial myocardial and development of atrial fibrosis in particular. While CHF models consistently reported rapid development of atrial damage,<sup>[17]</sup> and irreversible atrial fibrosis associated with conduction heterogeneities and AF stability, rapid atrial pacing models demonstrated a wider spectrum of structural alterations with less pronounced fibrosis development. Some studies indicated that the likelihood of fibrosis development in the rapid atrial pacing model of AF strongly depends on the resulting ventricular rate,<sup>[18]</sup> so that animals with prolonged rapid atrial pacing and controlled ventricular rate by means of AV node ablation develop atrial fibrosis in a significantly lesser extent than those with preserved AV conduction.<sup>[19,20]</sup> Importantly, animals with controlled ventricular rate and minimal structural alterations were also less likely to develop persistent AF, thus supporting the link between the atrial fibrosis and AF mechanisms.<sup>[19]</sup> Even though it may be problematic to prove this in clinical studies, these observations made in experimental models of AF demonstrate clinical relevance

to human AF observed in patients with and without adequate rate control.

### 4 Histological evidence of atrial fibrosis in patients with AF

In humans, indirect indication of the link between cardiovascular comorbidities and AF comes from epidemiological studies, in which potentially fibrosis-causing conditions such as hypertension, ischemic heart disease and diabetes were highly predictive of incident AF.<sup>[21]</sup> Age-related increase in the prevalence of AF has also been well documented<sup>[22]</sup> and explained by growing cardiovascular disease burden in the elderly as well as age-related increase in the atrial fibrosis extent.<sup>[23]</sup> However, attempts to provide a quantitative assessment of atrial structural abnormalities associated with AF have shown a more complex picture. Even though catheter-based techniques of endocardial voltage mapping and emerging non-invasive magnetic resonance imaging (MRI) have shown their value in visualization of atrial structural abnormalities, histological evaluation of atrial tissue samples remains a golden standard of tissue characterization. This approach, however, is often limited to a small volume of tissue samples that can be collected in patients undergoing atrial biopsy or confined to right or left atrial appendages in patients undergoing open-chest heart surgery, thus imposing a significant selection bias on patient selection and leaving large portions of atrial walls, in which AF perpetuates, outside reach.

One of the first observations of the structural substrate of AF in patients without apparent structural heart disease came from the study by Frustaci, *et al.*,<sup>[3,24]</sup> who collected biopsies from atrial septum as well as from ventricles in patients with lone AF and reported a consistent finding of

myocardial inflammation and fibrosis confined to the atrial myocardium but not present in ventricular walls. These studies were the first that suggested the presence of occult myocardial disease that might have direct causal relationship with development of AF.

Our group has further expanded this concept by studying histology specimens from multiple sampling locations in the right and left atrium collected post mortem from deceased patients with common cardiovascular comorbidities with previous paroxysmal, permanent AF and those without AF history enrolled in a 1: 1: 1 fashion according to pre-specified inclusion criteria.<sup>[25]</sup> The extent of fibrosis and fatty tissue in the atrial myocardium showed strong and significant correlation with the presence of AF at all tissue sampling locations in the left and right atria. Notably, patients with and without AF did not differ in regard to cardiovascular co-morbidities and one could not observe any age-related increase in the extent of atrial fibrosis. Similar observations were made in patients with persistent or long-standing AF referred for surgical ablation,<sup>[26]</sup> thus suggesting that development of structural abnormalities in the atria is not a result of concomitant diseases but rather a phenomenon associated with AF. Indirect assessment of atria fibrosis using MRI-technique in a large cohort has further supported this theory by not finding any significant differences in the estimated fibrosis extent between AF patients with and without co-morbidities.<sup>[27]</sup> To the best of our knowledge, however, there is no histology data that would specifically address the question of causal relationships between the burden of concomitant cardiovascular diseases and atrial fibrosis in patients with AF.

Contrary to the findings in lone AF,<sup>[24]</sup> we did observe similar extent of fibrotic replacement and inflammatory infiltration in the free walls of the right and left ventricles in patients with common cardiovascular comorbidities. In our controlled study, ventricular fibrosis demonstrated strong correlation with AF history and with the extent of fibrosis in the major atrial conduction routes such as Bachmann's bundle and terminal crest.<sup>[28]</sup> These findings may be interpreted as indicated an underlying occult cardiomyopathy with significant inflammatory component in patients with AF, the viewpoint that which has recently received support from a study of left ventricular function and energetics in patients with lone AF.<sup>[29]</sup> As demonstrated by Wijesurendra, *et al.*,<sup>[29]</sup> not only the patients with lone AF had reduced phosphocreatine to ATP ratio as the measure of ventricular energetics, but this function remained lower than in control subjects regardless of both recovery of sinus rhythm and freedom from recurrent AF during long-term follow-up.

## 5 Atrial fibrosis in AF: cause or consequence?

Whether or not structural abnormalities observed in the atria are the cause or consequence of AF remains, however, an open question. The presence of relationship between the extent of fibrosis and AF burden does not give us a definitive answer and could be explained both ways: expansive fibrotic process in the atria may promote persistent AF or may be a consequence of the long-standing fibrillatory process. The lack of this relationship, however, would favour the concept of the primary occult cardiomyopathy underlying AF development.

Available data suggest that the extent of fibrosis tends to be higher in patients with permanent compared with paroxysmal AF,<sup>[25]</sup> but the relationship between the extent of structural abnormalities and duration of AF seems to disappear in patients with persistent AF.<sup>[26]</sup> In another study that quantified the expression of extracellular matrix proteins in atrial tissue samples collected during heart surgery, no systematic difference between patients with paroxysmal and permanent AF was documented.<sup>[30]</sup> Even though this does not address the unresolved causality issue, one can speculate that fibrosis extent in the atrial walls may be linked to AF burden and clinical manifestations of the arrhythmia at the early stages of the disease but, upon reaching a certain level, would no longer affect AF phenotype in patients who develop persistent AF.

If fibrosis is directly related to the mechanisms governing development of AF substrate rather than being a consequence of the arrhythmia itself, then interventions attenuating fibrosis expansion would be expected to slow down or abolish AF progression. Indeed, there is considerable experimental evidence that a number of compounds, such as angiotensin-converting enzyme (ACE) inhibitors, Angiotensin 1 (AT<sub>1</sub>)-receptor blockers or statins, may delay structural remodelling process and reduce AF stability.<sup>[31–34]</sup> Clinical validity of these findings is however uncertain. Experimental findings have been supported by data presented in a recent meta-analysis (at least in regard to ACE inhibitors and AT<sub>1</sub> receptor blockers),<sup>[35]</sup> and upstream therapy with these compounds has been advocated by ESC guidelines for primary and secondary prevention of AF.<sup>[36]</sup> However, it is important to observe that the evidence is strongest in patients with heart failure and those who otherwise have indications for the upstream therapy drugs, while studies that used AF as a pre-specified endpoint demonstrate less convincing and conflicting results.<sup>[37–39]</sup> Efficacy of pre-treatment with candesartan<sup>[40]</sup> or pravastatin<sup>[41]</sup> for reduction of AF relapse after cardioversion was not proved in two randomized placebo-controlled studies. It is likely,

though remains unproven, that efficacy of fibrosis reducing drugs for AF prevention may depend on the degree of structural remodelling and irreversibility of fibrotic transformation of atrial myocardium achieved by the time when drug therapy is initiated so that early administration of the drug would affect the course of the disease, while initiation of therapy late in the course of the disease would not affect the outcome.

## 6 Conclusions

Long-term observational studies would be able to resolve this controversy if show that successful rhythm-control intervention or upstream fibrosis-reducing therapies may slow down or abolish progression of the atrial structural changes, however direct histological evidence of this cause-effect relationship is lacking at this point. On the opposite, evidence of progressive cardiac remodelling that continues after a successful catheter ablation<sup>[42]</sup> or not reversed by the achieved freedom from arrhythmia<sup>[29]</sup> is emerging thus highlighting remaining knowledge gaps in our understanding of mechanisms of this common rhythm disorder.

## References

- Kirchhof P, Breithardt G, Aliot E, *et al.* Personalized management of atrial fibrillation: Proceedings from the Fourth Atrial Fibrillation Competence Network/European Heart Rhythm Association Consensus Conference. *Europace* 2013; 15: 1540–1556.
- Kottkamp H. Fibrotic atrial cardiomyopathy: a specific disease/syndrome supplying substrates for atrial fibrillation, atrial tachycardia, sinus node disease, AV node disease, and thromboembolic complications. *J Cardiovasc Electrophysiol* 2012; 23: 797–799.
- Frustaci A, Caldarulo M, Buffon A, *et al.* Cardiac biopsy in patients with “primary” atrial fibrillation. Histologic evidence of occult myocardial diseases. *Chest* 1991;100: 303–306.
- Miragoli M, Glukhov AV. Atrial fibrillation and fibrosis: beyond the cardiomyocyte centric view. *Biomed Res Int* 2015; 798768.
- Kohl P, Kamkin AG, Kiseleva IS, Noble D. Mechanosensitive fibroblasts in the sino-atrial node region of rat heart: interaction with cardiomyocytes and possible role. *Exp Physiol* 1994; 79: 943–956.
- Gaudesius G, Miragoli M, Thomas SP, Rohr S. Coupling of cardiac electrical activity over extended distances by fibroblasts of cardiac origin. *Circ Res* 2003; 93: 421–428.
- de Jong S, van Veen TA, van Rijen HV, de Bakker JM. Fibrosis and cardiac arrhythmias. *J Cardiovasc Pharmacol* 2011; 57: 630–638.
- Begg GA, Holden AV, Lip GY, *et al.* Assessment of atrial fibrosis for the rhythm control of atrial fibrillation. *Int J Cardiol* 2016; 220: 155–161.
- Nattel S, Maguy A, Le Bouter S, Yeh YH. Arrhythmogenic ion-channel remodeling in the heart: heart failure, myocardial infarction, and atrial fibrillation. *Physiol Rev* 2007; 87: 425–456.
- Xie Y, Garfinkel A, Camelliti P, *et al.* Effects of fibroblast-myocyte coupling on cardiac conduction and vulnerability to reentry: A computational study. *Heart Rhythm* 2009; 6: 1641–1649.
- Caldwell JC, Contractor H, Petkar S, *et al.* Atrial fibrillation is under-recognized in chronic heart failure: insights from a heart failure cohort treated with cardiac resynchronization therapy. *Europace* 2009; 11: 1295–1300.
- Li D, Fareh S, Leung TK, Nattel S. Promotion of atrial fibrillation by heart failure in dogs: atrial remodeling of a different sort. *Circulation* 1999; 100: 87–95.
- Morillo CA, Klein GJ, Jones DL, Guiraudon CM. Chronic rapid atrial pacing. Structural, functional, and electrophysiological characteristics of a new model of sustained atrial fibrillation. *Circulation* 1995; 91: 1588–1595.
- Wijffels MC, Kirchhof CJ, Dorland R, Allesie MA. Atrial fibrillation begets atrial fibrillation. A study in awake chronically instrumented goats. *Circulation* 1995; 92: 1954–1968.
- Shinagawa K, Shi YF, Tardif JC, *et al.* Dynamic nature of atrial fibrillation substrate during development and reversal of heart failure in dogs. *Circulation* 2002; 105: 2672–2678.
- Cha TJ, Ehrlich JR, Zhang L, *et al.* Dissociation between ionic remodeling and ability to sustain atrial fibrillation during recovery from experimental congestive heart failure. *Circulation* 2004; 109: 412–418.
- Hanna N, Cardin S, Leung TK, Nattel S. Differences in atrial versus ventricular remodeling in dogs with ventricular tachypacing-induced congestive heart failure. *Cardiovasc Res* 2004; 63: 236–244.
- Schoonderwoerd BA, Ausma J, Crijns HJ, *et al.* Atrial ultrastructural changes during experimental atrial tachycardia depend on high ventricular rate. *J Cardiovasc Electrophysiol* 2004; 15: 1167–1174.
- Anne W, Willems R, Holemans P, *et al.* Self-terminating af depends on electrical remodeling while persistent af depends on additional structural changes in a rapid atrially paced sheep model. *J Mol Cell Cardiol* 2007; 43: 148–158.
- Avitall B, Bi J, Mykytsey A, Chicos A. Atrial and ventricular fibrosis induced by atrial fibrillation: evidence to support early rhythm control. *Heart Rhythm* 2008; 5: 839–845.
- Smith JG, Newton-Cheh C, Almgren P, *et al.* Assessment of conventional cardiovascular risk factors and multiple biomarkers for the prediction of incident heart failure and atrial fibrillation. *J Am Coll Cardiol* 2010; 56: 1712–1719.
- Smith JG, Platonov PG, Hedblad B, *et al.* Atrial fibrillation in the malmo diet and cancer study: A study of occurrence, risk factors and diagnostic validity. *Eur J Epidemiol* 2010; 25: 95–102.
- Gramley F, Lorenzen J, Knackstedt C, *et al.* Age-related atrial

- fibrosis. *Age (Dordr)* 2009; 31: 27–38.
- 24 Frustaci A, Chimenti C, Bellocci F, *et al.* Histological substrate of atrial biopsies in patients with lone atrial fibrillation. *Circulation* 1997; 96: 1180–1184.
  - 25 Platonov PG, Mitrofanova LB, Orshanskaya V, Ho SY. Structural abnormalities in atrial walls are associated with presence and persistency of atrial fibrillation but not with age. *J Am Coll Cardiol* 2011; 58: 2225–2232.
  - 26 Corradi D, Callegari S, Manotti L, *et al.* Persistent lone atrial fibrillation: clinicopathologic study of 19 cases. *Heart Rhythm* 2014; 11: 1250–1258.
  - 27 Mahnkopf C, Badger TJ, Burgon NS, *et al.* Evaluation of the left atrial substrate in patients with lone atrial fibrillation using delayed-enhanced MRI: implications for disease progression and response to catheter ablation. *Heart Rhythm* 2010; 7: 1475–1481.
  - 28 Mitrofanova LB, Orshanskaya V, Ho SY, Platonov PG. Histological evidence of inflammatory reaction associated with fibrosis in the atrial and ventricular walls in a case-control study of patients with history of atrial fibrillation. *Europace* 2016; 18: iv156–iv162.
  - 29 Wijesurendra RS, Liu A, Eichhorn C, *et al.* Lone atrial fibrillation is associated with impaired left ventricular energetics that persists despite successful catheter ablation. *Circulation* 2016; 134: 1068–1081.
  - 30 Boldt A, Wetzel U, Lauschke J, *et al.* Fibrosis in left atrial tissue of patients with atrial fibrillation with and without underlying mitral valve disease. *Heart* 2004; 90: 400–405.
  - 31 Kumagai K, Nakashima H, Urata H, *et al.* Effects of angiotensin ii type 1 receptor antagonist on electrical and structural remodeling in atrial fibrillation. *J Am Coll Cardiol* 2003; 41: 2197–2204.
  - 32 Li D, Shinagawa K, Pang L, *et al.* Effects of angiotensin-converting enzyme inhibition on the development of the atrial fibrillation substrate in dogs with ventricular tachypacing-induced congestive heart failure. *Circulation* 2001; 104: 2608–2614.
  - 33 Milliez P, Deangelis N, Rucker-Martin C, *et al.* Spironolactone reduces fibrosis of dilated atria during heart failure in rats with myocardial infarction. *Eur Heart J* 2005; 26: 2193–2199.
  - 34 Shiroshita-Takeshita A, Brundel BJ, Burstein B, *et al.* Effects of simvastatin on the development of the atrial fibrillation substrate in dogs with congestive heart failure. *Cardiovasc Res* 2007; 74: 75–84.
  - 35 Schneider MP, Hua TA, Bohm M, *et al.* Prevention of atrial fibrillation by renin-angiotensin system inhibition a meta-analysis. *J Am Coll Cardiol* 2010; 55: 2299–2307.
  - 36 Kirchhof P, Benussi S, Kotecha D, *et al.* 2016 ESC guidelines for the management of atrial fibrillation developed in collaboration with eacts. *Eur Heart J* 2016; 37: 2893–2962.
  - 37 Hansson L, Lindholm LH, Ekblom T, *et al.* Randomised trial of old and new antihypertensive drugs in elderly patients: cardiovascular mortality and morbidity the swedish trial in old patients with hypertension-2 study. *Lancet* 1999; 354: 1751–1756.
  - 38 Wachtell K, Lehto M, Gerds E, *et al.* Angiotensin II receptor blockade reduces new-onset atrial fibrillation and subsequent stroke compared to atenolol: the losartan intervention for endpoint reduction in hypertension (life) study. *J Am Coll Cardiol* 2005; 45: 712–719.
  - 39 Schmieder RE, Kjeldsen SE, Julius S, *et al.* Reduced incidence of new-onset atrial fibrillation with angiotensin ii receptor blockade: the value trial. *J Hypertens* 2008; 26: 403–411.
  - 40 Tveit A, Grundvold I, Olufsen M, *et al.* Candesartan in the prevention of relapsing atrial fibrillation. *Int J Cardiol* 2007; 120: 85–91.
  - 41 Tveit A, Grundtvig M, Gundersen T, *et al.* Analysis of pravastatin to prevent recurrence of atrial fibrillation after electrical cardioversion. *Am J Cardiol* 2004; 93: 780–782.
  - 42 Teh AW, Kistler PM, Lee G, *et al.* Long-term effects of catheter ablation for lone atrial fibrillation: progressive atrial electroanatomic substrate remodeling despite successful ablation. *Heart Rhythm* 2012; 9: 473–480.

This article is part of a Special Issue “**Atrial fibrillation in the elderly**”.  
Guest Editors: Manuel Martínez-Sellés & Antoni Bayés de Luna