



Contents lists available at ScienceDirect

## International Journal of Surgery Case Reports

journal homepage: [www.casereports.com](http://www.casereports.com)

# Large bowel obstruction as a consequence of transverse colon volvulus: A case report

Mohammad A. Al-Doud<sup>a,\*</sup>, Malek A. Al- Omari<sup>a</sup>, Heba G. Dboush<sup>a</sup>, Ahmad S. Alabbadi<sup>a</sup>, Intithar E. Al- Rahamneh<sup>b</sup>

<sup>a</sup> Department of General Surgery, Jordanian Royal Medical Services (JRMS), Amman, Jordan

<sup>b</sup> Department of Nursing, Jordanian Royal Medical Services (JRMS), Amman, Jordan

## ARTICLE INFO

### Article history:

Received 26 September 2020

Received in revised form 16 October 2020

Accepted 17 October 2020

Available online 21 October 2020

### Keywords:

Transverse colon  
Volvulus  
Bowel obstruction

## ABSTRACT

**INTRODUCTION:** Transverse colon volvulus incidence is comparatively rare when compared to cecal and sigmoid volvulus. Its diagnosis is still challenging for the surgeon. Delay in the diagnosis of this condition carries high morbidity and mortality rates.

**AIM:** To report a rare case of transverse colon volvulus in a young adult male that presented as large bowel obstruction and was operated upon in the General Surgery department in the Jordanian Royal Medical Services (JRMS), Amman, Jordan.

**PRESENTATION OF CASE:** An 18-year-old male presented with severe generalized abdominal pain of 12-h-duration, associated with significant abdominal distention and constipation of one-day duration. His abdominal examination revealed a massively distended, tender abdomen; however, there were no signs of peritonitis. Abdominal radiographs showed a massively dilated large bowel. He underwent exploratory laparotomy that revealed the diagnosis of transverse colon volvulus. His condition was managed operatively with transverse colectomy with a primary anastomosis. The patient had a satisfactory postoperative recovery.

**DISCUSSION:** Only 3–5% of all cases of intestinal obstruction are caused by colonic volvulus. Transverse colon is involved in 2–4% of them. The diagnosis of transverse colon volvulus can be delayed and difficult because it does not have the same classically recognizable radiographic features as cecal and sigmoid volvulus.

**CONCLUSION:** Transverse colon volvulus is a rare entity. A swift suspicion of diagnosis is key to preventing severe outcomes. It can result in bowel perforation and fecal peritonitis. The definitive diagnosis is frequently made intraoperatively. Early surgical intervention is essential for better outcome and avoiding complications.

© 2020 The Authors. Published by Elsevier Ltd on behalf of IJS Publishing Group Ltd. This is an open access article under the CC BY-NC-ND license (<http://creativecommons.org/licenses/by-nc-nd/4.0/>).

## 1. Introduction

Large bowel obstruction is a common surgical emergency. Mechanical causes account for more than 60%, and colonic tumors account for about 20%. Colonic volvulus is involved only in 3–5% of all cases of intestinal obstruction. Nausea and vomiting are late signs as the obstruction is distal in the gastrointestinal tract. Computerized tomography (CT) scan has largely replaced other investigations as it can differentiate between different pathologies and, if the obstruction is the result of a malignant cause, it will provide more-detailed information on staging [1].

The most common site of colonic volvulus is the sigmoid colon. Transverse colon volvulus incidence is comparatively rare when compared to cecal volvulus and sigmoid volvulus. Its diagnosis is still challenging for the surgeon [2,3].

We report our experience in the General Surgery department in the Jordanian Royal Medical Services (JRMS), Amman, Jordan, with a young adult male patient who had a transverse colon volvulus. The CT scan as a modality of imaging lacks the classical recognizable radiographic features seen in sigmoid and cecal volvulus. The definitive diagnosis is frequently made intra-operatively. Delay in the diagnosis of this condition carries high mortality and morbidity rates. This work is submitted in line with the SCARE 2018 criteria [4].

## 2. Case report

An 18-year-old male was brought to the emergency department by his parents complaining of severe generalized abdominal pain

\* Corresponding author.

E-mail addresses: [Mohammad.aldoud@yahoo.com](mailto:Mohammad.aldoud@yahoo.com) (M.A. Al-Doud), [Malekamo86@yahoo.com](mailto:Malekamo86@yahoo.com) (M.A. Al- Omari), [Jordanian1@rocketmail.com](mailto:Jordanian1@rocketmail.com) (H.G. Dboush), [Abbadi.Ahmad@mail.ru](mailto:Abbadi.Ahmad@mail.ru) (A.S. Alabbadi), [Tariq.abbadi@yahoo.com](mailto:Tariq.abbadi@yahoo.com) (I.E. Al- Rahamneh).

of 12-h-duration. He described the pain as crampy. A significant abdominal distention was noticed by the patient as well as constipation of one-day duration. No history of vomiting was reported. He denied fever, chills or urinary symptoms. No change on his appetite. He was known to have epilepsy and on regular treatment with Valproic acid. No drug allergies were documented. He had never had surgical operations nor any history of abdominal wall hernias. The patient reported that he had chronic constipation, straining during defecation and sitting for a long duration in the toilet for which he often self-medicated with glycerin suppositories without seeking medical advice.

Physical examination revealed a thin young man screaming of pain. He rated his pain as 7/10. Vital signs, on arrival were: temperature 37.6 °C, pulse rate 110/minute, respiratory rate 22/minute, and blood pressure 100/60 mmHg. His SpO<sub>2</sub> on room air was 98%. Head and neck examination was negative for jaundice, lymphadenopathy or any other stigmata of chronic systemic disease. His lips were dry and cracked. His chest examination had normal symmetrical expansion, normal percussion note and adequate air entry on both lungs. Abdominal examination revealed a massively distended abdomen with visible dilated bowel loops. On auscultation, bowel sounds were exaggerated. It was significantly tympanic to percussion. The abdomen was tender on palpation. However there were no signs of peritonitis. Hernia orifices were checked and were intact. On digital rectal examination, the rectum was empty of stool. No blood per rectum was detected nor palpable intraluminal masses.

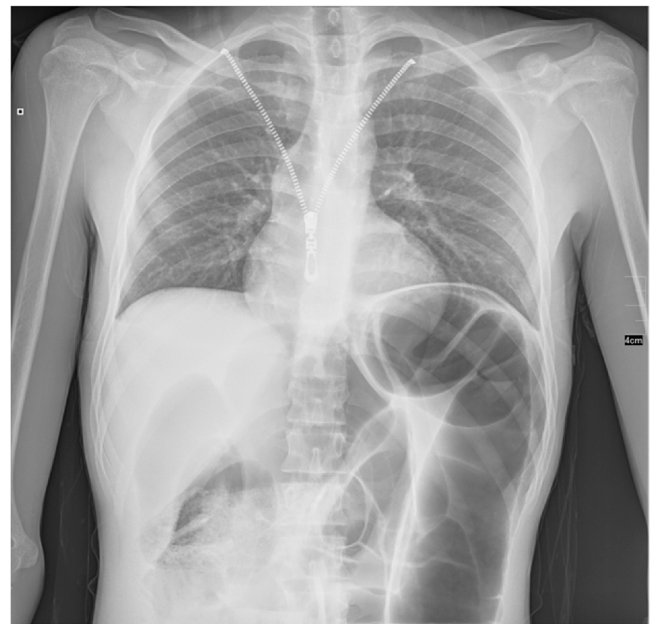Laboratory studies performed in the ER included complete blood count (CBC), kidney function and electrolytes, arterial blood gases (ABGs) and liver function test. Leukocytosis of 19,000 / $\mu$ L was present with normal hematocrit and normal platelet counts. Kidney function test and electrolytes showed elevated BUN/creatinine ratio as well as hypokalemia (BUN : 35 mg/dL; Creatinine 0.9 mg/dL; K<sup>+</sup> 3.1 mEq/L). Arterial blood gases showed metabolic acidosis (pH : 7.29; CO<sub>2</sub> : 32; HCO<sub>3</sub> : 15). Initial resuscitation had been instituted in the ER.

Chest and Abdominal radiographs were obtained and showed a massively dilated large bowel with a “U-shaped” loop in the left upper abdomen, and multiple air-fluid levels suggesting intestinal obstruction due to colonic volvulus (Figs. 1 & 2). The abdominal CT scan demonstrated dilatation of the right colon and the transverse colon with a ‘cut-off’ sign near the splenic flexure. Minimal free fluid was noted in the abdomen and pelvis (Fig. 3). No signs of malignancy were found on CT imaging. Treatment has been initiated in the ER with fluid resuscitation by administration of 1,000 mL Ringer’s lactate solution. Nasogastric tube was inserted to decompress the stomach. Urinary catheter was inserted to monitor urine output.

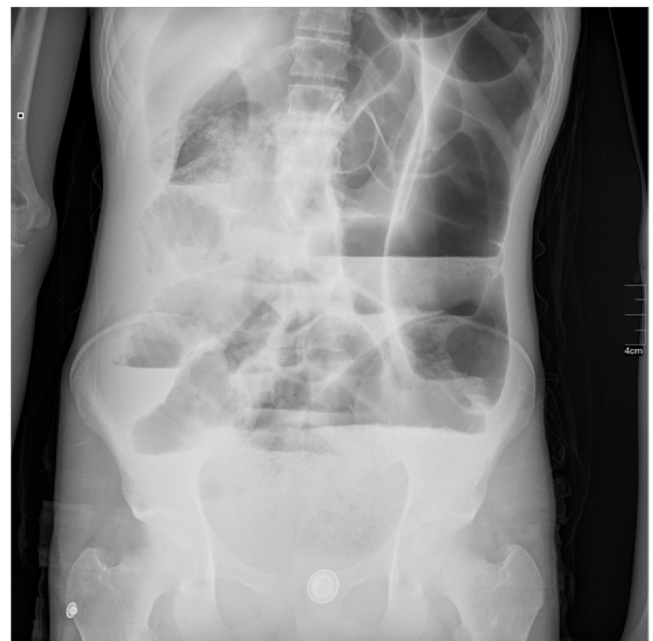After initial resuscitation, the decision was taken to perform emergent endoscopic detorsion. The patient signed an informed consent for endoscopic decompression as well as laparotomy for possible failure of the procedure or complication with bowel perforation. The procedure was unsuccessful, due to poor preparation and the too high level of obstruction. The patient was prepared and taken to the theatre for exploratory laparotomy.

General anesthesia with endotracheal intubation was performed. Preoperative antibiotics were administered, as a prophylaxis. Urinary catheter and nasogastric drainage tubes had already been inserted.

The abdomen was prepped and draped in the routine manner. A midline lower abdominal incision was made with subsequent opening in layers. Intra-operatively, rotation of the transverse colon on its mesentery was detected, resulting in a closed loop obstruction (Fig. 4). The point of twist was found to be in the left upper quadrant. The bowel was healthy-looking with no gross signs of ischemia. The transverse colon was abnormally lengthy and exces-



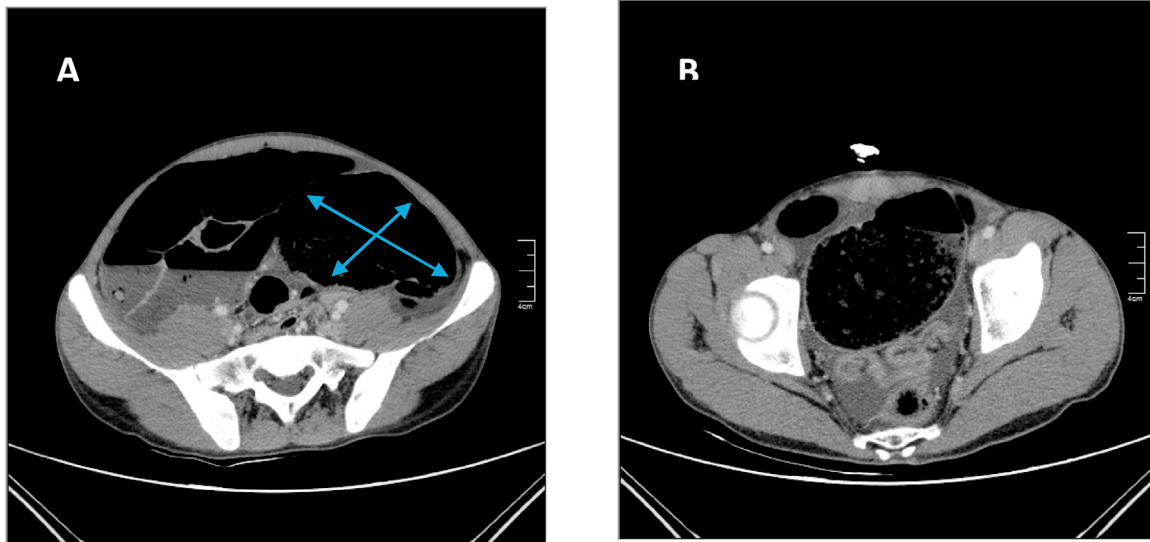
**Fig. 1.** Radiograph of the chest showing massively dilated bowel loop in left upper quadrant.



**Fig. 2.** Plain abdominal X-ray in erect position showing multiple air-fluid levels, a dilated bowel loop and gasless rectum.

sively redundant. Other abdominal organs were assessed and were intact. The volvulus was detorsed in a counter-clockwise fashion. We performed a transverse colectomy with side-to-side anastomosis using gastrointestinal anastomosis (GIA) stapler. The patient had a satisfactory postoperative recovery and was discharged from the hospital seven days later. Histologically, the resected part had no acute inflammation, infarction, granulomas, dysplasia, malignancy, or vascular abnormality.

Two follow-up visits at 2 weeks and 4 weeks post-surgery were unremarkable and he returned to his secondary school one month after surgery. The patient maintained the same body weight as when discharged and constipation-related symptoms disappeared after surgery.



**Fig. 3.** Selected images of abdominal CT scan.

A. Axial CT image demonstrating a significant dilatation of the right colon and the transverse colon.  
 B Axial CT image demonstrating an intra-abdominal free fluid.

### 3. Discussion

The term volvulus, derived from the Latin word *volvere* meaning roll or to turn, describes the axial twisting of the bowel along its mesenteric axis. If the twisting is tight enough, or the venous return impaired is of sufficient duration, arterial inflow will become compromised, leading to bowel ischemia, infarction and necrosis, resulting in bowel perforation and fecal peritonitis [5,6]. There are multiple types of volvulus: gastric, midgut volvulus, volvulus neonatorum, cecal volvulus, sigmoid volvulus and transverse colon volvulus [6].

Mechanical colonic obstruction accounts for around 10% of all mechanical obstructions. The usual causes of this are cancer, volvulus, or diverticulitis resulting in a stricture [9]. The most common site of colonic volvulus is the sigmoid colon, and accounts for approximately 75% of large bowel volvulus [2,3]. Sigmoid volvulus has a characteristic appearance of a “bent inner tube” on plain abdominal X-ray, due to massively distended, twisted loop in the right upper quadrant. The initial management of sigmoid volvulus is relief of the obstruction, by sigmoidoscopic decompression and detorsion. This procedure is effective in 70–80% of cases. Despite a successful result, volvulus recurs in 50–90% of patients, and as such this technique should be considered as a temporizing measure only. The definitive surgery is sigmoid colectomy. Spontaneous reduction is rare and occurs in only two per cent of patients [2,3].

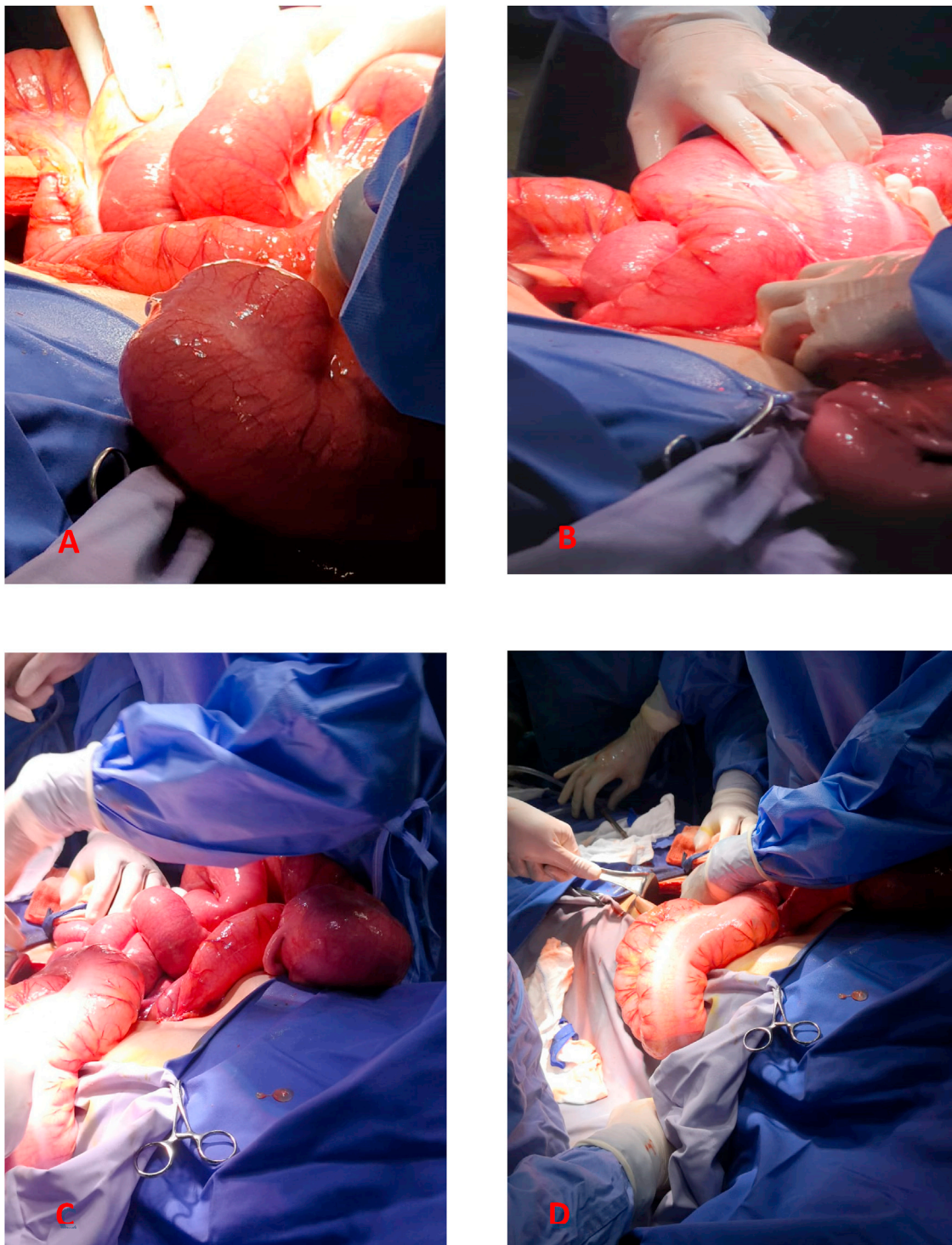
Cecal volvulus, on the other hand, is the second most common. There may be a radiographic evidence of small bowel obstruction. The initial management of cecal volvulus, is similar to sigmoid volvulus. However, the endoscopic decompression is effective only in 25% of cases. The definitive surgery, cecopexy with or without cecostomy, is sufficient. If the cecum is gangrenous, it must be resected [10].

Cecal volvulus is found most frequently in persons 25–35 years of age, whereas it is unusual for sigmoid volvulus to occur in an active, otherwise healthy individual. Usually, it occurs in elderly, damped persons or in those with neurologic or psychiatric disorders. Medications that reduce bowel motility and cause loss of accessory defecatory muscles may lead to elongation of the colon and constipation [5,10].

Transverse colon volvulus incidence is comparatively rare when compared to cecal volvulus and sigmoid volvulus. Usually, the descending and ascending portions of the colon are fused to the retroperitoneum, whereas the sigmoid and transverse portions are free. Developmental anomalies of fixation, seen with in some cases of volvulus and malrotation, are one of the congenital predisposing factors for volvulus [5]. Chronic constipation and high fiber content in the diet result in large volumes of stool and an elongated colon, leading to twisting of the bowel around its mesentery [10]. In 1932, the first case of transverse colon volvulus was reported as a cause of large bowel obstruction by the Finnish surgeon Kallio [7]. Transverse colon volvulus presents with clinical features of proximal large bowel obstruction. This is usually associated with abdominal pain that is colicky in nature, vomiting and abdominal distension. The diagnosis of transverse colon volvulus can be delayed and difficult because it does not have the same classically recognizable radiographic features as cecal and sigmoid volvuli [11].

Transverse colon volvulus must be emergently treated surgically. Initially detorsion is mandatory but resection is the treatment of choice to prevent recurrence [11]. Actually, detorsion with or without colopexy has a higher rate of recurrence than resection [11]. The incidence of volvulus recurrence following resection and primary anastomosis varies between 22% and 36% [12].

The surgical options in the management of acute large bowel obstruction, as a consequence of transverse colon volvulus are: **One-stage procedure:** includes intra-operative colonic irrigation, resection of non-viable bowel and primary anastomosis to avoid a stoma creation. In a **two-stage procedure** two options are available: (1) Bowel is resected; proximal end is brought out as terminal colostomy and distal end as a mucus fistula; 2–3 months post-surgery, end-to-end anastomosis is performed. (2) Bowel is resected and end-to-end anastomosis is performed; A de-functioning colostomy or a loop ileostomy is fashioned to protect the anastomosis which is closed 3–4 weeks later [8,11]. The two-stage procedure is preferred in bowel perforation and hemodynamic instability. In the absence of vascular compromise, one-stage procedure is sufficient [11,12]. In our patient's case, the bowel was viable and the patient was hemodynamically stable so transverse colectomy with primary anastomosis was performed.



**Fig. 4.** Intra operative photos demonstrating.  
 A. Rotation of the transverse colon on its mesentery.  
 B. Detorsion of the transverse colon volvulus.  
 C. The point of twist, in the left upper quadrant.  
 D. The transverse colon was excessively redundant.

#### 4. Conclusion

Transverse colon volvulus is a rare entity. Usually occurs in adults with minor predisposing factors such as chronic constipation and redundant intestinal tissue. A swift suspicion of diagnosis is key to preventing severe outcomes. It can result in bowel perforation and fecal peritonitis. The definitive diagnosis is frequently

made intra-operatively. Early surgical intervention is essential for better outcome and avoiding complications.

#### Declaration of Competing Interest

The authors report no declarations of interest.

**Sources of funding**

This study has no sponsors and is self-funded.

**Ethical approval**

Ethical approval has been taken from The Ethical Committee at King Hussein Medical Center, Amman, Jordan. The reference number is 8/10/2019.

**Consent**

Written informed consent was obtained from the patient for publication of this case report and accompanying images. A copy of the written consent is available for review by the Editor-in-Chief of this journal on request.

**Author contribution****Category 1:****Pre-Operative care:**

**Emergency department care:** Mohammad A. Al-Doud, Ahmad S. Alabbadi.

**Operation:**

**Main Surgeon:** Mohammad A. Al-Doud.

**Assistants Surgeon:** Malek A. Al- Omari

**Post-Operative Care:** Mohammad A. Al-Doud, Malek A. Al-Omari, Heba G.Dboush, Ahmad S. Alabbadi, Intithar E. Al- Rahamneh.

**Category 2:**

**Drafting the manuscript:** Mohammad A. Al-Doud, Malek A. Al-Omari

**Revising the manuscript critically for important intellectual content:** Heba G.Dboush, Ahmad S. Alabbadi, Intithar E. Al- Rahamneh.

**Category 3:**

**Approval of the version of the manuscript to be published** (the names of all authors must be listed): Mohammad A. Al-Doud,

Malek A. Al- Omari, Heba G.Dboush, Ahmad S. Alabbadi, Intithar E. Al- Rahamneh.

**Registration of research studies**

The authors don't need to register this work.

**Guarantor**

Dr. Mohammad A. Al-Doud.

**Provenance and peer review**

Not commissioned, externally peer-reviewed.

**References**

- [1] John Marx, Robert Hockberger, Ron Walls, Rosen's Emergency Medicine – Concepts and Clinical Practice, 8th edition, 2013, pp. 1220, 15th August.
- [2] David E. Beck, Steven D. Wexner, Janice F. Rafferty, Gordon and Nivatvongs' Principles and Practice of Surgery for the Colon, Rectum, and Anus, Fourth edition 4, 2018, pp. 678–692, December. *Volvulus of the Colon*.
- [3] V. Raveenthiran, T.E. Madiba, S.S. Atamanalp, U. De, *Volvulus of the sigmoid colon*, *Colorectal Dis.* 12 (2010) e1–e17, 7 Online.
- [4] R.A. Agha, M.R. Borrelli, R. Farwana, K. Koshy, A. Fowler, D.P. Orgill, For theSCARE Group, The SCARE 2018 statement: updating consensus Surgical Case Report (SCARE) guidelines, *Int. J. Surg.* (60) (2018) 132–136.
- [5] Charles Yeo, Chapter 73: *Volvulus of the stomach and small bowel*: page 851 and Chapter 155: *colonic intussusception and Volvulus*: page 1808–1813, in: *Shackelford's Surgery of the Alimentary Tract*, 8th edition, 2018, 16th February.
- [6] Dorland, *Dorland's Illustrated Medical Dictionary*, 32nd edition, 2011, pp. 2071, 2nd May.
- [7] K.B. Kallio, *Uber volvulus coli transversii*, *Acta Chir. Scand.* 70 (1932) 39–58.
- [8] Rupen Dattani, Ridzuan Farouk (Eds.), *Principles of Surgery Vivas for the MRCS*, Cambridge University Press, 2010, p. 166, March 11.
- [9] Robert B. Lim, Daniel B. Jones, *General Surgery Examination and Board Review*, McGraw Hill Professional, 2016, pp. 154, Jun 22.
- [10] F. Charles Brunnicardi, et al., Chapter 29: *Colon, rectum, and anus*, in: *Schwartz's Principles of Surgery*, 10e eds., McGraw-Hill, 2016, pp. 1220.
- [11] D.A. Sparks, M.Y. Dawood, D.M. Chase, et al., *Ischemic volvulus of the transverse colon: a case report and review of literature*, *Cases J.* 1 (2008) 174.
- [12] K.A.C. Booi, P.J. Tanis, T.M. Van Gulik, D.J. Gouma, *Recurrent volvulus of the transverse colon after sigmoid resection*, *Int. J. Colorectal Dis.* 24 (Apr. (4)) (2009) 471–472.

**Open Access**

This article is published Open Access at [sciencedirect.com](https://www.sciencedirect.com). It is distributed under the [IJSCR Supplemental terms and conditions](#), which permits unrestricted non commercial use, distribution, and reproduction in any medium, provided the original authors and source are credited.