

# Application of a Minimally Invasive Liposuction Technique for Harvesting Fat during Transsphenoidal Surgery: A Technical Note

Yuichi FUJITA,<sup>1</sup> Masaaki TANIGUCHI,<sup>1</sup> Takashi TSUZUKI,<sup>2</sup> Tomoaki NAKAI,<sup>1</sup>  
Yoichi UOZUMI,<sup>1</sup> Hidehito KIMURA,<sup>1</sup> and Eiji KOHMURA<sup>1</sup>

<sup>1</sup>Department of Neurosurgery, Kobe University Graduate School of Medicine,  
Kobe, Hyogo, Japan;

<sup>2</sup>Department of Neurosurgery, Yao Municipal Hospital, Yao, Osaka, Japan

## Abstract

Secure reconstruction in transsphenoidal surgery (TSS) is important for the prevention of the major and serious complication of postoperative cerebrospinal fluid (CSF) leak. Although abdominal fat can be safely and effectively used as a reconstruction tissue, harvesting it from the abdominal wall is traumatic and invasive, resulting in cosmetic problems. In this report, we present a method of harvesting abdominal fat using a minimally invasive liposuction technique to avoid cosmetic issues. Since 2016, we have been using fat harvested from the abdominal wall by suctioning with a dedicated syringe for reconstruction after TSS in selected cases. The liquefied fat obtained by the liposuction technique was wrapped with an oxycellulose sheet and changed its form to what we termed “fatty candy”. In this form, the fat maintained its configuration and could be handled almost as easily as a conventional fat graft. In our experienced series, there was no case with wound complication nor postoperative or late-onset CSF leak during a postoperative follow-up of at least 3 months. The fat harvested by this simple and minimally invasive liposuction technique can be expected to provide an autologous graft that is adequate not only for prevention of cosmetic problems but also for prevention of postoperative CSF leak.

Key words: cerebrospinal fluid, rhinorrhea, fat graft, pituitary adenoma, transsphenoidal surgery

## Introduction

Transsphenoidal surgery (TSS) is the standard operative approach for pituitary and parasellar lesions. Although TSS is a safe procedure with a mortality rate of less than 1%,<sup>1)</sup> postoperative cerebrospinal fluid (CSF) leak remains a serious complication.<sup>1–7)</sup> The CSF leak rate after TSS for pituitary adenoma has consistently been reported to be up to 5%.<sup>1–3,8–10)</sup> Furthermore, bacterial meningitis after TSS is reported to occur at a rate of 0.7–14% and to be closely associated with the incidence of postoperative CSF leak, and can lead to significant disability.<sup>1,9,11)</sup> Therefore, a reconstruction method that prevents postoperative CSF leak after TSS remains an important issue.

Use of a fat graft to pack the sella and paranasal sinus after TSS was first described by Collins in 1974.<sup>12)</sup>

By the late 1970s, there were several reports by Tindall et al.<sup>13–15)</sup> of the fat used in TSS being harvested from the abdominal wall instead of the thigh. However, although fat from the abdomen has been used safely and effectively since then, an additional skin incision in the abdomen is unavoidable and causes cosmetic issues.<sup>7,16)</sup>

To solve this problem, we have been using the liposuction technique used in plastic surgery to harvest abdominal fat for use in TSS and achieved good results in terms of preventing not only wound complication including cosmetic complaints but also postoperative CSF leak. Here we present the details of this technique and our results using it in TSS.

## Surgical Technique

Intraoperative CSF leak was evaluated according to the grading system devised by Esposito et al.<sup>8)</sup> (grade 0, no leak observed; grade 1, small weeping CSF leak confirmed by Valsalva maneuver without a visible diaphragmatic defect; grade 2, moderate

Received November 9, 2018; Accepted December 27, 2018

Copyright© 2019 by The Japan Neurosurgical Society  
This work is licensed under a Creative Commons Attribution-NonCommercial-NoDerivatives International License.

leak with definite diaphragmatic defect; grade 3, large diaphragmatic and/or dural defect created as part of a suprasellar or transclival extended TSS). To assess an intraoperative CSF leak, the Valsalva maneuver and endoscopic observation were performed to help localize occult CSF leak. Abdominal fat harvested by liposuction technique was used in patients with intraoperative CSF leak grades 0–2. The reconstruction protocol in our institution entailed packing the abdominal fat tissue collected by liposuction into the sella, suturing the dura with 6-0 resorbable (polydioxanone monofilament) sutures (PDS, Ethicon, Inc., Somerville, NJ, USA), reconstructing the sellar floor with nasal septal cartilage or bone, repositioning the sphenoid sinus mucosal flap to cover the sellar floor, and finally applying fibrin glue (Beriplast, CSL Behring, King of Prussia, PA, USA) to hold the repair in position. We also utilized a nasal septal mucosal vascularized flap in a limited number of cases where the cavernous portion of the internal carotid artery was widely exposed, necessitating a cover for this vital structure. A lumbar drain was not routinely inserted.

### Liposuction Technique

A dedicated system for liposuction consisting of a harvesting cannula with an outer diameter of 2.1 mm, a 10-mL syringe, and a snap lock (Tulip, Medical U&A, Inc., Osaka) was used in all cases (Fig. 1A). The liposuction procedure includes the following steps. After disinfection and draping that exposes the umbilicus and left side of the abdomen, local anesthesia is injected (Fig. 1B). A small incision about 3 mm in length is then made along the umbilical folds using a sharp-pointed scalpel (Fig. 1C). Next, a Tulip cannula is inserted into the subcutaneous fat layer and moved back and forth while applying negative pressure to aspirate liquefied fat into the syringe. The cannula needs to be moved in all directions to avoid recessed deformation because of excessive suction at a single site. Care is taken not to penetrate the abdominal wall too deeply to avoid injury to the rectus abdominis muscle, perforation of the peritoneum, and intestinal injury (Figs. 1D–1F). Liposuction is considered complete when an adequate volume of liquefied fat has been collected (Fig. 1G). Application of a Steri-Strip is sufficient to close the wound.

The whole procedure can be completed within 5 min. The amount of fat required is determined by using the size of neurosurgical patties in the operative view of endoscope as a reference. Approximately 3–10 mL of liquefied fat is enough to make “fatty

candy” explained in the below section, in most cases, although the exact amount of fat harvested depends on the volume of the tumor cavity.

### Making “Fatty Candy”

Oxycellulose gauze (Surgicel Absorbable Hemostat, Ethicon, Inc., Somerville, NJ, USA) is cut to an appropriate size to wrap sufficient liquefied fat to fill the tumor cavity. Both sides of the wrapped fat are then tied with a 6-0 PDS suture in a shape that resembles “fatty candy”, after which the surplus Surgicel and 6-0 PDS suture are cut (Fig. 1H). This “fatty candy” can be handled in the same manner as a conventionally harvested fat graft and put into the intraoperative CSF leak site.

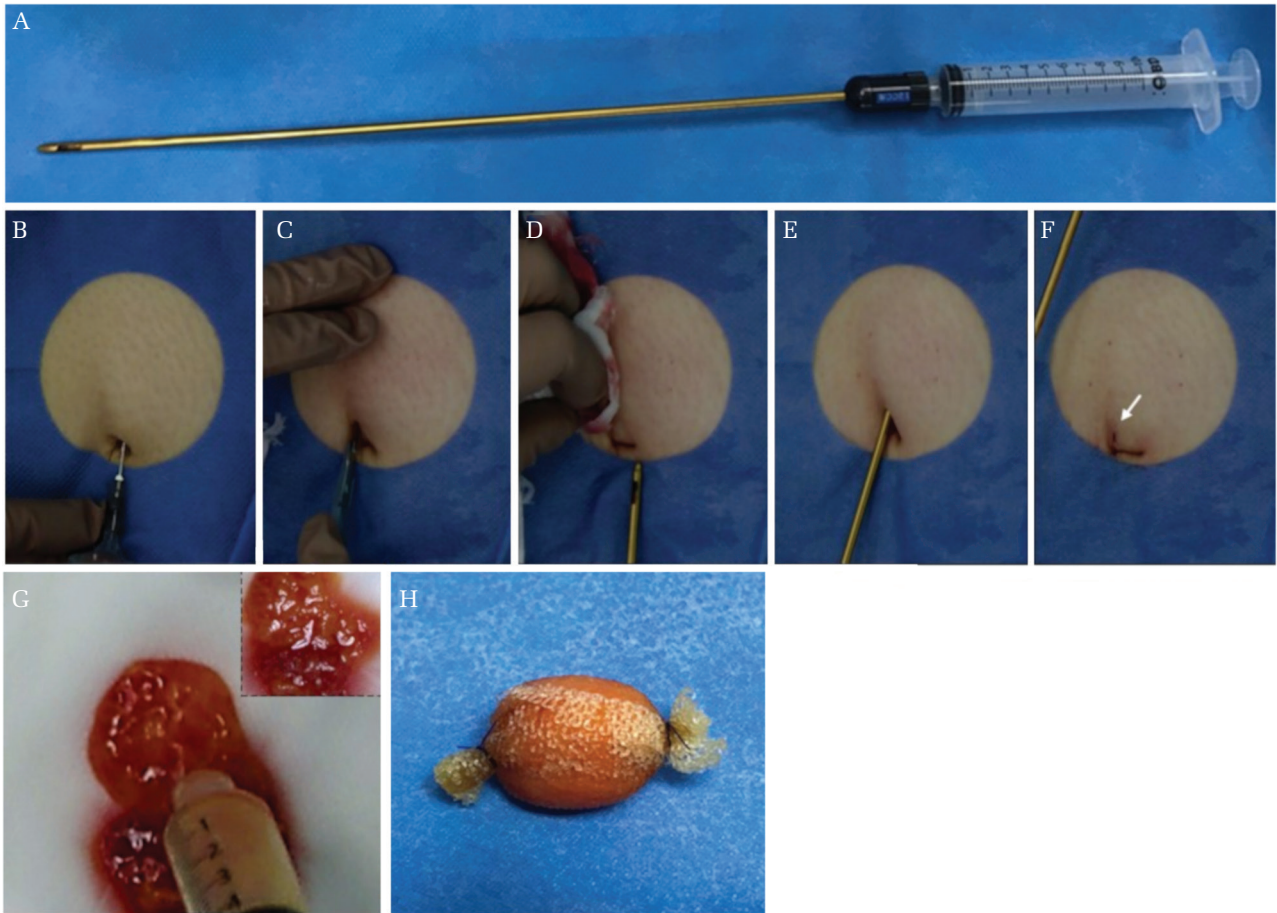
## Case Presentation

### Illustrative case (Case No. 21)

A 58-year-old woman with a history of transcranial surgery for a non-functioning pituitary adenoma presented with a visual field deficit and a recurrence as defined by magnetic resonance image 7 years after the initial operation (Fig. 2H). Endoscopic endonasal TSS was performed and intraoperative CSF leak (grade 2) was detected with a tear of the sellar diaphragm and arachnoid membrane after tumor removal (Fig. 2A). The reconstruction entailed packing of the “fatty candy” containing 3 mL of abdominal fat harvested by liposuction technique into the sella, suturing of the dura of the sellar floor with a 6-0 PDS suture, reconstruction of the sellar floor with nasal septal bone, repositioning of the sphenoid sinus mucosal flap to cover the sellar floor and sealed with fibrin glue (Figs. 2B–2G). Postoperative sagittal T<sub>1</sub>-weighted magnetic resonance images showed the iso-intense solid tumor was replaced by “fatty candy”, which appeared as a hyperintense mass in 1 week later and 3 months later (Figs. 2I–2J). Wound complication including cosmetic complaints in the liposuction site and postoperative CSF leak were not experienced during a postoperative follow-up of 4.8 months.

### Case using “fatty candy” to mainly fill up the dead space (Case No. 17)

A 68-year-old man presented with a visual field deficit and diplopia, and a macroadenoma (Knosp grade 4, non-functioning pituitary adenoma) was detected by magnetic resonance image (Figs. 3A and 3B). Endoscopic endonasal TSS was performed and intraoperative CSF leak (grade 2) was detected. Furthermore, a nasal septal mucosal vascularized flap needed to be utilized since the cavernous portion



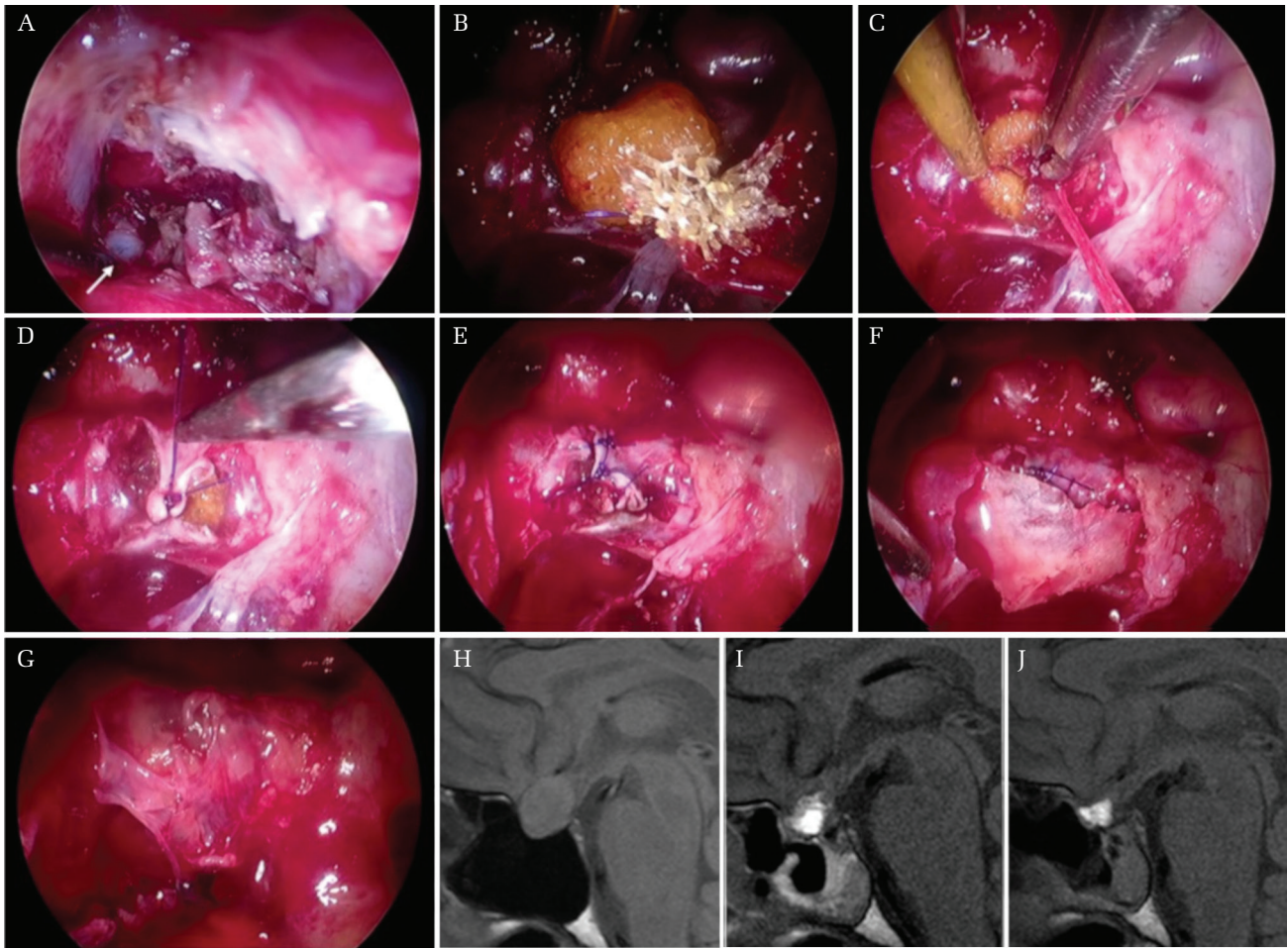
**Fig. 1** Liposuction technique and making the “fatty candy”. (A) A dedicated system for liposuction consisting of a harvesting cannula with an outer diameter of 2.1 mm, a 10-mL syringe and a snap lock (Tulip). (B) Administration of local anesthesia after disinfection and draping to expose the umbilicus and left side of the abdomen. (C) A small incision about 3 mm in length is made along the umbilical folds using a sharp-pointed scalpel. (D) Insertion of the Tulip cannula into the subcutaneous fat layer. (E) The cannula is moved back and forth applying negative pressure to aspirate liquefied fat into the syringe. (F) After the procedure, a barely visible skin incision is left along the umbilical folds (indicated with *white arrow*). (G) The liquefied fat harvested from the abdominal wall by the liposuction technique. (H) Appearance of the “fatty candy”, made by wrapping the liquefied fat with Surgicel Absorbable Hemostat gauze and tying both sides with a 6-0 PDS suture.

of the internal carotid artery was widely exposed. In this case, “fatty candy” was used to fill up the dead space between the sellar floor and the nasal septal mucosal flap in addition to packing into the CSF leak point. The reconstruction entailed packing of the “fatty candy” containing 13 mL of abdominal fat harvested by liposuction technique into the sella and sphenoid sinus, covered with a nasal septal mucosal vascularized flap and sealed with fibrin glue. Postoperative sagittal T<sub>1</sub>-weighted magnetic resonance images showed “fatty candy” as a hyperintense mass in 1 week later (Figs. 3C and 3D). Wound complication including cosmetic complaints in the liposuction site and postoperative CSF leak were not experienced during a postoperative follow-up of 25.6 months.

## Discussion

Although a reconstruction method that prevents postoperative CSF leak after TSS remains an important issue, there is no consensus on the ideal methodology especially in use of a fat graft. Surgeons may usually select their method based on anecdotal evidence, and a multilayered reconstruction with fat graft even in cases which seem to have a low risk of postoperative CSF leak such as grades 0–1 to prevent serious complications whenever possible. One of the crucial problems is that harvesting the abdominal fat using conventional methods is traumatic and invasive, and sometimes causes cosmetic problems such as additional scarring with dimple or keloid formation or postoperative hematoma.<sup>7,16)</sup>

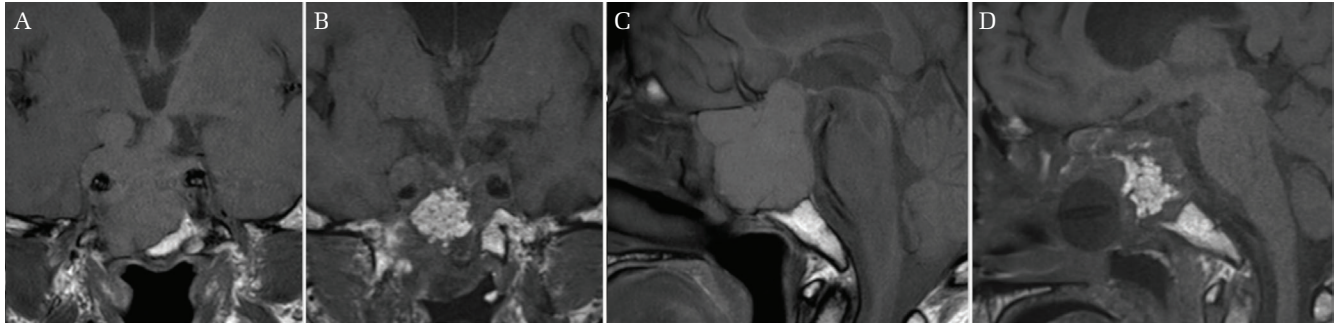




**Fig. 2** Reconstruction protocol using the “fatty candy”. Intraoperative view of endoscopic endonasal transsphenoidal surgery for a recurrent pituitary adenoma in a 58-year-old woman. (A) The *white arrow* shows the cerebrospinal fluid leak point with a tear of the sellar diaphragm and arachnoid membrane after tumor removal. The leak was grade 2. (B and C) Packing of the “fatty candy” containing 3 mL of abdominal fat into the sella. (D and E) Suturing of the dura of the sellar floor with a 6-0 PDS suture. (F) Reconstruction of the sellar floor with nasal septal bone. (G) Repositioning of the sphenoid sinus mucosal flap to cover the sellar floor, sealed with fibrin glue. Preoperative (H) and postoperative (I; 1 week later, J; 3 months later) sagittal T<sub>1</sub>-weighted magnetic resonance images for the same patient. Note the iso-intense solid tumor in (H) is replaced by “fatty candy”, which appears as a hyperintense mass in (I) and (J).

Direct suturing of the dura of the sellar floor,<sup>17)</sup> use of a sphenoid sinus mucosal flap<sup>18)</sup> and a nasal septal mucosal flap,<sup>19)</sup> and use of collagen sponge technique<sup>20)</sup> have been reported as methods to avoid poor cosmetic outcomes. Our liposuction technique introduced in this report is much less invasive, enables abdominal fat to be harvested in a short time, avoids cosmetic problems, and lowers the threshold for use of abdominal fat. Furthermore, to overcome the drawback of the liposuction technique that the collected fat tissue is in a liquefied state and is therefore difficult to handle, we wrapped the fat obtained by the liposuction technique with Surgicel sheet and changed its form to what we termed

“fatty candy”. We have used fat graft harvested from the abdominal wall by liposuction technique and transformed it to “fatty candy” for reconstruction in 21 TSS cases for pituitary adenomas (Table 1). Handling of “fatty candy” was almost the same manner as a conventional fat graft and we could easily carry it into the target place maintaining its configuration with a single stroke in all cases. The amount of liposuction fat was mean of 7 mL (2–14 mL). Although to determine the amount of fat harvested by liposuction and the size of “fatty candy” may require some experience, there is no problem with deciding the size in the same way when a plug of fat is harvested by the conventional



**Fig. 3** “Fatty candy” used in order to mainly fill up the dead space. **A** non-functioning pituitary macroadenoma in a 68-year-old man. Preoperative coronal (A) and sagittal (B) T<sub>1</sub>-weighted magnetic resonance images show the massive, iso-intense and solid tumor extending to the oculomotor cistern and the sphenoid sinus. Postoperative (1 week later) coronal (C) and sagittal (D) T<sub>1</sub>-weighted magnetic resonance images show “fatty candy” as a hyperintense mass between the sella and the nasal septal mucosal flap.

technique. No patient in our series experienced wound complication including cosmetic complaints in the liposuction site during a mean postoperative follow-up of 16.1 (range 3.2–29.5) months.

In addition to minimal invasiveness, a prevention of postoperative CSF leak must be secured. Our use of “fatty candy” harvested by liposuction achieved acceptable results with a 0% failure rate in the prevention of postoperative CSF leak without a lumbar drain. Esposito et al.<sup>8)</sup> reported postoperative CSF leak rates of 1.6% in patients with grades 0–2 leaks and 12% in those with grade 3 leaks. We have used “fatty candy” harvested by liposuction in seven cases with grade 1 and six cases with grade 2. Although the other eight cases were grade 0, the sellar floor was reconstructed with “fatty candy” in a standard manner according to the operator’s judgment because of observation of fragile arachnoid, extensive arachnoid herniation or a large dead space after removal of the tumor. Strickland et al.<sup>21)</sup> reported that 50% of all postoperative CSF leaks developed in patients in whom there was no intraoperative identification of a leak and in whom no sellar floor repair was performed. It is to be noted that postoperative CSF leak is observed even in the case of grade 0 who do not have intraoperative CSF leak findings. The principle of our reconstruction concept is to restore the sellar floor and sphenoid sinus as close as possible to the original anatomic condition, which entails multilayered reconstruction using a combination of several autologous grafts rather than a single graft. Multilayered reconstruction also has the advantage of ensuring prevention of postoperative CSF leak. The use of “fatty candy” harvested by this liposuction technique effectively achieves this aim.

In our experienced series, use of abdominal fat harvested in the form of “fatty candy” by the liposuction technique is considered as an effective method not only for the prevention of wound complication but also for the prevention and repair of at least grades 0–2 intraoperative CSF leak in patients undergoing TSS. On the other hand, for repair of a large dural defect after extended TSS or if the intraoperative CSF leak is grade 3, the effectiveness of “fatty candy” by the liposuction technique regarding prevention of postoperative CSF leak is unclear because we have no experience in the case with grade 3 leak. In such a situation, we recommend a plug of fat harvested by the conventional technique as a more suitable graft. Further studies are needed to verify the effectiveness and limitation of “fatty candy” by the liposuction technique in terms of prevention of postoperative CSF leak, not cosmetic problems.

In conclusion, our liposuction technique for harvesting an abdominal fat graft is a simple and minimally invasive procedure with good cosmetic results. The “fatty candy” made by wrapping the liquified fat obtained using this liposuction technique can be expected to serve as an autologous graft that can prevent CSF leak.

### Conflicts of Interest Disclosure

The authors report no conflicts of interest concerning the materials or methods used in this study or the findings reported in this paper. All authors who are members of The Japan Neurosurgical Society (JNS) have registered online self-COI Disclosure Statement Forms through the website for JNS members.

Table 1 Patient characteristics with pituitary adenomas treated by TSS with the liposuction technique

Case no.	Age	Sex	Pathological diagnosis	Size macro/micro	Knosp grade	Approach	TSS times (times)	Intraoperative CSF leak grade	Amount of liposuction fat (mL)	Multilayered reconstruction	Lumbar CSF diversion	Postoperative		Abdominal wound complication
												CSF leak	Cosmetic complains	
1	64	F	GH-secreting	Micro	1	EETSS	Primary	0	2	+	-	No	No	No
2	63	M	Non-functioning	Macro	2	EETSS	Primary	0	10	+	-	No	No	No
3	73	M	Non-functioning	Macro	3	EETSS	Primary	0	9	+	-	No	No	No
4	57	F	Non-functioning	Macro	4	EETSS	Repeated (2)	0	6	+	-	No	No	No
5	19	F	PRL-secreting	Macro	1	EETSS	Primary	0	5	+	-	No	No	No
6	75	M	Non-functioning	Macro	3	EETSS	Primary	0	6	+	-	No	No	No
7	45	M	Non-functioning	Macro	3	EETSS	Primary	0	14	+	-	No	No	No
8	40	F	Non-functioning	Macro	2	EETSS	Primary	0	9	+	-	No	No	No
9	15	F	PRL-secreting	Macro	1	EETSS	Primary	1	3	+	-	No	No	No
10	46	M	Non-functioning	Macro	1	EETSS	Primary	1	2	-	-	No	No	No
11	41	F	GH, PRL-secreting	Macro	3	EETSS	Repeated (2)	1	8	+	-	No	No	No
12	54	M	Non-functioning	Macro	3	EETSS	Primary	1	9	+	-	No	No	No
13	45	M	Non-functioning	Macro	2	EETSS	Primary	1	2	+	-	No	No	No
14	69	M	Non-functioning	Macro	3	EETSS	Primary	1	4	+	-	No	No	No
15	62	M	Non-functioning	Macro	4	EETSS	Primary	1	11	+	-	No	No	No
16	42	F	ACTH-secreting	Macro	1	EETSS	Primary	2	2	+	-	No	No	No
17	68	M	Non-functioning	Macro	4	EETSS	Primary	2	13	+	-	No	No	No
18	38	F	Non-functioning	Macro	4	EETSS	Primary	2	8	+	-	No	No	No
19	60	F	Non-functioning	Macro	2	EETSS	Primary	2	9	+	-	No	No	No
20	31	F	Non-functioning	Macro	3	EETSS	Repeated (3)	2	7	+	-	No	No	No
21	58	F	Non-functioning	Macro	2	EETSS	Primary	2	3	+	-	No	No	No

ACTH: adrenocorticotroph hormone, CSF: cerebrospinal fluid, EETSS: endoscopic endonasal transsphenoidal surgery, F: female, GH: growth hormone, M: male, PRL: prolactin, TSS: transsphenoidal surgery.



## References

- 1) Ciric I, Ragin A, Baumgartner C, Pierce D: Complications of transsphenoidal surgery: results of a national survey, review of the literature, and personal experience. *Neurosurgery* 40: 225–236; discussion 236–237, 1997
- 2) Berker M, Hazer DB, Yücel T, et al.: Complications of endoscopic surgery of the pituitary adenomas: analysis of 570 patients and review of the literature. *Pituitary* 15: 288–300, 2012
- 3) Cappabianca P, Cavallo LM, Esposito F, Valente V, De Divitiis E: Sellar repair in endoscopic endonasal transsphenoidal surgery: results of 170 cases. *Neurosurgery* 51: 1365–1371; discussion 1371–1372, 2002
- 4) Charalampaki P, Ayyad A, Kockro RA, Perneczky A: Surgical complications after endoscopic transsphenoidal pituitary surgery. *J Clin Neurosci* 16: 786–789, 2009
- 5) Gondim JA, Almeida JP, Albuquerque LA, et al.: Endoscopic endonasal approach for pituitary adenoma: surgical complications in 301 patients. *Pituitary* 14: 174–183, 2011
- 6) Kassam AB, Prevedello DM, Carrau RL, et al.: Endoscopic endonasal skull base surgery: analysis of complications in the authors' initial 800 patients. *J Neurosurg* 114: 1544–1568, 2011
- 7) Kaptain GJ, Kanter AS, Hamilton DK, Laws ER: Management and implications of intraoperative cerebrospinal fluid leak in transnasoseptal transsphenoidal microsurgery. *Neurosurgery* 68: 144–150; discussion 150–151, 2011
- 8) Esposito F, Dusick JR, Fatemi N, Kelly DF: Graded repair of cranial base defects and cerebrospinal fluid leaks in transsphenoidal surgery. *Neurosurgery* 60: 295–303; discussion 304, 2007
- 9) Cappabianca P, Cavallo LM, Colao A, de Divitiis E: Surgical complications associated with the endoscopic endonasal transsphenoidal approach for pituitary adenomas. *J Neurosurg* 97: 293–298, 2002
- 10) Nishioka H, Haraoka J, Ikeda Y: Risk factors of cerebrospinal fluid rhinorrhea following transsphenoidal surgery. *Acta Neurochir (Wien)* 147: 1163–1166, 2005
- 11) Kaptain GJ, Vincent DA, Sheehan JP, Laws ER: Transsphenoidal approaches for the extracapsular resection of midline suprasellar and anterior cranial base lesions. *Neurosurgery* 49: 94–100; discussion 100–101, 2001
- 12) Collins WF: Hypophysectomy: historical and personal perspective. *Clin Neurosurg* 21: 68–78, 1974
- 13) Tindall GT, McLanahan CS, Christy JH: Transsphenoidal microsurgery for pituitary tumors associated with hyperprolactinemia. *J Neurosurg* 48: 849–860, 1978
- 14) Tindall GT, McLanahan CS, Christy JH: Transsphenoidal microsurgery for pituitary tumors. *J Med Assoc Ga* 66: 951–957, 1977
- 15) Tindall GT, Ambrose SS, Christy JH: Hypophysectomy in the treatment of disseminated carcinoma of the breast and prostate gland. *J Med Assoc Ga* 64: 69–74, 1975
- 16) Couldwell WT, Kan P, Weiss MH: Simple closure following transsphenoidal surgery. Technical note. *Neurosurg Focus* 20: E11, 2006
- 17) Nishioka H, Izawa H, Ikeda Y, Namatame H, Fukami S, Haraoka J: Dural suturing for repair of cerebrospinal fluid leak in transnasal transsphenoidal surgery. *Acta Neurochir (Wien)* 151: 1427–1430, 2009
- 18) Amano K, Hori T, Kawamata T, Okada Y: Repair and prevention of cerebrospinal fluid leakage in transsphenoidal surgery: a sphenoid sinus mucosa technique. *Neurosurg Rev* 39: 123–131, 2016
- 19) Kassam AB, Thomas A, Carrau RL, et al.: Endoscopic reconstruction of the cranial base using a pedicled nasoseptal flap. *Neurosurgery* 63: ONS44–ONS52; discussion ONS52–ONS53, 2008
- 20) Kelly DF, Oskouian RJ, Fineman I: Collagen sponge repair of small cerebrospinal fluid leaks obviates tissue grafts and cerebrospinal fluid diversion after pituitary surgery. *Neurosurgery* 49: 885–889; discussion 889–890, 2001
- 21) Strickland BA, Lucas J, Harris B, et al.: Identification and repair of intraoperative cerebrospinal fluid leaks in endonasal transsphenoidal pituitary surgery: surgical experience in a series of 1002 patients. *J Neurosurg* 129: 425–429, 2018

---

Address reprint requests to: Masaaki Taniguchi, MD, PhD, Department of Neurosurgery, Kobe University Graduate School of Medicine, 7-5-1 Kusunoki-cho, Chuo-ku, Kobe, Hyogo 650-0017, Japan.  
e-mail: mtani@med.kobe-u.ac.jp