

# Oxygen Venous Embolism After Hydrogen Peroxide Use During Percutaneous Nephrolithotomy

John Michael DiBianco, MD, Jessica Lange, MD, Daniel Heidenberg, MD, and Patrick Mufarrij, MD

## Abstract

**Background:** Hydrogen peroxide ( $H_2O_2$ ) is a common antiseptic that is available without a prescription in the United States, and it is indicated for minor dermal abrasion; mouth, gum, or dental irritations; and removal of oral secretion. Several other medical uses have also been described, including clot dissolution during endoscopic gastrointestinal evaluation, cleansing of orthopedic surgical sites, and bladder irrigation. However, these uses of  $H_2O_2$ , as well as high-dose ingestion, have been associated with a wide variety of medical complications, including but not limited to air pulmonary embolism and stroke.

**Case Presentation:** Our patient is a 51-year-old female with a medical history of hypertension, familial hypercholesterolemia, gallstones, depression, coronary artery disease (identified on calcium study because of familial hypercholesterolemia), nephrolithiasis, and recurrent cystitis. She required percutaneous nephrolithotomy and had  $H_2O_2$  administered for clot dissolution. The clinical and temporal evidence would suggest a transient pulmonary air embolus after the intrarenal administration of or irrigation with  $H_2O_2$ , large amounts under high pressure.

**Conclusion:** This represents the first reported incidence of air embolus as a result of intrarenal administration of  $H_2O_2$ .

**Keywords:** nephrolithiasis, percutaneous nephrolithotomy, oxygen pulmonary embolus, hydrogen peroxide

## Introduction

**H**YDROGEN PEROXIDE ( $H_2O_2$ ) is a common antiseptic that is available without a prescription in the United States, and it is indicated for minor dermal abrasion; mouth, gum, or dental irritations; and removal of oral secretion.<sup>1</sup> Its mechanism of action involves the release of oxygen and water upon tissue contact. The complications of these uses are minor and mostly include pain on administration and irritation to areas of administration.<sup>1</sup>

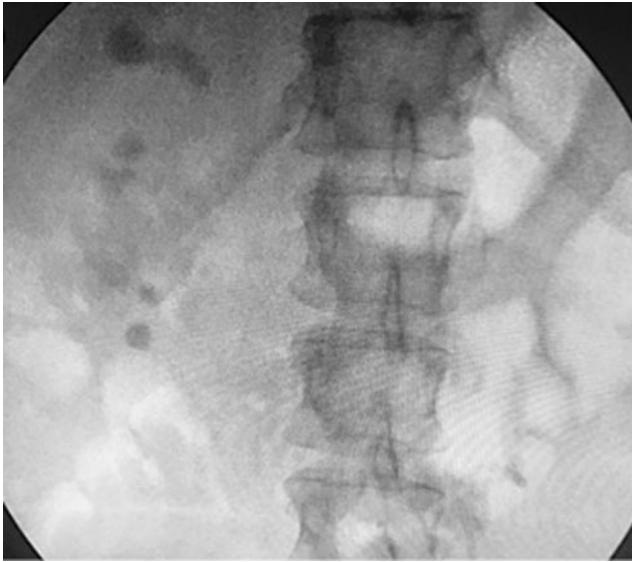
Several other medical uses have also been described, including clot dissolution during endoscopic gastrointestinal evaluation, cleansing of orthopedic surgical sites, and bladder irrigation. However, these uses of  $H_2O_2$ , as well as high-dose ingestion, have been associated with a wide variety of medical complications, including but not limited to air pulmonary embolism and stroke.<sup>2–5</sup>

## Case Report

Our patient is a 51-year-old female with a medical history of hypertension, familial hypercholesterolemia, gallstones, depression, coronary artery disease (identified on calcium study because of familial hypercholesterolemia), nephrolithiasis, and recurrent cystitis. Her first stone event was in 2008 that subsequently required ureteroscopy (URS) and ureteral stent placement. She presented to our outpatient clinic initially in consultation for left-sided abdominal pain, and subsequent CT scan revealed nephrolithiasis with three separate left ureteral stones (Fig. 1), requiring urgent ureteral stent placement.

After urgent decompression with a stent, she was scheduled for bilateral URS with laser lithotripsy (LL) and possible bilateral percutaneous nephrolithotomy (PCNL) for definitive stone management. She ultimately underwent bilateral


<sup>1</sup>Department of Urology, George Washington University Medical School, Washington, District of Columbia.



**FIG. 1.** Preoperative stone burden.

URS with LL and right-sided PCNL. Postoperative CT scan revealed residual right-sided stone burden, so she was scheduled for a second stage right-sided PCNL. In the interim, her postoperative course was complicated by gross hematuria and anemia, requiring transfusion of 2 U of packed red blood cells.

During her planned second stage PCNL, initial ureteroscopic observation was very poor because of extensive clot burden in the right renal pelvis and calices (Fig. 2). Three percent  $H_2O_2$  standard preparation was diluted three times and  $\sim 100$  mL was instilled using a 60 mL Toomey syringe through the current indwelling 22 Council nephrostomy tube to dissolve the extensive clot burden and improve observation. Approximately 45 seconds after instillation, the anesthesiologist noted that the patient's end tidal carbon dioxide ( $CO_2$ ) had suddenly plummeted (0–9) and she had become hypotensive. ST segment elevation was also noted on the telemetry tracings that were a change from her preoperative electrocardiogram. Owing to immediate concern for pulmonary embolus, the procedure was terminated, and the patient was taken out of dorsal lithotomy position and placed in the supine position. The patient's blood pressure increased over the next several minutes, and she became hemodynamically stable; however, her end tidal  $CO_2$  remained well below



**FIG. 2.** Poor intraoperative observation.

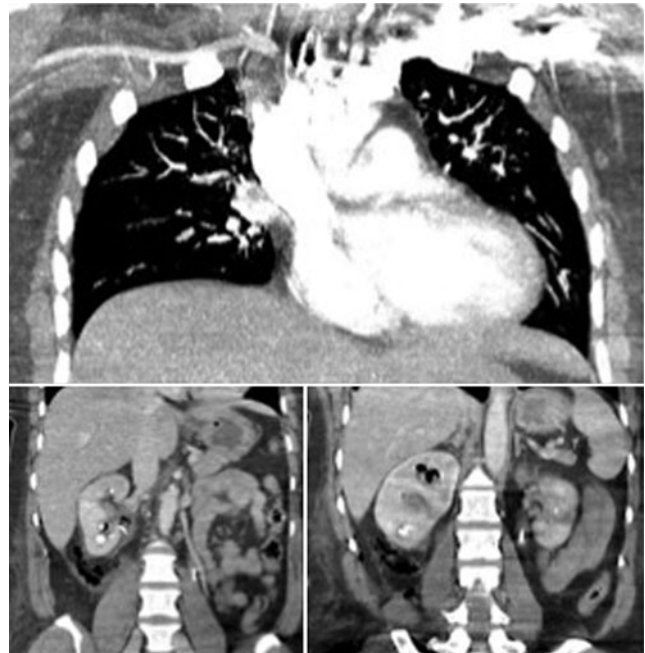
normal. She was immediately transferred from the operating room to radiology for emergent CT angiography (CTA). At the time of CTA, the patient's end tidal  $CO_2$  had risen to 30 to 40. Ultimately the CTA revealed no evidence of pulmonary thrombus; however, abdominal follow-through was notable for extensive air in the right renal collecting system (Fig. 3). The patient was transferred back to the operating room, extubated, and brought to postanesthesia care unit for intensivist consultation without complication. She demonstrated stability and returned to her inpatient floor. She recovered well without evidence of residual effects. Three days later, she underwent her final stage procedure to render her stone free without complications. Final postoperative CT after third stage procedure revealed no residual stones bilaterally.

### Discussion

Intraoperative pulmonary embolus is hallmarked by rapid respiratory distress, fall in end tidal  $CO_2$ , and possible hemodynamic instability, depending on the size of the embolus. It is estimated that detrimental effects of venous gas embolism are determined by the total volume of air injected as well as the rate of injection and the final location of the air embolus in the pulmonary arterial tree. It is estimated that 300 to 500 mL of gas introduced at a rate of 100 mL/sec can be acutely fatal for humans.<sup>6</sup>

The clinical and temporal evidence in this case would suggest a transient pulmonary air embolus after the intrarenal administration of  $H_2O_2$ . It is not known whether  $H_2O_2$  administration through an indwelling nephrostomy tube during URS can produce these levels of intravascular gas. A thorough search of the available literature did not reveal any prior reports of this phenomenon; therefore, we believe we have presented the first case here. Given the patient's persistent hematuria and anemia, it is likely that she had increased intravascular  $H_2O_2$ .

Studies suggest that excessive  $H_2O_2$  under pressure may result in peroxynitrite production that vascular endothelium



**FIG. 3.** Intraoperative CT angiography.

cannot metabolize rapidly, resulting in its disruption and subsequent air embolism.<sup>2</sup> Case reports demonstrate that intraoperative usage of H<sub>2</sub>O<sub>2</sub> for spinal, gastroenterology, and neurosurgical surgeries have resulted in venous air embolism with metabolic disturbances. These typically involve the use of copious amounts of H<sub>2</sub>O<sub>2</sub>.<sup>4</sup> There is even a risk of air embolism with H<sub>2</sub>O<sub>2</sub> injection.<sup>3</sup>

In general, if an intraoperative air embolus is suspected, assessment for air stability and vascular access is of the utmost priority. At the same time, the patient should be positioned in the left lateral decubitus position (Durant's maneuver) with or without head down to avoid further embolization. Next, attention should be turned to determining hemodynamic stability.<sup>6,7</sup> Hemodynamically stable patients without end organ damage can be treated with high-flow oxygen and repositioning, whereas hemodynamically unstable patients require more aggressive treatment.<sup>7</sup> Central venous access should be obtained in those in whom peripheral access cannot be obtained, and in those who need infusions of large volumes of fluids, infusion of vasopressors, and/or frequent blood draws. Additional treatments include hyperbaric oxygen, withdrawal of air from the right atrium, and cardiac massage in extreme cases.<sup>6,7</sup>

We believe that the intraoperative instability and clinical decompensation along with drop in end tidal CO<sub>2</sub> in our case likely resulted from transient intraoperative usage of H<sub>2</sub>O<sub>2</sub> with moderate irrigating force in a closed cavity. In addition, given the patient's preoperative evidence of hemorrhage, she may have had an increased risk of venous backflow. We consider our experience in addition to the literature to date as adequate evidence for advising caution when considering its use during urologic procedures.

## Conclusion

The clinical and temporal evidence would suggest a transient pulmonary air embolus after the intrarenal administration of or irrigation with H<sub>2</sub>O<sub>2</sub>, large amounts under high pressure. This represents the first reported incidence of air embolus as a result of intrarenal administration of H<sub>2</sub>O<sub>2</sub>.

## Disclosure Statement

No authors have any conflicts of interest or relevant financial disclosure to report.

## References

1. 3% Hydrogen Peroxide Spray [prescribing information]: Deerfield, IL: Walgreen Co., 2015. Available at: <https://www.walgreens.com/store/c/walgreens-hydrogen-peroxide-3-topical->

2. solution-usp-spray/ID=prod6376461-product (accessed September 5, 2018).
3. Mut M, Yemisci M, Gursoy-Ozdemir Y, Ture U. Hydrogen peroxide-induced stroke: Elucidation of the mechanism in vivo. *J Neurosurg* 2009;110:94–100.
4. Food and Drug Administration (FDA). FDA Warns Consumers Against Drinking High-Strength Hydrogen Peroxide for Medicinal Use. Ingestion can lead to serious health risks and death. 2006. Science Daily. Available at: [www.science.dailly.com/releases/2006/07/060730134156.htm](http://www.science.dailly.com/releases/2006/07/060730134156.htm) (accessed September 5, 2018).
5. Berlot G, Rinaldi A, Moscheni M, Ferluga M, Rossini P. Uncommon occurrences of air embolism: Description of cases and review of the literature. *Case Rep Crit Care* 2018; 2018:5808390.
6. Patankar PS, Joshi SS, Choudhari KA. Air-embolism and cerebral ischaemia following epidural hydrogen peroxide irrigation in a closed lumbar cavity. *Br J Neurosurg* 2014;28: 556–558.
7. Jorens PG, Van Marck E, Snoeckx A, Parizel PM. Non-thrombotic pulmonary embolism. *Eur Respir J* 2009;34:452–474.
8. Shaikh N, Ummunisa F. Acute management of vascular air embolism. *J Emerg Trauma Shock* 2009;2:180–185.

Address correspondence to:  
 John Michael DiBianco, MD  
 Department of Urology  
 George Washington University Medical School  
 2300 Eye Street, NW - Ross Hall  
 Washington, DC 20037  
 E-mail: [drjmdibianco@gmail.com](mailto:drjmdibianco@gmail.com)

### Abbreviations Used

CT = computed tomography  
 CTA = CT angiography  
 CO<sub>2</sub> = carbon dioxide  
 H<sub>2</sub>O<sub>2</sub> = hydrogen peroxide  
 LL = laser lithotripsy  
 PCNL = percutaneous nephrolithotomy  
 URS = ureteroscopy

**Cite this article as:** DiBianco JM, Lange J, Heidenberg D, Mufarrrij P (2019) Oxygen venous embolism after hydrogen peroxide use during percutaneous nephrolithotomy, *Journal of Endourology Case Reports* 5:1, 25–27, DOI: 10.1089/jcren.2018.0111.