

Available online at [www.sciencedirect.com](http://www.sciencedirect.com)

ScienceDirect

journal homepage: [www.elsevier.com/locate/radcr](http://www.elsevier.com/locate/radcr)

## Case Report

# Pyocolpos: A rare cause of recurrent abdominal pain - Always insist on a thorough physical examination ☆☆☆

Jad A. Degheili, MD<sup>a,#</sup>, Mohamed Khaled, MD<sup>b,#</sup>, Taieb Chouikh, MD<sup>c</sup>, Bilal Aoun, MD<sup>b,d,\*</sup>

<sup>a</sup> Division of Pediatric Urology, Department of Surgery, Children's Hospital of Eastern Ontario, University of Ottawa, Ontario, Canada

<sup>b</sup> Department of Pediatrics and Neonatology, Intercommunal Hospital Group Le Raincy Montfermeil, Montfermeil, France

<sup>c</sup> Department of visceral, vascular and urological surgery, Intercommunal Hospital Group Le Raincy Montfermeil, Montfermeil, France

<sup>d</sup> Division of Pediatric Nephrology, Department of Pediatrics and Adolescent Medicine, American University of Beirut Medical Center, Beirut, Lebanon

## ARTICLE INFO

## Article history:

Received 5 February 2022

Revised 15 February 2022

Accepted 19 February 2022

## Keywords:

Hydrocolpos

Pyocolpos

Abdominal pain

Imperforate hymen

Vaginal atresia

## ABSTRACT

Thorough physical examination is a must for proper diagnosis of medical diseases and to elucidate all physical findings. Abdominal pain is a very common presentation to Emergency Department, compromising 5%-10% of all visits, and around a quarter are discharged with no particular diagnosis. Pyocolpos is one of those presentations that requires a thorough physical examination, including that of the external genitalia. A 3-year-old girl presented with recurrent history of abdominal pain and a recent history of fever with acute abdomen picture-like presentation, with difficulty voiding over the past few days. She was previously assessed for recurrent abdominal pain, without any identifiable etiology. Upon inspection for indwelling catheter insertion, absence of the vaginal introitus was noted with a bulging mass and an imperforate hymen. Pyocolpos was diagnosed and drained following hymenotomy. Pyocolpos is a rare complication of hydrocolpos. Enlarged vagina causes extrinsic compression to nearby structures, such as the bladder trigone and ureters, causing hydronephrosis, hydroureter, and other sequel including acute kidney injury and urosepsis. An imperforate hymen must be considered in the differential for chronic and recurrent abdominal pain, and can be easily identified by a thorough physical examination, including that of the external genitalia, which is a must in today's every medical practice.

© 2022 The Authors. Published by Elsevier Inc. on behalf of University of Washington.

This is an open access article under the CC BY-NC-ND license

(<http://creativecommons.org/licenses/by-nc-nd/4.0/>)

☆ Acknowledgments: The authors declare that they have no relevant financial interests.

☆☆ Declaration of Competing Interest: The authors declared no conflict of interest.

\* Corresponding author.

E-mail addresses: [jdegheili@gmail.com](mailto:jdegheili@gmail.com) (J.A. Degheili), [ba69@aub.edu.lb](mailto:ba69@aub.edu.lb) (B. Aoun).

# Dr. Degheili and Dr. Khaled have contributed equally to this manuscript; thus both qualify as first authors.

<https://doi.org/10.1016/j.radcr.2022.02.051>

1930-0433/© 2022 The Authors. Published by Elsevier Inc. on behalf of University of Washington. This is an open access article under the CC BY-NC-ND license (<http://creativecommons.org/licenses/by-nc-nd/4.0/>)

---

## Introduction

Recurrent abdominal pain is a common problem in pediatric population, defined by at least 3 episodes of abdominal pain (AP) over at least 3 months interval, leading to activity limitation on some occasions [1]. Despite being occasionally self-limited, AP in pediatric patients has been a challenge for health care providers, in general, due to the nonspecific nature of symptoms, relative to patient's age and gender. Approximately, 5%-10% of pediatric emergency visits are due to AP [2]. Initial assessment should focus to differentiate a surgical abdomen requiring immediate intervention versus a non-surgical one.

Despite the frequent use of laboratory tests and imaging studies, still a thorough physical exam is a must as the primary key in diagnosing abdominal pain. Unfortunately, the genital examination is frequently missed leading to delay or even a missed diagnosis. Among such missed physical findings is an imperforate hymen. The latter is the cornerstone for forming a hydrocolpos which can become a pyocolpos, with further serious sequel. What follows, is a report of a 3-year-old female, with an imperforate hymen and pyocolpos, presenting to the Emergency Department with chronic abdominal pain and picture of an acute abdomen. Further management is also highlighted.

---

## Case report

A 3-year-old girl presented to the Emergency Room of our tertiary hospital for abdominal pain and high grade fever (~40°C) of 1 week duration associated with several episodes of non-projectile non bilious vomiting and dysuria. She was transferred from a local hospital, suspecting a surgical abdomen, based on her clinical presentation and lack of General Surgery service over there. Parents had reported an increase in intensity of the abdominal pain over the last 4 days with difficulty voiding since 48 hours. The patient has no significant past medical history, except for recurrent episodes of abdominal pain requiring consultation with the primary physician, without any identified etiology.

Physical examination showed a well-oriented kid with stable vital signs: temperature of 40°C, blood pressure of 110/70 mmHg, and a heart rate of 120 pulse/minute. Upon palpation, abdominal distension was noted, with a palpable tender mass within the infra-umbilical region.

Laboratory testing showed a peripheral leucocyte count of 14,000/mm<sup>3</sup> with a differential count of 8.6 and 3.48, for neutrophils and lymphocytes, respectively. C-reactive protein was 135 mg/dL (Reference range: ≤5), and a Procalcitonin level of 0.20 (Reference range: ≤0.50). The serum chemistry was normal with a serum creatinine of 18 μmole/L. Considering high grade fever for 7 days, viral serologies were done, including Epstein-bar virus, Cytomegalovirus and Covid PCR, and all came back as negative.

An ultrasound of the abdomen and pelvis was then performed and revealed a cystic mass in the infra-umbilical region, measuring 147×74×67 mm (Fig. 1). For better delineation

of this mass and other intra-abdominal abnormalities, a low-dose Computed Tomography (CT) scan of the abdomen and pelvis showed again a large fluid-filled mass posterior to the bladder, and displacing it anteriorly (Fig. 2). The large mass was in fact an enlarged vagina, consistent with a hydrocolpos. No hydronephrosis or hydroureter noted.

Upon inspecting the genital area for the purpose of an indwelling catheter insertion, absence of the vaginal introitus was noted with a bulging mass and an imperforate hymen. Given the constellation of clinical, laboratory and radiological findings, a pyocolpos was suspected.

Patient was brought to the operating table and drainage of the pyocolpos was performed, draining around 400 cc of pus, followed by a hymenoplasty. No intraoperative complications were encountered. The pus culture grew *Proteus Mirabilis*. Patient was treated with IV antibiotics. Clinical improvement was noted, and patient was shifted to oral antibiotics, on post-op day 2 upon discharge. MRI of the abdomen and pelvis was performed a week later and no uterine or vaginal congenital abnormalities could be noted, including absence of fistulous tract.

---

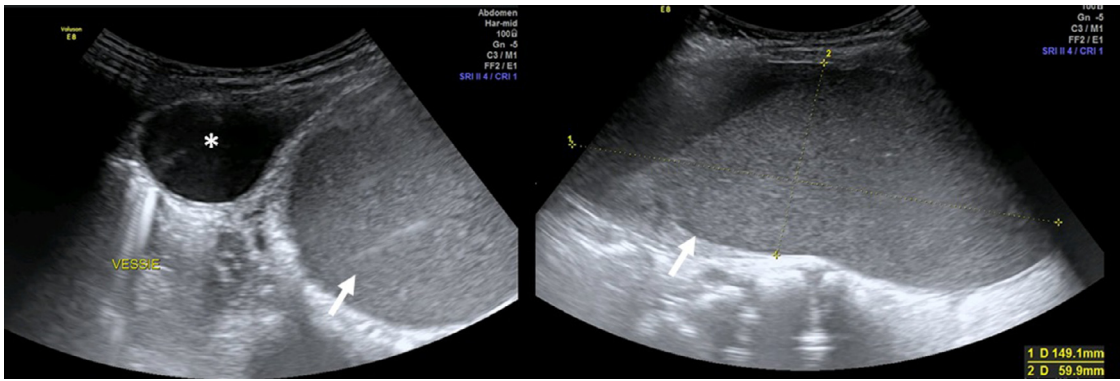
## Discussion

Pyocolpos is defined as an infected hydrocolpos, which in turn is the accumulation of secretions within the vagina and failure to exteriorize, secondary to mostly an imperforate hymen. Rarely, the cause could be the presence of a transverse vaginal membrane or vaginal atresia. The incidence of hydrocolpos and pyocolpos is estimated to be 1 in 30,000 newborns [3].

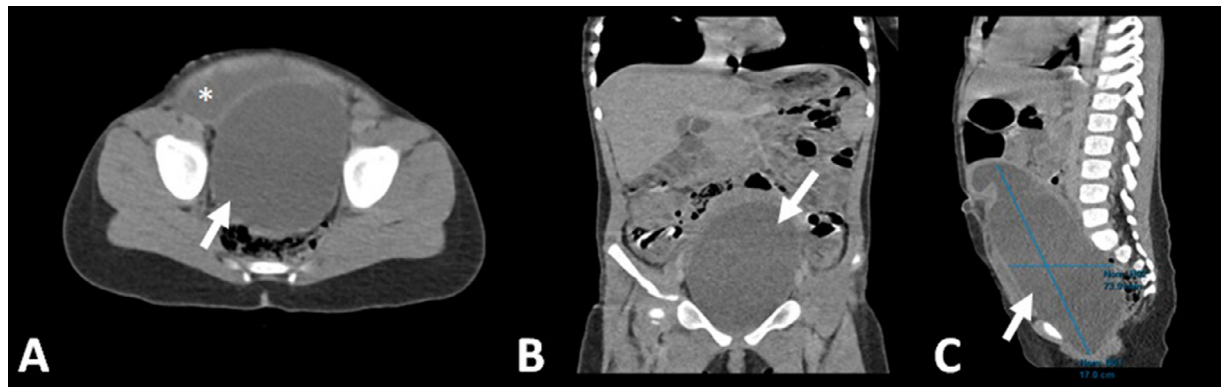
Hydrocolpos is usually encountered either in the newborn and/or neonatal period, secondary to stimulation from residual mother's hormones, or at menarche, during estrogen surge [4]. The occurrence beyond infancy and before puberty, is somehow rare, mainly due to inadequate uterine and vaginal secretions during this period [5]. As such, there is a bimodal age distribution for developing hydrocolpos and secondary pyocolpos [4]. The high levels of maternal hormones during the neonatal period and the hormonal surge during puberty, would increase vaginal gland secretions, and in the presence of distal obstruction, can lead to hydrocolpos or hydrometrocolpos.

Hydrocolpos usually presents as an asymptomatic abdominal mass or sometimes with symptoms of compression and obstruction of adjacent structures by the enlarged vagina, such as the bladder trigone and ureters, causing hydronephrosis and other sequel [6, 7]. Most presentations usually occur soon after birth. In fact, around two thirds of newborns present during the first 3 months of life with abdominal distention, a palpable mass, urinary retention, edema, intestinal obstruction, a bulging perineum, peritonitis from a ruptured hydrocolpos or a hydrometra, and even respiratory distress [8].

An infected hydrocolpos is called a pyocolpos, and this usually happens after a hematogenous spread [9], and can result in sepsis [6]. Failure to recognize a hydrocolpos early on can lead to drastic consequences, such as hydronephrosis, recurrent urinary infections, metabolic disturbances, and eventually failure to thrive [10].



**Fig. 1 – Ultrasound images of pyocolpos.** Ultrasound imaging of the vagina reveals a large dilated cystic structure with low-level internal echoes and fluid debris levels (arrow). The uterus, both kidneys, ovaries, and bladder (asterisk) were all normal.



**Fig. 2 – Computed tomography (CT) scan of the abdomen and pelvis revealing an enlarged vagina consistent with pyocolpos (arrow), extending to the level of the umbilicus and measuring around 17 cm in its greatest dimension. The bladder (asterisk) is also visualized in the axial cut, pushed over the anterior abdominal wall (A: axial; B: coronal; C: sagittal view).**

Hydrocolpos or hydrometrocolpos can sometimes go unnoticed by pediatricians or neonatologists, as soon as the child is born. Several series have highlighted the importance of early recognition. Bischoff et al. reviewed 117 cases of cloacal anomaly with associated hydrocolpos [11]. Forty two were not drained after delivery, and of those, 24 got complicated including the development of pyocolpos, sepsis, and failure to thrive. Another series from Nigeria reported 7 cases of neonatal hydrometrocolpos, with age between 2 to 27 days, presenting with abdominal distention and mass. Despite that, the diagnosis was initially missed and management was delayed [12].

Among the differential diagnoses for hydro and pyocolpos are various cystic masses originating from ovaries, adnexa, mesenteric or enteric cysts, meconium cysts, and cystic variations of sacrococcygeal teratomas, among others [8]. Hydrocolpos could also be part of various syndromes, such as McKusick-Kaufman syndrome, Herlyn-Werner-Wunderlich syndrome [13], and also part of the cloacal spectrum [14].

The management of pyocolpos in particular and hydrocolpos in general, is determined by the age at presentation, sever-

ity, and any associated anomalies. In the simplest cases of pyocolpos secondary to an imperforate hymen, urgent drainage followed by hymenotomy or intubated vaginostomy, in case of atresia, must be attempted [8]. This would relieve obstruction and drain pus; thus, controlling sepsis, along with any other associated symptoms such as obstructive uropathy [7].

## Conclusion

As evident from this case report, thorough and detailed examination of the external genitalia must never be underestimated. The presence of an imperforate hymen can result in hydrocolpos with secondary pyocolpos; albeit the latter is rarely encountered in the pre-pubertal age group, but should be always kept in mind. Aside from chronic abdominal pain, pyocolpos can cause various drastic sequel necessitating urgent decompression and hymenotomy, to relief obstruction and control sepsis.

### Ethical approval

A written informed consent was obtained from the patient's legal guardian, for publication of this manuscript and any accompanying images. A copy of the consent can be available for review by the Editor-in-Chief of this journal, upon his request.

### Author's Contribution

JAD and TC extracted the data and wrote the initial draft together; TC and BA obtained the figures; JAD made the literature review; MK and BA had important intelligent contribution and critically revised the manuscript. All authors in read and approved the final manuscript. Dr. Degheili and Dr. Khaled have contributed equally to this manuscript, thus both qualify as first authors.

### Patient Consent Statement

A written informed consent was obtained from the patient's legal guardian, for publication of this manuscript and any accompanying images. A copy of the consent can be available for review by the Editor-in-Chief of this journal, upon his request.

### REFERENCES

- [1] Bufler P, Gross M, Uhlig HH. Recurrent abdominal pain in childhood. *Dtsch Arztebl Int* 2011;108(17):295–304. doi:10.3238/arztebl.2011.0295.
- [2] Scholer SJ, Pituch K, Orr DP, Dittus RS. Clinical outcomes of children with acute abdominal pain. *Pediatrics* 1996;98(4):680–5 Pt 1.
- [3] Gandage S G, Aironi VD, Agarwal S, Singh J. Ultrasound diagnosis of pyocolpos. *J Indian Assoc Pediatr Surg* 2007;12:235–7.
- [4] Sidatt M, Ould Sidi Mohamed Wedih A, Ould Boubaccar A, Ould Ely Litime A, Feil A. Ould Moussa A. Hydrocolpos and hydrometrocolpos in newborns. *Arch Pediatr* 2013;20(2):176–80.
- [5] Agarwal N, Singh S, Dayal R, Pathak A. *Int J Reprod Contracept Obstet Gynecol.* 2013; 2(3):488-490.
- [6] Zamir O, Hadary A, Udassin R, Nissan S. Pyocolpos a rare cause of neonatal sepsis. *Pediatr Surg Int* 1987;2:362–4.
- [7] Shen MC, Yang LY. Imperforate hymen complicated with pyocolpos and lobar nephronia. *J Chin Med Assoc* 2006;69(5):224–7.
- [8] Khanna K, Sharma S, Gupta DK. Hydrometrocolpos etiology and management: past beckons the present. *Pediatr Surg Int* 2018;34(3):249–61.
- [9] Brevetti LS, Kimura K, Brevetti GR, Lawrence JP, Soper RT. Pyocolpos: diagnosis and treatment. *J Pediatr Surg* 1997;32(1):110–11.
- [10] Levitt MA, Peña A. Pitfalls in the management of newborn cloacas. *Pediatr Surg Int* 2005;21(4):264–9.
- [11] Bischoff A, Levitt MA, Breech L, Loudon E, Peña A. Hydrocolpos in cloacal malformations. *J Pediatr Surg* 2010;45(6):1241–5.
- [12] Okoro PE, Obiorah C, Enyindah CE. Experience with neonatal hydrometrocolpos in the Niger Delta area of Nigeria: Upsurge or increased recognition? *Afr J Paediatr Surg* 2016;13:161–5.
- [13] Jung EJ, Cho MH, Kim DH, et al. Herlyn-Werner-Wunderlich syndrome: An unusual presentation with pyocolpos. *Obstet Gynecol Sci* 2017;60(4):374–7.
- [14] Cerrah Celayir A, Kurt G, Sahin C, Cici I. Spectrum of etiologies causing hydrometrocolpos. *J Neonatal Surg* 2013;2(1):5.