



# Intra-articular Lipoma of the Pisotriquetral Joint: A Rare Case Report

Sindhura Mettu<sup>1</sup> Sai Niharika Gavvala<sup>2</sup> K. Shirodkar<sup>2</sup> Karthikeyan Parthasarathy Iyengar<sup>3</sup><sup>ID</sup>  
Vijay Ram Kumar Papineni<sup>4</sup><sup>ID</sup> Rajesh Botchu<sup>2</sup>

<sup>1</sup> Department of Radiology, PACE Hospital, Hyderabad, Telangana, India

<sup>2</sup> Department of Musculoskeletal Radiology, Royal Orthopaedic Hospital, Birmingham, United Kingdom

<sup>3</sup> Department of Orthopedics, Southport and Ormskirk Hospital, Southport, United Kingdom

<sup>4</sup> Department of Radiology, Sheikh Shakhboub Medical City (Mayo Clinic), Abu Dhabi, United Arab Emirates

Address for correspondence Rajesh Botchu, MRCS, FRCR, Department of Musculoskeletal Radiology, The Royal Orthopaedic Hospital, Bristol Road South, Northfield B21 3AP, Birmingham, United Kingdom (e-mail: drbrajesh@yahoo.com).

Indian J Radiol Imaging 2024;34:558–561.

## Abstract

### Keywords

- ▶ lipoma
- ▶ intra-articular
- ▶ wrist
- ▶ pisotriquetral
- ▶ musculoskeletal
- ▶ ultrasonography
- ▶ CT

Intra-articular lipomas are infrequently reported, with most reported cases occurring in the knee joint. A case of intra-articular lipoma in the small joints of the hand, specifically in the pisotriquetral joint, has been documented for the first time. A 24-year-old male visited the emergency department after a road traffic accident with a painful and swollen wrist. Radiographic examination revealed fractures of the distal radius and triquetrum. A subsequent wrist computed tomography scan identified an intra-articular lipoma within the pisotriquetral joint, further confirmed by ultrasonography. This article underscores the importance of recognizing that, though exceedingly rare, intra-articular lipomas should be considered in the differential diagnosis of soft-tissue tumors affecting the hand and wrist.

## Introduction

Lipomas are benign tumors that arise from mesenchymal cells. Although they are the most common soft-tissue tumor of the body, they are relatively rare in the hand and make up only 8% of all benign hand tumours.<sup>1</sup> Lipomas in the hand can occur in different locations, such as subcutaneous, subfascial, intramuscular, and even intraosseous.<sup>2</sup> This particular case is unique because it involves an intra-articular lipoma of the hand, which affects the pisotriquetral (PT) joint.

## Case Report

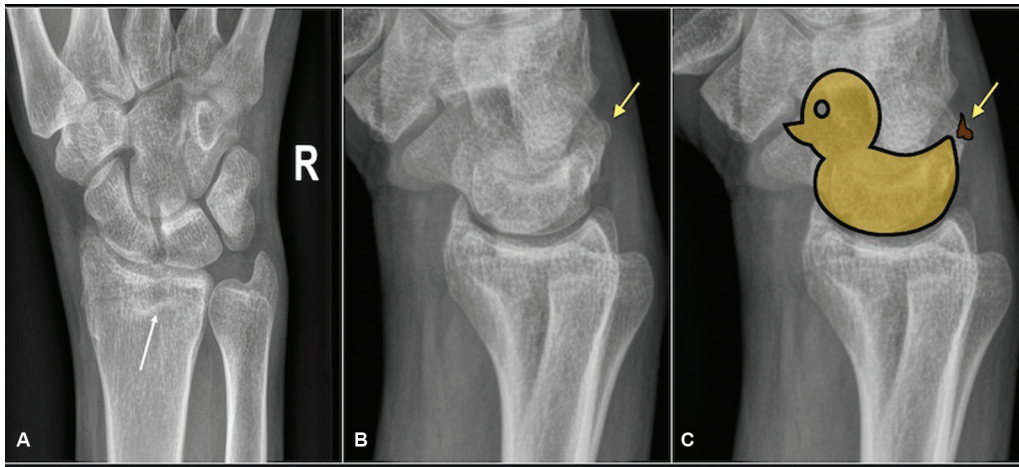
A 24-year-old male patient with severe pain in their right leg and foot, as well as pain in the right wrist, presented to the

emergency department following a motor vehicular accident. A routine trauma screening radiograph of the affected bone was performed, which revealed fractures of the distal radius and triquetrum. A “pooping duck sign” indicating a dorsal triquetral fracture could also be demonstrated on the lateral wrist radiograph (▶ Fig. 1). Subsequently, a computed tomography (CT) of the hand was performed to assess the triquetral and distal radius fracture. In addition to confirming the distal radius and triquetral fractures, the CT scan revealed an incidental soft-tissue mass in the PT joint (▶ Fig. 2). The soft-tissue mass was well-circumscribed and demonstrated intrinsic Hounsfield attenuation identical to subcutaneous fat in keeping with a simple lipoma. Ultrasonography revealed a well-defined hypoechoic lesion arising from the PT joint (▶ Fig. 3). Unfortunately, a magnetic resonance imaging (MRI) could not

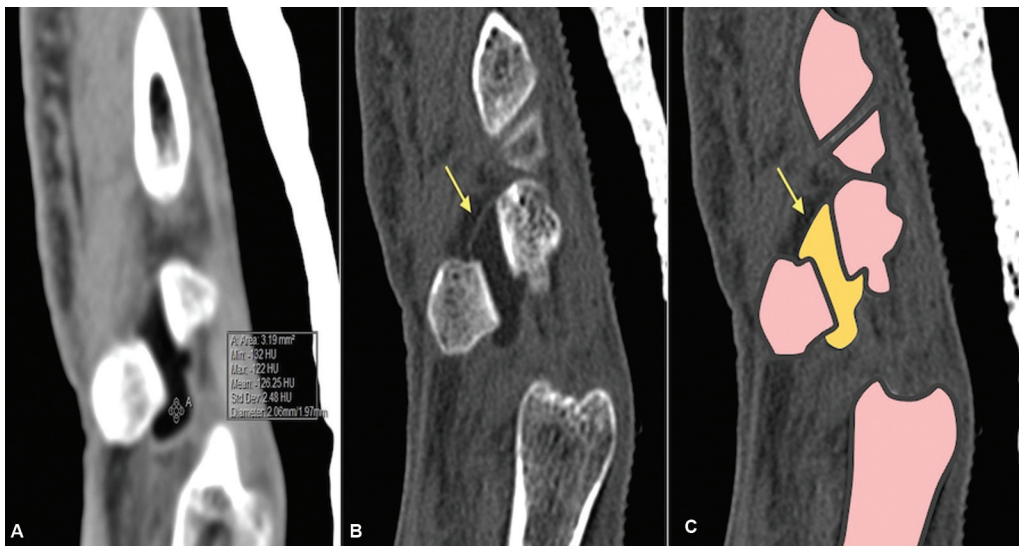
article published online  
February 23, 2024

DOI <https://doi.org/10.1055/s-0044-1779521>.  
ISSN 0971-3026.

© 2024. Indian Radiological Association. All rights reserved.  
This is an open access article published by Thieme under the terms of the Creative Commons Attribution-NonDerivative-NonCommercial-License, permitting copying and reproduction so long as the original work is given appropriate credit. Contents may not be used for commercial purposes, or adapted, remixed, transformed or built upon. (<https://creativecommons.org/licenses/by-nc-nd/4.0/>)  
Thieme Medical and Scientific Publishers Pvt. Ltd., A-12, 2nd Floor, Sector 2, Noida-201301 UP, India



**Fig. 1** Anteroposterior (A) and lateral (B, C) radiographs of the right wrist. Fractures of the distal radius and triquetrum seen (arrow). The arrow points to an avulsed fragment from the dorsal cortex of the triquetrum. “Poop” in the pooping duck sign refers to the avulsed fragment (C).



**Fig. 2** Sagittal computed tomography images (A–C) with schematic (C) show a well-defined hypodense lesion (–126 Hounsfield unit) (arrow) in the pisotriquetral joint (A).

be performed as the patient had undergone metallic fixation for his bony injuries. The imaging diagnosis was that of a benign intra-articular synovial lipoma. No sinister features were seen within the lesion. Since the lesion was incidentally detected with no lesion-related symptoms, a surgical excision biopsy was deemed inappropriate and was not performed. The patient was reassured and told to keep an eye on the lesion and report back to the doctors in case development of any lesion-related symptoms.

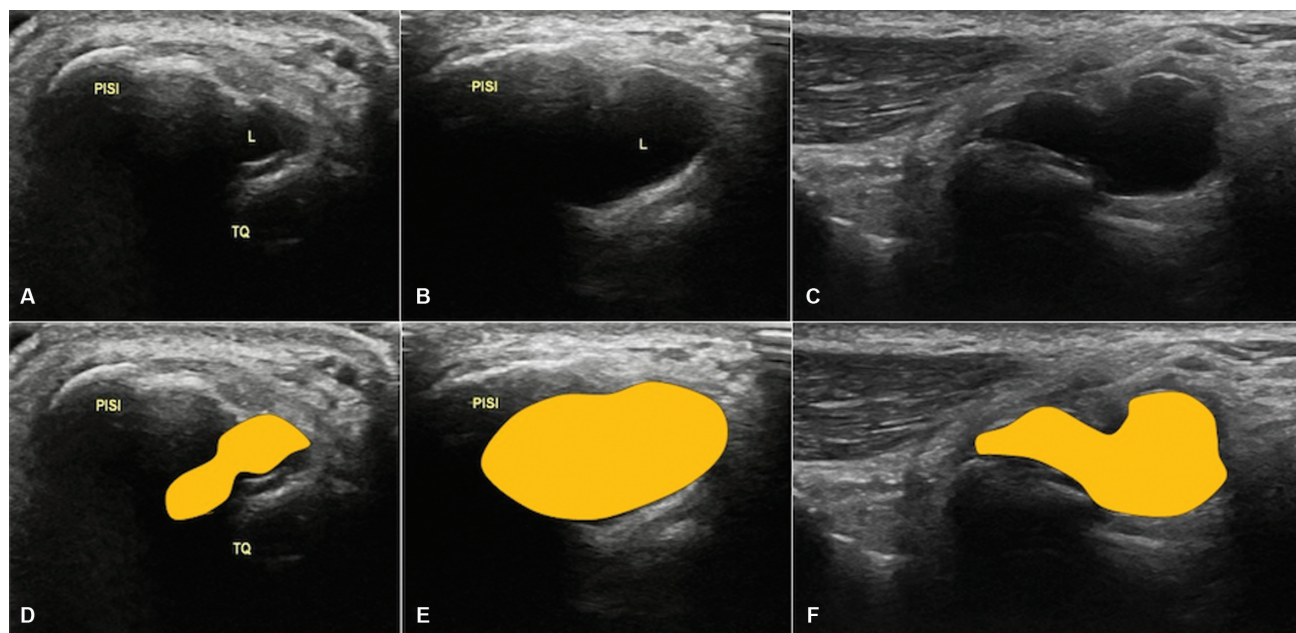
### Discussion

Understanding the PT joint’s intricate anatomy and potential pathologies is essential for musculoskeletal radiologists, as lesions within or adjacent to the PT joint are an important but underdiagnosed cause of wrist pain. The pisiform is a small, pea-shaped carpal bone situated on the wrist’s volar (palmar) aspect, proximal to the volar surface of the triquetrum. These two bones articulate to form the PT joint. The PT

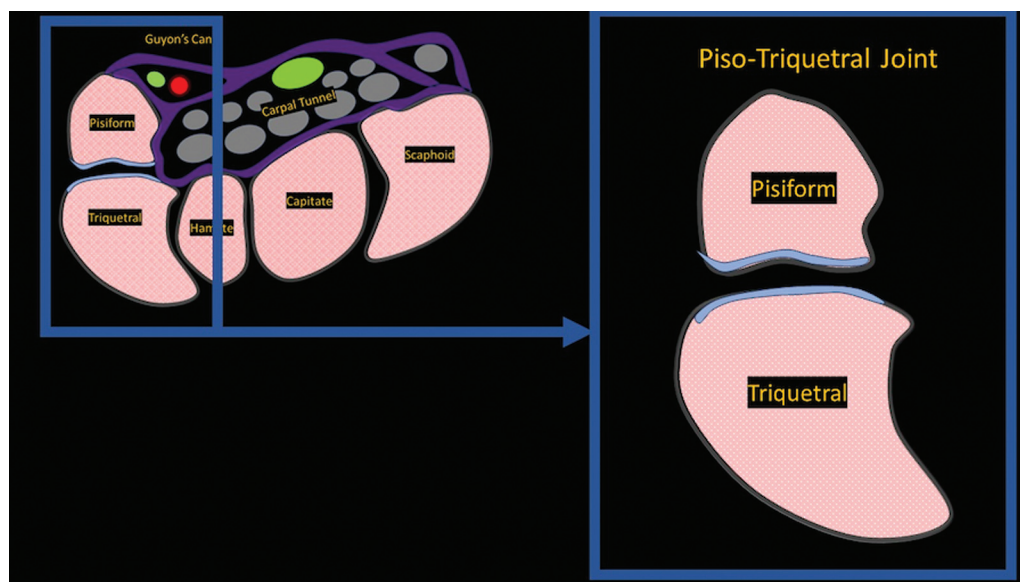
joint is a synovial joint with a loose capsule that provides little or no stability (► **Fig. 4**). The pisiform is stabilized by the flexor carpi ulnaris and three ligaments, namely the pisohamate ligament and pisometacarpal ligament. PT ulnar ligament with secondary stabilization provided by flexor and extensor retinaculum, as well as the abductor digiti minimi muscle insertion.<sup>3</sup> Damage to the structures surrounding the pisiform can lead to instability and dysfunction of the PT joint.

Pisiform forms the ulnar boundary of Guyon’s canal, and its hypermobility due to PT joint instability can potentially lead to ulnar nerve irritation or compression by distorting the anatomy of Guyon’s canal.

Clinicians and musculoskeletal radiologists must consider PT joint disorders when evaluating patients presenting with pain and tenderness at the palmar and ulnar aspects of the wrist, especially when this pain is exacerbated by wrist flexion and/or ulnar deviation. Besides trauma and degenerative arthritis, a few other pathologies affecting the PT joint



**Fig. 3** Ultrasound short-axis (A–E) and longitudinal (C, F) images show a well-defined hypoechoic lesion arising from the pisotriquetral joint space (yellow). L, lesion, PISI, pisiform.



**Fig. 4** Schematic showing the close proximity of the pisotriquetral joint to the Guyon's canal.

include ganglion cysts, synovial osteochondromatosis, and tenosynovial giant cell tumours.<sup>4</sup>

After reviewing the current literature, this appears to be the first documented case of an intra-articular lipoma in the PT joint. Although the lesion was not well-appreciated on the initial radiograph, a well-defined radiolucency can often be seen if the lesion is large in size.<sup>2</sup> Ultrasound is a valuable modality for evaluating pathologies in and around the PT joint due to its high image resolution and the superficial location of the PT joint. On ultrasonography, lipomas appear as well-circumscribed lesions and predominantly hyperechoic or isoechoic to subcutaneous fat, with some lesions appearing hypoechoic (as in our case). The variations in the

echotexture of the lipomas can be attributed to the acoustic impedance mismatch at the fat-water interphase. Pure fat lipomas have few interfaces and less acoustic impedance mismatch, so they appear echo-free. In contrast, echogenicity increases when there is mixed cellularity or fibrous septae because it means more interfaces and acoustic impedance mismatch.<sup>5</sup>

MRI is the best modality for imaging soft-tissue lesions, including lipomas, because of its excellent soft-tissue resolution and multiplanar capability. However, we could not perform an MRI in our case because the patient had an emergency tibial nailing for a traumatic fracture. However, the ultrasound and CT imaging provided enough diagnostic

confidence/evidence to clinch the diagnosis and label the lesion as a benign simple intra-articular lipoma on imaging.<sup>6</sup>

Awareness of the possibility of intra-articular lipoma at the PT joint is essential for evaluating cases of lateral wrist pain. Ulnar nerve evaluation is necessary in cases of PT lipoma due to its proximity to Guyon's canal.<sup>7</sup>

## Conclusion

This represents the first recorded case of a lipoma within the PT joint in English medical literature. This case encourages radiologists and clinicians to consider lipomas when evaluating potential PT joint issues. In situations where lipomas are incidentally discovered, it is crucial to assess the ulnar nerve carefully, and if the choice is not to pursue surgery, close and comprehensive follow-up by the clinical team is strongly recommended.

### Funding

None.

### Conflict of Interest

None declared.

## References

- 1 Bankaoglu M, Ugurlar OY, Ugurlar M, Sonmez MM, Eren OT. Intra-articular lipoma of the knee joint located in the posterior compartment: a rare location. *North Clin Istanb* 2016;4(01):89–92
- 2 Burt AM, Huang BK. Imaging review of lipomatous musculoskeletal lesions. *SICOT J* 2017;3:34
- 3 Pevny T, Rayan GM, Egle D. Ligamentous and tendinous support of the pisiform, anatomic and biomechanical study. *J Hand Surg Am* 1995;20(02):299–304
- 4 Moraux A, Lefebvre G, Pansini V, et al. Pisotriquetral joint disorders: an under-recognized cause of ulnar side wrist pain. *Skeletal Radiol* 2014;43(06):761–773
- 5 Paunipagar BK, Griffith JF, Rasalkar DD, Chow LT, Kumta SM, Ahuja A. Ultrasound features of deep-seated lipomas. *Insights Imaging* 2010;1(03):149–153
- 6 Kransdorf MJ, Bancroft LW, Peterson JJ, Murphey MD, Foster WC, Temple HT. Imaging of fatty tumors: distinction of lipoma and well-differentiated liposarcoma. *Radiology* 2002;224(01):99–104
- 7 Seror P, Vuillemin V. Ulnar nerve lesion at the wrist related to pisotriquetral joint arthropathy. *Muscle Nerve* 2013;47(04):600–604
- 8 AbuMoussa S, Roshan MP, Souza FF, et al. Soft tissue masses of the hand: a review of clinical presentation and imaging features. *Curr Oncol* 2023;30(02):2032–2048