



OPEN ACCESS

Functional outcomes of an adult with osteogenesis imperfecta after rehabilitation post bilateral Girdlestone procedure

Isabella Supnet ,¹ Joycie Eulah Abiera,¹ Maria Melanie Liberty Alcausin,² Carlo Emmanuel Sumpaico³

¹Rehabilitation Medicine, Philippine General Hospital, University of the Philippines Manila, Manila, Philippines
²Pediatrics, Philippine General Hospital, University of the Philippines Manila, Manila, Philippines

³Orthopedics, Philippine General Hospital, University of the Philippines Manila, Manila, Philippines

Correspondence to

Dr Isabella Supnet; isabella.supnet@gmail.com

Accepted 17 March 2021

SUMMARY

This is a case of a 54-year-old woman managed as a case of osteogenesis imperfecta type 1 who sustained a left subtrochanteric fracture and eventual ankylosis of both hips after surgery and immobilisation. These injuries rendered her bedridden, maximally assisted in transitions and transfers, and unable to be positioned past 30° of backrest elevation. The patient underwent a bilateral Girdlestone procedure and had tailored progressive postoperative rehabilitation in both the inpatient and outpatient settings. The patient also continued to receive bisphosphonates during her preoperative and postoperative period, to improve bone stock and aid in relieving pain. Through the efforts of a team of physiatrists, geneticists and orthopaedic surgeons, the patient was able to achieve pain-free sitting, independent transitions and short-distance ambulation, which have allowed her to care for herself more effectively and return to her work and activities of daily living.

BACKGROUND

Osteogenesis imperfecta (OI) is a highly heterogeneous disorder characterised by bone fragility. Prognoses may vary depending on the type of OI, and much of the literature on OI in adults have been viewed through the lens of genotypic and phenotypic correlations.¹ With the advent of bisphosphonate therapy, recent studies have also highlighted its value in improving OI outcomes.² Rehabilitation care, although recognised as important, has been explored more extensively on its effects in children than in adults.³

The Girdlestone resection arthroplasty was first described by Gathorne Robert Girdlestone in 1928 as a technique to treat tuberculosis and other disorders of the hip wherein no formal articulation between the pelvis and femur is established after resection of the femoral head.⁴ With the advent of replacement arthroplasty, the Girdlestone arthroplasty is considered as a procedure performed as a last resort in cases of significant infection, poor bone stock or failed total hip arthroplasty due to decreased functional outcomes.⁵ It has been documented in use for patients with neglected femoral neck fractures, failed osteosynthesis, failed hemiarthroplasty and painful aseptic osteonecrosis of the femoral head.⁶ Incidence of the procedure is generally low, with only 43 procedures performed from 1990 to 2002 in two large hospitals in the UK,⁷

with recent trends pointing that the conduct of the procedure today is even lower. There is also a noted lack of literature on the bilateral procedure and its outcomes, with only anecdotal evidence of three patients, who were eventually able to ambulate with gait aids.⁸ Its application on a patient with OI has not been described in the literature.

The purpose of this case report is to describe and document the functional outcomes of an adult with complex orthopaedic impairments after rehabilitation following bilateral Girdlestone procedure, who achieved ambulation with multidisciplinary collaboration.

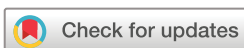CASE PRESENTATION

Consent for this case report was explained and requested from the patient, which she gave under the condition to conceal her name and face.

The patient is a 54-year-old female accountant. She was born at full term to a then 34-year-old father and 26-year-old G2P1 mother. Immediate neonatal course was unremarkable. Developmentally, her milestones were at par with her sibling, but she was noted to be smaller than expected for her age. At the age of 3 years, the patient was noted to have bowed legs, prompting consult. She was managed as a case of rickets and underwent bracing of both knees, with eventual bilateral epiphyseal stapling at the age of 11 years. No similar condition was noted in the family. She was lost to follow-up thereafter.

At the age of 14 years, the patient slipped on the floor, breaking her right femur. On consult, she was then managed as a case of OI and underwent an open reduction internal fixation (ORIF) with plates and screws. She was eventually able to ambulate after a year, and continued follow-up with her local physician.

In 2012, at the age of 48 years, the patient tripped and sustained a left subtrochanteric femoral fracture, rendering her non-ambulatory. She again underwent an ORIF. In 2013, due to a fracture at the proximal site of attachment of her implanted plate, she underwent revision ORIF. At that time, the patient was still unable to sit and ambulate due to pain. She consulted with orthopaedics and rehabilitation medicine at the Philippine General Hospital (PGH) and underwent removal of her plates and screws in October 2014, with intraoperative findings of a healed femoral fracture. She



© BMJ Publishing Group Limited 2021. Re-use permitted under CC BY-NC. No commercial re-use. See rights and permissions. Published by BMJ.

To cite: Supnet I, Abiera JE, Alcausin MML, et al. *BMJ Case Rep* 2021;**14**:e239884. doi:10.1136/bcr-2020-239884

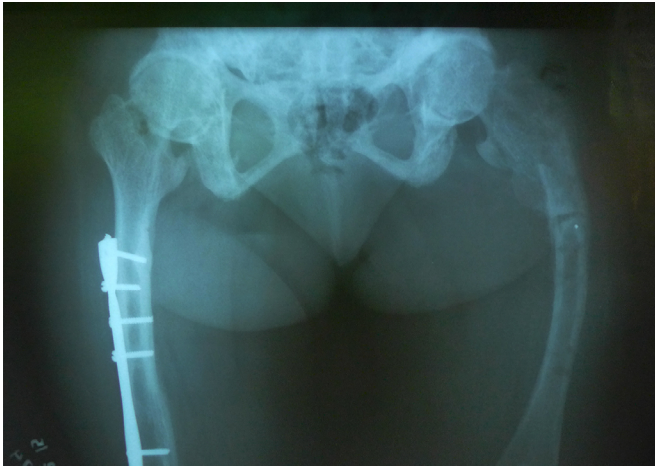


Figure 1 Anteroposterior radiograph of the patient's pelvis taken prior to Girdlestone arthroplasty.

was placed on a hip spica and sent home with modest pain improvement.

Prior to discharge and in the interim, the patient was managed by the genetics service, who clinically diagnosed the patient with OI type 1 and prescribed pamidronate infusions. On removal of the hip spica, there was noted limitation of the patient's range of motion (ROM) of bilateral hips, only allowing low backrest elevation. Radiographical findings showed ankylosis of both hips (figure 1). She was readmitted in November 2015, and findings of preoperative examination showed passive hip flexion of 0°–30°, and 0°–12° of the right and left hips. There was also

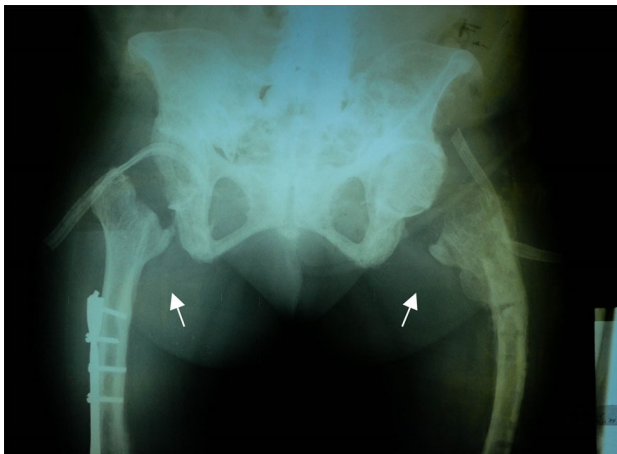


Figure 2 Anteroposterior radiograph of the patient's pelvis taken post-Girdlestone arthroplasty, with absence of the anatomic head and neck of both femurs (short arrows).

Table 1 Lower extremity passive range of motion findings 33 months postoperatively, with normal values²⁰

Passive joint motion	Normal values	Right	Left
<i>Hip</i>			
Flexion	0°–120°	0°–95°	0°–95°
Extension	0°–20°	0°	0°
Abduction	0°–40°	0°–40°	0°–35°
Adduction	0°–20°	0°–20°	0°–20°
Internal rotation	0°–45°	0°	0°–45°
External rotation	0°–45°	0°–30°	0°–25°
<i>Knee</i>			
Flexion	0°–135°	10°–60°	0°–67°
Extension	0°–10°	–10°	0°
<i>Ankle</i>			
Dorsiflexion	0°–20°	0°	0°
Plantar flexion	0°–50°	0°–30°	0°–30°

noted limitation of the patient's cervical ROM on all planes, and that she was maintained in kyphosis of the neck. She underwent bilateral Girdlestone procedure during the admission (figure 2). To prevent postoperative complications and to facilitate functional recovery, the patient was then referred for inpatient rehabilitation and management.

TREATMENT

At the time of referral, there was noted pain on movement of the lower extremities, with both legs placed in traction. At this time, rehabilitation goals included alleviation of pain and prevention of complications of immobility. The patient was prescribed icing and transcutaneous electrical nerve stimulation at the perioperative area and instructed on isometric exercises of the lower extremities.

Two weeks postprocedure, the traction was removed and the patient progressed to bed mobility exercises as well as assisted ROM exercises of bilateral lower extremities. She was eventually cleared for sitting, strengthening of bilateral hip flexors and out-of-bed exercises. Prior to discharge, she was able to tolerate wheelchair rides with the backrest at 90°. At this time, she was maximally assisted in transfers. She continued physical therapy at home and was able to continue ROM and conditioning exercises. She remained primarily bedbound and assisted in transfers to a bedside chair, as well as in performing activities of daily living requiring mobility, particularly toileting.

In May 2017, the patient was readmitted to PGH for progressive rehabilitation care in coordination with genetics service for her pamidronate infusions. She was then able to tolerate standing exercises for 2 min and gradually progressed to ambulation training with a standard walker during her month-long admission. She continued rehabilitation management on an

Table 2 Description of assessment tools used and summary of findings

Assessment tool	Description	Findings and interpretation
Modified Merle d'Aubigne Postel score	Assesses hip function in terms of pain, walking and hip motion	B-13 (fair functional capacity)
Harris hip score	Used to assess results after hip surgery but is also employed to assess general hip function	Prior to operation: 20/100 33 months postoperatively: 60/100 (higher is better)
Functional independence measure	General indicator of patient disability	Prior to operation: 85/126 33 months postoperatively: 105/126 (higher is better)
Short form-36	Used to survey health status and quality of life	Decreased functional capacity and physical domains Normal findings in other domains

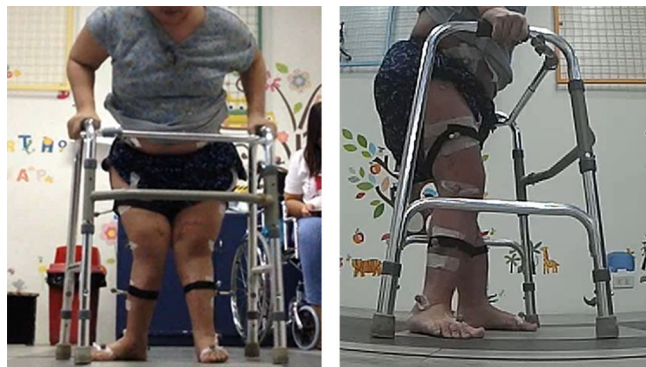

Figure 3 Coronal (left) and sagittal (right) views of the patient undergoing motion analysis.

outpatient basis. Therapy included ROM exercises, strengthening of bilateral crutch bearing muscles, standing balance and tolerance exercises, and short-distance gait retraining with an adult standard walker.

OUTCOME AND FOLLOW-UP

During the patient's follow-up last August 2018, the patient was noted to have limited passive ROM of both hips, knees and ankles, particularly on hip extension and internal rotation as well as knee flexion (table 1). Given these impairments, the patient had achieved functional ROM with adequate strength to provide resistance.

The patient was able to complete the Timed Up and Go test, with an average time of 2 min and 11 s. Although this result classifies her under an increased risk of falls requiring standby assistance and a gait aid,⁹ the patient was able to finish the examination—a feat she was unable to perform 6 months prior.

The patient was also assessed using the modified Merle d'Aubigne-Postel score, the Harris hip score, the functional independence measure and the short form-36 (table 2). From these assessment tools, the patient showed improvements in her independence and her general hip function. Although the patient had lower scores in functional capacity and physical domains than others who had a unilateral Girdlestone or a combination unilateral Girdlestone-contralateral hip arthroplasty,¹⁰ the patient had similar ratings in the social and emotional domains, as well as in pain, vitality, mental health and overall status.

The patient also underwent motion analysis (figure 3). On assessment of her kinematics and temporospatial parameters

(video 1), there was decreased walking speed and cadence, as well as an increase in the peak anterior pelvic tilt. There was also noted decreased peak hip extension, with decreased ankle plantar flexion during the third rocker. These findings are comparable with a local study performed with ambulatory OI patients, from type I to V.¹¹

DISCUSSION

In the management of an adult with OI, it is important to keep in mind that, although fracture rates generally decline as a patient reaches skeletal maturity, the incidence of fracture in persons aged 20–54 years, and 55 years and above, is 6.2 and 4.1 times as high as those of the normal population, respectively.¹² Prevention can be done with the administration of bisphosphonates, which increase bone mass density and reduce fracture risk.¹³ Decreased pain may also be an effect of bisphosphonate administration,¹⁴ which also facilitates therapy exercises. Once with a fracture requiring surgical intervention, factors, such as bony deformity, increased risk of fractures and shorter limbs, must be considered. Load-sharing intramedullary devices are strongly preferred over locking plates, as the latter can promote stress shielding and can lead to bony resorption. As was demonstrated by our patient, the ends of plates are also prone to fracture, as these are areas with a high concentration of stress.¹⁵

The congenital weakness in bones, ligaments and muscles in OI, and their accompanying skeletal deformities and functional limitations emphasises the importance of rehabilitation care in attaining independent living and active social participation. Active movement is encouraged to enhance musculoskeletal strength and cardiovascular fitness. Programmes are tailored according to the degree of motor development of the individual, clinical severity of OI and attained ability.¹⁶

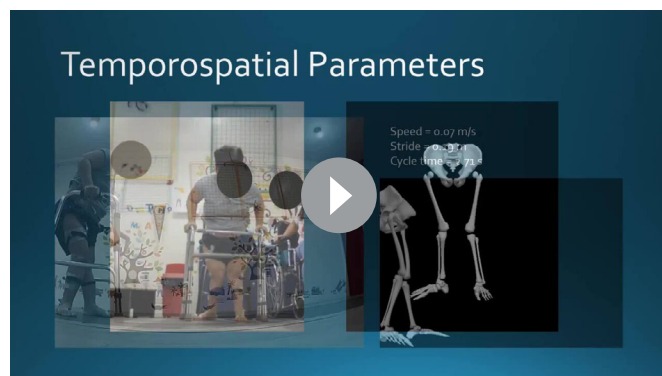
After a fracture, guided rehabilitation care is even more necessary. Prolonged immobilisation is detrimental to recovery, as fracture risk may be further increased by disuse osteopenia, weakness and functional impairment.¹⁷ Current consensus is that the cycle of fracture, immobilisation, osteoporosis and refracture must be interrupted, as the possibility of autonomy is inversely

Patient's perspective

I am thankful to God, my support system, and my doctors from ortho, rehab and genetics for my continued progress. At the start, I was unsure of the surgery, especially since they were going to remove my hips. But now, I can stand and walk around on my own, even if just a little bit, for the first time in 6 years. I still need help with a lot of things, but I believe that with the help of the entire team, I can achieve even more.

Learning points

- ▶ Well-structured therapeutic interventions and strong multidisciplinary collaboration are immensely important for patients with complex musculoskeletal concerns.
- ▶ For cases such as these, preparation for and commitment to a prolonged rehabilitation course is necessary for continued improvement in functional ability.
- ▶ Although not all impairments may be reverted to normal in complex orthopaedic cases, a significant level of functional improvement and enhancement of quality of life may be achieved.



Video 1 Video clips of the patient undergoing motion analysis in both coronal and sagittal views with their corresponding computer-generated three-dimensional anatomic representations.

correlated to subsequent injury and deformity, especially in later years.¹⁸

The Girdlestone arthroplasty has been progressively left aside in favour of replacement arthroplasty due to its functional inferiority, mainly attributed to poor postoperative joint stability and subsequent limb length discrepancy, eventually leading to increased energy expenditure and stance changes resulting to possible ambulation support.¹⁹ However, it still is able to provide some level of pain relief, improvement of patient function and an increase in patient satisfaction. In our patient, the orthopaedic service chose to proceed with this procedure with the primary aim of allowing the patient to sit.

Through the efforts of physiatrists, geneticists and orthopaedic surgeons, as well as the rehabilitation medicine team, the patient was able to achieve pain-free sitting, independent transitions and short-distance ambulation. These functional improvements have allowed the patient to care for herself more effectively and return to her work as a municipal accountant. The outcome measures give a quantitative scale to the patient's improvement and provide guidance as to which areas need more focus.

Correction notice The article has been corrected since it was published. The affiliations have been updated.

Acknowledgements The authors would like to acknowledge the assistance of Dr Juanito S Javier, whose knowledge and expertise regarding the patient's case proved invaluable to the report.

Contributors IS: Served as the primary investigator of this study, selected and administered functional tests, performed the technical analysis of the patient, reviewed the literature and wrote the manuscript. JEA: Supervised management of the patient and gave input during the examination period. She also edited and reviewed the final manuscript. MMLA: Gave critical information on the status of the patient and the nuances of her management, and assisted in editing the manuscript. CES: Assisted in the general design of the report, and gave feedback on the completed manuscript. All authors have read and approved the final manuscript.

Funding The authors have not declared a specific grant for this research from any funding agency in the public, commercial or not-for-profit sectors.

Competing interests None declared.

Patient consent for publication Obtained.

Provenance and peer review Not commissioned; externally peer-reviewed.

Open access This is an open access article distributed in accordance with the Creative Commons Attribution Non Commercial (CC BY-NC 4.0) license, which permits others to distribute, remix, adapt, build upon this work non-commercially, and license their derivative works on different terms, provided the original work is properly cited and the use is non-commercial. See: <http://creativecommons.org/licenses/by-nc/4.0/>.

ORCID iD

Isabella Supnet <http://orcid.org/0000-0001-9753-505X>

REFERENCES

- Scheres LJJ, van Dijk FS, Harsevoort AJ, *et al.* Adults with osteogenesis imperfecta: clinical characteristics of 151 patients with a focus on bisphosphonate use and bone density measurements. *Bone Rep* 2018;8:168–72.
- Feehan AG, Zacharin MR, Lim AS, *et al.* A comparative study of quality of life, functional and bone outcomes in osteogenesis imperfecta with bisphosphonate therapy initiated in childhood or adulthood. *Bone* 2018;113:137–43.
- Trovato MK, Schultz SC, Joseph C. Rehabilitation for Adults with Osteogenesis Imperfecta. In: *Osteogenesis Imperfecta* [Internet]. Elsevier 2014:485–91.
- Vincenten CM, Gosens T, van Susante JC, *et al.* The Girdlestone situation: a historical essay. *J Bone Jt Infect* 2019;4:203–8.
- Marinko LN, Christie RE, Lewis CL. Successful rehabilitation of a young adult with total hip arthroplasty a decade after a Girdlestone procedure: a case presentation. *PM&R* 2015;7:895–900.
- Sawadogo M, Kafando H, Ouedraogo S, *et al.* Is Head and Neck Resection of the Femur (Girdlestone's Procedure) Still Relevant? Indications and Results About 24 Cases. *Open Orthop J* 2018;12:69–74.
- Sharma H, De Leeuw J, Rowley DI. Girdlestone resection arthroplasty following failed surgical procedures. *Int Orthop* 2005;29:92–5.
- Tanchev P. Does anyone have experience with bilateral Girdlestone hips after removal of infected THR? [Internet]. ResearchGate Q&A, 2014. Available: https://www.researchgate.net/post/Does_anyone_have_experience_with_bilateral_Girdlestone_hips_after_removal_of_infected_THR [Accessed cited 2019 Jan 23].
- Lysack CL. Household and Neighborhood Safety, Mobility. In: *Handbook of Assessment in Clinical Gerontology* [Internet]. Elsevier, 2010: 619–46.
- Yamamoto PA, Lahoz GL, Takata ET, *et al.* Evaluation of the function and quality of life of patients submitted to Girdlestone's Resection Arthroplasty. *Acta Ortop Bras* 2007;4.
- Kurapati N, Boerigter R, Sumpaico C, *et al.* Lower body gait kinematics in mild-to-moderate vs. severe osteogenesis imperfecta in southeastern Asia. *Proc Biomed Eng Soc* 2017;215.
- Folkestad L, Hald JD, Ersbøll AK, *et al.* Fracture rates and fracture sites in patients with osteogenesis imperfecta: a nationwide register-based cohort study. *J Bone Miner Res* 2017;32:125–34.
- Dwan K, Phillipi CA, Steiner RD. Bisphosphonate therapy for osteogenesis imperfecta. Cochrane cystic fibrosis and genetic disorders group, editor. *Cochrane Database Syst Rev* 2016.
- Garganta MD, Jaser SS, Lazow MA, *et al.* Cyclic bisphosphonate therapy reduces pain and improves physical functioning in children with osteogenesis imperfecta. *BMC Musculoskelet Disord* 2018;19:344.
- Roberts TT, Cepela DJ, Uhl RL, *et al.* Orthopaedic considerations for the adult with osteogenesis imperfecta. *J Am Acad Orthop Surg* 2016;24:298–308.
- Smith PA, ed. *Rehabilitation in Osteogenesis Imperfecta. In: Transitional care in osteogenesis imperfecta: advances in biology, technology, and clinical practice.* Chicago: Shriners Hospitals for Children, 2015.
- Kruse RW, ed. *Osteogenesis Imperfecta: A Case-Based Guide to Surgical Decision-Making and Care* [Internet]. Cham: Springer International Publishing, 2020.
- Monti E, Mottes M, Fraschini P, *et al.* Current and emerging treatments for the management of osteogenesis imperfecta. *Ther Clin Risk Manag* 2010;6:367–81.
- Waters RL, Perry J, Conaty P, *et al.* The energy cost of walking with arthritis of the hip and knee. *Clin Orthop* 1987;214:278–84.
- Norkin CC, White DJ. *Measurement of joint motion: a guide to goniometry.* 4th ed.. Philadelphia: F.A. Davis, 2009: 450.

Copyright 2022 BMJ Publishing Group. All rights reserved. For permission to reuse any of this content visit <https://www.bmj.com/company/products-services/rights-and-licensing/permissions/>
BMJ Case Report Fellows may re-use this article for personal use and teaching without any further permission.

Become a Fellow of BMJ Case Reports today and you can:

- ▶ Submit as many cases as you like
- ▶ Enjoy fast sympathetic peer review and rapid publication of accepted articles
- ▶ Access all the published articles
- ▶ Re-use any of the published material for personal use and teaching without further permission

Customer Service

If you have any further queries about your subscription, please contact our customer services team on +44 (0) 207111 1105 or via email at support@bmj.com.

Visit casereports.bmj.com for more articles like this and to become a Fellow