



CASE REPORT

REVISED Case Report: Clinically amyopathic dermatomyositis presenting acutely with isolated facial edema [version 2; referees: 2 approved]

Previously titled: Case Report: Acute amyopathic dermatomyositis presenting with isolated facial edema

Efthymia Pappa ¹, Marina Gkeka ¹, Asimina Protogerou ¹, Leonidas Marinou ², Chariclia Loupa ¹, Constantinos Christopoulos ¹

¹Department of Internal Medicine, Amalia Fleming General Hospital, Athens, 15127, Greece

²Department of Hematopathology, Evangelismos General Hospital, Athens, 10376, Greece

v2 First published: 16 Jan 2018, 7:60 (doi: [10.12688/f1000research.13604.1](https://doi.org/10.12688/f1000research.13604.1))
 Latest published: 26 Mar 2018, 7:60 (doi: [10.12688/f1000research.13604.2](https://doi.org/10.12688/f1000research.13604.2))

Abstract

A 45-year-old Asian man presented with acute-onset periorbital and facial edema associated with pyrexia. Muscle weakness was absent. Initial laboratory investigations showed an inflammatory reaction, while screening for infections was negative. Serum muscle enzyme levels were normal. He was hospitalized and treated empirically with antibiotics and corticosteroids, pending the result of facial skin and muscle biopsy. He showed a good clinical and laboratory response but an attempt to discontinue corticosteroids led to a prompt relapse of facial edema and pyrexia, associated with rising laboratory indices of inflammation. Biopsy findings were typical of dermatomyositis. Reintroduction of corticosteroid treatment resulted in complete clinical and laboratory remission.

Facial edema as the sole clinical manifestation of dermatomyositis is extremely rare. There have been no previous reports of isolated facial edema in the setting of acute, clinically amyopathic dermatomyositis in adults. A high level of suspicion is required to make the diagnosis in the absence of myopathy and the hallmark cutaneous manifestations of the disease (heliotrope rash, Gottron papules).

Open Peer Review

Referee Status:

	Invited Referees	
	1	2
REVISED version 2 published 26 Mar 2018	 report	
	↑	
version 1 published 16 Jan 2018	? report	 report

- 1 **Lyubomir A. Dourmishev** , Medical University, Sofia, Bulgaria
- 2 **Albert Selva-O'Callaghan**, Autonomous University of Barcelona, Spain

Discuss this article

Comments (0)

Corresponding author: Efthymia Pappa (pappaefi@yahoo.gr)

Author roles: **Pappa E:** Conceptualization, Investigation, Writing – Original Draft Preparation; **Gkeka M:** Investigation; **Protogerou A:** Investigation; **Marinos L:** Validation, Visualization; **Loupa C:** Conceptualization, Investigation, Visualization; **Christopoulos C:** Conceptualization, Supervision, Writing – Review & Editing

Competing interests: No competing interests were disclosed.

How to cite this article: Pappa E, Gkeka M, Protogerou A *et al.* **Case Report: Clinically amyopathic dermatomyositis presenting acutely with isolated facial edema [version 2; referees: 2 approved]** *F1000Research* 2018, 7:60 (doi: [10.12688/f1000research.13604.2](https://doi.org/10.12688/f1000research.13604.2))

Copyright: © 2018 Pappa E *et al.* This is an open access article distributed under the terms of the [Creative Commons Attribution Licence](#), which permits unrestricted use, distribution, and reproduction in any medium, provided the original work is properly cited. Data associated with the article are available under the terms of the [Creative Commons Zero "No rights reserved" data waiver](#) (CC0 1.0 Public domain dedication).

Grant information: The author(s) declared that no grants were involved in supporting this work.

First published: 16 Jan 2018, 7:60 (doi: [10.12688/f1000research.13604.1](https://doi.org/10.12688/f1000research.13604.1))

REVISED Amendments from Version 1

- 1) The term "amyopathic dermatomyositis" has been replaced by the more accurate "clinically amyopathic dermatomyositis" in both the title and the manuscript text.
- 2) Orbital myositis has been included in the differential diagnosis of periorbital edema mentioned in the Introduction section.
- 3) Clarifications have been made regarding the levels of serum alanine aminotransferase, the exact site of skin and muscle biopsy, and the assessment of muscle weakness.
- 4) A passage commenting on the specificity of the skin biopsy findings has been added.

See referee reports

Introduction

A patient presenting with isolated periorbital and facial edema may pose diagnostic challenges. The differential diagnosis includes allergic reactions, soft tissue infections, intracranial venous thrombosis, auto-immune (dermatomyositis (DM), lupus erythematosus) and auto-inflammatory (periodic syndrome) disorders, orbital myositis, and trichinosis. In this setting, it may be difficult to make an accurate clinical diagnosis, and the patient is often treated empirically, pending the results of specific laboratory investigations. We present a case where skin and muscle biopsy established the previously unsuspected diagnosis of DM in a patient presenting acutely with periorbital and facial edema without myopathy. To our knowledge, there have been no previous reports of isolated facial edema in the setting of acute, clinically amyopathic dermatomyositis.

Case report

A 45-year-old Asian man, unskilled worker, who had lived in Greece for the last three years, presented to the Emergency Department with a three day history of painful facial swelling, pyrexia and vomiting. His medical history was notable only for type 2 diabetes mellitus treated with metformin and gliclazide. He denied recent travel abroad.

On examination there was bilateral, sensitive to palpation, edema involving the eyelids, nose, malar areas, forehead and anterior part of the scalp, associated with painful cervical lymphadenopathy (Figure 1A). The rest of the physical examination, including cardiovascular, respiratory, neuromuscular systems and abdomen, was unremarkable - in particular there were no muscle weakness or arthritis, and no skin eruptions on the trunk or extremities. Urgent laboratory investigations showed a picture of inflammation, with neutrophil leukocytosis (17,800/ μ L, normal 2,500–8,000), increased C-reactive protein levels (323 mg/L, normal <3.5) and elevated erythrocyte sedimentation rate (80 mm/h, normal <15). Biochemical profile revealed hyperglycemia (glucose 385 mg/dL, normal 70–100) and mild compensated acidosis (serum bicarbonate 14.5 mmol/L, normal 22–29), but was otherwise unremarkable. Notably, serum muscle enzyme levels (creatinine phosphokinase, aspartate aminotransferase, alanine aminotransferase, lactic dehydrogenase) were normal. Urinalysis and chest radiogram were normal. Abdominal ultrasound examination revealed cholelithiasis without signs of cholecystitis. The patient was admitted to hospital and, in the absence of a diagnosis, was treated empirically with intravenous ampicillin-sulbactam (3 g q.i.d.), clindamycin (600 mg t.i.d.) dime-thindene (4 mg b.i.d. for 3 days, then o.d. for 7 days) ranitidine (50 mg b.i.d.), and methylprednisolone (40 mg t.i.d.). Soluble insulin was administered subcutaneously as required, based on capillary glucose measurements t.i.d.. Blood cultures and screening for infections, including HIV and hepatitis were negative. Computed tomography and magnetic resonance imaging (MRI) of the head showed marked subcutaneous tissue edema of face and cranial vault, while MRI venography was normal.

A skin and muscle biopsy was obtained from the right malar area. The facial edema and cervical lymphadenopathy remitted gradually over the following days in parallel with falling levels of inflammation markers. No abnormalities were detected on repeated clinical assessment of muscle tone, power and tendon reflexes throughout his hospitalization. An attempt to discontinue corticosteroid therapy on hospital day 9

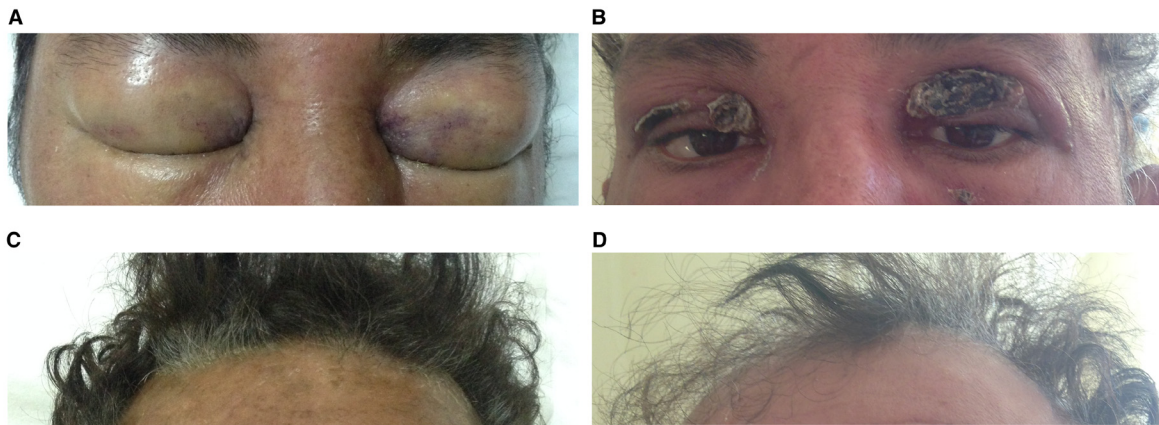


Figure 1. Patient facial appearances before (A,C) and after (B,D) treatment. A: Periorbital edema at presentation. The edema was evolving rapidly and the patient was unable to open his eyes. **B:** Subsidence of edema was followed by extensive skin desquamation. Erythema is due to corticosteroid therapy. **C,D:** Development of marked alopecia. Photographs B and D were taken on hospital day 26.

was quickly followed by relapse of facial edema, pyrexia and cervical lymphadenopathy, associated with a new rise of inflammation markers. Discontinuation of antibiotics and reintroduction of methylprednisolone (40 mg I.V. t.i.d, switching to 16 mg p.o. t.i.d after five days) on hospital day 14 led to a new clinical and laboratory remission within five days.

Additional investigations showed an elevated antinuclear antibody titer (1:320, normal <1:80), while anti-dsDNA, RNP, Sm, SSA(Ro), SSB(La), Jo1, Mi2 autoantibodies and rheumatoid factor were negative. *Trichinella spiralis* IgG antibodies were also negative. C1-inhibitor levels were normal, while serum

C3 levels were low (26.9 mg/dl, normal 88–135) and C4 levels were within normal range. Serum aldolase levels were normal. The muscle biopsy findings were typical of DM, while skin biopsy histology was compatible with, although not diagnostic of DM. (Figure 2).

By day 33, all laboratory abnormalities had returned to normal. Edema of face and scalp had completely subsided, leaving extensive desquamation and alopecia of involved areas (Figure 1B–D). The patient was discharged taking methylprednisolone 32 mg daily, with arrangements for rheumatology outpatient follow-up. He declined further investigations to exclude an underlying malignancy.

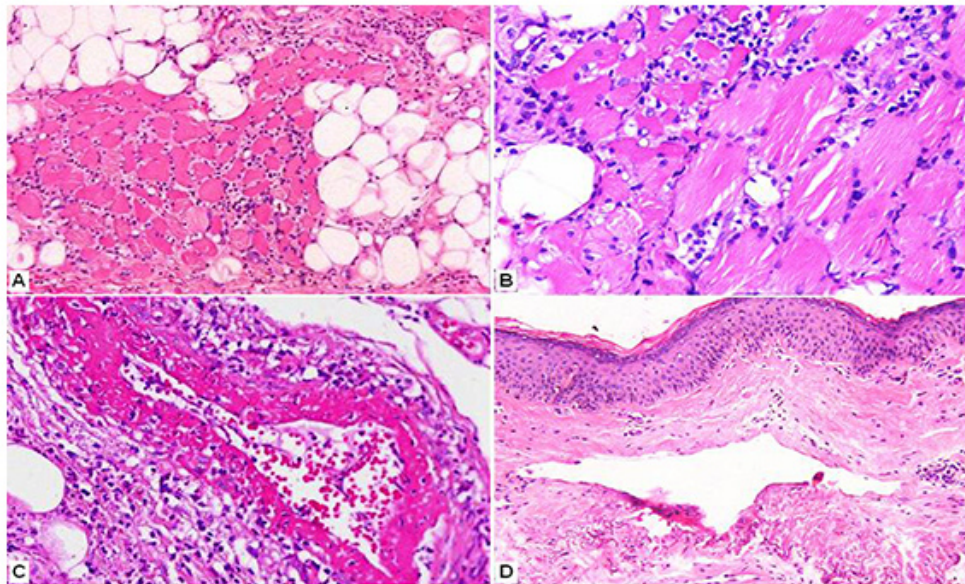


Figure 2. Skin and muscle biopsy. **A, B:** Myositis in the form of a mainly lymphocytic cellular infiltrate of striated muscle fibers with subsequent destruction and regeneration. (Hematoxylin and eosin x250, x400.) **C:** Leukocytoclastic vasculitis (fibrinoid necrosis and nuclear dust) in septal vessels of the subcutaneous tissue. (Hematoxylin and eosin x400.) **D:** Telangiectatic vessels in the reticular dermis, edema and a mild lymphocytic infiltrate. (Hematoxylin and eosin x200.)

Discussion

In its typical form, DM presents with the unique combination of inflammatory myopathy and characteristic cutaneous lesions (heliotrope periorbital edema, Gottron papules and sign, shawl and V-sign, holster sign). Internal organs (lungs, heart, and gastrointestinal tract) may become involved, contributing to the significant morbidity and mortality of patients with DM who are not diagnosed and treated at an early stage. The importance of timely diagnosis is enhanced by the fact that approximately 15% of adult patients with newly diagnosed DM either have a preexisting malignancy or will develop one within a few years following diagnosis^{1,2}. When clinical or laboratory manifestations of myopathy (proximal muscle weakness or elevated muscle enzyme levels in the serum) are absent, as was the case with our patient, DM may elude diagnosis. This can occur in the early stages of the illness, when muscle involvement may not yet be evident (“pre-myopathic DM”). The term “amyopathic DM” (synonym: dermatomyositis-sine-myositis) is usually reserved for patients with the hallmark cutaneous manifestations or histological findings of DM who have normal serum muscle enzyme levels and no muscle weakness for at least 6 months after the initial diagnosis (10–20% of all cases of DM, may be higher in Asian populations)³. A limitation of the present report is the lack of long-term outcome information because the patient was lost to follow-up.

Although cutaneous manifestations of DM commonly involve the face, isolated facial edema as the sole clinical sign of disease is an extremely rare occurrence. Such an atypical presentation can lead to significant delays in diagnosis. Hall *et al.* reported a case where DM was diagnosed only when the patient was hospitalized for dysphagia, six months after his initial presentation with severe periorbital edema⁴. Subcutaneous edema, usually localized or regional, is being increasingly recognized as a manifestation of DM and appears to be associated with more aggressive disease^{5,6}. The presumed pathophysiological mechanism involves

increased permeability of capillaries caused by complement-mediated microvascular endothelial damage. In DM, putative antibodies directed against antigens of capillary endothelium activate the classical complement pathway, resulting in deposition of membrane attack complex on capillary endothelial cells early in the inflammatory process⁷. This is in keeping with the low serum complement C3 levels present in our case. Other, non-immunological mechanisms might be contributing to increased capillary permeability: Levels of vascular endothelial growth factor (VEGF), which induces hyperpermeability by a direct action on endothelial cells, have been found to be increased in muscle tissue and plasma of patients with early-phase DM^{8,9}.

In conclusion, DM should be included in the differential diagnosis of patients presenting acutely with isolated facial edema of unknown cause, even when other clinical and laboratory manifestations of the disease are absent. An aggressive diagnostic approach with skin and muscle biopsy may enable early diagnosis and treatment of this potentially fatal disease.

Consent

Written informed consent for publication of his clinical details and clinical images was obtained from the patient.

Competing interests

No competing interests were disclosed.

Grant information

The author(s) declared that no grants were involved in supporting this work.

Acknowledgements

We thank Dr. Spiliotis Papanikolaou, General surgeon at “Amalia Fleming” General Hospital, for performing the skin and muscle biopsy.

References

- Dalakas MC, Hohlfeld R: **Polymyositis and dermatomyositis**. *Lancet*. 2003; **362**(9388): 971–82.
[PubMed Abstract](#) | [Publisher Full Text](#)
- Marie I: **Morbidity and Mortality in Adult Polymyositis and Dermatomyositis**. *Curr Rheumatol Rep*. 2012; **14**(3): 275–85.
[PubMed Abstract](#) | [Publisher Full Text](#)
- Gerami P, Schope JM, McDonald L, *et al.*: **A systematic review of adult-onset clinically amyopathic dermatomyositis (dermatomyositis sine myositis): a missing link within the spectrum of the idiopathic inflammatory myopathies**. *J Am Acad Dermatol*. 2006; **54**(4): 597–613.
[PubMed Abstract](#) | [Publisher Full Text](#)
- Hall VC, Keeling JH, Davis MD: **Periorbital edema as the presenting sign of dermatomyositis**. *Int J Dermatol*. 2003; **42**(6): 466–7.
[PubMed Abstract](#) | [Publisher Full Text](#)
- Milisenca JC, Doti PI, Prieto-González S, *et al.*: **Dermatomyositis presenting with severe subcutaneous edema: five additional cases and review of the literature**. *Semin Arthritis Rheum*. 2014; **44**(2): 228–33.
[PubMed Abstract](#) | [Publisher Full Text](#)
- Tu J, McLean-Tookey A, Junckerstorff R: **Increasing recognition of dermatomyositis with subcutaneous edema - is this a poorer prognostic marker?** *Dermatol Online J*. 2014; **20**(1): 21244.
[PubMed Abstract](#)
- Chen M, Daha MR, Kallenberg CG: **The complement system in systemic autoimmune disease**. *J Autoimmun*. 2010; **34**(3): J276–86.
[PubMed Abstract](#) | [Publisher Full Text](#)
- Grundtman C, Tham E, Ulfgren AK, *et al.*: **Vascular endothelial growth factor is highly expressed in muscle tissue of patients with polymyositis and patients with dermatomyositis**. *Arthritis Rheum*. 2008; **58**(10): 3224–38.
[PubMed Abstract](#) | [Publisher Full Text](#)
- Hippenstiel S, Krüll M, Ikemann A, *et al.*: **VEGF induces hyperpermeability by a direct action on endothelial cells**. *Am J Physiol Lung Cell Mol Physiol*. 1998; **274**(5 Pt 1): L678–84.
[PubMed Abstract](#) | [Publisher Full Text](#)

Open Peer Review

Current Referee Status:  

Version 2

Referee Report 03 April 2018

doi:[10.5256/f1000research.15685.r32410](https://doi.org/10.5256/f1000research.15685.r32410)

 **Lyubomir A. Dourmishev** 

Department of Dermatology and Venereology, Medical University, Sofia, Sofia, Bulgaria

No further remarks.

Competing Interests: No competing interests were disclosed.

I have read this submission. I believe that I have an appropriate level of expertise to confirm that it is of an acceptable scientific standard.

Version 1

Referee Report 05 March 2018

doi:[10.5256/f1000research.14778.r31365](https://doi.org/10.5256/f1000research.14778.r31365)

 **Albert Selva-O'Callaghan**

Department of Internal Medicine, Autonomous University of Barcelona, Barcelona, Spain

The authors report the case of a patient with periorbital and facial oedema in whom muscle biopsy allowed the diagnosis of myositis (probably DM). The skin biopsy in this case is not specific, absence of mucine and leukocytoclastic vasculitis are not typical of DM. This reviewer, nevertheless, agree that the most probably diagnosis is DM. In this case it would be appropriate to define it as a Clinically Amyopathic DM.

Determination of other specific autoantibodies would have been of help: anti-TIF1gamma, anti-PL12, anti-PL7, anti-SRP, anti-MDA5, or anti-NXP2.

In opinion of the reviewer, this presentation is not so rare.

Please comment or modify all these points.

Is the background of the case's history and progression described in sufficient detail?

Partly

Are enough details provided of any physical examination and diagnostic tests, treatment given and outcomes?

Partly

Is sufficient discussion included of the importance of the findings and their relevance to future understanding of disease processes, diagnosis or treatment?

No

Is the case presented with sufficient detail to be useful for other practitioners?

Yes

Competing Interests: No competing interests were disclosed.

I have read this submission. I believe that I have an appropriate level of expertise to confirm that it is of an acceptable scientific standard.

Author Response 22 Mar 2018

Efthymia Pappa, Amalia Fleming General Hospital, Greece

We thank Dr. Selva-O'Callaghan for critically reviewing our manuscript. Our response is as follows:

1. We have used the term "clinically amyopathic dermatomyositis" in the revised version, as suggested by both reviewers. We have also clarified that the skin biopsy findings were compatible with but not diagnostic of DM.
2. Among the autoantibodies specific for myositis, we only had access to anti-Mi2 and anti-Jo1. Anti-Mi2 tends to be positive in classical DM with typical skin manifestations and high muscle enzyme levels, both of which were absent in our case. Positive anti-Mi2 was reported in 38.8% of DM patients from the Indian subcontinent (P Srivastava *et al.* Rheumatol Int 2016, DOI 10.1007/s00296-016-3494-3). In the same ethnic group, Jo1 was detected in 5.4% of DM patients.
3. Although the face is frequently the only area affected in dermatomyositis, particularly in the early stages, we could find no published cases of adult DM presenting with isolated facial edema without rash or muscle enzyme abnormalities.

Competing Interests: No competing interests were disclosed.

Referee Report 15 February 2018

doi:10.5256/f1000research.14778.r30305



Lyubomir A. Dourmishev

Department of Dermatology and Venereology, Medical University, Sofia, Sofia, Bulgaria

The case report presents the diversity of clinical variants in autoimmune inflammatory myopathies. Clinical case is present briefly, but the information is sufficient.

My critical remarks are:

1. It is not clear how the authors clinically assess the muscle weakness;
2. Authors state creatine phosphokinase, aspartate aminotransferase and lactic dehydrogenase are in normal ranges. What about alanine aminotransferase and aldolase?
3. I would suppose the term clinical amyopathic dermatomyositis, since muscle biopsy shows definite features of myositis and thus is the key evidence for diagnosis.
4. It is not indicated the place of muscle biopsy.
5. I would recommend discussing the orbital myositis as a possible differential diagnosis.
6. Investigation of anti-MDA5 and may have value in this case.

In conclusion article is interesting and after some corrections will be useful for variety of medical specialists.

Is the background of the case's history and progression described in sufficient detail?

Partly

Are enough details provided of any physical examination and diagnostic tests, treatment given and outcomes?

Partly

Is sufficient discussion included of the importance of the findings and their relevance to future understanding of disease processes, diagnosis or treatment?

Partly

Is the case presented with sufficient detail to be useful for other practitioners?

Partly

Competing Interests: No competing interests were disclosed.

I have read this submission. I believe that I have an appropriate level of expertise to confirm that it is of an acceptable scientific standard, however I have significant reservations, as outlined above.

Author Response 22 Mar 2018

Efthymia Pappa, Amalia Fleming General Hospital, Greece

We thank Professor Dourmishev for his constructive comments, which we took into account in revising the manuscript. Our detailed response to his remarks is as follows:

1. Muscle weakness was assessed by clinical examination. No abnormalities were detected on repeated clinical assessment of muscle tone, power and tendon reflexes. A relevant passage has been included in the revised text.
2. Serum alanine aminotransferase levels were also normal. This has been stated in the revised text. Aldolase levels were normal – this is stated in the original text (paragraph 4, line 5 of case report section).

3. We have used the more accurate term “Clinically amyopathic dermatomyositis” as suggested by the reviewer.
4. We have indicated the site of biopsy (right malar area) in the revised text.
5. Orbital myositis has been included in the differential diagnosis as suggested.
6. We only had access to Jo1 and Mi2 autoantibodies at that time, and therefore no anti-MDA5 or other autoantibodies of potential value in DM could be looked for. We note, however, the low sensitivity of such antibodies. Only 6.9% of DM patients in a recent USA study had positive anti-MDA5, and most of these had overt myopathy (JC Hall *et al.* Arthritis Care Res. (Hoboken) 2013; 65: 1307-15).

Competing Interests: No competing interests were disclosed.

The benefits of publishing with F1000Research:

- Your article is published within days, with no editorial bias
- You can publish traditional articles, null/negative results, case reports, data notes and more
- The peer review process is transparent and collaborative
- Your article is indexed in PubMed after passing peer review
- Dedicated customer support at every stage

For pre-submission enquiries, contact research@f1000.com

F1000Research