

Successful flow reduction surgery for a ruptured true posterior communicating artery aneurysm caused by the common carotid artery ligation for epistaxis

Yukihiro Yamao, Jun C. Takahashi¹, Tetsu Satow¹, Koji Iihara², Susumu Miyamoto

Departments of Neurosurgery, Kyoto University Graduate School of Medicine, Kyoto, ¹Neurosurgery, National Cerebral and Cardiovascular Research Center Hospital, Osaka, ²Neurosurgery, Graduate School of Medical Sciences, Kyusyu University, Fukuoka, Japan

E-mail: *Yukihiro Yamao - yyamao@kuhp.kyoto-u.ac.jp; Jun C. Takahashi - juntak@kuhp.kyoto-u.ac.jp; Tetsu Satow - tetsus@ncvc.go.jp;

Koji Iihara - kiihara@ns.med.kyushu-u.ac.jp; Susumu Miyamoto - miy@kuhp.kyoto-u.ac.jp

*Corresponding author

Received: 09 July 14 Accepted: 12 September 14 Published: 28 November 14

This article may be cited as:

Yamao Y, Takahashi JC, Satow T, Iihara K, Miyamoto S. Successful flow reduction surgery for a ruptured true posterior communicating artery aneurysm caused by the common carotid artery ligation for epistaxis. *Surg Neurol Int* 2014;5:S501-5.

Available FREE in open access from: <http://www.surgicalneurologyint.com/text.asp?2014/5/15/501/145657>

Copyright: © 2014 Yamao Y. This is an open-access article distributed under the terms of the Creative Commons Attribution License, which permits unrestricted use, distribution, and reproduction in any medium, provided the original author and source are credited.

Abstract

Background: Carotid artery occlusion can lead to the development of rare true posterior communicating artery (PCoA) aneurysms because of hemodynamic stress on the PCoA. Surgical treatment of these lesions is challenging.

Case Description: The authors report a case of a true PCoA aneurysm that developed and ruptured 37 years after ligation of the ipsilateral common carotid artery for epistaxis. The lesion was successfully treated with clipping of the distal M1 segment of the middle cerebral artery (MCA) after the occipital artery-radial artery free graft-MCA bypass, which led to extreme reduction in collateral flow through the PCoA. A cortical branch, located just proximal to the obliteration site, functioned as a sufficient flow outlet. The aneurysm shrank, and the patient has been doing well without any symptoms for 5 years after surgery.

Conclusions: M1 obliteration combined with high-flow extra-intracranial bypass might be a promising option for a true PCoA aneurysm, and therapeutic design that leaves a sufficient flow outlet on the M1 is mandatory to avoid unexpected occlusion of the M1 and its perforators.

Key Words: Common carotid artery ligation, extra-intracranial bypass, flow reduction, true posterior communicating artery aneurysm

Access this article online

Website:

www.surgicalneurologyint.com

DOI:

10.4103/2152-7806.145657

Quick Response Code:



INTRODUCTION

A true posterior communicating artery (PCoA) aneurysm is defined as an aneurysm originating with and involving the PCoA itself.^[16] This aneurysm is extremely rare, comprising only 0.1–2.8% of all intracranial aneurysms.^[3,4] Carotid artery occlusion, whether iatrogenic, atherosclerotic, or congenital, can lead to the development and rupture of a true PCoA aneurysm, probably because of long-standing hemodynamic stress

on the PCoA, which functions as a critical collateral pathway.^[1,13] In such cases, both surgical and endovascular treatment is challenging because they are not amenable to simple neck clipping or coil embolization. The authors herein report a case of a ruptured true PCoA aneurysm detected 37 years after ligation of the ipsilateral common carotid artery (CCA) for epistaxis. The lesion was successfully treated by means of clipping of the distal M1 segment of the middle cerebral artery (MCA) with the occipital artery (OA)-radial artery (RA) free graft-MCA

bypass, which led to extreme reduction of the collateral flow through the PCoA.

CASE REPORT

History and findings

A 62-year-old female presented with sudden headache and vomiting was referred to our institute. Her consciousness level was evaluated as 14 points on the Glasgow Coma Scale (E3V5M6), and no weakness was observed in her extremities. Computed tomography (CT) demonstrated subarachnoid hemorrhage [SAH; Figure 1a]. An interview revealed that she had experienced massive epistaxis and had been treated with emergent ligation of the right CCA at the age of 25. She had also suffered from SAH caused by rupture of a left internal carotid artery (ICA) aneurysm that had been treated by means of neck clipping at the age of 37.

Emergent digital subtraction angiography (DSA) revealed that the right CCA was occluded at its origin [Figure 2a]. The blood flow to the right MCA territory came mainly from the right posterior cerebral artery (PCA) through the enlarged PCoA, and an irregular-shaped aneurysm was found on the right PCoA [Figures 1b and 2b, c]. A right vertebral artery (VA) injection also detected collateral blood flow from the VA to the OA (through the dilated muscle branches) that had reversed toward the right external carotid artery (ECA) and the carotid bifurcation [Figure 2d]. The right ICA, ECA, and

superficial temporal artery (STA) were found to be extremely small in caliber. The left ICA aneurysm had been completely clipped [Figure 2c]. The parietal branch of the left STA had been sacrificed by the previous craniotomy.

Diagnosis of the ruptured true PCoA aneurysm was made from the radiological data. The lesion did not appear amenable to simple neck clipping or coil embolization. Trapping of the PCoA with bypass to the anterior circulation was considered, but insufficient flow of the ECA precluded a standard bypass strategy such as STA-MCA bypass or ECA-RA-MCA bypass. In addition, trapping of the PCoA could cause thrombosis of the perforators arising from the PCoA, which could lead to thalamic infarction. A surgical treatment strategy in the acute stage, therefore, was abandoned, and the patient was kept under sedation for 14 days. When the sedative was discontinued, she was found to have right oculomotor nerve palsy (anisocoria) and mild left hemiparesis. Repeated DSA did not demonstrate vasospasm, but demonstrated enlargement of the aneurysm [Figure 1c].

Surgical treatment

Surgery to reduce the PCoA flow was designed to prevent rebleeding and further growth of the aneurysm. The strategy consisted of (i) OA-RA free graft-MCA bypass and (ii) subsequent obliteration of the distal M1 portion of the right MCA with a clip [Figure 3]. Although the patient initially refused surgery, informed consent was

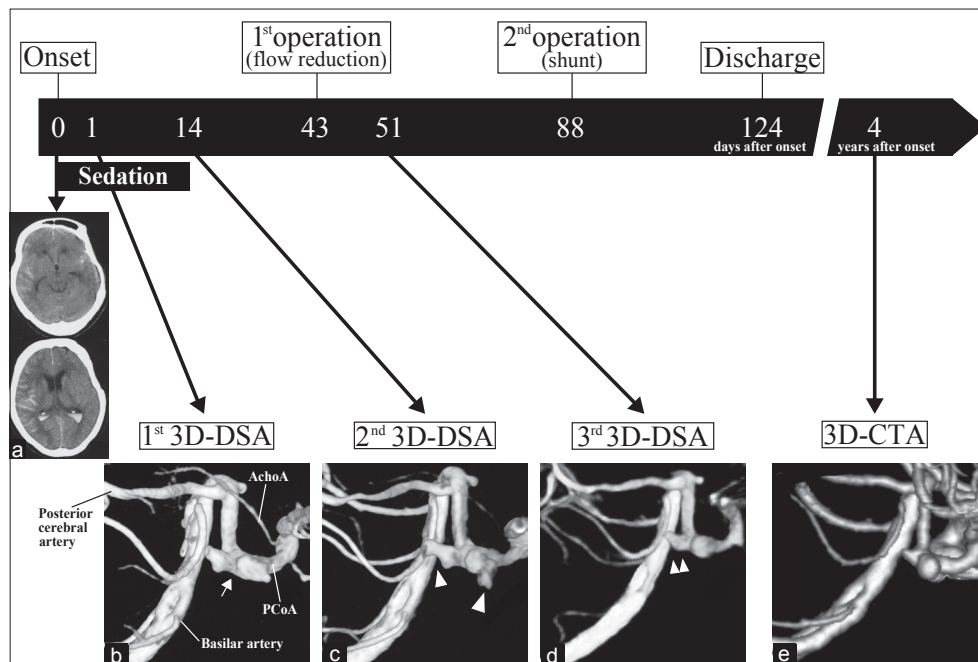


Figure 1: Schema of the timing of imaging and surgery. (a) CT image obtained at onset showing subarachnoid hemorrhage. **(b)** Three-dimensional digital subtraction angiography (3D-DSA) showing an irregular-shaped aneurysm on the right posterior communicating artery (white arrow). **(c)** Follow-up 3D-DSA showing enlargement of the aneurysm (white arrowhead). **(d)** Postoperative 3D-DSA showing reduction of the aneurysm (double white arrowheads). **(e)** Follow-up three-dimensional CT angiography (3D-CTA) after 4 years showing further reduction of aneurysm

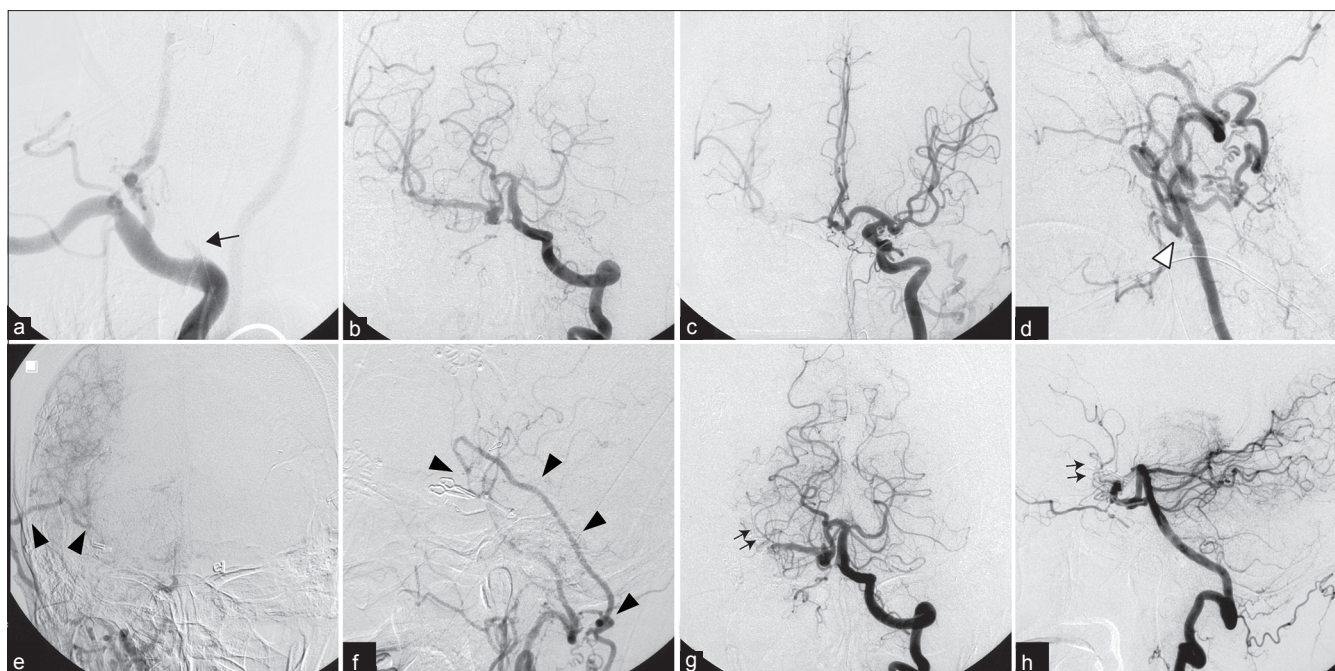


Figure 2: DSA before (a-d) and after surgery (e-f). (a) The right CCA occluded at its origin (arrow). (b, c) The blood flow to the right MCA territory originated mainly from the right PCA through the enlarged PCoA. The left ICA aneurysm had been completely clipped. (d) The blood flow from VA to OA (through the dilated muscle branches) had reversed toward ECA and the carotid bifurcation (white arrowhead). (e, f) The bypass was patent (arrow head). (g, h) The flow through the PCoA finally directed to the cortical artery of the distal M1, preserving the flow of M1 and its perforators (double arrows)

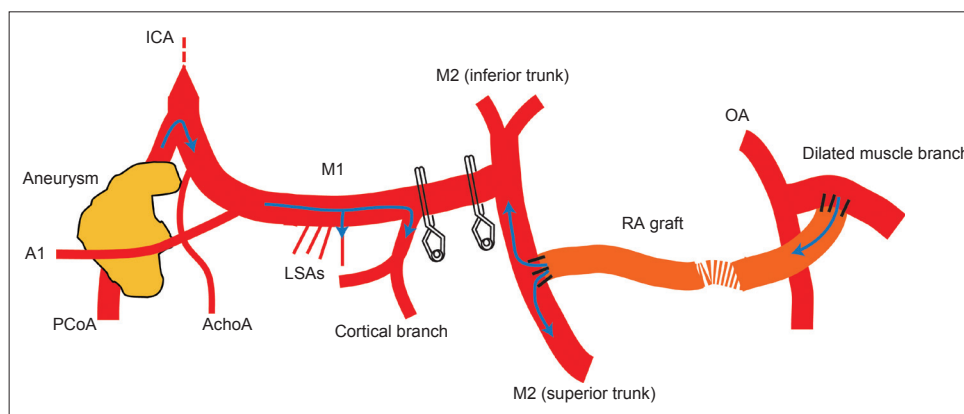


Figure 3: The diagram of surgical flow reduction. The radial artery graft was anastomosed to the M2, and the M1 segment was obliterated with two Sugita Elgiloy clips just distal to bifurcation of the cortical branch. The opposite side of the radial artery graft was anastomosed to the dilated muscle branch of the occipital artery. **AchoA: Anterior choroidal artery; LSA: Lenticulostriate artery**

obtained finally, and the operation was performed 43 days after the hemorrhagic onset.

The patient was positioned supine with her head turned 80° to the left. A retromastoid linear incision was made to expose the OA and its dilated muscle branch. The RA was harvested from her left forearm. After the right frontotemporal craniotomy, the RA graft was implanted from the retromastoid field to the frontotemporal field through the subcutaneous tunnel. The Sylvian fissure was opened and the superior and inferior trunk (M2) of the MCA was exposed. The RA graft was anastomosed

to the superior trunk in end-to-side fashion with interrupted 10-0 nylon sutures. Subsequently, the opposite side of the RA was anastomosed to the dilated muscle branch of the OA with interrupted 9-0 nylon sutures. After the bypass was opened, the M1 segment of the MCA was observed carefully. A cortical branch with 2 mm in caliber was found to originate from the M1 approximately 1.5 cm proximal to the MCA bifurcation. The M1 was then obliterated with two Sugita Elgiloy clips just distal to this point, leaving the cortical branch proximally to function as a flow-outlet

of the collateral flow through the PCoA [Figure 3]. The flow of the bypass was confirmed with a Doppler microprobe.

Postoperative course and follow-up

Postoperative DSA revealed sufficient bypass flow perfusing the MCA territory and extremely reduced collateral flow through the PCoA [Figure 2e-h]. This flow directed to the cortical artery of the distal M1 as designed during the operation, preserving the flow of the M1 and its perforators [Figure 2g, h]. The size and shape of the aneurysm appeared to be reduced [Figure 1d]. The oculomotor nerve palsy and the left hemiparesis gradually improved, suggesting the reduced mass effect of the aneurysm.

After the placement of the ventricular-peritoneum shunt system for the hydrocephalus, the patient was discharged without major sequelae. Three-dimensional CT angiography performed 4 years after surgery demonstrated further reduction of the aneurysm [Figure 1e]. She has remained asymptomatic as of last follow-up, 5 years after surgery.

DISCUSSION

Long-standing hemodynamic stress following CCA occlusion can cause an ipsilateral true PCoA aneurysm.^[6,11,13] In the present case, the patient had undergone cervical CCA ligation for massive epistaxis at the age of 25. DSA on admission revealed that blood flow of the right MCA territory was supplied mainly from the PCA through the enlarged PCoA. Therefore, it is speculated that the PCoA had been subjected to excessive hemodynamic stress for 37 years, which led to the development of the true PCoA aneurysm and its rupture.

In the present case, a flow reduction strategy was adopted instead of conventional trapping of the PCoA. True PCoA aneurysms are usually not amenable to neck clipping, and the only surgical strategy reported has been the trapping of the aneurysm and the PCoA.^[3,10] This trapping surgery, however, poses the risk of ischemic complications caused by sacrifice of the perforators originating from the PCoA,^[3] which supply vital structures.^[12] Some authors have reported successful trapping of the PCoA without ischemic complications,^[10] which may be attributable to rich collateral flow from other vessels such as the posterolateral choroidal artery.^[7] The authors, however, avoided PCoA trapping for fear of ischemic complications that could severely affect the patient, who had exhibited good neurological status so far.

Obliteration of the distal M1 had reduced the collateral flow through the PCoA. The cortical branch remaining just proximal to the obliteration site functioned as a sufficient flow outlet, and the flow of the M1 and its

perforators were well preserved. Although the aneurysm did not disappear, it did shrink, and the patient has been doing well for 5 years. Few reports exist regarding this kind of flow reduction surgery in MCA and basilar artery aneurysms.^[5,9,15] To the authors' knowledge, this is the first report of flow reduction targeting a true PCoA aneurysm.

OA-RA-MCA bypass was used to secure the MCA territory from the hemodynamic ischemia caused by the M1 clipping. Because the ipsilateral CCA had been previously occluded and the ECA was small in caliber, the authors judged that STA-MCA bypass or ECA-RA-MCA bypass was insufficient to supply the entire MCA territory. Bypass grafting from the contralateral STA, known as a "Bonnet" bypass, has been reported.^[2,10,12] In the present case, however, this strategy could not be adopted because the contralateral STA had been sacrificed in the previous craniotomy. A few reports exist of the OA-MCA bypass^[14] or VA-RA-MCA bypass.^[2,8] In the present case, the caliber of the distal OA was insufficient, and taking the transylvian approach and the VA-RA-MCA bypass simultaneously seemed rather difficult due to the head position.

Surgical treatment of a secondarily formed, flow-related unclippable true PCoA aneurysm is quite challenging. Judging from the clinical course of the present case, M1 obliteration combined with high-flow extra-intracranial bypass might be a promising option. Obliteration designed to leave a sufficient flow outlet is mandatory to avoid unexpected occlusion of the M1 and its perforators.

REFERENCES

1. Arnaout OM, Rahme RJ, Aoun SG, Daou MR, Batjer HH, Bendok BR. De novo large fusiform posterior circulation intracranial aneurysm presenting with subarachnoid hemorrhage 7 years after therapeutic internal carotid artery occlusion: Case report and review of the literature. *Neurosurgery* 2012;71:E764-71.
2. Hadeishi H, Yasui N, Okamoto Y. Extracranial-intracranial high-flow bypass using the radial artery between the vertebral and middle cerebral arteries. Technical note. *J Neurosurg* 1996;85:976-9.
3. He W, Gandhi CD, Quinn J, Karimi R, Prestigiacomo CJ. True aneurysms of the posterior communicating artery: A systematic review and meta-analysis of individual patient data. *World Neurosurg* 2011;75:64-72.
4. He W, Hauptman J, Pasupuleti L, Setton A, Farrow MG, Kasper L, et al. True posterior communicating artery aneurysms: Are they more prone to rupture? A biomorphometric analysis. *J Neurosurg* 2010;112:611-5.
5. Kalani MY, Zabramski JM, Nakaji P, Spetzler RF. Bypass and flow reduction for complex basilar and vertebrobasilar junction aneurysms. *Neurosurgery* 2013;72:763-75.
6. Kaspera W, Majchrzak H, Kopera M, Ładziński P. "True" aneurysm of the posterior communicating artery as a possible effect of collateral circulation in a patient with occlusion of the internal carotid artery. A case study and literature review. *Minim Invasive Neurosurg* 2002;45:240-4.
7. Matsumoto K, Kuriyama M, Tamiya T, Ohmoto T. Direct clip obliteration of a ruptured giant aneurysm of the posterior communicating artery: Case report. *Neurosurgery* 1997;41:939-42.
8. Miele VJ, Rosen CL, Carpenter J, Rai A, Bailes JE. Vertebral artery-to-middle cerebral artery bypass with coil embolization of giant internal carotid artery aneurysm: Technical case report. *Neurosurgery* 2005;56:E1159.

9. Miyamoto S, Funaki T, Iihara K, Takahashi JC. Successful obliteration and shrinkage of giant partially thrombosed basilar artery aneurysms through a tailored flow reduction strategy with bypass surgery. *J Neurosurg* 2011;114:1028-36.
10. Nakatsuka H, Ohta S, Kuroda J, Moriwaki T, Maeda Y, Sakaki S. Ruptured true posterior communicating artery fusiform aneurysm: Case report. *No Shinkei Geka* 2007;35:691-6.
11. Ogasawara K, Numagami Y, Kitahara M. A case of ruptured true posterior communicating artery aneurysm thirteen years after surgical occlusion of the ipsilateral cervical internal carotid artery. *No Shinkei Geka* 1995;23:359-63.
12. Pedroza A, Dujovny M, Artero JC, Umansky F, Berman SK, Diaz FG, et al. Microanatomy of the posterior communicating artery. *Neurosurgery* 1987;20:228-35.
13. Santoro A, Passacantilli E, Guidetti G, Dazzi M, Guglielmi G, Cantore G. Bypass combined with embolization via a venous graft in a patient with a giant aneurysm in the posterior communicating artery and bilateral idiopathic occlusion of the internal carotid artery in the neck. *J Neurosurg* 2002;96:135-9.
14. Stoll A, Chater N. Long-term patency of occipital artery-middle cerebral artery bypass demonstrated by angiography. *Surg Neurol* 1981;16:41-3.
15. Takemoto K, Hatano T, Abekura Y, Takahashi JC, Miyamoto S. Successful flow reduction treatment for a middle cerebral artery aneurysm in a patient with systemic lupus erythematosus. *Neurol Med Chir* 2013;53:192-5.
16. Yoshida M, Watanabe M, Kuramoto S. "True" posterior communicating artery aneurysm. *Surg Neurol* 1979;11:379-81.