

# Hereditary protein C deficiency with portal vein thrombosis in a Chinese male: A case report

CHUN ZOU<sup>1\*</sup>, TINGYING LI<sup>2\*</sup>, LIU LONG<sup>1</sup>, LIU LIU<sup>3</sup> and JIAN ZHU<sup>1</sup>

<sup>1</sup>Department of Gastroenterology, Guizhou Provincial Orthopedics Hospital; <sup>2</sup>Department of Pediatrics, Guiyang Second People Hospital; <sup>3</sup>Department of Endocrinology, Guizhou Provincial Orthopedics Hospital, Guiyang, Guizhou 550014, P.R. China

Received September 13, 2022; Accepted October 17, 2022

DOI: 10.3892/etm.2022.11688

**Abstract.** Hereditary protein C deficiency (PCD) is caused by mutation in the PC gene (PROC). The homozygous mutation form of PCD is rare. Furthermore, in Asia, cases of noncirrhotic patients with portal vein thrombosis (PVT) secondary to PCD have been rarely reported. The present study reported the case of a patient with PVT due to hereditary PCD. Of note, the mutation of PROCc.152G>A was observed in the patient of the present study. According to the current literature, there has been no previous report regarding the mutation of this gene in China. The patient suffered abdominal pain for 20 days, which was accompanied by vomiting for 2 days. Multiple ulcers and diverticula in the sigmoid colon, as well as erosive small ulcers throughout the colon, were discovered during a colonoscopy. Abdominal angiography indicated thrombosis of the portal vein and its branches. Furthermore, laboratory parameters indicated a hypercoagulable state with normal PC antigen values but decreased PC activity. The discovery of blood coagulation-related genes suggested that homozygous mutation in PC resulted in an amino acid missense mutation. Anticoagulants were prescribed after a diagnosis of type II hereditary PCD with PVT was made. After 15 days, the blood coagulation function of the patient was restored to normal and the symptoms were substantially alleviated. Hence, the present study expanded the mutation spectrum of PROC in China and reaffirmed the value of anticoagulant therapy in PCD.

## Introduction

Hereditary protein C deficiency (PCD) is engendered by mutations in the PC gene (PROC) located on chromosome 2q14.3 (1). PCD has been estimated to affect 1 in 20,000 individuals who present with clinical symptoms (2). The liver produces a vitamin K-dependent serine protease, PC (1). Activated PC inhibits the activation of coagulation factor X and II by suppressing coagulation factors VIIIa and Va, respectively, thereby preventing coagulation. PCD is a risk factor for thrombosis, with symptoms involving an asymptomatic presentation, venous thromboembolism (VTE) and life-threatening neonatal purpura fulminans (1). According to the abnormal quantity and quality of PC, PCD is divided into two types. Type I is characterized by the simultaneous decrease of PC antigen (PC:Ag) and activity (PC:A). Type II is characterized by normal PC:Ag and decreased PC:A. Type II deficiency is less common compared with type I (3). In Asia, noncirrhotic patients with portal vein thrombosis (PVT) secondary to PCD have been rarely reported. The present study reported a patient with PVT caused by type II PCD. Furthermore, the mutation of PROCc.152G>A was observed in the patient of the present study, and according to the current literature, there has been no previous report of this mutation of this gene in China.

## Case report

A 30-year-old male visited Guizhou Provincial Orthopedics Hospital (Guiyang, China) in March 2019 due to abdominal pain and recurring episodes of vomiting. The patient had developed persistent distension pain in the left lower abdomen 20 days ago, with no radiating pain and certain relief in the knee flexion position. Two days previously, the patient experienced nonejective vomiting and vomiting immediately after eating; however, no fever, diarrhea, bloody stool or other discomfort were observed. When the patient was 21 years old, he had a filter for deep vein thrombosis inserted in the right lower extremity. Physical examination indicated deep tenderness in the left lower abdomen with no rebound pain and muscle tension.

From the laboratory examination, the following results were obtained: Increased leukocyte count ( $15.14 \times 10^9/l$ ; normal range:  $3.5-9.5 \times 10^9/l$ ) with increased neutrophils (78.5%; normal range:

---

*Correspondence to:* Dr Jian Zhu, Department of Gastroenterology, Guizhou Provincial Orthopedics Hospital, 206 Sixian Street, Baiyun, Guiyang, Guizhou 550014, P.R. China  
E-mail: 1169764090@qq.com

\*Contributed equally

*Abbreviations:* PCD, hereditary protein C deficiency; PC, protein C; PVT, portal vein thrombosis; VTE, venous thromboembolism; INR, international normalized ratio

*Key words:* protein C deficiency, venous thromboembolism, portal vein thrombosis, ischemic bowel disease, anticoagulants, case report

40-75%), increased C-reactive protein (142.15 mg/l; normal range: 0-10 mg/l), positive fecal occult blood test, increased fibrinogen degradation products (55  $\mu\text{g/ml}$ ; normal range, 0-5  $\mu\text{g/ml}$ ) and D-dimer (11.01  $\mu\text{g/ml}$ ; normal range, 0.00-1.00  $\mu\text{g/ml}$ ). Other laboratory tests indicated no signs of renal, hepatic, pancreatic or cardiac disease. Since the laboratory parameters indicated a hypercoagulable state and the patient was a young male with no obvious predisposing factors for recurrent vein thrombosis, exhaustive investigations were started. The screening results related to hereditary anticoagulant protease deficiency, as determined by chromogenic substrate, suggested normal PC antigen values (115.2%; normal range, 70.0-140%) and antithrombin III (101.5%; normal range, 75.0-125.0%), but diminished PC activity (35%; normal range, 70.0-130.0%) and protein S activity (69.5%; normal range, 75.0-130%). PC, PS and antithrombin III were determined by chromogenic substrate. Coagulation factor V and anticardiolipin antibodies were within the normal range. The patient was considered to have type II hereditary PCD based on decreased PC activity but normal PC antigen values. To identify disease-causing gene variants, blood coagulation-related genes (including 128 genes; Fig. S1) were determined by next generation high-throughput sequencing (MyGenostics Inc., Beijing, China). The results indicated that a homozygous mutation in PC resulted in an amino acid missense mutation (Fig. 1), i.e., compared with the normal PC gene (Fig. 1A), the nucleotide site 152 of exon 3, which was located in the light chain of PC encoded by chromosome 2 and was mutated from guanine to adenine (Fig. 1B), resulting in the mutation of amino acid 9 of PC light chain from arginine to histidine (Fig. 1F and G). Further analysis of the PC gene of the mother, maternal grandmother and paternal grandfather revealed that the mother's PC had a heterozygous mutation (Fig. 1D), whereas those of the maternal grandmother and paternal grandfather did not (Fig. 1C-E). For various reasons, such as the death of the patient's father in a car accident (the father had no syndromes associated with thrombosis during his lifetime), only the patient's mother, maternal grandmother and paternal grandfather were genetically tested. However, the proband had a homozygous mutation and the proband's mother had a heterozygous mutation. It was thus inferred that the proband's father had a heterozygous mutation as well. The patient's parents were carriers of pathogenic genes and the genetic pattern was of autosomal recessive inheritance (Fig. 1H).

In terms of imaging examinations, abdominal computerized tomography (CT) revealed incomplete small intestinal obstruction and proximal intestinal wall thickening, considering the possibility of ischemia. During gastroscopy, a varicose vein in the fundus of the stomach was observed (Fig. 2A). Multiple ulcers and diverticula in the sigmoid colon, as well as erosive small ulcers throughout the colon, were discovered during a colonoscopy (Fig. 2B). A colonic pathological examination revealed moderate chronic mucous membrane inflammation with erosion and lamina propria hemorrhage. Since the patient's laboratory examination indicated a hypercoagulable state and colonoscopy suggested multiple erosion and ulcer formation of the whole colon, abdominal angiography was performed to identify ischemic bowel disease. Abdominal angiography revealed thrombosis of the portal vein and its branches (Fig. 2C); thus, it was speculated that ischemic bowel disease was the cause of the patient's abdominal pain.

The patient was diagnosed with type II hereditary PCD with PVT and ischemic bowel disease. Anticoagulant therapy was provided after definite diagnosis (low-molecular-weight heparin, 5,000 U every 12 h for 10 days, which was then changed to oral warfarin 3 mg/day). After 15 days, the patient's blood coagulation function was restored to normal and the symptoms were substantially relieved. The patient was discharged from the hospital with instructions to take warfarin 3 mg/day and to keep the international normalized ratio (INR) at 2-3. However, the patient did not take his medication as prescribed on a regular basis and did not monitor his blood coagulation function. Over 20 days after discharge, the patient went to a local hospital for oliguria and was diagnosed with 'acute renal failure' (the specific diagnosis and treatment were unknown), and was discharged after treatment. Two months later, the patient had sudden convulsions and loss of consciousness at home and died after  $\sim 1$  h.

## Discussion

Hereditary PCD comprises mostly autosomal dominant and heterozygous mutations, whereas certain cases feature autosomal recessive, homozygous or compound heterozygous mutation (4). These patients usually have severe PCD, as well as early-onset and severe clinical symptoms, such as skin purpura fulminans, pulmonary embolism and disseminated intravascular coagulation (4). Severe PCD (homozygous or compound heterozygous form) is rare with an incidence of 1 in 500,000-1 in 750,000 births (5). PROC mutations include missense mutations, frameshift mutations, nonsense mutations and splice site abnormalities, with missense mutations being the most common. To date, 391 different PROC gene mutations have been reported worldwide, most of which are from Western populations and a smaller number from Asian populations (6-9). The most common gene mutations in the Chinese population are PROCc.565C>T and PROCc.10230C>T (10,11). PROCc.152G>A was observed in the patient of the present study. As per the current literature, there has been no report regarding the mutation of this gene in China. However, the mutation is associated with PCD, as reported by a study from Italy (11).

PVT unrelated to solid malignancy is common in patients with cirrhosis; however, it is less frequently observed in patients without cirrhosis. Failure to detect and treat thromboses may lead to mesenteric ischemia, chronic cavernous transformation and portal hypertension complications (12). Previously reported cases of PVT caused by PCD in the literature are summarized and compared in Table I. PVT induced by PCD exhibits a chronic onset and cavernous transformation of the portal vein; i.e., development or dilatation of small vessels around the main trunk of the portal vein (13,14). Anticoagulant therapy is currently considered the gold standard to achieve portal vein recanalization. The European Association for the Study of the Liver published a guideline in 2015 and recommended initial treatment with low-molecular-weight heparin targeting a level of 0.5-0.8 IU/ml, which is based on a grade A1 level of evidence (15). Oral vitamin K antagonists are used for long-term anticoagulant treatment targeting an INR of 2-3, based on a grade B1 level of evidence (15). Anticoagulant therapy achieved remarkable results in the reported cases (Table I) as well as the present case.

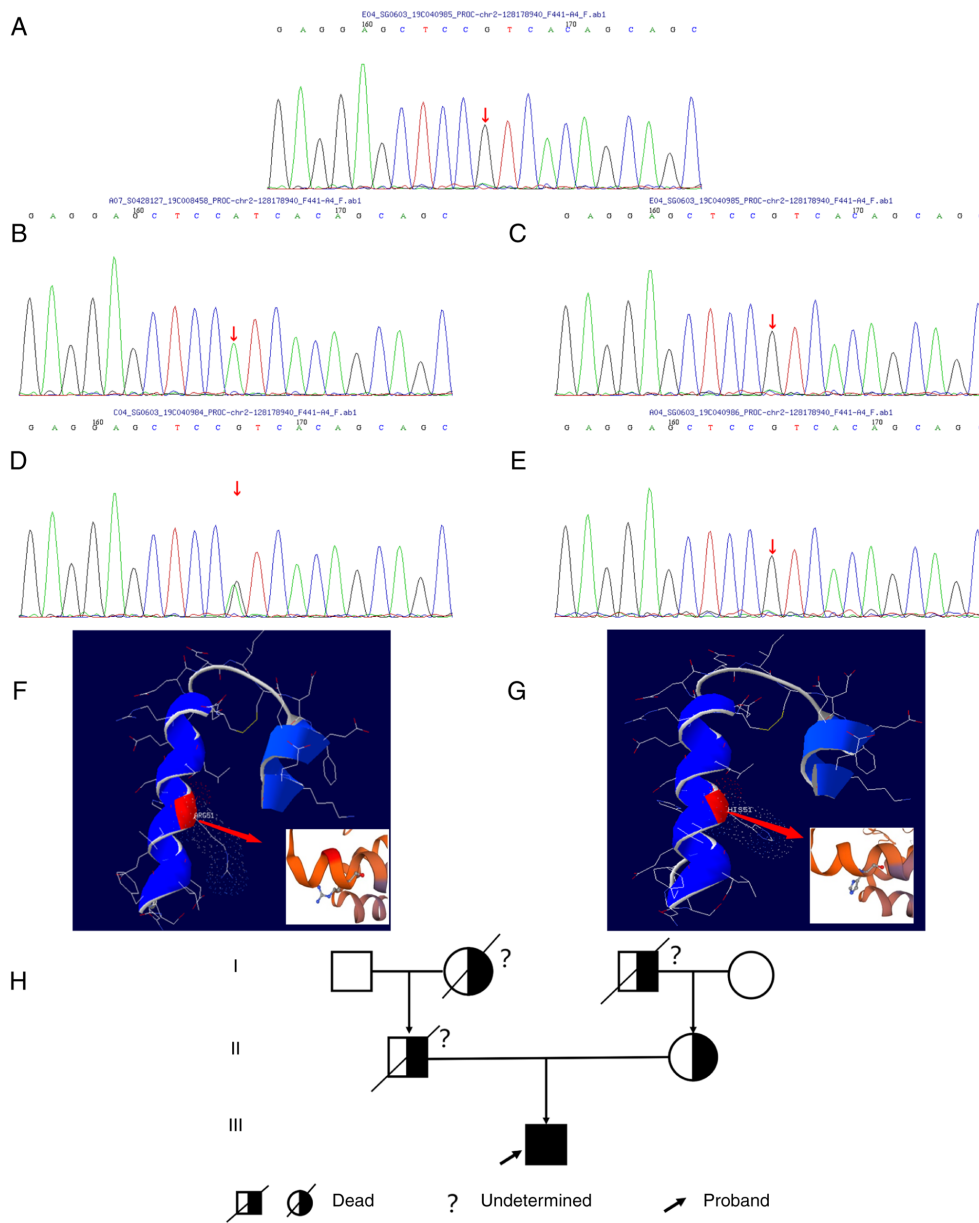


Figure 1. Results of protein C gene detection. (A) Normal PC gene reference sequence. (B) The patient had a homozygous mutation in the protein C gene. The nucleotide site 152 of the transcriptional exon 3, which was located in the light chain of protein C encoded by chromosome 2 and was mutated from guanine to adenine (c.152G>A); (C) there was no mutation in the protein C gene of the patient's maternal grandmother; (D) the patient's mother exhibited a heterozygous mutation in the protein C gene; (E) there was no mutation in the protein C gene of the patient's paternal grandfather. The mutation site is indicated with a red arrow. (F) Three-dimensional reconstruction of wild-type protein C and (G) three-dimensional reconstruction of mutated protein C. The ninth amino acid of protein C light chain was mutated from arginine to histidine and the guanidine group on arginine was changed to heterobenzene ring on histidine. (H) Pedigree chart. The arrow points at the proband.

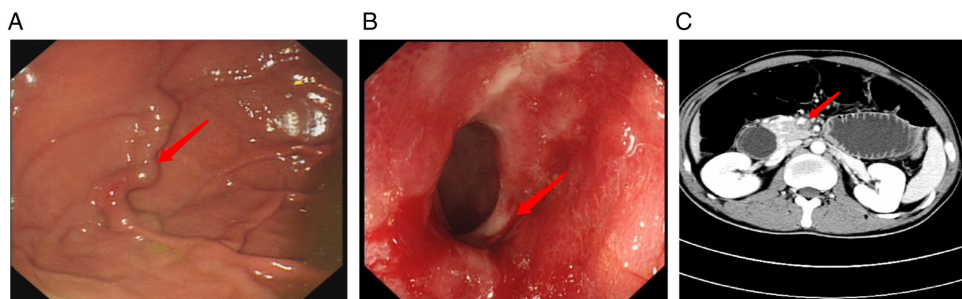


Figure 2. Supplementary examination. (A) Gastroscopy revealed a varicose vein in the fundus of the stomach. The red arrow points at the varicose vein. (B) Colonoscopy indicated scattered spots and small ulcers throughout the whole colon mucosa, particularly in the ileocecal area. The red arrow points at ulcers. (C) Contrast-enhanced computed tomography: Small nodular and short striped filling defects were seen in the portal vein. The red arrow points at the thrombosis.

Table I. Cases of PVT caused by hereditary PC deficiency reported in the literature.

Author, year	N	Age/sex	PVT or MVT	Symptoms	PC values/PC activity, %	Treatments	Survival status at last follow-up	(Refs.)
Momoi, 2003	1	39/M	MVT	Abdominal pain/melena	58/44	Anticoagulant/surgical	Alive (12 months)	(13)
Mitani, 1999	1	83/M	MVT	Abdominal pain/vomiting	45/45	Anticoagulant/surgical	Alive (16 months)	(22)
Yates, 1991	2	27/F	MVT	Suprapubic pain/urinary symptoms	46/-	Anticoagulant/surgical	Alive (-)	(23)
		24/M	MVT	Abdominal pain/vomiting	36/-	Anticoagulant/surgical	Alive (-)	
Hsu, 2015	1	47/M	MVT	Melaena	33.6/-	Anticoagulant	Alive (17 months)	(24)
Matsushita, 2000	1	64/M	MVT	Leg edema/hypoproteinemia	40/37	Anticoagulant/activated PC concentrate	Alive (18 months)	(25)
Valla, 1988	1	45/M	PVT	Abdominal pain/melaena	37/45	-	-	(26)
Rodríguez-Leal, 2014	1	63/M	PVT	Abdominal pain/nausea/diarrhea	39/54	Anticoagulant	Alive (36 months)	(14)
Yang, 1999	2	25/M	PVT	Abdominal pain/fever	55/-	Anticoagulant	Alive (60 months)	(27)
		31/M	PVT/MVT	Oesophageal variceal bleeding	-/-	Anticoagulant/surgical	Alive (36 months)	
Orozco, 1988	2	27/M	PVT/MVT	Upper gastrointestinal hemorrhage	10% of normal/-	Anticoagulant/surgical	Alive (24 months)	(28)
		55/M	PVT/MVT	Upper gastrointestinal hemorrhage	10% of normal/-	Anticoagulant/surgical	Alive (2 months)	
Choi, 2011	1	66/M	PVT	Fever/stomach ache/nausea	41/-	Anticoagulant	Alive (6 months)	(29)

MVT, mesenteric venous thrombosis; PVT, portal vein thrombosis; PC, protein C; M, male; F, female; N, number; -, no record.

Review of the medical history of the case of the present study indicated that the patient experienced multiple venous thromboses, including deep venous thrombosis of the right lower limb at the age of 21, and during hospitalization, thrombosis of the portal vein and its branches was revealed by abdominal arteriovenous CT imaging. The diagnosis of acute renal failure from the local hospital after discharge may be attributed to renal vein thrombosis. Hereditary PCD may increase the risk of thrombosis (1). In addition to deep venous thrombosis, cerebral infarction has been reported (16-18). In the present case, sudden convulsions and loss of consciousness at the time of death may have resulted from cerebral infarction caused by PCD. A previous study demonstrated that in heterozygous individuals, thrombotic episodes occur at the age of 30-40 years and is rare prior to the age of 20 years (19). In the patient of the present study, the age at onset of the first thrombotic episode was 21 years, which is the average age of the first onset of VTE in homozygous individuals and was earlier than that in heterozygous individuals (4).

Replacement of PC and the use of oral anticoagulant therapy to treat and prevent thrombosis are the currently applied treatments for severe PCD (1). Long-term anticoagulant therapy is critical for patients with PCD (20). The anticoagulant treatment of the patient of the present study achieved remarkable results (blood coagulation function returned to normal and abdominal pain was significantly reduced). Of note, warfarin-induced skin necrosis is a serious potential complication of PCD that occurs in adult patients (21), generally on the third or fourth day after starting warfarin. Pain, bruising and redness in the affected area are the first symptoms, and lesions may progress to a well-demarcated, inflamed lesion, and eventually to skin necrosis (21). PC replacement therapy has been indicated to be an effective treatment for patients with warfarin-induced skin necrosis, in association with low-molecular-weight heparin (5).

In conclusion, PCD is a predisposing cause of PVT, particularly in patients with noncirrhotic, thrombosis-related portal hypertension. Clinicians should focus on the differential diagnosis of unknown vascular diseases, particularly in younger patients. When routine tests fail to determine the cause of thromboembolic disease, additional examinations of hereditary anticoagulant protease deficiency and genetic testing are necessary. According to our successful experience with the present case, long-term anticoagulant therapy is a crucial treatment step for patients with PCD. However, care should be taken to avoid warfarin-induced skin necrosis during treatment.

### Acknowledgements

Not applicable.

### Funding

No funding was received.

### Availability of data and materials

The datasets used and/or analyzed during the current study are available from the corresponding author upon reasonable request.

### Authors' contributions

CZ, TL and JZ designed the experiments. LLo and LLI collected and evaluated the clinical data. CZ drafted the manuscript. CZ, TL and JZ confirm the authenticity of all the raw data. All authors read and approved the final manuscript.

### Ethics approval and consent to participate

Not applicable.

### Patient consent for publication

The patient provided written informed consent for the treatment, interventions, images, data collection and submission of this article for publication prior to his death. Furthermore, the patient's relatives (mother, grandmother, grandfather) provided written informed consent for the publication of this case report and all accompanying results of genetic testing.

### Competing interests

The authors declare that they have no competing interests.

### References

1. Dinarvand P and Moser KA: Protein C deficiency. *Arch Pathol Lab Med* 143: 1281-1285, 2019.
2. Dahlbäck B: The protein C anticoagulant system: Inherited defects as basis for venous thrombosis. *Thromb Res* 77: 1-43, 1995.
3. Kottke-Marchant K and Comp P: Laboratory issues in diagnosing abnormalities of protein C, thrombomodulin, and endothelial cell protein C receptor. *Arch Pathol Lab Med* 126: 1337-1348, 2002.
4. Pescatore SL: Clinical management of protein C deficiency. *Expert Opin Pharmacother* 2: 431-439, 2001.
5. Goldenberg NA and Manco-Johnson MJ: Protein C deficiency. *Haemophilia* 14: 1214-1221, 2008.
6. Gandrille S, Greengard JS, Alhenc-Gelas M, Juhan-Vague I, Abgrall JF, Jude B, Griffin JH and Aiach M: Incidence of activated protein C resistance caused by the ARG 506 GLN mutation in factor V in 113 unrelated symptomatic protein C-deficient patients. The French network on the behalf of INSERM. *Blood* 86: 219-224, 1995.
7. Miyata T, Sakata T, Yasumuro Y, Okamura T, Katsumi A, Saito H, Abe T, Shirahata A, Sakai M and Kato H: Genetic analysis of protein C deficiency in nineteen Japanese families: Five recurrent defects can explain half of the deficiencies. *Thromb Res* 92: 181-187, 1998.
8. Reitsma PH, Poort SR, Allaart CF, Briët E and Bertina RM: The spectrum of genetic defects in a panel of 40 Dutch families with symptomatic protein C deficiency type I: Heterogeneity and founder effects. *Blood* 78: 890-894, 1991.
9. Shen MC, Lin JS and Tsay W: High prevalence of antithrombin III, protein C and protein S deficiency, but no factor V Leiden mutation in venous thrombophilic Chinese patients in Taiwan. *Thromb Res* 87: 377-385, 1997.
10. Ding Q, Shen W, Ye X, Wu Y, Wang X and Wang H: Clinical and genetic features of protein C deficiency in 23 unrelated Chinese patients. *Blood Cells Mol Dis* 50: 53-58, 2013.
11. Faioni EM, Hermida J, Rovida E, Razzari C, Asti D, Zeinali S and Mannucci PM: Type II protein C deficiency: Identification and molecular modelling of two natural mutants with low anticoagulant and normal amidolytic activity. *Br J Haematol* 108: 265-271, 2000.
12. Intagliata NM, Caldwell SH and Tripodi A: Diagnosis, development, and treatment of portal vein thrombosis in patients with and without cirrhosis. *Gastroenterology* 156: 1582-1599.e1, 2019.
13. Momoi A, Komura Y, Kumon I, Tamai M, Tarumi Y, Matsubara J, Miyauchi K, Yamanouchi J and Hato T: Mesenteric venous thrombosis in hereditary protein C deficiency with the mutation at Arg169 (CGG-TGG). *Intern Med* 42: 110-116, 2003.

14. Rodríguez-Leal GA, Morán S, Corona-Cedillo R and Brom-Valladares R: Portal vein thrombosis with protein C-S deficiency in a non-cirrhotic patient. *World J Hepatol* 6: 532-537, 2014.
15. European Association for the Study of the Liver. Electronic address: easloffice@easloffice.eu: EASL clinical practice guidelines: Vascular diseases of the liver. *J Hepatol* 64: 179-202, 2016.
16. Li P and Qin C: Recurrent cerebellar infarction associated with hereditary heterozygous protein C deficiency in a 35-year-old woman: A case report and genetic study on the pedigree. *Exp Ther Med* 16: 2677-2681, 2018.
17. Majid Z, Tahir F, Ahmed J, Bin Arif T and Haq A: Protein C deficiency as a risk factor for stroke in young adults: A review. *Cureus* 12: e7472, 2020.
18. Zhu H, Liu H and Liu J: Pathogenic variants of PROC gene caused type II activity deficiency in a Chinese family: A case report. *Medicine (Baltimore)* 100: e25160, 2021.
19. Lensen RP, Rosendaal FR, Koster T, Allaart CF, de Ronde H, Vandenbroucke JP, Reitsma PH and Bertina RM: Apparent different thrombotic tendency in patients with factor V Leiden and protein C deficiency due to selection of patients. *Blood* 88: 4205-4208, 1996.
20. De Stefano V, Mastrangelo S, Schwarz HP, Pola P, Flore R, Bizzi B and Leone G: Replacement therapy with a purified protein C concentrate during initiation of oral anticoagulation in severe protein C congenital deficiency. *Thromb Haemost* 70: 247-249, 1993.
21. McGehee WG, Klotz TA, Epstein DJ and Rapaport SI: Coumarin necrosis associated with hereditary protein C deficiency. *Ann Intern Med* 101: 59-60, 1984.
22. Mitani M, Kuwabara Y, Kawamura H, Sato A, Hattori K and Fujii Y: Mesenteric venous thrombosis associated with protein C deficiency. *J Gastroenterol* 34: 387-389, 1999.
23. Yates P, Cumber PM, Sanderson S and Harrison BJ: Mesenteric venous thrombosis due to protein C deficiency. *Clin Lab Haematol* 13: 137-139, 1991.
24. Hsu WF, Tsang YM, Teng CJ and Chung CS: Protein C deficiency related obscure gastrointestinal bleeding treated by enteroscopy and anticoagulant therapy. *World J Gastroenterol* 21: 1024-1027, 2015.
25. Matsushita I, Hanai H, Sato Y, Arai H, Iida T, Hosoda Y, Kaneko E, Yasumi K and Sugimura H: Protein-losing enteropathy caused by mesenteric venous thrombosis with protein C deficiency. *J Clin Gastroenterol* 30: 94-97, 2000.
26. Valla D, Denninger MH, Delvigne JM, Rueff B and Benhamou JP: Portal vein thrombosis with ruptured oesophageal varices as presenting manifestation of hereditary protein C deficiency. *Gut* 29: 856-859, 1988.
27. Yang YY, Chan CC, Wang SS, Chiu CF, Hsu HC, Chiang JH, Tasy SH, Chang FY and Lee SD: Case report: Portal vein thrombosis associated with hereditary protein C deficiency: A report of two cases. *J Gastroenterol Hepatol* 14: 1119-1123, 1999.
28. Orozco H, Guraieb E, Takahashi T, Garcia-Tsao G, Hurtado R, Anaya R, Ruiz-Arguelles G, Hernandez-Ortiz J, Casillas MA and Guevara L: Deficiency of protein C in patients with portal vein thrombosis. *Hepatology* 8: 1110-1111, 1998.
29. Choi BK, Yang SH, Suh KH, Hwang JA, Lee MH, Si WK and Kim JH: A case of portal vein thrombosis by protein C and s deficiency completely recanalized by anticoagulation therapy. *Chonnam Med J* 47: 185-188, 2011.



This work is licensed under a Creative Commons Attribution-NonCommercial-NoDerivatives 4.0 International (CC BY-NC-ND 4.0) License.