

Nonionic irrigated radiofrequency ablation of refractory incessant ventricular tachycardia via great cardiac vein



Roderick Tung, MD, FHRS,^{*†} Qiang Liu, MS,^{*} Ruhong Jiang, MD,^{*} Chenyang Jiang, MD, FHRS^{*}

From the ^{*}Department of Cardiology, Sir Run Run Shaw Hospital, School of Medicine, Zhejiang University, Hangzhou, China, and [†]The University of Chicago Medicine, Center for Arrhythmia Care, Pritzker School of Medicine, Chicago, Illinois.

Introduction

Ventricular arrhythmias (VAs) arising from the summit of the left ventricle remain a challenge for radiofrequency (RF) catheter ablation. Ablation from the left coronary cusp, left ventricular outflow tract endocardium, septal right ventricular outflow tract, and the coronary venous system is often necessary to eliminate VAs from the left ventricular summit. Failure is often attributed to intramural location, risk of collateral damage, and limited energy delivery. We demonstrate a case of recurrent ventricular tachycardia (VT) with 3 failed attempts, which was successfully ablated from the coronary venous system using nonionic irrigated RF ablation.

Case report

A 76-year-old woman with preserved systolic function presented with a chief complaint of palpitations for 7 years. She had no history of coronary artery disease, hypertension, or structural heart disease. Three prior ablation procedures were unsuccessful (occurring 7 years, 6 years, and 1 month prior to the ablation procedure being presented). VT (tachycardia cycle length 440 ms) had indeterminate bundle block morphology with rightward inferior axis with QRS width of 182 ms. The precordium was R wave dominant and an rS complex was seen in lead I with aVL slightly more negative than aVR (Figure 1). During her most recent ablation attempt, activation mapping revealed earlier bipolar electrograms within the great cardiac vein (GCV) compared to the aortic sinuses and corresponding endocardial mitral annulus. Irrigated RF (ThermoCool SmartTouch, Biosense Webster,

Diamond Bar, CA) delivery with 0.9% normal saline (NS) from within the distal GCV (30 W, 30 seconds, followed by 150 seconds, average contact force: 25–28 g) resulted in termination of VT during the procedure, but recurrence was seen 20 minutes after her transfer to the cardiac care unit. The patient was discharged home with amiodarone and metoprolol. She presented with recurrent hemodynamically stable incessant VT.

During her fourth ablation attempt, mapping within the coronary sinus was performed with a 3F multielectrode catheter to optimize mapping density. A coronary venogram was performed to assess the patency and size of the GCV and a slight taper was seen at the site of prior ablation, potentially indicating low-grade stenosis. The earliest site of activation recorded from the multielectrode catheter was -20 ms with reversal of local bipolar electrogram polarity between electrodes 6,7 and 8,9 (Figure 1). One lesion from the most adjacent endocardial site below the left coronary cusp was attempted up to 45 W irrigated for 90 seconds with 0.9% NS with brief late interruption (>30 seconds), with immediate recurrence of incessant VT (Figure 2). Dextrose 5% in water (D5W) was chosen as the irrigant solution with the intention of creating a deeper lesion, but recurrence was seen immediately after suppression from endocardial ablation. Coronary angiography was performed, which confirmed a safe distance > 5 mm from all branches of the proximal left arterial system.

An irrigated ablation catheter (FlexAbility, Abbott, Abbott Park, IL) was advanced to the earliest site of activation in the distal GCV, where -21 ms was reproduced with the larger-tip catheter. Owing to history of multiple failure, D5W, which has higher local impedance than saline to preferentially direct energy delivery into the tissue, was also chosen as the irrigant solution. The first epicardial RF application was performed at 20 W with titration to 30 W and VT terminated in 20 seconds (72 seconds in total). Impedance cutoff was increased to the maximum upper limit of the generator and the highest recorded impedance was 326

KEYWORDS Great cardiac vein; Left ventricular summit; Nonionic irrigation; Radiofrequency ablation; Ventricular tachycardia (Heart Rhythm Case Reports 2018;4:572–575)

Address reprint requests and correspondence: Dr Roderick Tung, The University of Chicago Medicine, Center for Arrhythmia Care, Pritzker School of Medicine, 5841 S Maryland Ave MC 6080, Chicago, IL 60637. E-mail address: rodericktung@uchicago.edu.

KEY TEACHING POINTS

- Ablation of left ventricular summit ventricular arrhythmias can be clinically challenging, as biophysics (high impedance) and local anatomy (coronary artery) from within the coronary venous system may limit effective radiofrequency delivery.
- Use of low-ionic or nonionic irrigant solution may improve ablation efficacy by decreasing dispersion of current, which may direct energy delivery toward myocardial tissue.
- Future studies are needed to confirm safety with different irrigant composition, as increased steam pop incidence has been reported in animal models.

ohms. VT remained suppressed after the first application and 2 additional consolidation lesions were delivered at 15–20 W for 120 seconds and 88 seconds, respectively. The corresponding impedance drops were 32, 59, and 59 ohms, respectively. No steam pops were observed.

The patient was transferred to the cardiac care unit and discharged 1 day after ablation without any recurrence of VT with continuous telemetry. At 2-month follow-up in a previously incessant case, she has remained free of any VT recurrence.

Discussion

Nguyen and colleagues^{1–3} have compared RF lesion size with NS, half NS, and D5W irrigation in preclinical animal models. D5W was found with the largest lesions as compared to the former 2 fluids, which has been attributed to decreased dispersion or shunting of energy that may result with an ionic charged solution, decreasing the local impedance field. To the best of our knowledge, this is the first report of successful ablation from within the coronary venous system using nonionic irrigated RF ablation after failed traditional methods. Though D5W irrigation was chosen in this case, other novel adjunctive strategies such as alcohol ablation and bipolar ablation may have been effective.⁴ Alcohol ablation may create more diffuse injury and can be limited by venous anatomy and collaterals, and bipolar ablation was not performed, as epicardial location was suspected rather than a midmyocardial site or origin. The potential complication of D5W irrigation is higher incidence of steam pops (50/80 applications) when using high power (50 W) and a perpendicular position¹; we applied lower power and parallel touch in this case, which may help avoid the risk. Meanwhile, for achieving deeper lesions, we increased the impedance cutoff to improve the efficacy of RF energy delivery.³ Whether increasing to high power may have been equally as effective as changing the irrigant, our clinical experience has shown rapid increases in temperature that impair continued RF when ablating within the coronary venous system.

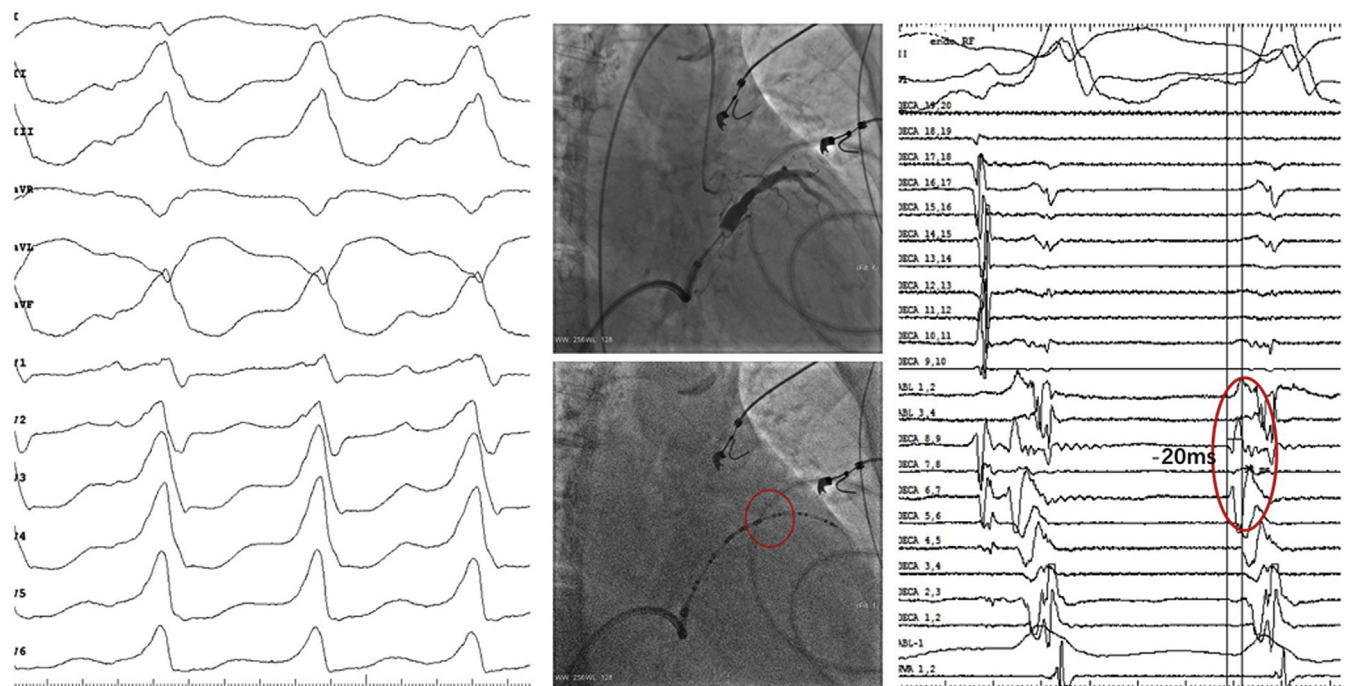


Figure 1 A 12-lead electrocardiogram of clinical ventricular tachycardia demonstrating R wave–dominant precordium with right axis deviation. Two fluoroscopic images of right anterior oblique view demonstrate the coronary venous system with balloon occlusion in the proximal great cardiac vein and the corresponding position of a multielectrode mapping catheter that extends into the anterior interventricular vein. The earliest site of activation is -20 ms with reversal of polarity at decapolar 6,7 and 8,9. The ablation catheter channel was adjacent (between 9,10 and 8,9) to the earliest site of activation during the case to facilitate comparison of timing.

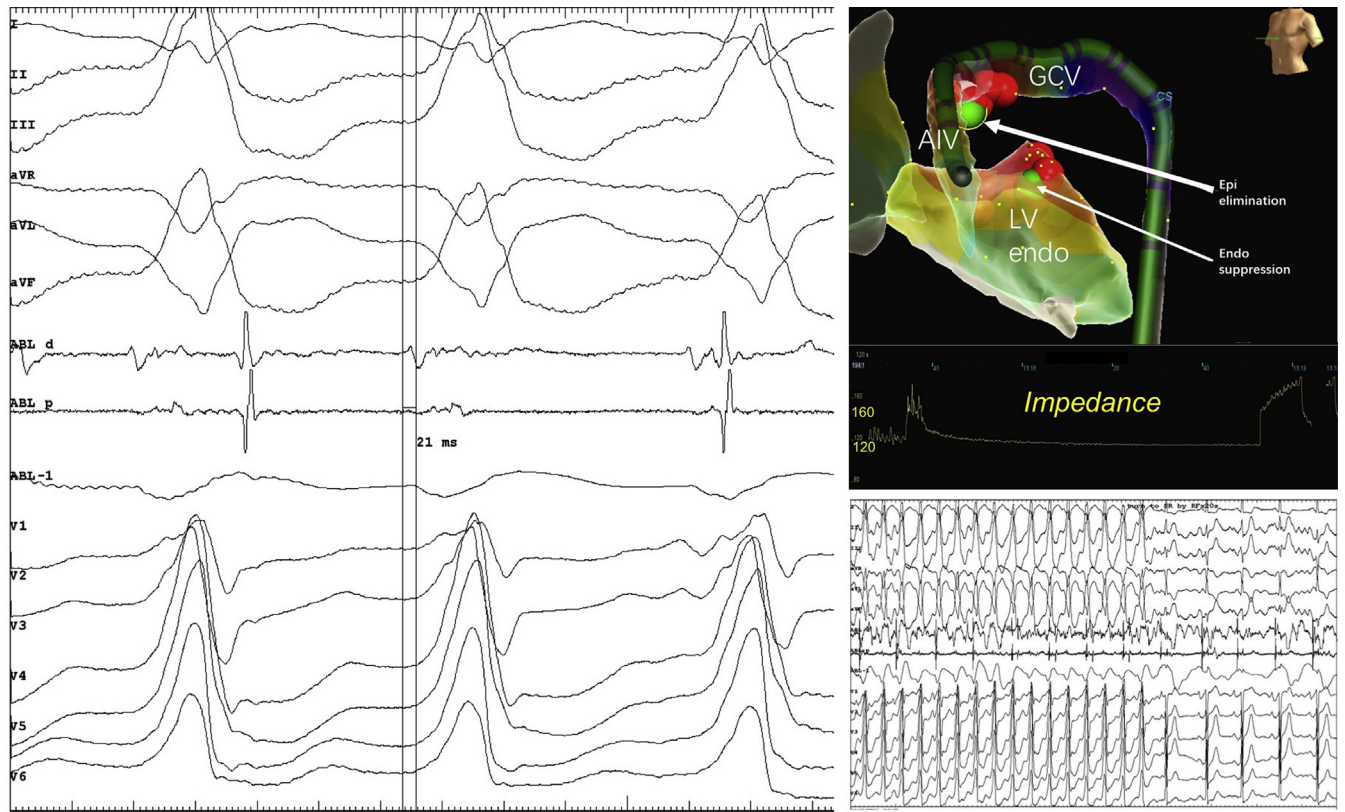


Figure 2 Location of successful ablation site within the distal great cardiac vein (GCV) (-21 ms) with electroanatomic map demonstrating the site of endocardial (Endo) suppression across from the site of ultimate success (*upper green dot*). The change of impedance during ablation is shown beneath the 3-dimensional map. Termination of incessant ventricular tachycardia during the first radiofrequency application at 20 seconds is shown without recurrence. AIV = anterior interventricular vein; Epi = epicardial; LV endo = left ventricular endocardial.

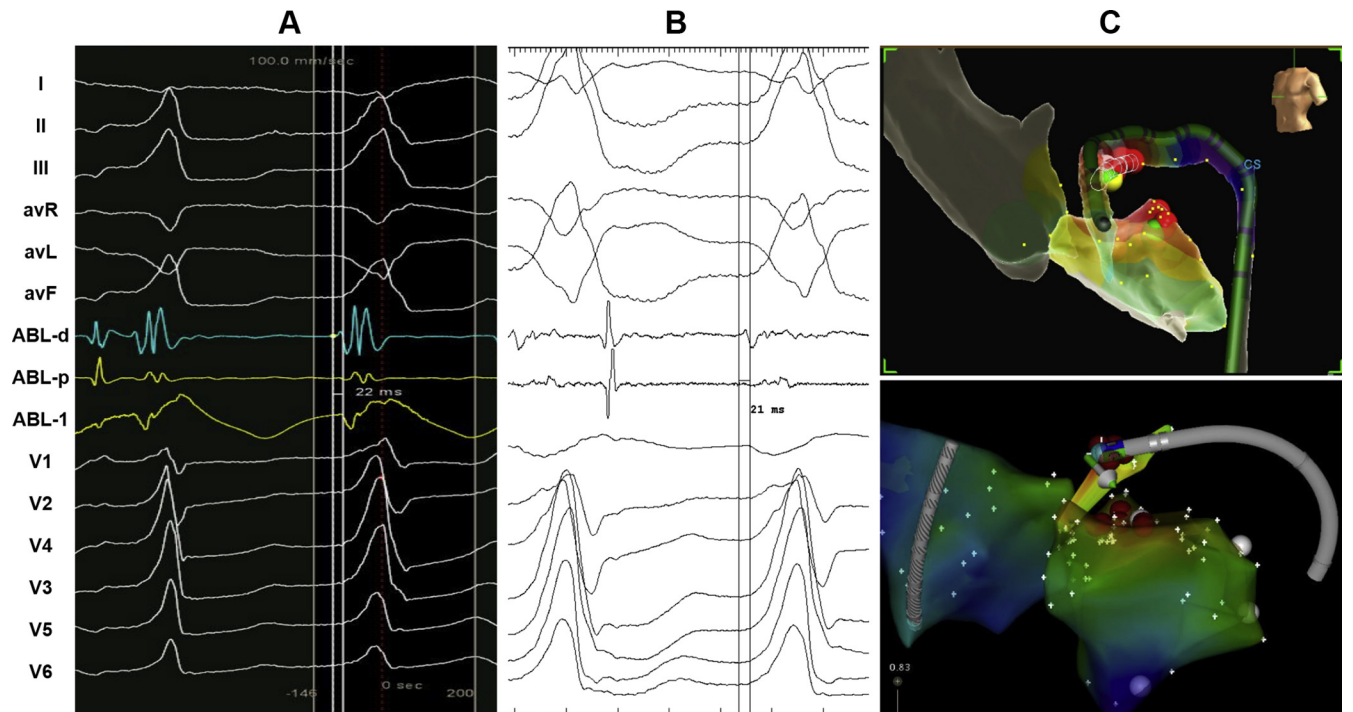


Figure 3 Similar timing in the distal great cardiac vein and location with representative earliest electrogram (EGM) recorded from the ablation catheter during third and fourth procedure. **A:** The earliest EGM in prior (third) procedure. **B:** The earliest EGM in this (fourth) procedure. **C:** Location of successful ablation site in the third (CARTO) and fourth (EnSite) procedure.

The rationale for using NS is to preserve blood osmolarity and sodium balance when a large volume of irrigation is anticipated with more extensive ablation procedures. In a focal arrhythmia mechanism, in this case, there is less concern for dilutional effects of lower or nonionic concentrated irrigant. The incremental value of ablation with varied ionic concentrations of irrigation is difficult to assess in clinical human cases. Success after crossover (after unsuccessful 0.9% NS application) is most compelling, although not always clearly demonstrated. Additionally, the impact of sequential and repeated applications cannot be understated as a form of probabilistic success. Success due to variability between the 2 irrigated catheters cannot be excluded; also, ablation with 0.9% NS irrigation was not reattempted in GCV prior to D5W on the final ablation procedure, although similar power settings were applied. Variability in contact force, initial power settings, and irrigation flow rate may all contribute to differential success. In this case, the procedure was performed at the same hospital using the same approach via the coronary sinus. Within the coronary venous system, where the catheter lies tangential to the epicardial surface, contact force cannot be manipulated to the same extent as during endocardial ablation. Despite the similar location within the GCV on multiple procedures on fluoroscopy and mapping system (Figure 3), slight differences in the exact

anatomic location cannot be excluded. Further studies are necessary to confirm and assess the efficacy and safety of nonionic irrigant during RF ablation.

Conclusion

The present case demonstrates the potential utility of using nonionic irrigated RF ablation when targeting VA from the coronary venous system to approach the left ventricular summit. In this instance, the patient served as her own control owing to prior failure at the same location using standard NS irrigation.

References

1. Nguyen DT, Olson M, Zheng L, Barham W, Moss JD, Sauer WH. Effect of irrigant characteristics on lesion formation after radiofrequency energy delivery using ablation catheters with actively cooled tips. *J Cardiovasc Electrophysiol* 2015; 26:792–798.
2. Nguyen DT, Gerstenfeld EP, Tzou WS, Jurgens PT, Zheng L, Schuller J, Zipse M, Sauer WH. Radiofrequency ablation using an open irrigated electrode cooled with half-normal saline. *JACC Clin Electrophysiol* 2017;3:1103–1110.
3. Nguyen DT, Nguyen K, Zheng L, Schuller J, Zipse M, Tzou WS, Sauer WH. Effect of environmental impedance surrounding a radiofrequency ablation catheter electrode on lesion characteristics. *J Cardiovasc Electrophysiol* 2017;28:564–569.
4. Gianni C, Mohanty S, Trivedi C, Di Biase L, Al-Ahmad A, Natale A, David Burkhardt J. Alternative approaches for ablation of resistant ventricular tachycardia. *Card Electrophysiol Clin* 2017;9:93–98.