

Hearing Outcomes after Microvascular Decompression for Hemifacial Spasm: An Institutional Experience

Abstract

Introduction: Hearing loss following microvascular decompression (MVD) for hemifacial spasm is one of the most dreaded complications. Several factors such as stretching of VIII cranial nerve, vasospasm of labyrinthine artery, and acoustic trauma due to drill noise may be considered in its causation. We evaluated the incidence and severity of hearing loss following MVD in hemifacial spasm and the factors which might be responsible for this complication. **Methods:** A retrospective analysis of 30 patients operated for hemifacial spasm between January 1, 2014, and December 31, 2018, with at least 3 months of follow-up were included in the study. Retromastoid craniotomy was made, and Teflon was placed between involved vessel and VII nerve. **Results:** Freedom from hemifacial spasm was noted in 27 of 30 patients. Moderate spasm persisted in one patient, which was controlled with medications. The recurrence was noted in 3 patients at 6 months follow-up. Postoperatively, hearing loss was found in one female patient. The offending vessel was both anterior inferior cerebellar artery (AICA) and posterior inferior cerebellar artery (PICA) loop, which was transpositioned during surgery, and the patient was spasm free postoperatively. **Conclusion:** The incidence of hearing loss following MVD can be minimized using proper surgical techniques and various intraoperative adjuncts such as brainstem auditory evoked responses monitoring, use of endoscope, and indocyanine green or dual-image video angiography.

Keywords: Hearing loss, microvascular decompression, retromastoid

Introduction

Hemifacial spasm is a clinical syndrome manifesting as irregular, involuntary, and recurring unilateral facial muscles contractions.^[1] Medical treatment and botulinum toxin are less invasive alternates; however, microvascular decompression (MVD) had been proven as a more effective and long-lasting option.^[2,3] The complications of MVD procedure for hemifacial spasm include cerebrospinal fluid (CSF) leak, facial palsy, hearing loss, lower cranial nerve (LCN) palsy, cerebellar or brainstem infarcts, and hematomas.^[4,5] Hearing loss is one of the most dreadful complications following MVD. Sensorineural hearing loss (SNHL) can be caused due to stretching of CN VIII, whereas cerebellar retraction, direct manipulation of cranial nerve (CN) 8, injury or vasospasm of the labyrinthine artery and AICA, and acoustic trauma due to drill noise^[6] may also be included in causative factors. Fluid entering the mastoid air cells

may cause middle ear effusion leading to conductive hearing loss.^[7]

Hearing loss may have a very significant impact on an individual's social and professional life. The aim of our study was to evaluate the incidence and severity of hearing loss following MVD in hemifacial spasm. We also tried to analyze the factors which might be responsible for this complication, so that it can be further minimized in future. The role of intraoperative adjuncts such as neurophysiological monitoring (brainstem auditory evoked responses [BAER]), dual-image video angiography (DIVA), and endoscope was evaluated in terms of outcome.

Methods

An retrospective analysis of records of all patients who underwent MVD for trigeminal neuralgia at Bantane Hospital, Fujita Health University from January 1, 2014, to December 31, 2018, was conducted. This included patients with at least 3 months of follow-up. Preoperative evaluation

**Ambuj Kumar,
Ahmed Ansari¹,
Yasuhiro Yamada²,
Tsukasa Kawase²,
Yoko Kato²**

*Department of Neurosurgery,
NSCB Government Medical
College, Superspeciality
Hospital, Jabalpur,
Madhya Pradesh, ¹Department
of Neurosurgery, UPUMS,
Etawah, Uttar Pradesh, India,
²Department of Neurosurgery,
Fujita Health University
Banbuntane Hospital, Nagoya,
Japan*

Address for correspondence:

*Dr. Ahmed Ansari,
Department of Neurosurgery,
UPUMS, Saifai, Etawah,
Uttar Pradesh, India.
E-mail: ahmed.ansari2@gmail.
com*

Access this article online

Website: www.asianjns.org

DOI: 10.4103/ajns.AJNS_362_19

Quick Response Code:



How to cite this article: Kumar A, Ansari A, Yamada Y, Kawase T, Kato Y. Hearing outcomes after microvascular decompression for hemifacial spasm: An institutional experience. *Asian J Neurosurg* 2020;15:344-8.

Submitted: 15-Dec-2019 **Accepted:** 03-Jan-2020

Published: 07-Apr-2020

This is an open access journal, and articles are distributed under the terms of the Creative Commons Attribution-NonCommercial-ShareAlike 4.0 License, which allows others to remix, tweak, and build upon the work non-commercially, as long as appropriate credit is given and the new creations are licensed under the identical terms.

For reprints contact: reprints@medknow.com

included magnetic resonance imaging (MRI) brain spoiled gradient recalled echo (SPGR) sequence and computed tomography (CT) angiography. MRI and CT angiography images were fused to clearly demonstrate the neurovascular conflict [Figure 1]. Pure-tone audiometry (PTA) was not performed routinely in all patients.

Surgical technique

All patients were operated in a lateral decubitus position. A small retromastoid craniotomy was made. Dura opened in the curvilinear fashion based on sigmoid sinus and laterally tented with tack-up sutures. Cisterns were fenestrated to release CSF and relax the cerebellum. Sharp arachnoid dissection was performed around CNs except CN 8. The

endoscope was used at this time for identification and better anatomical orientation of offending vessel loop. Machida right angle endoscope was used, which is easy to introduce deep through narrow working corridor. Teflon pledget was placed between the vessel loop and VII nerve. Transposition of the vessel loop was the preferred method whenever feasible. The primary dural closure was performed in all cases [Figure 2].

Intraoperative brainstem auditory evoked potential

Brainstem auditory evoked potential (BAEP) monitoring was performed using Nihon Kohden's system. The auditory stimulus was delivered at a frequency and intensity 11.1 Hz and 105 db, respectively, through earphones. Baseline recordings were done. An increase in wave V latency by >1.0 ms and fall in amplitude by more than 50% were considered significant.

Postoperatively, the outcome was assessed using the scoring system given by Kondo *et al.* Hearing was assessed subjectively; however, PTA was performed in patients who complained hearing loss.

Statistical analysis

Quantitative data were described in mean, and qualitative data were described in proportions. The factors responsible for good outcomes were analyzed as well as those for complications.

Results

Patient demographics

A total number of patients included in the study was 30 ($n = 30$). The mean age was 60.7 years (range = 36–83 years, standard deviation = 15.5). There

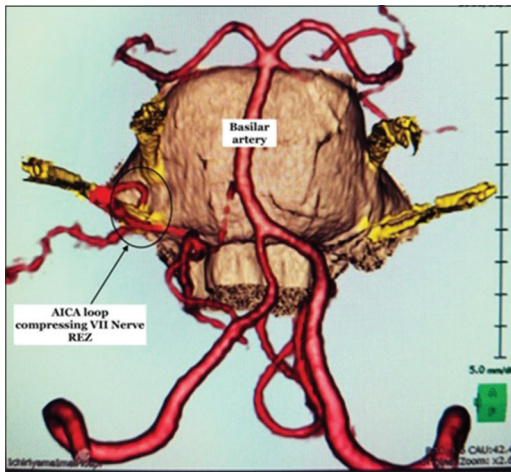


Figure 1: Fusion image (magnetic resonance imaging brain SPGR sequence and computed tomography angiography) demonstrating anterior inferior cerebellar artery (AICA) loop compressing right side VII cranial nerve root entry zone

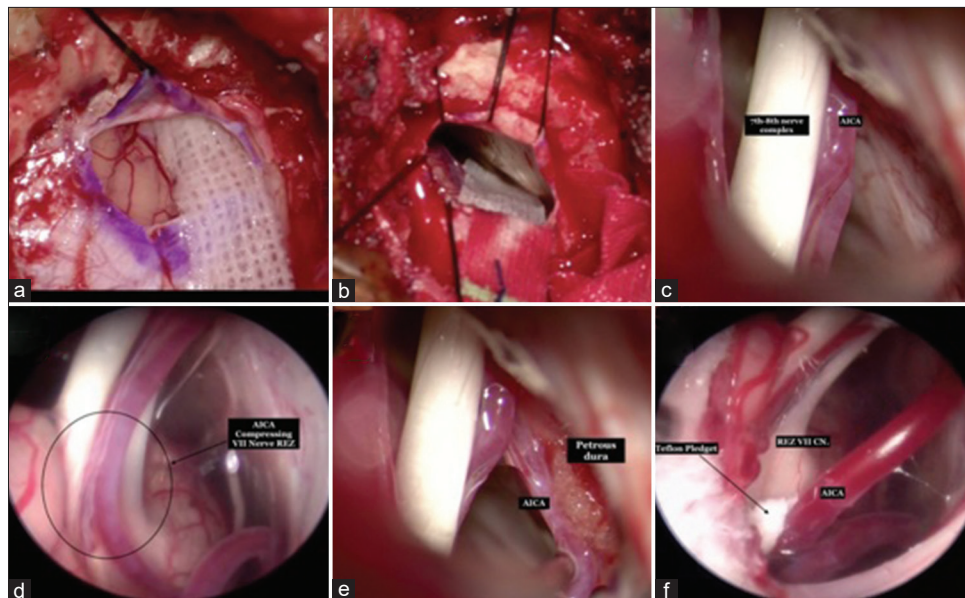


Figure 2: Intraoperative images. (a) Craniotomy and dural opening. (b) Lax cerebellum after draining cerebrospinal fluid from cerebellopontine cistern. (c) AICA in close proximity to VII–VIII nerve complex. (d) Endoscopic view showing AICA loop compressing VII nerve root entry zone. (e) AICA transpositioned away from VII to VIII nerve complex and fixed to petrous dura with gel foam soaked in glue. (f) Teflon pledget placed between AICA and VII nerve root entry zone

were 11 (36.7%) male and 19 female patients (63.3%). All the patients presented with hemifacial spasm [Table 1].

Operative findings

The most commonly encountered offending vessel was AICA (40%), followed by PICA (33.3%). In seven cases (23.3%), two loops were found compressing the nerve. The vein was not found culprit in any case. The late phase of fusion images can identify venous compression. Fusion imaging was able to correctly localize the culprit vessel in all cases except in the two patients which did not showed any benefit in spasm, probably due to thick arachnoidal bands present at the root entry zone (REZ). Out of total 37 vessel loops, interposition and transposition were done in 16 (43.2%) and 21 (56.7%) cases, respectively. The endoscope and DIVA were used in all cases.

Outcomes

Freedom from spasm

The mean follow-up period was 12.9 months. Freedom from spasm (E0 and E1) was achieved in 27 patients (90%) at the time of discharge. Moderate spasm (E2) persisted in one patient (3.3%) which was controlled with medicines. There was no relief from spasm in two (6.7%) patients, probably due to the thick arachnoidal bands present at REZ in them.

Complications

The recurrence was noted in 3 patients (10%) at 6 months follow-up. In the recurrence group, two of three patients were managed successfully with botulinum injection. Facial palsy was noted in one patient (3.3%).

Hearing loss

Postoperative hearing loss was found in one female patient, which was confirmed by audiometry. The offending vessel, in this case, was both AICA and PICA loop which were transpositioned during surgery. This patient was completely spasm free postoperatively.

Postoperative audiogram showed left side severe SNHL [Figure 3].

The retractor was not applied during the surgery. During arachnoid dissection, there was an increase in wave V latency by 1 ms and drop in amplitude by more than 50%, after which dissection was stopped till wave V latency and amplitude came back to normal [Figure 4]. At the end of the procedure, V-wave latency and amplitude were the same as baseline.

Discussion

Hemifacial spasm is a movement disorder, characterized by progressive, involuntary, and irregular contractions of facial muscles.^[1,8] It typically begins with the periocular muscles involvement and gradually involves other ipsilateral facial muscles.^[9] In severe cases, the platysma and stapedius can also be involved. Differential diagnoses include blepharospasm, oromandibular dystonia, facial tic, and focal seizures.^[1] Disease prevalence reported in the literature is 11 cases/100,000 population, with a female-to-male ratio of 2:1.^[10]

The most common cause of HFS is compression of VII CN by vessel loop at its REZ.^[11] REZ is the transition between

Table 1: Patient demographics and operative findings

| Demographics | Findings |
|--|---|
| Age range | 36-83 years (Mean 60.7, SD- 15.5) |
| Sex distribution | Male: female=11:19 |
| Offending vessel | AICA- 12 (40%) PICA- 10 (33.3%) PICA, AICA- 5 (16.6%) VA- 1 (3.3%) VA, PICA- 1 (3.3%) VA, AICA- 1 (3.3%) |
| Procedure done (Interposition/Transposition) | Interposition- 16 (43.2%) Transposition- 21 (56.7%) |

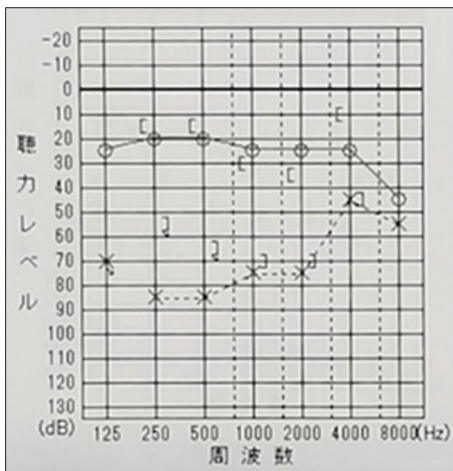


Figure 3: Pure-tone audiometry showing left side severe sensorineural hearing loss

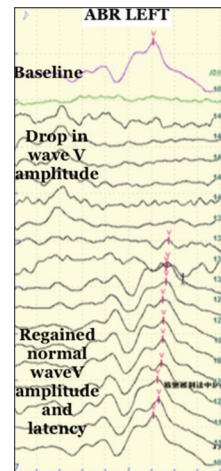


Figure 4: Intraoperative brainstem auditory evoked potential showing drop in amplitude and increase in latency of wave V

central and peripheral myelination.^[12] Other less common causes of compression include cerebellopontine angle tumors, arachnoid cysts, and thick arachnoid bands.^[1,13] Rarely multiple sclerosis and brainstem infarct can also cause HFS.

Several hypotheses had been proposed to explain the pathogenesis of HFS.

Peripheral hypothesis advocates ectopic and ephaptic transmission in VII CN, whereas the central hypothesis assumes hyperexcitability of the facial nerve nucleus.^[12]

The treatment options include medical treatment, botulinum injection, and MVD. Medical treatment is effective only for mild form of the disease.^[1,3] The drugs commonly used include carbamazepine, oxcarbazepine, baclofen, and gabapentin. Botulinum injection provides symptomatic relief in 85%–90% of patients; however, its major disadvantage is needed to repeat injection at 3–4 months' interval. Patients with high anesthetic risk and not willing for surgery are suitable candidates for botulinum injection.^[1,2,14] MVD is the most effective option as it deals directly with the etiology. Postoperative complications include CSF leak, wound infection, stroke and hematomas, facial palsy, hearing loss, and LCN palsy.^[4,5,15]

As HFS is a benign disease, patients usually do not accept undue postoperative complications. Hence, all the measures should be applied during surgery, which helps in minimizing the complications. As per the literature, the success rate of MVD for HFS is 80%–88% in the first postoperative year, which is consistent with our results.^[3-5] As per the meta-analysis done by Bartindale *et al.*, which included 11,140 patients operated for TN, the overall prevalence of hearing loss was 8.25%.^[16] Miller *et al.* reported a 2.3% incidence of permanent hearing loss after MVD.^[17] As per Youn *et al.*, the incidence of hearing loss was higher in elderly patients (3.9% vs. 1.9%, $P = 0.042$).^[18] In our study, the mean age of patients was 60.7 years and hearing loss incidence was 3.3%. There is lots of variation in hearing outcomes after MVD in literature. The use of routine perioperative audiogram and intraoperative BAEP had a significant impact on hearing loss detection. HFS studies in which routine perioperative audiogram was done reported 2.27% higher incidence of hearing loss as compared to studies not using perioperative audiogram routinely.^[16]

Stretching of root due to excessive cerebellar retraction is the main cause of hearing loss in MVD. Lee *et al.* demonstrated a change in BAEP during cerebellar retraction in all 12 patients who developed permanent hearing loss.^[6] Intraoperative use of rigid retractors, especially for longer duration, should be avoided.^[19,20] Suction cannula can be used for gentle retraction of the cerebellum. Early CSF drainage also helps in relaxing the cerebellum and minimizing the need for retraction. Even in the cases where retractors are required, it should not be applied along the

VIII nerve as it may produce tension on the REZ of nerve, leading to hearing disturbances.

Lee *et al.* studied the correlation between cerebellar retraction time and intraoperative BAER changes and emphasized the greater distance between the cerebellar surface of petrous temporal bone and point of neurovascular conflict as an important risk factor for SNHL.^[21]

Spasm of labyrinthine artery is another major cause of hearing loss after MVD. Morawski *et al.* demonstrated the use of topical papaverine in the reversal of internal auditory artery vasospasm and its impact on cochlear nerve functions in animals.^[22] Scavo *et al.* also reported a prophylactic effect of diluted papaverine in preventing hearing loss during MVD for trigeminal neuralgia.^[23]

Intraoperative BAEP is a useful monitoring adjunct in posterior fossa MVD surgery.^[16,24] As per the American Society of Neurophysiology monitoring recommendations, surgeon should be alerted when the wave V amplitude decreases by >50% or latency increases by >1.0 ms.^[24] However, Dannenbaum *et al.* reported 114 cases of MVD without using BAEP monitoring, in which they found comparable results with those studies using monitoring.^[4]

The intraoperative use of endoscope is quite helpful in the visualization of vessel loop near REZ. It also helps in minimizing the cerebellar retraction and related complications.^[25] Indocyanine green (ICG) angiography can be helpful intraoperatively for delineating neurovascular conflict in the cerebellopontine angle cistern. We routinely use DIVA during MVD.^[26]

Limitations

We acknowledge certain limitations of our retrospective study. The most important is the small number of cases as compared to the other studies. Perioperative audiogram had not been performed routinely, which might have changed our results.

Conclusion

MVD is a safe and effective surgical technique for hemifacial spasm. Hearing loss is one of the most disastrous complications having a significant impact on patients' life. The incidence can be minimized using proper surgical techniques and various intraoperative adjuncts such as BAER monitoring, use of endoscope, and ICG or DIVA.

Financial support and sponsorship

Nil.

Conflicts of interest

There are no conflicts of interest.

References

1. Wang A, Jankovic J. Hemifacial spasm: Clinical findings and treatment. *Muscle Nerve* 1998;21:1740-7.
2. Yoshimura DM, Aminoff MJ, Tami TA, Scott AB. Treatment

- of hemifacial spasm with botulinum toxin. *Muscle Nerve* 1992;15:1045-9.
3. Barker FG 2nd, Jannetta PJ, Bissonette DJ, Shields PT, Larkins MV, Jho HD. Microvascular decompression for hemifacial spasm. *J Neurosurg* 1995;82:201-10.
 4. Dannenbaum M, Lega BC, Suki D, Harper RL, Yoshor D. Microvascular decompression for hemifacial spasm: Long-term results from 114 operations performed without neurophysiological monitoring. *J Neurosurg* 2008;109:410-5.
 5. Yuan Y, Wang Y, Zhang SX, Zhang L, Li R, Guo J. Microvascular decompression in patients with hemifacial spasm: Report of 1200 cases. *Chin Med J (Engl)* 2005;118:833-6.
 6. Lee MH, Jee TK, Lee JA, Park K. Postoperative complications of microvascular decompression for hemifacial spasm: Lessons from experience of 2040 cases. *Neurosurg Rev* 2016;39:151-8.
 7. Ying T, Thirumala P, Gardner P, Habeych M, Crammond D, Balzer J. The Incidence of Early Postoperative Conductive Hearing Loss after Microvascular Decompression of Hemifacial Spasm. *J Neurol Surg B Skull Base* 2015;76:411-5.
 8. Dou NN, Zhong J, Zhou QM, Zhu J, Wang YN, Xia L, *et al.* The mechanism of hemifacial spasm: A new understanding of the offending artery. *Neurol Res* 2015;37:184-8.
 9. Jannetta PJ. Typical or atypical hemifacial spasm. *J Neurosurg* 1998;89:346-7.
 10. Sindou M, Mercier P. Microvascular decompression for hemifacial spasm: Outcome on spasm and complications. A review. *Neurochirurgie* 2018;64:106-16.
 11. Girard N, Poncet M, Caces F, Tallon Y, Chays A, Martin-Bouyer P, *et al.* Three-dimensional MRI of hemifacial spasm with surgical correlation. *Neuroradiology* 1997;39:46-51.
 12. Nielsen VK. Electrophysiology of the facial nerve in hemifacial spasm: Ectopic/ephaptic excitation. *Muscle Nerve* 1985;8:545-55.
 13. Yaltho TC, Jankovic J. The many faces of hemifacial spasm: Differential diagnosis of unilateral facial spasms. *Mov Disord* 2011;26:1582-92.
 14. Simpson DM, Blitzer A, Brashear A, Comella C, Dubinsky R, Hallett M, *et al.* Assessment: Botulinum neurotoxin for the treatment of movement disorders (an evidence-based review): Report of the Therapeutics and Technology Assessment Subcommittee of the American Academy of Neurology. *Neurology* 2008;70:1699-706.
 15. Jo KW, Kim JW, Kong DS, Hong SH, Park K. The patterns and risk factors of hearing loss following microvascular decompression for hemifacial spasm. *Acta Neurochir (Wien)* 2011;153:1023-30.
 16. Bartindale M, Kircher M, Adams W, Balasubramanian N, Liles J, Bell J, *et al.* Hearing loss following posterior fossa microvascular decompression: A systematic review. *Otolaryngol Head Neck Surg* 2018;158:62-75.
 17. Miller LE, Miller VM. Safety and effectiveness of microvascular decompression for treatment of hemifacial spasm: A systematic review. *Br J Neurosurg* 2012;26:438-44.
 18. Youn J, Kwon S, Kim JS, Jeong H, Park K, Cho JW. Safety and effectiveness of microvascular decompression for the treatment of hemifacial spasm in the elderly. *Eur Neurol* 2013;70:165-71.
 19. Broggi G, Ferroli P, Franzini A, Servello D, Dones I. Microvascular decompression for trigeminal neuralgia: Comments on a series of 250 cases, including 10 patients with multiple sclerosis. *J Neurol Neurosurg Psychiatry* 2000;68:59-64.
 20. Sindou M. Operative strategies for minimizing hearing loss associated with microvascular decompression for trigeminal neuralgia. *World Neurosurg* 2010;74:111-2.
 21. Lee MH, Lee HS, Jee TK, Jo KI, Kong DS, Lee JA, *et al.* Cerebellar retraction and hearing loss after microvascular decompression for hemifacial spasm. *Acta Neurochir (Wien)* 2015;157:337-43.
 22. Morawski K, Telischi FF, Merchant F, Namyslowski G, Lisowska G, Lonsbury-Martin BL. Preventing internal auditory artery vasospasm using topical papaverine: An animal study. *Otol Neurotol* 2003;24:918-26.
 23. Scavo CG, Roperto R, Cacciotti G, Corrivetti F, Mastronardi L. Prophylactic effect of topical diluted papaverine in preventing hearing loss during microvascular decompression for typical trigeminal neuralgia: Case report and technical note. *Interdisciplinary Neurosurg* 2019;15:11-4. Available from: <http://www.sciencedirect.com/science/article/pii/S2214751918301415>. [Last accessed on 2019 Mar 18].
 24. Thirumala PD, Carnovale G, Loke Y, Habeych ME, Crammond DJ, Balzer JR, *et al.* Brainstem auditory evoked potentials' diagnostic accuracy for hearing loss: Systematic review and meta-analysis. *J Neurol Surg B Skull Base* 2017;78:43-51.
 25. Komatsu F, Imai M, Matsumae M. How I do it: Endoscopic microvascular decompression for hemifacial spasm associated with the vertebral artery. *Acta Neurochir (Wien)* 2018;160:157-9.
 26. Zhang H, Fu WM, Chen P, Shi J. Intraoperative indocyanine green angiography during microvascular decompression surgery: Report of 30 cases. *Acta Neurochir (Wien)* 2014;156:1561-4.