

[CASE REPORT]

Accidental Hypothermia Treated by Hemodialysis in the Acute Phase: Three Case Reports and a Review of the Literature

Tetsushi Murakami¹, Tadashi Yoshida², Arata Kurokochi³, Kimiharu Takamatsu¹,
Yu Teranishi¹, Keisuke Shigeta¹, Satoshi Tamaki^{1,2}, Shinya Morita^{1,2},
Ryuichi Mizuno¹ and Mototsugu Oya¹

Abstract:

Accidental hypothermia is defined as a core body temperature $<35^{\circ}\text{C}$. Even with the use of multiple active rewarming methods, it has a high mortality rate. No standard treatment strategy for moderate or severe hypothermia in the absence of cardiac arrest has yet been established. We herein report three patients with severe or moderate accidental hypothermia who were treated by hemodialysis in the acute phase. This case report with a literature review describes the usefulness of hemodialysis for the treatment of moderate and severe accidental hypothermia without cardiac arrest.

Key words: hypothermia, hemodialysis, rewarming

(Intern Med 58: 2743-2748, 2019)

(DOI: 10.2169/internalmedicine.1945-18)

Introduction

Accidental hypothermia is an involuntary reduction in the core body temperature to $<35^{\circ}\text{C}$ and is classified into mild ($32\text{--}35^{\circ}\text{C}$), moderate ($28\text{--}32^{\circ}\text{C}$), and severe hypothermia ($<28^{\circ}\text{C}$) (1, 2). Moderate and severe hypothermia in particular constitute medical emergencies, as they have high mortality rates ranging from 12% to 80% (3). Clinical manifestations of hypothermia vary, depending on the core body temperature. At $\leq 35^{\circ}\text{C}$, shivering, tachycardia, tachypnea, and apathy may occur (4). At $\leq 32^{\circ}\text{C}$, shivering may disappear, and bradycardia, slow respiration, and confusion may appear. At $\leq 28^{\circ}\text{C}$, decreased blood pressure, apnea, and coma may be apparent. Hypothermic patients have an increased risk of lethal arrhythmia and exhibit multiple abnormal electrocardiogram (ECG) findings, including atrial fibrillation, prolonged QT intervals, T-wave inversion, and Osborn waves (5, 6). Delays in rewarming and slower rates of rewarming have been shown to be the most important prog-

nostic factors associated with increased mortality (3).

A wide variety of rewarming techniques have been developed, and they are chosen based on the degree of hypothermia, presence or absence of cardiopulmonary arrest, and available resources. Mild hypothermia is treated by passive external rewarming, including the removal of wet clothing, movement to a warm environment, and wrapping with blankets (2, 4). The treatment strategy for moderate and severe hypothermia is a combination of active external and active internal rewarming. The use of electric blankets is the most common active external rewarming method, whereas active internal rewarming techniques involve intravenous infusion of warmed fluids, a heated air blower, pleural and peritoneal irrigation with warmed saline, hemodialysis (HD), cardiopulmonary bypass (CPB), and extracorporeal membrane oxygenation (ECMO) (7-11). For severe hypothermic patients with cardiopulmonary arrest, CPB and ECMO have been recommended as active internal rewarming methods (10, 12-14). However, the ideal active internal rewarming strategy for patients with moderate and severe hypother-

¹Department of Urology, Keio University School of Medicine, Japan, ²Apheresis and Dialysis Center, Keio University School of Medicine, Japan and ³Department of Internal Medicine, Keio University School of Medicine, Japan

Received: August 6, 2018; Accepted: March 22, 2019; Advance Publication by J-STAGE: June 7, 2019

Correspondence to Dr. Tadashi Yoshida, tayoshida-npr@umin.ac.jp

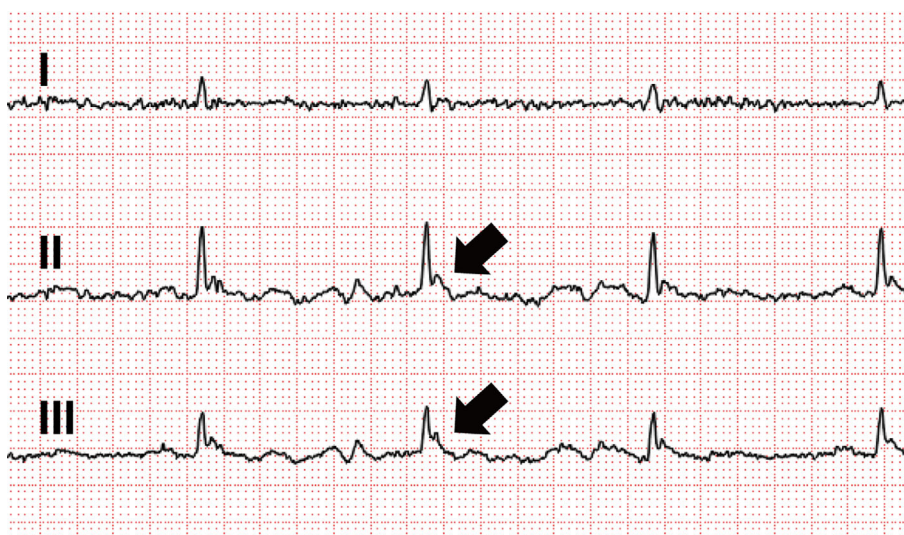


Figure 1. ECG in a patient with severe hypothermia before rewarming (Case 1). Arrows: Osborn waves. ECG: electrocardiogram

mia without circulatory collapse has not yet been established.

HD is widely used and readily available, in contrast to CPB and ECMO, and several case reports describe the use of HD as the active internal rewarming method (15-21). We herein report three cases of moderate and severe hypothermia that did not exhibit renal failure or cardiac arrest with rewarming applied using HD. In addition, we summarize the clinical characteristics of previous cases of hypothermia treated with HD as the active internal rewarming method.

Case Reports

Case 1

A 48-year-old homeless man was found lying with disturbed consciousness in a public lavatory at dawn. The outside air temperature was 3.5°C at that time. He had a history of chronic alcoholism. Since two days before this episode, he had drunk heavily and eaten nothing. He was transferred to the emergency room in our hospital. Our initial examination revealed a Glasgow Coma Scale (GCS) score of 8 (E3V1M4), bladder temperature of 26.4°C, blood pressure of 114/99 mmHg, heart rate of 42 beats/min, and respiratory rate of 25/min. Laboratory data showed white blood cells $4.4 \times 10^3/\mu\text{L}$, hemoglobin 11.9 g/dL, platelets $15.4 \times 10^4/\mu\text{L}$, blood urea nitrogen 10.9 mg/dL, creatinine 0.44 mg/dL, Na^+ 147.3 mEq/L, and K^+ 3.6 mEq/L. Venous blood gas showed hypoglycemia (glucose 60 mg/dL) and lactic acidosis (pH 7.202, base excess -3.1 mmol/L, lactate 4.7 mmol/L). A urinary test showed ketonuria. After glucose administration, his conscious level improved to a GCS score of 11 (E4V2M5). An ECG showed sinus bradycardia of 48 beats/min, Osborn waves, and long QT intervals (Fig. 1). A urinary drug screen test was positive for benzodiazepines. Blood cultures on admission were negative.

The patient was rewarmed with an electric blanket, and his core temperature rose from 26.4 to 28.3°C during the first 2 hours (mean rewarming rate of 1.0°C/h). As we predicted that it would take some time to increase his core temperature to the appropriate range, HD was initiated as an active internal rewarming method. Vascular access for blood removal and return was achieved through the right and left femoral veins, respectively. The blood flow rate (Q_b) was 100 mL/min for the first hour and 150 mL/min for the subsequent 1.5 hours, while the dialysate flow rate (Q_d) was 500 mL/min. The surface area of the dialyzer membrane was 1.5 m², and the dialysate concentration of K^+ was 3.0 mEq/L. Nafamostat mesilate was used as an anticoagulant agent. Fluid was not removed, and the dialysate temperature was set at 35°C. During the 2.5-h duration of dialysis therapy, the blood pressure of the patient was stable, and his core temperature rose from 28.3 to 32.4°C (mean rewarming rate of 1.6°C/h) (Fig. 2A). At the termination of HD, his lactic acidosis had improved (pH 7.318, base excess -1.7 mmol/L, lactate 1.6 mmol/L), whereas the serum K^+ levels had decreased to 3.0 mEq/L. Eight hours after the termination of HD, his core body temperature reached 36°C. The Osborn waves on the ECG disappeared. Despite a further evaluation, no diseases responsible for the secondary hypothermia, such as severe infections, endocrine disorders, or cerebrovascular diseases, were found.

He received a transfusion of glucose and vitamin B₁ because he was complicated with alcoholic ketoacidosis due to heavy drinking with fasting. However, following the recovery of consciousness (GCS 15), he exhibited alcohol withdrawal syndrome. Administration of diazepam 15 mg/day provided symptomatic improvement, and he was discharged on the fourth day of admission.

Case 2

A 78-year-old man who needed home care and spent

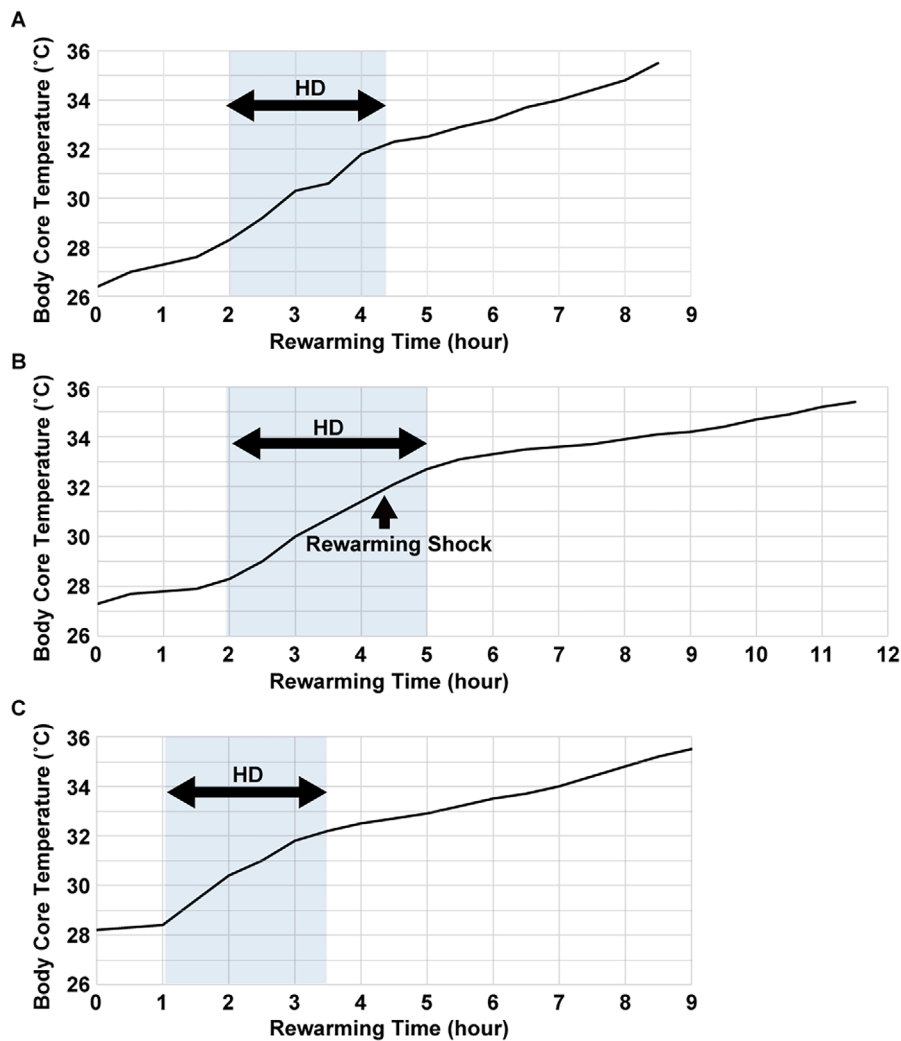


Figure 2. Temperature shifts during rewarming in three cases (A: case 1, B: case 2, C: case 3). HD: hemodialysis

most of the day in his bed was found unresponsive by his daughter. His vital signs on arrival at our hospital were a GCS scale of 3 (E1V1M1), bladder temperature of 27.3°C, blood pressure of 78/40 mmHg, heart rate of 39 beats/min, and respiratory rate of 18/min. An ECG showed sinus bradycardia and Osborn waves. He had hypoglycemia (54 mg/dL), and after glucose injection, his glucose level increased to 237 mg/dL. He was rewarmed by the intravenous administration of warmed fluids and an electric blanket. However, his core temperature rose only 1.0°C in an hour, so we decided to use HD in order to reduce the risk of lethal arrhythmia. A double-lumen catheter was temporarily placed in the right internal jugular vein. The Q_b was 150 mL/min, while the Q_d was 500 mL/min. The surface area of the dialyzer membrane was 1.1 m², and the dialysate concentration of K⁺ was 3.5 mEq/L. Heparin was used as an anticoagulant agent. Fluid was not removed, and the dialysate temperature was set at 37°C. Three hours of HD therapy raised his core temperature from 28.3 to 32.7°C (mean rewarming rate of 1.5°C/h) (Fig. 2B). During HD, he had an episode of rewarming shock, and his blood pressure dropped to 73/33 mmHg. He was treated by continuous administra-

tion of norepinephrine, and his hemodynamics stabilized. Continuous rewarming was ensured using a warmed blanket. Within 15 hours after arrival at the hospital, his core temperature had returned to 36.7°C. Computed tomography (CT) revealed aspiration pneumonia, and the administration of antibiotics was initiated. He was transferred to another hospital for additional treatment for pneumonia on the third day.

Case 3

A 77-year-old woman was found unconscious in her house by the police. She had last been seen alive two days earlier. Her vital signs on arrival at our hospital were a GCS score of 3 (E1V1M1), bladder temperature of 28.2°C, blood pressure of 133/83 mmHg, heart rate of 63 beats/min, and respiratory rate of 17/min. The diameter of both pupils was 4 mm, and she lacked a light reflex bilaterally. Head CT was not performed at this point. An ECG showed Osborn waves. An arterial blood gas analysis showed lactic acidosis (pH 7.334, base excess -7.2 mmol/L, lactate 8.5 mmol/L) and hypokalemia of K⁺ 2.8 mEq/L. Even after an hour of rewarming with an electric blanket and intravenous admini-

stration of warm fluids, the core body temperature of the patient was unaltered, so HD was started. Blood was removed from the right femoral vein and returned to the left antecubital vein. The Q_b was 120 mL/min, while the Q_d was 500 mL/min. The surface area of the dialyzer membrane was 0.9 m², and the dialysate concentration of K⁺ was 3.5 mEq/L. Nafamostat mesilate was used as an anticoagulant agent. Fluid was not removed, and the dialysate temperature was set at 35°C. One hour after the initiation of HD, her GCS score had improved to 6 (E1V1M4) with a bladder temperature of 30.5°C (Fig. 2C). However, 2.5 hours after the start of HD, her respiratory status worsened due to a large amount of sudden vomiting. HD was discontinued immediately when her bladder temperature reached 32°C (mean rewarming rate of 1.4°C/h). CT revealed subarachnoid hemorrhaging (SAH) with ventricular perforation and compression of the brain stem by the hemorrhaging. Her GCS score was 3 (E1V1M1) with decerebrate rigidity, and both pupils were fully dilated. Her SAH status was grade 5, as determined by the Hunt and Kosnik classification, and she was not a candidate for surgical operation. In addition, the patient's family requested no therapeutic intervention be performed. The patient died the following day.

Discussion

We experienced three patients with accidental hypothermia who were rewarmed using HD. In all the three cases, the core body temperature at our initial examination in the emergency room was below 30°C, and Osborn waves were present on an ECG. The major reason that HD was performed in these three patients was because the rewarming rates during the first 2 hours had been <1°C/h. The rewarming rate during HD was kept to about 1.5°C/h by adjusting Q_b. In order to avoid excess rewarming, HD was terminated before the body temperature reached 34°C.

Walpoth et al. suggested that CPB is an effective rewarming method for severe hypothermia in cases of cardiac arrest (10). Ruttman et al. also suggested that ECMO improves the survival in severe hypothermic patients with cardiocirculatory arrest (14). However, as several case reports have mentioned, HD is a therapeutically effective and safe internal rewarming method for moderate and severe hypothermia in the absence of cardiac arrest (18, 19). The advantages of HD for the treatment of hypothermia are low invasiveness, easy adjustment of the rewarming rate, and availability even in cases with a normal renal function. In addition, HD is easy to prepare as long as venous access can be achieved at the body surface, in contrast to CPB, which is an invasive surgical procedure with a high risk of cardiovascular events. Another advantage of HD for hypothermia is a low frequency of afterdrop compared to active external rewarming methods (4). Afterdrop, which is a decrease in the core temperature after the initiation of rewarming, is caused by peripheral vasodilation and returning cold blood from the periphery to the body core. For this rea-

son, it is recommended to limit the active external rewarming area to the trunk (4). Furthermore, the combinatorial use of active internal and external rewarming methods has also been recommended as the most certain way of preventing afterdrop (2, 7). In this regard, HD is quite useful as an active internal rewarming method. Another advantage of HD is the correction of electrolytes and acid-base imbalance, which are often complicated in cases of hypothermia, although HD does alter the circulatory dynamics to a certain degree. During HD therapy, it is important to monitor the vital signs carefully.

In case 1, the patient did not exhibit renal impairment, but we performed HD for 2.5 hours to treat hypothermia. Because we anticipated HD-induced hypokalemia in the patient, the dialysate concentration of K⁺ was adjusted to 3.0 mEq/L in advance. Nevertheless, the serum K⁺ level had decreased from 3.6 mEq/L to 3.0 mEq/L by the end of HD. In addition to hypothermia, hypokalemia is a major risk factor for arrhythmia. To avoid increasing the risk of arrhythmia due to overlapping risk factors, the dialysate concentration of K⁺ should be kept relatively high in patients with a normal renal function. Unfortunately, the concentration of K⁺ in all dialysates in Japan is set to 2.0 mEq/L at present, so we must adjust the dialysate concentration of K⁺ ourselves. The commercial availability of dialysates with multiple K⁺ concentrations, as can be found in a number of foreign countries, would be extremely useful in this regard.

In case 2, rewarming shock was observed during HD. Rewarming shock is a reduction in the blood pressure during rewarming caused by a decrease in the circulatory blood volume. It is triggered by peripheral vasodilation, cardiac hypofunction, and arrhythmia associated with heart re-cooling (10). To prevent rewarming shock, it is important to inject the warmed fluids intravenously before HD, as cold diuresis and hemodynamic instability decrease the circulatory blood volume (1, 22). In our case 2, the amount of warm fluids injected before starting HD was 1 L, which might have been insufficient. Guideline recommendations regarding the volume and rate of intravenous injection of warm fluids for the treatment of accidental hypothermia in the future are eagerly awaited.

In case 3, SAH was diagnosed by the progression of symptoms during HD. Under hypothermic conditions, many symptoms and physical signs are obscure (4). In patients with hypothermia who are unconscious, we recommend screening for cerebral vascular lesions by head CT before starting HD.

Seven cases of accidental hypothermia treated with HD have been previously reported (15-21). Based on a review of the 10 total cases of HD-treated accidental hypothermia, including the presently reported 3 cases, several points should be noted (Table). First, afterdrop was not observed in all cases, but rewarming shock was observed in three cases, suggesting that HD requires careful monitoring for rewarming shock. It may be best to ensure that a sufficient amount of warmed fluids have been injected before starting HD.

Table. Summary of Hypothermic Patients Treated by Hemodialysis.

Reference	Age (yr)	Renal failure	Minimal temp (°C)	Initial rewarming methods	Duration before HD (h)	Rewarming rate before HD (°C/h)	HD duration (h)	Dialysate K ⁺ (mEq/L)	Dialysate temp (°C)	Qb (mL/min)	Rewarming rate during HD (°C/h)	Afterdrop during HD	Rewarming shock during HD
16	34	Yes	27.0	wIVF	NS	NS	4	3	40	450-500	2.2	No	No
15	35	No	23.9	wIVF, wBL, hAir	<1	NS	7	NS	NS	NS	1.9	No	No
18	65	No	26.0	wIVF, wBL, hAir, Blad	>7	0.5	2	4	36→ 35→ 36	200	2.4	No	Yes
17	73	Yes	24.9	PD	6	1.0	3.5	4	NS	NS	1.9	No	No
21	71	Yes	30.0	wIVF, wBL	NS	NS	NS	NS	NS	NS	NS	NS	NS
19	45	No	26.2	wIVF, wBL, hAir	4.5	1.1	4	3	37	300	3.3	No	Yes
20	49	Yes	23.5	wIVF, wBL, hAir	5.5	0.8	4	4	36→ 37→ 38	400	1.5	No	No
Case 1	48	No	26.4	wIVF wBL	2	1.0	2.5	3	35	150	1.6	No	No
Case 2	78	No	27.4	wIVF, wBL	1	1.0	3	3.5	37	150	1.5	No	Yes
Case 3	77	No	28.4	wIVF, wBL	1	0.0	2.5	3.5	35	120	1.4	No	No

temp: temperature, HD: hemodialysis, Qb: blood flow rate, wIVF: warmed intravenous fluids, wBL: warmed blankets, hAir: heated air blower, Blad: bladder irrigation, PD: peritoneal dialysis, NS: not specified

Second, the average rewarming rates before and during HD in 10 cases were 0.8°C/h (range: 0.0-1.1°C/h) and 2.0°C/h (range: 1.4-3.3°C/h), respectively. HD successfully increased the rewarming rate. The results of the previous studies showed that a delay in rewarming is closely associated with a high mortality rate and is an important prognostic factor (3, 9). Indeed, Morita et al. reported that rapid rewarming up to 32°C by CPB reduced the risk of ventricular fibrillation and mortality in severe hypothermic patients (9). Furthermore, Vassal et al. analyzed patients with accidental hypothermia who were treated by passive rewarming methods solely and showed that a slower rewarming rate was an important prognostic factor related to increased mortality (3). During HD therapy, the rewarming rate tends to depend on the dialysate temperature and Qb. Although there are no data available concerning the best rewarming rate during HD and no reports that HD improves the outcome of hypothermic patients compared to other rewarming methods, HD is likely to be useful because it can accelerate the rewarming rate efficiently. Third, the duration before starting HD is relatively short compared to other invasive therapies, such as CPB and ECMO (9). Vassal et al. previously showed that a delay in rewarming was also an important prognostic factor related to increased mortality (3). Of note, less than 2 hours passed before HD was started in all 3 of our cases. To prevent the negative effects of a slow rewarming rate, minimally invasive internal rewarming techniques have been encouraged. In this regard, HD is readily available and useful.

In conclusion, HD is a safe rewarming therapy for moderate and severe hypothermia in the absence of circulatory arrest. Even cases with a normal renal function, it can provide

efficient and adjustable rapid rewarming without a core temperature afterdrop. However, further studies are required to establish the active internal rewarming strategy with the use of HD for moderate and severe hypothermia.

The authors state that they have no Conflict of Interest (COI).

References

- Larach MG. Accidental hypothermia. *Lancet* **345**: 493-498, 1995.
- Brown DJ, Brugger H, Boyd J, Paal P. Accidental hypothermia. *N Engl J Med* **367**: 1930-1938, 2012.
- Vassal T, Benoit-Gonin B, Carrat F, Guidet B, Maury E, Offenstadt G. Severe accidental hypothermia treated in an ICU: prognosis and outcome. *Chest* **120**: 1998-2003, 2001.
- Danzl DF, Pozos RS. Accidental hypothermia. *N Engl J Med* **331**: 1756-1760, 1994.
- Osborn JJ. Experimental hypothermia; respiratory and blood pH changes in relation to cardiac function. *Am J Physiol* **175**: 389-398, 1953.
- Graham CA, McNaughton GW, Wyatt JP. The electrocardiogram in hypothermia. *Wilderness Environ Med* **12**: 232-235, 2001.
- Steele MT, Nelson MJ, Sessler DI, et al. Forced air speeds rewarming in accidental hypothermia. *Ann Emerg Med* **27**: 479-484, 1996.
- Muthukrishnan J, Dhul P, Dhall A, Garg MK, Prakash MS, Baliga KV. Management of hypothermia with warm peritoneal dialysis. *Med J Armed Forces India* **59**: 149-151, 2003.
- Morita S, Inokuchi S, Yamagiwa T, et al. Efficacy of portable and percutaneous cardiopulmonary bypass rewarming versus that of conventional internal rewarming for patients with accidental deep hypothermia. *Crit Care Med* **39**: 1064-1068, 2011.
- Walpoth BH, Walpoth-Aslan BN, Mattle HP, et al. Outcome of survivors of accidental deep hypothermia and circulatory arrest treated with extracorporeal blood warming. *N Engl J Med* **337**:

- 1500-1505, 1997.
11. Gregory JS, Bergstein JM, Aprahamian C, Wittmann DH, Quebbeman EJ. Comparison of three methods of rewarming from hypothermia: advantages of extracorporeal blood warming. *J Trauma* **31**: 1247-1252, 1991.
 12. Farstad M, Andersen KS, Koller ME, Grong K, Segadal L, Husby P. Rewarming from accidental hypothermia by extracorporeal circulation: a retrospective study. *Eur J Cardiothorac Surg* **20**: 58-64, 2001.
 13. Oberhammer R, Beikircher W, Hörmann C, et al. Full recovery of an avalanche victim with profound hypothermia and prolonged cardiac arrest treated by extracorporeal re-warming. *Resuscitation* **76**: 474-480, 2008.
 14. Ruttman E, Weissenbacher A, Ulmer H, et al. Prolonged extracorporeal membrane oxygenation-assisted support provides improved survival in hypothermic patients with cardiocirculatory arrest. *J Thorac Cardiovasc Surg* **134**: 594-600, 2007.
 15. Carr Jr ME, Wolfert AI. Rewarming by hemodialysis for hypothermia: failure of heparin to prevent DIC. *J Emerg Med* **6**: 277-280, 1988.
 16. Hernandez E, Praga M, Alcazar JM, et al. Hemodialysis for treatment of accidental hypothermia. *Nephron* **63**: 214-216, 1993.
 17. Owda A, Osama S. Hemodialysis in management of hypothermia. *Am J Kidney Dis* **38**: E8, 2001.
 18. Sultan N, Theakston KD, Butler R, Suri RS. Treatment of severe accidental hypothermia with intermittent hemodialysis. *CJEM* **11**: 174-177, 2009.
 19. Rahman S, Rubinstein S, Singh J, Samih M, Balsam L. Early use of hemodialysis for active rewarming in severe hypothermia: a case report and review of literature. *Ren Fail* **34**: 784-788, 2012.
 20. Singh T, Hallows KR. Hemodialysis for the treatment of severe accidental hypothermia. *Semin Dial* **27**: 295-297, 2014.
 21. Yokoyama M, Noto Y, Kida H. Hypothermia with acute renal failure in a patient suffering from diabetic nephropathy and malnutrition. *Diabetes Metab* **26**: 145-147, 2000.
 22. Soar J, Perkins GD, Abbas G, et al. European Resuscitation Council Guidelines for Resuscitation 2010 Section 8: cardiac arrest in special circumstances: electrolyte abnormalities, poisoning, drowning, accidental hypothermia, hyperthermia, asthma, anaphylaxis, cardiac surgery, trauma, pregnancy, electrocution. *Resuscitation* **81**: 1400-1433, 2010.

The Internal Medicine is an Open Access journal distributed under the Creative Commons Attribution-NonCommercial-NoDerivatives 4.0 International License. To view the details of this license, please visit (<https://creativecommons.org/licenses/by-nc-nd/4.0/>).