





Research Article

Impact of Coenzyme Q10 Administration on Lead Acetate-Induced Testicular Damage in Rats

Manal El-khadragy ^{1,2}, Wafa A. Al-Megrin,¹ Norah A. AlSadhan,³ Dina M. Metwally ^{4,5},
Rehab E. El-Hennamy,² Fatma Elzahraa H. Salem,^{2,6} Rami B. Kassab ^{2,7}
and Ahmed E. Abdel Moneim ²

¹Biology Department, Faculty of Science, Princess Nourah Bint Abdulrahman University, Riyadh 84428, Saudi Arabia

²Zoology and Entomology Department, Faculty of Science, Helwan University, Cairo 11795, Egypt

³College of Medicine, AlMaarefa University, 11597 Riyadh, Saudi Arabia

⁴Zoology Department, Faculty of Science, King Saud University, Riyadh 11451, Saudi Arabia

⁵Faculty of Veterinary Medicine, Zagazig University, Zagazig, Egypt

⁶Biology Department, Faculty of Science, Taibah University, Medina 42353, Saudi Arabia

⁷Biology Department, Faculty of Science and Arts, Al Baha University, Almahwah Branch, Saudi Arabia

Correspondence should be addressed to Manal El-khadragy; manalelkhadragy@yahoo.com

Received 23 March 2020; Revised 28 April 2020; Accepted 12 May 2020; Published 3 June 2020

Guest Editor: German Gil

Copyright © 2020 Manal El-khadragy et al. This is an open access article distributed under the Creative Commons Attribution License, which permits unrestricted use, distribution, and reproduction in any medium, provided the original work is properly cited.

Exposure to lead (Pb) causes multiorgan dysfunction including reproductive impairments. Here, we examined the protective effects of coenzyme Q10 (CoQ10) administration on testicular injury induced by lead acetate (PbAc) exposure in rats. This study employed four experimental groups ($n = 7$) that underwent seven days of treatment as follows: control group intraperitoneally (i.p.) treated with 0.1 ml of 0.9% NaCl containing 1% Tween 80 ($v : v$), CoQ10 group that was i.p. injected with 10 mg/kg CoQ10, PbAc group that was i.p. treated with PbAc (20 mg/kg), and PbAc+CoQ10 group that was i.p. injected with CoQ10 2 h after PbAc. PbAc injection resulted in increasing residual Pb levels in the testis and reducing testosterone, luteinizing hormone, and follicle-stimulating hormone levels. Additionally, PbAc exposure resulted in significant oxidative damage to the tissues on the testes. PbAc raised the levels of prooxidants (malondialdehyde and nitric oxide) and reduced the amount of endogenous antioxidant proteins (glutathione and its derivative enzymes, catalase, and superoxide dismutase) available in the cell. Moreover, PbAc induced the inflammatory response as evidenced by the upregulation of inflammatory mediators (tumor necrosis factor- α and interleukin-1 β). Further, PbAc treatment induced apoptosis in the testicular cells, as indicated by an increase in Bax and caspase 3 expression, and reduced Bcl2 expression. CoQ10 supplementation improved testicular function by inhibiting Pb accumulation, oxidative stress, inflammation, cell death, and histopathological changes following PbAc exposure. Our findings suggest that CoQ10 can act as a natural therapeutic agent to protect against the reproductive impairments associated with PbAc exposure.

1. Introduction

Lead is an important environmental pollutant, which can cause serious illness if it is not controlled and monitored. It is widely used in industry, cosmetics, and medicine [1], and accumulation of lead in the environment can exert a toxic effect on humans and animals and causes damage to several important organs including the nervous system [2], skeleton

[3], and cardiovascular system [4]. Recently, lead exposure has been highlighted as an important cause of testicular malfunction and male infertility [5, 6]. Excess exposure to lead products reduces semen quality and reproductive capacity causing male infertility [6]. It also promotes apoptosis and DNA damage in the spermatozoa [1] and activates Bax and caspase-3 in spermatogenic cells, which induces apoptosis [5]. It also impairs sperm function by reducing

cyclic adenosine monophosphate and calcium levels of sperm and decreasing tyrosine phosphorylation of sperm proteins [7]. Pb exposure affects also the hormonal secretion as it suppresses the anterior pituitary secretion of LH and FSH [8]. Lead's toxic effect in the testes is facilitated by its ability to produce reactive oxygen species. It was reported that lead exposure causes an increase in membrane lipid peroxidation as well as reductions in the endogenous antioxidant [9]. It reduces the levels of glutathione, superoxide dismutase, and other enzymatic antioxidants [9].

Coenzyme Q10 (CoQ10) is concentrated in the mitochondria of eukaryotic cells, where it functions as a key element in the electron transport chain and thus an important factor in energy production. CoQ10 supplementation has been shown to have benefits in the treatment and prevention of a number of diseases including heart disease and cancer [10]. These benefits are associated with CoQ10's documented antioxidant and anti-inflammatory characteristics [11]. In addition, CoQ10 is able to prevent lipid peroxidation and adjust cytoplasmic redox potentials [12]. CoQ10 is found naturally in the seminal fluid and plays a central role in enhancing several key features of semen. Deficiency in CoQ10 has been linked to impaired sperm parameters [13]. Therefore, it has been used in several studies as a treatment for infertile men. It improves sperm density, sperm motility, sperm morphology, and sperm count [14, 15]. It also reduces the levels of follicle-stimulating hormone and luteinizing hormone [14, 15]. A recent study on men with idiopathic oligoasthenozoospermia has proven its ability to increase sperm concentration and motility that is associated with the increase in the antioxidant capacity and enzymatic antioxidant activity as well [16]. Hence, this study was designed to evaluate the protective effect of CoQ10 supplementation following PbAc exposure in the testes of rats. The study will explore the antioxidant, antiapoptotic, and anti-inflammatory properties of CoQ10, with a specific emphasis on the *Nfe2l2/Hmox1* pathway.

2. Materials and Methods

2.1. Chemicals and Experimental Animals. Lead acetate trihydrate and CoQ10 were sourced from Sigma-Aldrich (St. Louis, MO, USA). The other reagents and chemicals were all analytical grade. Double-distilled water was used as the solvent. CoQ10 was dissolved in saline solution (0.9% NaCl) containing 1% Tween 80 (*v : v*) by stirring overnight at 25°C.

Male Wistar albino rats, aged ten weeks and weighing 150–170 g, were purchased from the animal facility of the Holding Company for Biological Products and Vaccines (Cairo, Egypt) and maintained in wire polypropylene cages under standard conditions (25 ± 2°C; 12 h light-dark cycle). The rats had access to water and standard rodent's diet *ad libitum*. Prior to the initialization of the experiment, rats were given one week for acclimatization. The experimental protocols were designed using the European Community Directive (86/609/EEC), and the national rules on animal care and all experiments were carried out in accordance with the NIH Guidelines for the Care and Use of Laboratory Animals 8th edition. This study was approved by the Institutional Animal

Ethics Committee for animal care and use at Helwan University (approval number: HU/Z/010-18).

2.2. Experimental Design. In order to explore the application of CoQ10 as a protective against lead acetate- (PbAc-) induced testicular toxicity, the rats were divided randomly into four groups (seven rats/group):

- (i) Control group: rats were intraperitoneally (i.p.) treated with 0.1 ml of 0.9% NaCl containing 1% Tween 80 (*v : v*)
- (ii) CoQ10 group: CoQ10 was i.p. injected at 10 mg/kg according to the protocol described in a previous report [17]
- (iii) PbAc group: rats were i.p. treated with PbAc (20 mg/kg) based on the protocol developed by Moneim [18]
- (iv) PbAc+CoQ10 group: CoQ10 was i.p. injected 2 h after PbAc. All the treated groups were injected intraperitoneally for seven days

As reprotoxicity mediated by lead is well characterized, and several acute exposures at a much higher dosage as this have already been reported [19], we have applied this treatment regimen of seven days to mimic acute toxicity. CoQ10 and PbAc doses were selected based on the earlier published researches [17, 18].

2.3. Sampling and Tissue Preparations. At 24 h after the last injection, rats were sacrificed by using an overdose of isoflurane. Under anaesthesia and before sacrificing, blood was collected by syringe puncture of the abdominal aorta, and the serum was separated. The testes were removed. One of the testes from each rat was used for molecular and histopathological analyses, while the other was washed, weighed, and homogenized in ice-cold medium containing 50 mM Tris-HCl (pH 7.4). The homogenates were spun at 3000 × *g* at 4°C for 10 min; then, the supernatant was stored at -20°C for biochemical assay.

To evaluate the inflammatory and apoptotic markers using ELISA, testicular tissue was weighed and homogenized with ice-cold extracting buffer (0.1 ml), containing 0.1% nondenaturing detergent (Sigma, St. Louis, MO, USA) in phosphate-buffered saline with protease inhibitor cocktail (catalog number P8340, Sigma, St. Louis, MO, USA) in a 5:1 (*v : w*). After homogenization, the mixture was incubated for 10 min. The mixture was spun at 15,000 × *g* at 4°C (10 min). The developed supernatant was applied for the estimation of TNF-α, IL-1β, Bax, caspase 3, and Bcl-2.

2.4. Measurement of Lead Concentration in the Testis. The protocol established by Szkoda and Zmudzki [20] was used to estimate lead deposition in the left testis. Testicular specimens were dehydrated at 60°C and then dried at 150°C for 24 h in the oven. After which, the samples were dissolved in a hot solution of 1 M HNO₃ then made up to 50 ml with deionized water. The samples were measured using a flame atomic absorption spectrophotometer (Perkin-Elmer, 3100)

at 283.3 nm. Accumulated lead was expressed as $\mu\text{g/g}$ wet tissue weight.

2.5. Testicular Weight Assessment. The testicular absolute weight was measured using a sensitive weighing balance (Radwag, Model AS220/C/2, Clarkson Laboratory and Supply Inc., Chula Vista, CA, USA), whereas the relative testicular weight was calculated using the following formula:

$$\text{Relative testis weight} = \frac{\text{Left testis (LT)}}{\text{Body weight}} \times 100 \quad (1)$$

2.6. Measurements of Sex Hormone Concentrations in the Blood. The estimation of testosterone, luteinizing hormone (LH), and follicle-stimulating hormone (FSH) levels was performed using specific commercial enzyme-linked immunosorbent assay (ELISA) kits (MyBioSource, Inc., San Diego, CA, USA) according to the manufacturer's instructions.

2.7. Determination of Redox Status in the Testis. Testicular nitric oxide (NO) content was determined using the optimized acid reduction method in the presence of nitrite. In this reaction, nitrous acid diazotized sulfanilamide couples with N-(1-naphthyl) ethylenediamine, resulting in the production of a bright reddish purple azo dye which can be quantified at 540 nm [21]. LPO in the testicular tissues was assessed using the malondialdehyde (MDA) method described by Ohkawa et al. [22]. Briefly, 100 mg of the testicular homogenate (pH 7.4) was blended with 100 μl of sodium thioglycolate (1%), 100 μl 100% trichloroacetic acid (TCA), and 250 μl 1 N HCl. This mixture was then incubated for 20 min at 100°C and then centrifuged for 10 min (4000 rpm). The color was then used to estimate thiobarbituric acid reactive substance (TBARS) content and was evaluated at 532 nm. Additionally, the glutathione (GSH) levels in the testes was assessed via the reduction of 5,5'-dithiobis (2-nitrobenzoic acid) (Ellman's reagent) which turns yellow following reduction. The proportion of the reduced chromogen is directly proportional to the GSH concentration, and its absorbance can be evaluated at 405 nm [23].

2.8. Measurement of the Antioxidant Status of the Testes. The superoxide dismutase (SOD) activity was determined by measuring its ability to inhibit phenazine methosulfate-mediated reduction of nitroblue tetrazolium (NBT) [24]. Catalase (CAT) was estimated by adding 50 μl of the testicular homogenate to 30 mM H_2O_2 in 50 mM potassium phosphate buffer (pH 8.0). H_2O_2 decomposition was then measured as a change in absorbance at 340 nm over 120 s at 20 s intervals [25]. The activity of glutathione reductase (GR) was assessed indirectly by assaying its catalysis of the glutathione reduction reaction in the presence of NADPH. NADPH oxidation to NADP^+ was measured as a reduction in absorbance at 340 nm [26]. Finally, the activity of glutathione peroxidase (GPx) was estimated using the Paglia and Valentine [27] method. This assay measures the activity of GPx indirectly. The oxidized glutathione, resulting from the reduction of organic peroxide by GPx, is returned to its reduced state by glutathione reductase. This

oxidizes NADPH to NADP^+ which can be measured at 340 nm.

2.9. Inflammation Marker Assays. Tumor necrosis factor- α (TNF- α) and interleukin-1 β (IL-1 β) levels were evaluated in the testicular homogenate using ELISA kits purchased from Thermo Fisher Scientific. The kits were used as per the manufacturer's instructions.

2.10. Apoptotic Marker Assays. Testicular Bax, caspase 3, and Bcl-2 expressions were evaluated using commercial ELISA kits obtained from BioVision, Inc., Sigma-Aldrich, and Cusabio, respectively. These assays were completed as per the manufacturer's instructions.

2.11. Quantitative Real Time PCR. The RNeasy Plus Minikit (Qiagen, Valencia, CA) was used to purify the total RNA from the testicular tissues. cDNA was prepared using the RevertAid™ H Minus Reverse Transcriptase kit (Fermentas, Thermo Fisher Scientific Inc., Canada). For real-time PCR analysis, samples of cDNA were run in triplicate. The reaction was performed using the Power SYBR® Green Mastermix (Life Technologies, CA) on an Applied Biosystems 7500 system. The PCR cycling thermal conditions were established as follows: preliminary denaturation at 95°C for 12 min, then by 45 cycles of denaturation at 94°C for 60 s and annealing at 55°C for 60 s, extension at 72°C for 90 s, and afterwards held for a final extension at 72°C for 10 min. Gene expression values were normalized against *Actb*. The primer sequences and accession numbers for each of these genes are provided in Table 1.

2.12. Histological Examinations. The testes were fixed in 10% neutral buffered formalin for 24 h at room temperature. The tissues were dehydrated using an ascending series of alcohol concentrations, cleared in xylene, and embedded in paraffin wax. Paraffin blocks were sectioned at 5 μm thickness then hydrated and stained with hematoxylin and eosin according to the Drury and Wallington [28] method. Sections were examined using a Nikon microscope (Eclipse E200-LED, Tokyo, Japan). Images represent the 400x magnification.

2.13. Immunohistochemical Investigations. After the deparaffinization and hydration of the testis sections, the peroxidase activity was blocked by H_2O_2 (3%). The sections were rinsed twice with distilled water, followed by phosphate buffer for 5 min. After the washing procedure, the sections were incubated with a blocking solution, the bovine serum albumin (5%), for 60 min. Testis sections were incubated with primary antibodies for caspase 3 (Santa Cruz, CA, USA) at 4°C overnight. Washing the sections with PBS was applied three times (5 min) the next day. Then, the sections were incubated with the secondary antibodies for 30 min. Another wash with PBS for three times (5 min) was performed before the incubation with diaminobenzidine for 5 min. Finally, sections were washed with distilled water (5 min) then stained with hematoxylin. Sections were investigated with the Eclipse E200-LED microscope (Nikon, Kawasaki, Japan) at the magnification of 400x.

TABLE 1: Primer sequences of genes analyzed by real time PCR.

Name	Sense (5'—3')	Antisense (5'—3')
<i>Actb</i>	GGCATCCTGACCCTGAAGTA	GGGGTGTGAAGGTCTCAAA
<i>Sod2</i>	AGCTGCACCACAGCAAGCAC	TCCACCACCCTTAGGGCTCA
<i>Cat</i>	TCCGGGATCTTTTAAACGCCATTG	TCGAGCACGGTAGGGACAGTTCAC
<i>Gpx1</i>	CGGTTTCCCGTGCAATCAGT	ACACCGGGGACCAAATGATG
<i>Gsr</i>	TGCACTTCCCGGTAGGAAAC	GATCGCAACTGGGGTGAGAA
<i>Nfe2l2</i>	GGTTGCCACATTCCCAAAC	GGCTGGGAATATCCAGGGC
<i>Hmox1</i>	GCGAAACAAGCAGAACCCA	GCTCAGGATGAGTACCTCCCA
<i>Nos2</i>	CGAAACGCTTCACTTCCAA	TGAGCCTATATTGCTGTGGCT
<i>Il1b</i>	TGCCACCTTTTGACAGTGATG	TTCTTGTGACCCTGAGCGAC
<i>Tnf-α</i>	AGAGGCACTCCCCAAAAGA	CGATCACCCCGAAGTTCAGT
<i>Bcl2</i>	GACAGAAGATCATGCCGTCC	GGTACCAATGGCACTTCAAG
<i>Bax</i>	CTGAGCTGACCTTGGAGC	GACTCCAGCCACAAAGATG
<i>Casp3</i>	GAGCTTGAACGGTACGCTA	CCGTACCAGAGCGAGATGAC

Abbreviations of the genes: *Actb*: beta actin; *Sod2*: superoxide dismutase 2 mitochondrial (MnSOD); *Cat*: catalase; *Gpx1*: glutathione peroxidase 1; *Gsr*: glutathione reductase; *Nfe2l2*: nuclear factor erythroid 2-related factor 2; *Hmox1*: heme oxygenase-1; *Nos2*: inducible nitric oxide synthase; *Il-1β*: interleukin 1-beta; *Tnf-α*: tumor necrosis factor-alpha; *Bcl2*: B-cell lymphoma 2; *Bax*: Bcl-2-associated X protein; *Casp3*: caspase 3.

2.14. Statistical Analysis. The results are expressed as the mean ± standard error of the mean (SEM). Data were analyzed by one-way analysis of variance (ANOVA) using the statistical package SPSS, version 17. In order to compare the significance between groups, Duncan's test was used post hoc. A probability level of $p < 0.05$ was considered statistically significant.

3. Results

Lead accumulates in various body tissues including the reproductive organs. Here, PbAc i.p. injection (20 mg/kg, seven days) significantly increased Pb concentrations ($p < 0.001$) in testicular homogenates when compared to the vehicle control group. On the other hand, rats posttreated with CoQ10 showed a marked decrease in Pb levels in the testicular tissues when compared to the PbAc-treated group (Figure 1).

Data in Figure 2 shows that Pb accumulation correlates with the increased absolute and relative testicular weights in the lead-treated groups when compared to the control group. This weight gain decreased significantly ($p < 0.001$) following CoQ10 treatment.

In order to evaluate PbAc-induced reprotoxicity, serological levels of the sex hormones were determined (Figure 3). PbAc injection significantly decreased the levels of testosterone ($p < 0.001$), LH ($p < 0.05$), and FSH ($p < 0.01$) when compared to the control. In contrast, CoQ10 supplementation of Pb-free rats showed a significant increase in testosterone and LH levels, while FSH remained unchanged when compared to the control group. Interestingly, the group treated with both PbAc and CoQ10 showed a significant increase in the levels of these sex hormones when compared to the PbAc group.

PbAc injection impaired the balance between pro- and antioxidants in the testicular tissues as demonstrated by the increased LPO ($p < 0.001$) and NO ($p < 0.001$) concen-

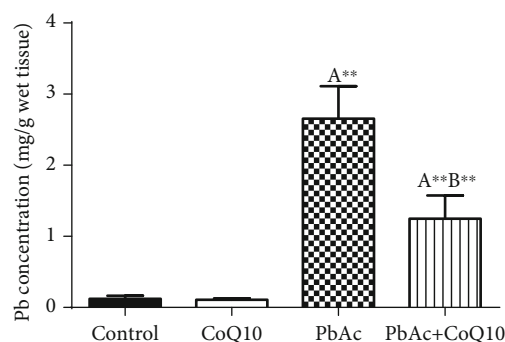


FIGURE 1: Effects of coenzyme Q10 (CoQ10, 10 mg/kg) administration on the concentration of Pb in the testis of rats treated with lead acetate (PbAc, 20 mg/kg). Data was represented as mean ± SEM ($n = 7$). ^{A,B}Significant change at $p < 0.05$; ^{***}Significant variation at $p < 0.01$ and $p < 0.001$, respectively, as compared to the control and PbAc groups, respectively. Data was analyzed by one-way ANOVA using Duncan's post hoc test.

trations and increased glutathione depletion ($p < 0.001$) observed in PbAc-treated rats (Figure 4). Moreover, we were able to demonstrate a significant decrease in the activity and expression of the antioxidant enzymes ((GPx1, *Gpx1*), (GR, *Gsr*), (CAT, *Cat*), and (SOD, *Sod2*)) following PbAc injection when compared to the control group. As expected, CoQ10 supplementation restored the redox status by decreasing the prooxidant concentration and promoting the activity of the endogenous antioxidant enzymes and their expression as demonstrated by changes in these parameters when compared to the PbAc-treated group (Figure 5).

To understand the molecular antioxidant activity of CoQ10, testicular expression of *Nfe2l2* and *Hmox1* was evaluated. Nrf2 regulates the expression and activity of numerous antioxidant and detoxifying proteins. PbAc treatment significantly downregulated ($p < 0.001$) *Nfe2l2*

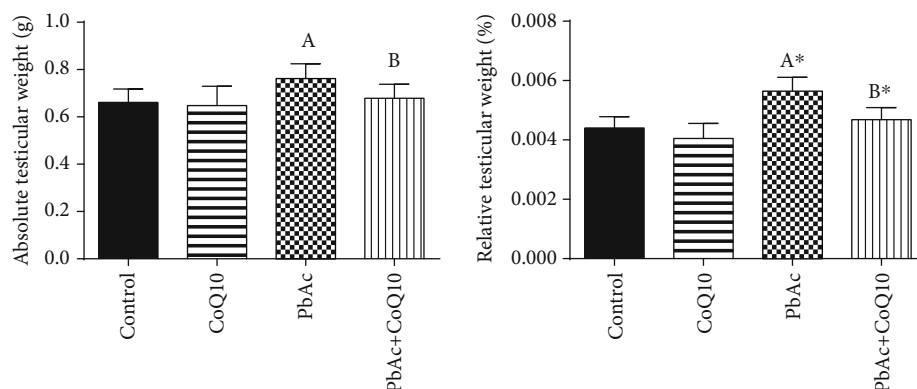


FIGURE 2: Effects of coenzyme Q10 (CoQ10, 10 mg/kg) administration on the absolute and relative testicular weight in rats treated with lead acetate (PbAc, 20 mg/kg). All data represented as mean \pm SEM ($n = 7$). ^{A,B}Significant change at $p < 0.05$; *Significant variation at $p < 0.01$ as compared to the control and PbAc groups, respectively. Data was analyzed by one-way ANOVA using Duncan's post hoc test.

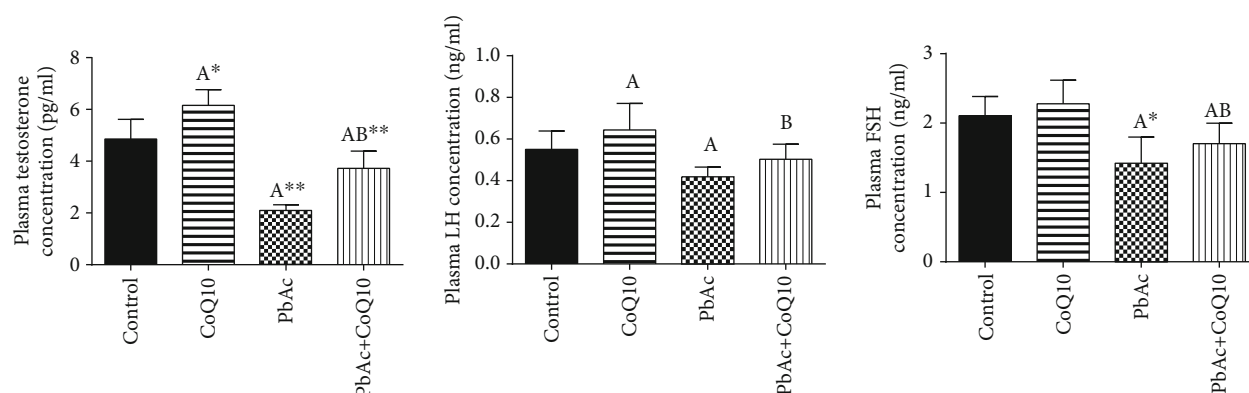


FIGURE 3: Effects of coenzyme Q10 (CoQ10, 10 mg/kg) administration on the plasma levels of testosterone, LH, and FSH in rats treated with lead acetate (PbAc, 20 mg/kg). All data represented as mean \pm SEM ($n = 7$). ^{A,B}Significant change at $p < 0.05$; **Significant variation at $p < 0.01$ and $p < 0.001$, respectively, as compared to the control and PbAc groups, respectively. Data was analyzed by one-way ANOVA using Duncan's post hoc test.

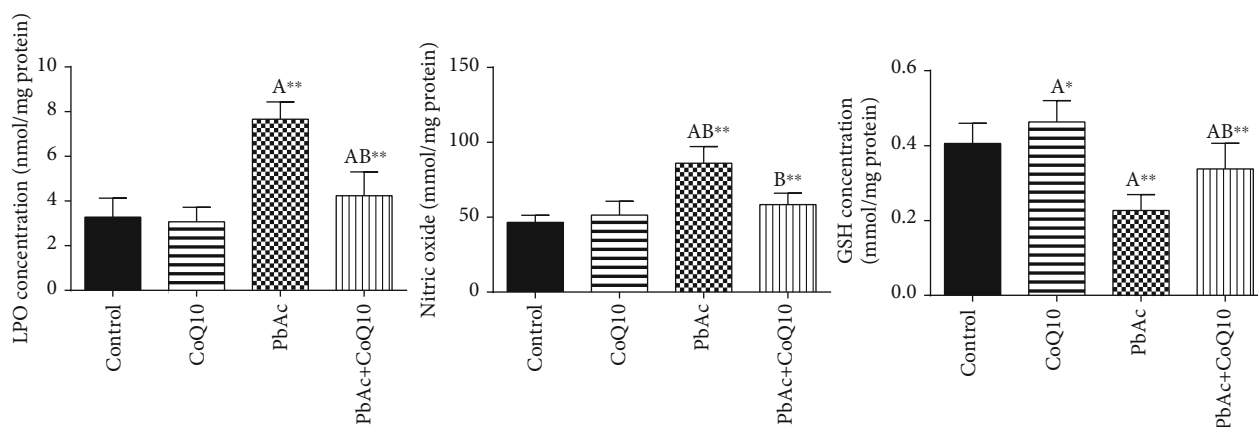


FIGURE 4: Effects of coenzyme Q10 (CoQ10, 10 mg/kg) administration on lipid peroxidation (LPO), nitric oxide (NO), and reduced glutathione (GSH) concentrations in the testis of rats treated with lead acetate (PbAc, 20 mg/kg). Data was represented as mean \pm SEM ($n = 7$). ^{A,B}Significant change at $p < 0.05$; **Significant variation at $p < 0.01$ and $p < 0.001$, respectively, as compared to the control and PbAc groups, respectively. Data was analyzed by one-way ANOVA using Duncan's post hoc test.

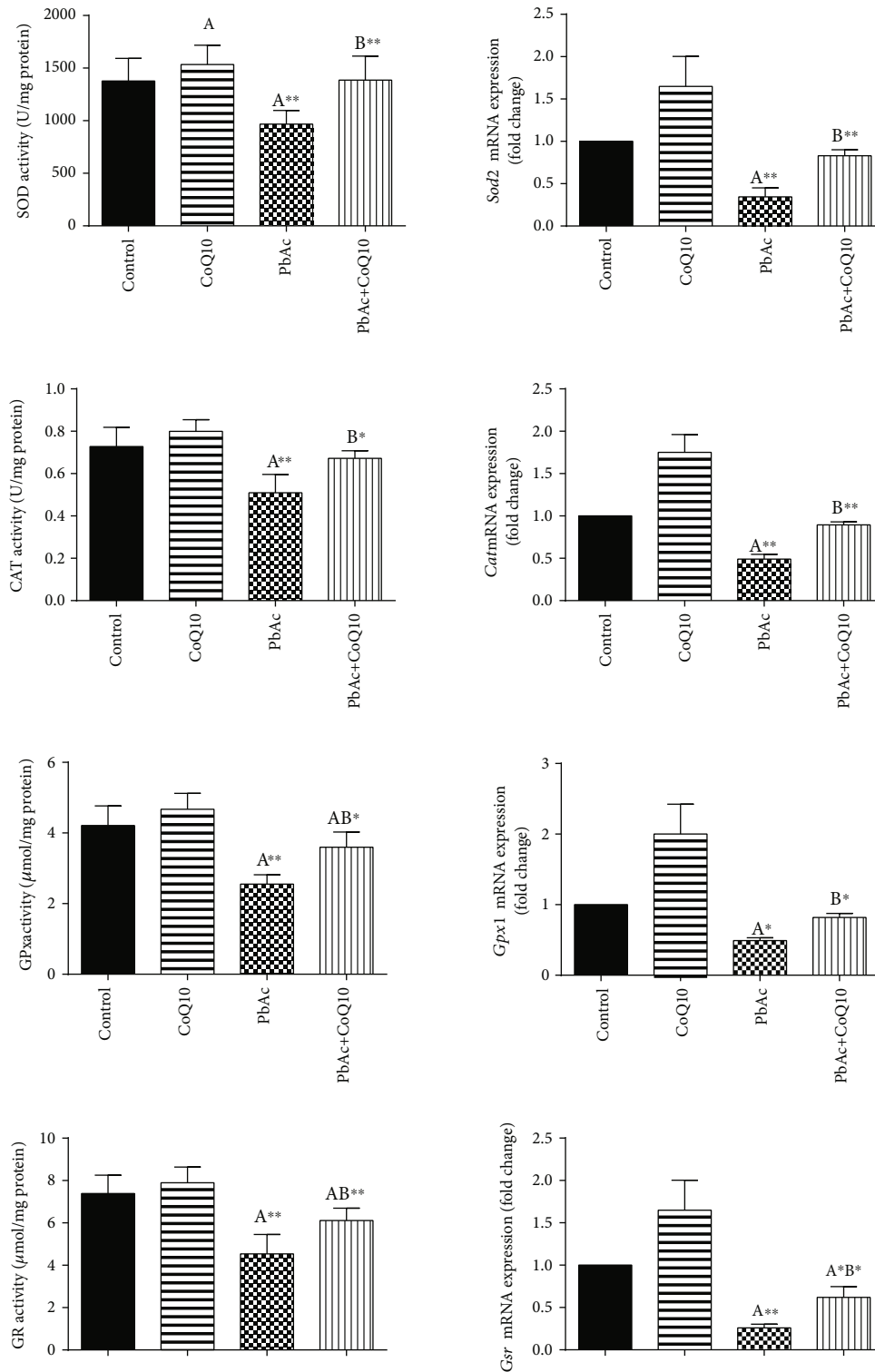


FIGURE 5: Effects of coenzyme Q10 (CoQ10, 10 mg/kg) administration on the activity of superoxide dismutase (SOD), catalase (CAT), glutathione peroxidase (GPx), glutathione reductase (GR), and their corresponding mRNA expressions in the testis of rats exposed to lead acetate (PbAc, 20 mg/kg). Data of the antioxidant enzyme activity was represented as mean \pm SEM ($n = 7$), while the values of mRNA expressions (mean \pm SEM of triplicate assays) were normalized to the *Actb* mRNA levels and are expressed as the fold change relative to the control group. ^{A,B}Significant change at $p < 0.05$; ^{**}Significant variation at $p < 0.01$ and $p < 0.001$, respectively, as compared to the control and PbAc groups, respectively. Data was analyzed by one-way ANOVA using Duncan's post hoc test.

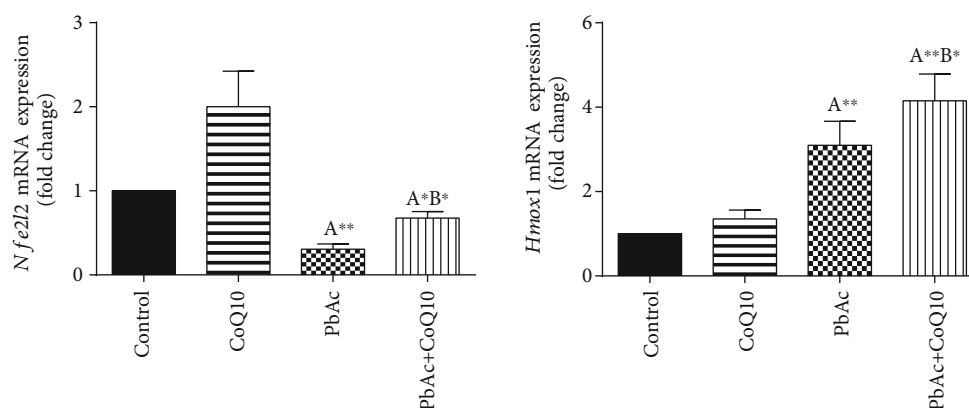


FIGURE 6: Effects of coenzyme Q10 (CoQ10, 10 mg/kg) administration on the mRNA levels of *Nfe2l2* and *Hmox1* in the testes of rats exposed to lead acetate (PbAc, 20 mg/kg). Data was represented as mean \pm SEM of triplicate assays. Data was first normalized to the *Actb* mRNA levels then was expressed as a fold change relative to the control group. ^{A,B}Significant change at $p < 0.05$; **Significant variation at $p < 0.01$ and $p < 0.001$, respectively, as compared to the control and PbAc groups, respectively.

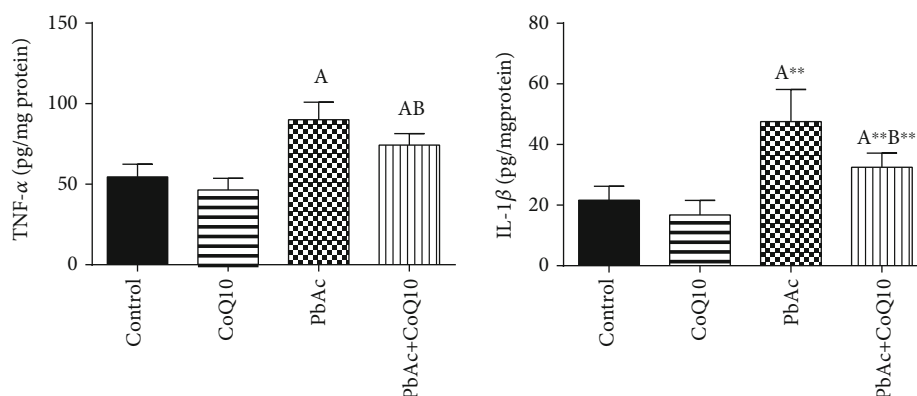


FIGURE 7: Effects of coenzyme Q10 (CoQ10, 10 mg/kg) administration on the levels of tumor necrosis factor- α (TNF- α) and interleukin-1 β (IL-1 β) in the testis of rats treated with lead acetate (PbAc, 20 mg/kg). Data was represented as mean \pm SEM ($n = 7$). ^{A,B}Significant change at $p < 0.05$; **Significant variation at $p < 0.01$ and $p < 0.001$, respectively, as compared to the control and PbAc groups, respectively.

expression, while upregulated ($p < 0.001$) *Hmox1* expression when compared to the control group. When CoQ10 supplementation was added after PbAc treatment, both *Nfe2l2* and *Hmox1* expressions were upregulated when compared to PbAc treatment (Figure 6).

Inflammation has been suggested as one of the pathways that affect reproductive function following heavy metal intoxication. Rats injected with PbAc showed increased inflammation in the testicular tissues as demonstrated by increases in TNF- α ($p < 0.05$) and IL-1 β ($p < 0.001$) expression when compared to the control group, while CoQ10 post-treatment attenuated this response following PbAc exposure (Figure 7).

To evaluate cell death and the apoptotic cascade in the testicular tissue, the proapoptotic markers (Bax and caspase 3) and the antiapoptotic marker (Bcl2) were evaluated in each of the various groups. Rats treated with PbAc exhibited testicular cell loss as evidenced by the increased expression of *Bax* ($p < 0.001$) and *Casp3* ($p < 0.001$) and decreased *Bcl2* ($p < 0.001$) expression when compared to the control group,

while CoQ10 injection after PbAc exposure was found to protect the testicular tissues by enhancing *Bcl2* expression and inhibiting *Bax* and *Casp3* expression (Figure 8). Constant with the gene expression level of caspase-3, immunohistochemical analysis obviously showed that PbAc enhances the apoptotic cascade in the testicular tissue as presented by elevating the immunostaining intensity for the proapoptotic protein, caspase-3. However, postadministration of CoQ10 markedly decreased the number of the positively stained spermatogenic epithelial cells for caspase-3 immunoreactivity (Figure 9).

Histological examination of testicular sections stained with H&E was represented in Figure 10. Control and CoQ10-treated alone rats revealed normal testicular morphology with typical and functional seminiferous tubules with well-arranged spermatogenic cells displaying all stages and the interstitial cells filling the space between the seminiferous tubules (Figures 10(a) and 10(b), respectively). On the other hand, PbAc-injected rats exhibited deleterious histopathological alterations verified by degeneration

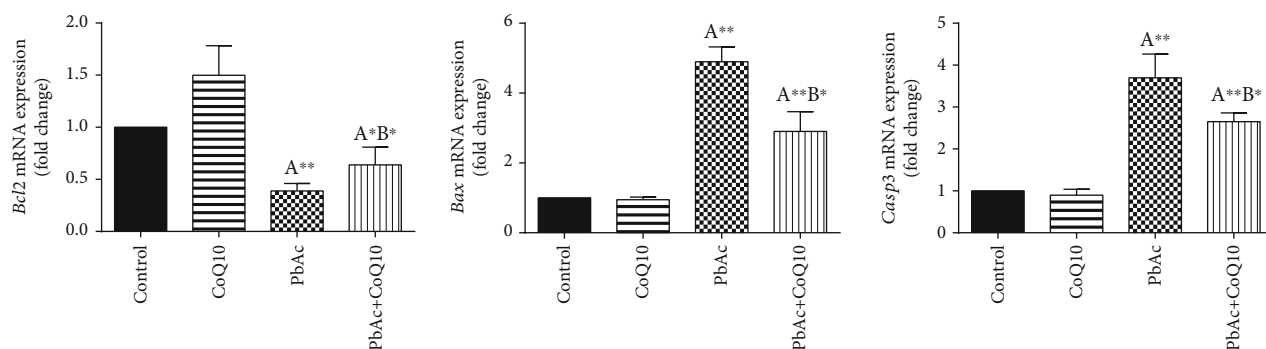


FIGURE 8: Effects of coenzyme Q10 (CoQ10, 10 mg/kg) administration on the mRNA expression of *Bcl2*, *Bax*, and *Casp3* in the testes of rats exposed to lead acetate (PbAc, 20 mg/kg). Data was represented as mean \pm SEM of triplicate assays. Data was first normalized to the *Actb* mRNA levels then was expressed as the fold change relative to the control group. ^{A,B}Significant change at $p < 0.05$; ^{***}Significant variation at $p < 0.01$ and $p < 0.001$, respectively, as compared to the control and PbAc groups, respectively. Data was analyzed by one-way ANOVA using Duncan's post hoc test.

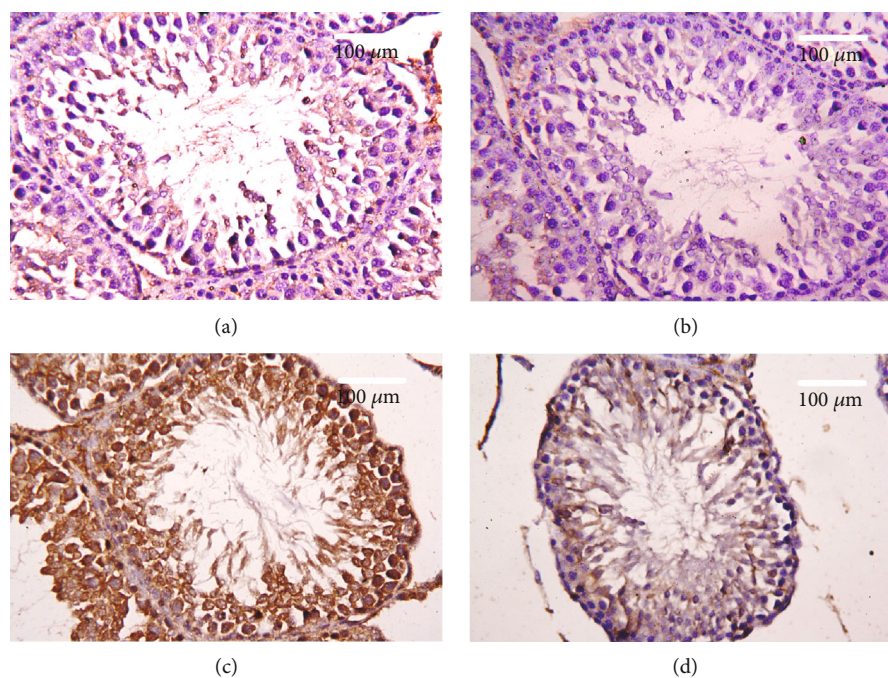


FIGURE 9: Effects of coenzyme Q10 (CoQ10, 10 mg/kg) administration on the caspase-3 expression in the testis tissue after lead acetate (PbAc, 20 mg/kg) exposure. (a) Control group, (b) CoQ10-administered group, (c) PbAc-exposed group, and (d) PbAc+CoQ10-treated group. Scale bar = 100 μ m.

of spermatogenic cells, detachment of the spermatogenic epithelial cells from the basement membrane, and appearance of a vacuolated area within the seminiferous tubules (Figure 10(c)). Interestingly, CoQ10 posttreatment repaired these abnormalities and largely preserved the testicular structures (Figure 10(d)).

4. Discussion

Pb toxicity primarily affects the testes [5, 29]. Testicular toxicity induced by PbAc treatment was characterized by diminished plasma testosterone and LH and FSH concentrations, which was in agreement with the observations of

Doumouchtsis et al. [30] and Soleimanzadeh *et al.* [31]. Hormonal reduction resulting from Pb exposure is attributed to impairment of the hypothalamus-pituitary-gonadal axis [8, 30, 32]. Pb exposure causes degeneration of the pituitary gland gonadotrophic cells [33] and induces apoptotic signals in the Leydig cells [7]. In addition, Pb inhibits steroidogenic enzyme production in Leydig cells resulting in reduced testosterone secretion [34].

The high levels of polyunsaturated fatty acids in the testicular cells make them vulnerable to oxidative stress [35]. Consequently, Pb toxicity-induced testicular malfunction may result from its ability to evoke membrane lipid peroxidation promoting oxidative stress and apoptosis [5, 36, 37].

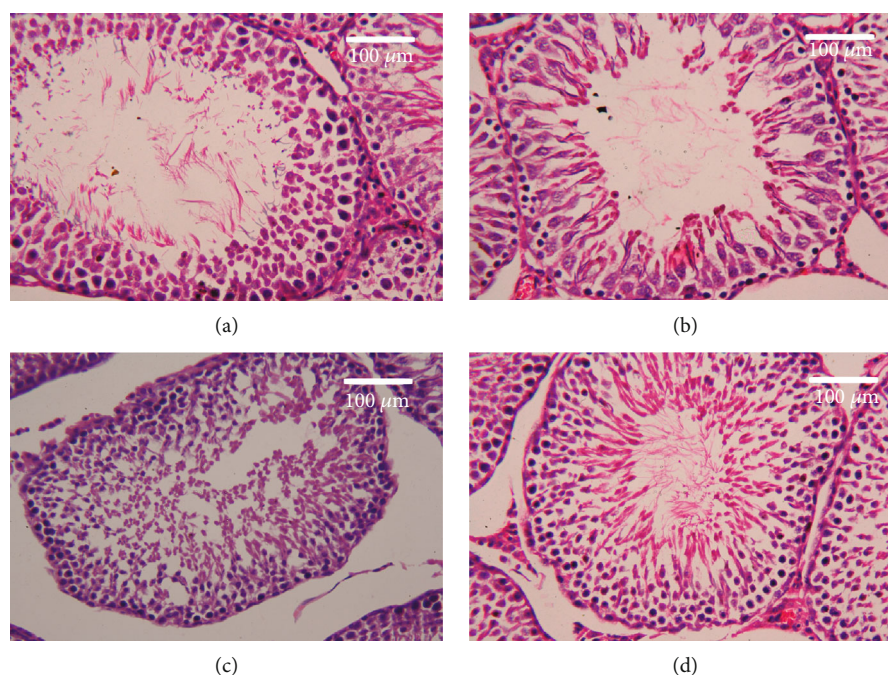


FIGURE 10: Effects of coenzyme Q10 (CoQ10, 10 mg/kg) administration on the histopathological changes in the testis tissue after lead acetate (PbAc, 20 mg/kg) exposure. (a) Control group, (b) CoQ10-administered group, (c) PbAc-exposed group, and (d) PbAc+CoQ10-treated group. Scale bar = 100 μ m.

Likewise, the prooxidant parameters, LPO and NO, increased after Pb injection. On the other hand, the antioxidant parameters were diminished with Pb treatment. The gene expression of the antioxidant enzymes, Cat mRNA, Gpx1 mRNA, Gsr mRNA, and Sod mRNA, and its corresponding proteins (CAT, GPX, GR, and SOD) were downregulated after Pb exposure. The GSH level and the activity of the antioxidant enzymes (GPx, GR, CAT, and SOD) were also all reduced. This depletion may be caused by Pb binding of the metal cofactors of these enzymes or from the interaction of Pb and their SH group, reducing overall function [38].

Moreover, the apoptotic pathway was activated by Pb administration which is demonstrated by the proapoptotic genes (Bax and caspase-3) upregulation, as well as the downregulation of the antiapoptotic gene, Bcl2. Similarly, previous studies revealed a testicular damage and apoptosis in the spermatogenic cells with Pb exposure [5, 7].

The inflammatory responses were elevated in the testes after Pb exposure, which was evidenced by the rise in the pro-inflammatory cytokines, TNF- α and IL1- β . Salama et al. [39] also reported an elevation in the proinflammatory cytokine levels in the kidneys of rats after Pb exposure. Furthermore, PbAc administration resulted in the downregulation of *Nfe212* gene expression. Suppression of *Nfe212* induces apoptosis, activates the inflammatory response, and decreases expression of the antioxidant enzymes [40]. *Hmox1* gene expression was upregulated. The activation of the *Hmox1* pathway may act to counter the elevation in the ROS and the inflammatory response [41].

Coenzyme Q10 is a natural antioxidant that plays a fundamental role in the electron transport chain [42]. It has been shown to exhibit a protective effect on the testes when they

are exposed to magnetic fields [43], ischemia/reperfusion injuries [44], and sodium arsenite toxicity [45]. Here, we focused on its effect after PbAc exposure and we found that it could improve testicular function even in the presence of Pb. The absolute and relative testicular weight was restored following CoQ10 supplementation, while the testosterone, LH, and FSH levels were improved; signs of oxidative stress were decreased as evidenced by the reduction in LPO and NO concentrations. In addition, CoQ10 enhanced expression and level of glutathione and the antioxidant enzymes, CAT, SOD, GPx, and GR. Fouad et al. [45] revealed that CoQ10 could suppress oxidative stress in the testis by inhibiting lipid peroxidation and enhancing antioxidant enzyme activity. This in turn can counteract oxidative damage and sustain the function of Leydig cells protecting testosterone secretion [46]. The key application of CoQ10 in the testis is to increase the levels of CoQ10 and its reduced form, ubiquinol, in the semen [13]. Ubiquinol is a potent fat-soluble antioxidant that can regenerate other antioxidants including vitamins E and C [47]. It also eliminates peroxy radicals resulting from the lipid peroxidation process [48].

The antiapoptotic effect of CoQ10 has been described by several studies [40, 49], and it was confirmed in this study when CoQ10 treatment upregulated the expression of the antiapoptotic gene *Bcl2* and downregulated proapoptotic genes *Casp3* and *Bax*. Papucci et al. [50] attributed the antiapoptotic effect of CoQ10 to the inhibition of DNA fragmentation and mitochondrial depolarization as well as increasing ATP levels. Additionally, CoQ10 inhibits nuclear translocation of apoptosis-inducing factors and prevents cell death via the inhibition of mitochondrial complex I activity [51].

CoQ10 is implicated in the prevention of inflammation in the liver [52] and kidneys [40]. This anti-inflammatory effect can now be extended to the testes, as CoQ10 administration following PbAc reduced the concentrations of pro-inflammatory cytokines, TNF- α and IL-1 β , consequently attenuating inflammation. Meanwhile, it activated the *Nfe2l2/Hmox1* pathway by upregulating both *Nfe2l2* and *Hmox1* gene expressions. Previous studies indicated that CoQ10 exerts its cytoprotective role and antioxidant activity by activating the *Nfe2l2/Hmox1* pathway [53]. *Nfe2l2/Hmox1* signaling induces the transcription of the cytoprotective and antioxidant enzymes [54] and protects cells from damage and death [55]. *Nfe2l2*, the transcription factor, translocates from cytosol into the nucleus and bind to the antioxidant response element so upregulating the genes encoding antioxidant enzymes [56]. In addition, *Nfe2l2* activation resulted in the inhibition of NF- κ B and in turn reduces the proinflammatory cytokines [57]. Increased *Hmox1* activity generates two important metabolites, bilirubin and CO. Bilirubin acts as an antioxidant that inhibits lipid peroxidation [58], while CO protects the cell during oxidative stress [59] thus inhibiting apoptosis in various cells [53], and attenuates the production of proinflammatory cytokine [57].

5. Conclusion

Taken together, we can conclude that CoQ10 posttreatment ameliorates Pb-induced testicular toxicity by reducing oxidative stress, apoptosis, and inflammation. These observations may be the result of *Nfe2l2/Hmox1* pathway activation, but this will need further study for confirmation.

Data Availability

All relevant data are within the paper.

Conflicts of Interest

The authors declare no conflict of interest.

Authors' Contributions

All the authors contributed equally to this work.

Acknowledgments

This research was funded by Deanship of Scientific Research at Princess Nourah Bint Abdulrahman University through the Fast-Track research funding program.

References

- [1] S. R. Kumar and A. S. Devi, "Lead toxicity on male reproductive system and its mechanism: a review," *Research Journal of Pharmacy and Technology*, vol. 11, no. 3, p. 1228, 2018.
- [2] A. Rossi-George, M. B. Virgolini, D. Weston, M. Thiruchelvam, and D. A. Cory-Slechta, "Interactions of lifetime lead exposure and stress: behavioral, neurochemical and HPA axis effects," *Neurotoxicology*, vol. 32, no. 1, pp. 83–99, 2011.
- [3] M. J. Zuscik, L. Ma, T. Buckley et al., "Lead induces chondrogenesis and alters transforming growth factor-beta and bone morphogenetic protein signaling in mesenchymal cell populations," *Environmental Health Perspectives*, vol. 115, no. 9, pp. 1276–1282, 2007.
- [4] D. Nash, L. Magder, M. Lustberg et al., "Blood lead, blood pressure, and hypertension in perimenopausal and postmenopausal women," *JAMA*, vol. 289, no. 12, pp. 1523–1532, 2003.
- [5] E. Hassan, M. El-Neweshy, M. Hassan, and A. Noreldin, "Thymoquinone attenuates testicular and spermotoxicity following subchronic lead exposure in male rats: possible mechanisms are involved," *Life Sciences*, vol. 230, pp. 132–140, 2019.
- [6] C. Li, K. Zhao, H. Zhang et al., "Lead exposure reduces sperm quality and DNA integrity in mice," *Environmental Toxicology*, vol. 33, no. 5, pp. 594–602, 2018.
- [7] Y. He, Q. Zou, H. Chen, S. Weng, T. Luo, and X. Zeng, "Lead inhibits human sperm functions by reducing the levels of intracellular calcium, cAMP, and tyrosine phosphorylation," *The Tohoku Journal of Experimental Medicine*, vol. 238, no. 4, pp. 295–303, 2016.
- [8] Y. S. El-Sayed and M. S. El-Neweshy, "Impact of lead toxicity on male rat reproduction at "hormonal and histopathological levels"," *Toxicological & Environmental Chemistry*, vol. 92, no. 4, pp. 765–774, 2010.
- [9] A. E. A. Moniem, M. A. Dkhil, and S. Al-Quraishy, "Protective role of flaxseed oil against lead acetate induced oxidative stress in testes of adult rats," *African Journal of Biotechnology*, vol. 9, no. 42, pp. 7216–7223, 2010.
- [10] A. Sarmiento, J. Diaz-Castro, M. Pulido-Moran, N. Kajarabille, R. Guisado, and J. J. Ochoa, "Coenzyme Q10 supplementation and exercise in healthy humans: a systematic review," *Current Drug Metabolism*, vol. 17, no. 4, pp. 345–358, 2016.
- [11] S. A. Mirmalek, A. Gholamrezaei Boushehrinejad, H. Yavari et al., "Antioxidant and Anti-Inflammatory Effects of Coenzyme Q10 on L-Arginine- Induced Acute Pancreatitis in Rat," *Oxidative Medicine and Cellular Longevity*, vol. 2016, 8 pages, 2016.
- [12] J. J. Challem, "Toward a new definition of essential nutrients: is it now time for a third 'vitamin' paradigm?," *Medical Hypotheses*, vol. 52, no. 5, pp. 417–422, 1999.
- [13] G. Balercia, "Coenzyme q10 supplementation in infertile men with idiopathic asthenozoospermia: an open, uncontrolled pilot study," *Fertility and Sterility*, vol. 81, no. 1, pp. 93–98, 2004.
- [14] M. R. Safarinejad, "Efficacy of coenzyme Q10 on semen parameters, sperm function and reproductive hormones in infertile men," *The Journal of Urology*, vol. 182, no. 1, pp. 237–248, 2009.
- [15] A. Mancini and G. Balercia, "Coenzyme Q10 in male infertility: physiopathology and therapy," *BioFactors*, vol. 37, no. 5, pp. 374–380, 2011.
- [16] A. T. Alahmar, "The impact of two doses of coenzyme Q10 on semen parameters and antioxidant status in men with idiopathic oligoasthenoteratozoospermia," *Clinical and Experimental Reproductive Medicine*, vol. 46, no. 3, pp. 112–118, 2019.
- [17] A. A. Fouad and I. Jresat, "Hepatoprotective effect of coenzyme Q10 in rats with acetaminophen toxicity," *Environmental Toxicology and Pharmacology*, vol. 33, no. 2, pp. 158–167, 2012.
- [18] A. E. Abdel Moneim, "Flaxseed oil as a neuroprotective agent on lead acetate-induced monoaminergic alterations and

- neurotoxicity in rats," *Biological Trace Element Research*, vol. 148, no. 3, pp. 363–370, 2012.
- [19] N. Li, Y. H. Hou, D. D. Ma, W. X. Jing, H. U. Dahms, and L. Wang, "Lead accumulation, oxidative damage and histopathological alteration in testes and accessory glands of freshwater crab, *Sinopotamon henanense*, induced by acute lead exposure," *Ecotoxicology and Environmental Safety*, vol. 117, pp. 20–27, 2015.
- [20] J. Szkoda and J. Zmudzki, "Determination of lead and cadmium in biological material by graphite furnace atomic absorption spectrometry method," *Bulletin of the Veterinary Institute in Pulawy*, vol. 49, pp. 89–92, 2005.
- [21] L. C. Green, D. A. Wagner, J. Glogowski, P. L. Skipper, J. S. Wishnok, and S. R. Tannenbaum, "Analysis of nitrate, nitrite, and [15N] nitrate in biological fluids," *Analytical Biochemistry*, vol. 126, no. 1, pp. 131–138, 1982.
- [22] H. Ohkawa, N. Ohishi, and K. Yagi, "Assay for lipid peroxides in animal tissues by thiobarbituric acid reaction," *Analytical Biochemistry*, vol. 95, no. 2, pp. 351–358, 1979.
- [23] G. L. Ellman, "Tissue sulfhydryl groups," *Archives of Biochemistry and Biophysics*, vol. 82, no. 1, pp. 70–77, 1959.
- [24] Y. Sun, L. W. Oberley, and Y. Li, "A simple method for clinical assay of superoxide dismutase," *Clinical Chemistry*, vol. 34, no. 3, pp. 497–500, 1988.
- [25] H. Lück, "Catalase," in *Methods of Enzymatic Analysis*, H. U. Bergmeyer, Ed., pp. 855–888, Academic Press, New York, 1965.
- [26] V. M. Factor, A. Kiss, J. T. Weitach, P. J. Wirth, and S. S. Thorgerisson, "Disruption of redox homeostasis in the transforming growth factor- α /c-myc transgenic mouse model of accelerated hepatocarcinogenesis," *The Journal of Biological Chemistry*, vol. 273, no. 25, pp. 15846–15853, 1998.
- [27] D. E. Paglia and W. N. Valentine, "Studies on the quantitative and qualitative characterization of erythrocyte glutathione peroxidase," *The Journal of Laboratory and Clinical Medicine*, vol. 70, no. 1, pp. 158–169, 1967.
- [28] R. Drury and E. Wallington, *Carleton's histological techniques*, Oxford press, London, New York, 1980.
- [29] P. J. Landrigan, P. Boffetta, and P. Apostoli, "The reproductive toxicity and carcinogenicity of lead: a critical review," *American Journal of Industrial Medicine*, vol. 38, no. 3, pp. 231–243, 2000.
- [30] K. K. Doumouchtsis, S. K. Doumouchtsis, E. K. Doumouchtsis, and D. N. Perrea, "The effect of lead intoxication on endocrine functions," *Journal of Endocrinological Investigation*, vol. 32, no. 2, pp. 175–183, 2009.
- [31] A. Soleimanzadeh, M. Kian, S. Moradi, and S. Mahmoudi, "Carob (*Ceratonia siliqua* L.) fruit hydro-alcoholic extract alleviates reproductive toxicity of lead in male mice: evidence on sperm parameters, sex hormones, oxidative stress biomarkers and expression of Nrf2 and iNOS," *Avicenna journal of phyto-medicine*, 2019.
- [32] J. Gandhi, R. J. Hernandez, A. Chen et al., "Impaired hypothalamic-pituitary-testicular axis activity, spermatogenesis, and sperm function promote infertility in males with lead poisoning," *Zygote*, vol. 25, no. 2, pp. 103–110, 2017.
- [33] N. Hamadouche, N. Sadi, O. Kharoubi, M. Slimani, and A. Aoues, "The protective effect of vitamin E against genotoxicity of lead acetate intraperitoneal administration in male rat," *Archives of Biological Sciences*, vol. 65, no. 4, pp. 1435–1445, 2013.
- [34] B.-M. Huang and M.-Y. Liu, "Inhibitory actions of lead on steroidogenesis in MA-10 mouse Leydig tumor cells," *Archives of Andrology*, vol. 50, no. 1, pp. 5–9, 2009.
- [35] N. E. Furland, S. R. Zanetti, G. M. Oresti, E. N. Maldonado, and M. I. Aveldaño, "Ceramide and sphingomyelin with high proportions of very long-chain polyunsaturated fatty acids in mammalian germ cells," *Journal of Biological Chemistry*, vol. 282, no. 25, pp. 18141–18150, 2007.
- [36] D. D. Thomas, L. A. Ridnour, J. S. Isenberg et al., "The chemical biology of nitric oxide: implications in cellular signaling," *Free Radical Biology and Medicine*, vol. 45, no. 1, pp. 18–31, 2008.
- [37] M. A. Dkhal, M. S. Al-Khalifa, S. Al-Quraishy, R. Zrieq, and A. E. Abdel Moneim, "Indigofera oblongifolia mitigates lead-acetate-induced kidney damage and apoptosis in a rat model," *Drug Design, Development and Therapy*, vol. 10, pp. 1847–1856, 2016.
- [38] R. C. Patra, A. K. Rautray, and D. Swarup, "Oxidative Stress in Lead and Cadmium Toxicity and Its Amelioration," *Veterinary Medicine International*, vol. 2011, 9 pages, 2011.
- [39] S. A. Salama, H. H. Arab, I. A. Maghrabi, M. H. Hassan, and M. S. AlSaeed, "Gamma-glutamyl cysteine attenuates tissue damage and enhances tissue regeneration in a rat model of lead-induced nephrotoxicity," *Biological Trace Element Research*, vol. 173, no. 1, pp. 96–107, 2016.
- [40] A. M. Kabel and A. A. Elkhoely, "Ameliorative effect of coenzyme Q10 and/or candesartan on carboplatin-induced nephrotoxicity: roles of apoptosis, transforming growth factor-B1, nuclear factor kappa-B and the Nrf2/HO-1 pathway," *Asian Pacific journal of cancer prevention: APJCP*, vol. 18, no. 6, pp. 1629–1636, 2017.
- [41] E. M. Al Olayan, A. S. Aloufi, O. D. AlAmri, O. H. El-Habit, and A. E. Abdel Moneim, "Protocatechuic acid mitigates cadmium-induced neurotoxicity in rats: role of oxidative stress, inflammation and apoptosis," *Science of The Total Environment*, vol. 723, p. 137969, 2020.
- [42] H. Nohl, L. Gille, and A. V. Kozlov, "Critical aspects of the antioxidant function of coenzyme Q in biomembranes," *Bio-Factors*, vol. 9, no. 2-4, pp. 155–161, 1999.
- [43] L. A. Ramadan, A. R. Abd-Allah, H. A. Aly, and A. A. Saad-El-Din, "Testicular toxicity effects of magnetic field exposure and prophylactic role of coenzyme Q10 and L-carnitine in mice," *Pharmacological Research*, vol. 46, no. 4, pp. 363–370, 2002.
- [44] B. Erol, M. Bozlu, V. Hanci, H. Tokgoz, S. Bektas, and G. Mungan, "Coenzyme Q10 treatment reduces lipid peroxidation, inducible and endothelial nitric oxide synthases, and germ cell-specific apoptosis in a rat model of testicular ischemia/reperfusion injury," *Fertility and Sterility*, vol. 93, no. 1, pp. 280–282, 2010.
- [45] A. A. Fouad, A. I. Al-Sultan, and M. T. Yacoubi, "Coenzyme Q10 counteracts testicular injury induced by sodium arsenite in rats," *European Journal of Pharmacology*, vol. 655, no. 1-3, pp. 91–98, 2011.
- [46] C. M. Palmeira, D. L. Santos, R. Seica, A. J. Moreno, and M. S. Santos, "Enhanced mitochondrial testicular antioxidant capacity in Goto-Kakizaki diabetic rats: role of coenzyme Q," *American Journal of Physiology-Cell Physiology*, vol. 281, no. 3, pp. C1023–C1028, 2001.
- [47] M. Turunen, J. Olsson, and G. Dallner, "Metabolism and function of coenzyme Q," *Biochimica et Biophysica Acta (BBA)-Biomembranes*, vol. 1660, no. 1-2, pp. 171–199, 2004.

- [48] M. Potgieter, E. Pretorius, and M. S. Pepper, "Primary and secondary coenzyme Q10 deficiency: the role of therapeutic supplementation," *Nutrition Reviews*, vol. 71, no. 3, pp. 180–188, 2013.
- [49] A. A. K. El-Sheikh, M. A. Morsy, M. M. Mahmoud, R. A. Rifaai, and A. M. Abdelrahman, "Effect of coenzyme-Q10 on doxorubicin-induced nephrotoxicity in rats," *Advances in Pharmacological Sciences*, vol. 2012, 8 pages, 2012.
- [50] L. Papucci, N. Schiavone, E. Witort et al., "Coenzyme q10 prevents apoptosis by inhibiting mitochondrial depolarization independently of its free radical scavenging property," *Journal of Biological Chemistry*, vol. 278, no. 30, pp. 28220–28228, 2003.
- [51] H. Li, G. Chen, W. Ma, and P.-A. Li, "Water-soluble coenzyme q10 inhibits nuclear translocation of apoptosis inducing factor and cell death caused by mitochondrial complex I inhibition," *International Journal of Molecular Sciences*, vol. 15, no. 8, pp. 13388–13400, 2014.
- [52] J. L. Tarry-Adkins, D. S. Fernandez-Twinn, I. P. Hargreaves et al., "Coenzyme Q10 prevents hepatic fibrosis, inflammation, and oxidative stress in a male rat model of poor maternal nutrition and accelerated postnatal growth¹," *The American Journal of Clinical Nutrition*, vol. 103, no. 2, pp. 579–588, 2016.
- [53] A. E. Khodir, H. Atef, E. Said, H. A. ElKashef, and H. A. Salem, "Implication of Nrf2/HO-1 pathway in the coloprotective effect of coenzyme Q10 against experimentally induced ulcerative colitis," *Inflammopharmacology*, vol. 25, no. 1, pp. 119–135, 2017.
- [54] K. A. Kang and J. W. Hyun, "Oxidative stress, Nrf2, and epigenetic modification contribute to anticancer drug resistance," *Toxicological research*, vol. 33, no. 1, pp. 1–5, 2017.
- [55] A. Loboda, M. Damulewicz, E. Pyza, A. Jozkowicz, and J. Dulak, "Role of Nrf2/HO-1 system in development, oxidative stress response and diseases: an evolutionarily conserved mechanism," *Cellular and Molecular Life Sciences*, vol. 73, no. 17, pp. 3221–3247, 2016.
- [56] Y.-K. J. Zhang, K. C. Wu, and C. D. Klaassen, "Genetic activation of Nrf2 protects against fasting-induced oxidative stress in livers of mice," *PLoS ONE*, vol. 8, no. 3, p. e59122, 2013.
- [57] H. So, H. J. Kim, Y. Kim et al., "Evidence that cisplatin-induced auditory damage is attenuated by downregulation of pro-inflammatory cytokines via Nrf2/HO-1," *Journal of the Association for Research in Otolaryngology*, vol. 9, no. 3, pp. 290–306, 2008.
- [58] J. E. Clark, R. Foresti, P. Sarathchandra, H. Kaur, C. J. Green, and R. Motterlini, "Heme oxygenase-1-derived bilirubin ameliorates postischemic myocardial dysfunction," *American Journal of Physiology-Heart and Circulatory Physiology*, vol. 278, no. 2, pp. H643–H651, 2000.
- [59] L. E. Otterbein and A. M. K. Choi, "Heme oxygenase: colors of defense against cellular stress," *American Journal of Physiology-Lung Cellular and Molecular Physiology*, vol. 279, no. 6, pp. L1029–L1037, 2000.