

# Maggot therapy for calciphylaxis wound debridement complicated by bleeding



Allen F. Shih, AM,<sup>a</sup> Alicia J. Little, MD, PhD,<sup>a,b</sup> Gauri Panse, MD,<sup>b,d</sup> Junjie Liu, MD, PhD,<sup>c</sup> Gloria Yiu, MD, MPH,<sup>c</sup> H. Klar Yaggi, MD, MPH,<sup>a,c</sup> and Amanda Zubek, MD, PhD<sup>a,b</sup>  
*New Haven, Connecticut*

**Key words:** calciphylaxis; bleeding; debridement; maggot therapy.

## INTRODUCTION

Calciphylaxis is a rare disease with significant morbidity and mortality. Reported 1-year mortality is up to 80%, with sepsis as the leading cause of death.<sup>1</sup> Although most cases occur in end-stage renal disease patients on dialysis, nonuremic cases also occur. Maggot therapy for wound debridement in calciphylaxis has been reported, but the literature is limited.

## CASE REPORT

A 35-year-old morbidly obese woman with alcohol use disorder was admitted for decreased urine output and anasarca caused by presumed alcoholic cirrhosis. On admission, laboratory values showed acute kidney injury (creatinine, 2.9; baseline, 1.1; normal, 0.5-1.2 mg/dL) and liver dysfunction with Model for End-Stage Liver Disease (MELD) score of 32 (estimated 52.6% 3-month mortality rate). Shock, transfer to the medical intensive care unit, and initiation of hemodialysis, vasopressors, and broad-spectrum antibiotics complicated her hospital course. Three weeks into hospitalization, she was weaned off vasopressors and was found to have purpuric plaques on the bilateral lower extremities.

Physical examination of the bilateral, lateral, and medial thighs found greater than 20-cm retiform purpuric plaques with central necrotic eschar and surrounding indurated stellate red-brown plaques (Fig 1). A very firm hyperpigmented plaque with overlying peau d'orange appeared on the abdomen. Laboratory values showed normal calcium (hypo-albuminemia corrected, 10.0; normal, 8.8-10.2 mg/dL) and parathyroid hormone (61.1, normal, 10-69 pg/mL), and low phosphorus (2.0, normal, 2.5-4.5 mg/dL). Excisional biopsy showed

### Abbreviation used:

STS: sodium thiosulfate

foci of calcification within small vessels and between adipocytes with fat necrosis, consistent with calciphylaxis (Fig 2).

Treatment with intravenous sodium thiosulfate (STS) was initiated and titrated to 25 g/d. She also received vitamin K, pentoxifylline, and 1 dose of zoledronic acid. Given the patient's extensive disease, young age, and persistence of necrotic eschars despite conventional wound care, medical maggot therapy was initiated for wound debridement. Approximately 1500 pathogen-free maggot larvae were applied to the right lateral thigh and enclosed with mesh for containment. They began debriding the necrotic tissue (Video). Although debridement had been planned for 48 to 72 hours, serosanguinous oozing occurred, and maggots were removed after 24 hours. Despite early treatment cessation, the right thigh showed debridement including a 3-cm-deep concavity and palpably hollowed eschar (Fig 3).

Two days after discontinuing maggot therapy, the patient suffered massive hemorrhage from a site of debridement on the right lateral thigh, which resolved with pressure and suture ligation. Eight units of blood were transfused for hemorrhagic shock, and subcutaneous heparin was discontinued. The patient bled intermittently from deep wounds on both the maggot-treated and untreated thighs. Bleeding was controlled with pressure dressings and did not require volume resuscitation. Over the next 3 weeks, treatment with STS, vitamin K, and

From Yale School of Medicine<sup>a</sup> and the Departments of Dermatology,<sup>b</sup> Medicine,<sup>c</sup> and Pathology,<sup>d</sup> Yale University School of Medicine.

Funding sources: None.

Conflicts of interest: None declared.

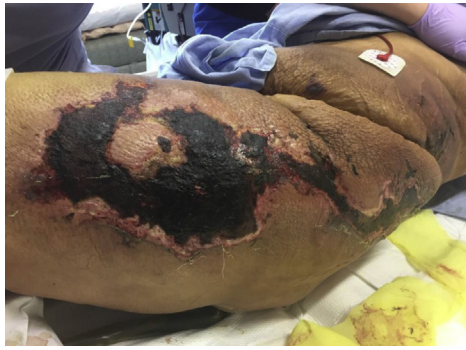Correspondence to: Amanda Zubek, MD, PhD, FAAD, 333 Cedar Street, PO Box 208059, New Haven, CT 06520. E-mail: [amanda.zubek@yale.edu](mailto:amanda.zubek@yale.edu).

JAAD Case Reports 2018;4:396-8.

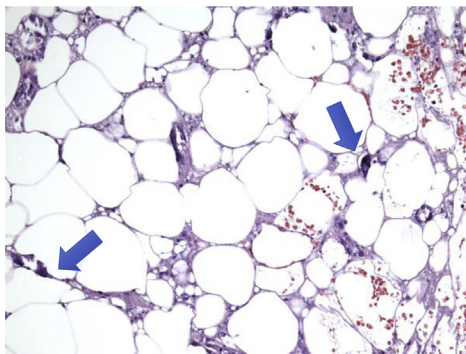
2352-5126

© 2018 by the American Academy of Dermatology, Inc. Published by Elsevier, Inc. This is an open access article under the CC BY-NC-ND license (<http://creativecommons.org/licenses/by-nc-nd/4.0/>).

<https://doi.org/10.1016/j.jdc.2018.01.011>



**Fig 1.** Greater than 20 cm retiform purpuric plaques with central necrotic eschar and surrounding indurated stellate red-brown plaques with peau d'orange on the left thigh.



**Fig 2.** Excisional biopsy from the left thigh shows calcium deposits (blue arrows) in blood vessels and between adipocytes consistent with calciphylaxis. (Hematoxylin-eosin stain; original magnification:  $\times 200$ .)

pentoxifylline was continued, and the patient's skin improved clinically. No new lesions developed, and existing indurated plaques softened. Renal function recovered, and hemodialysis was discontinued. Four weeks after maggot therapy, placement of a percutaneous gastrostomy tube to optimize nutrition was complicated by pneumoperitoneum and septic shock, and the patient died.

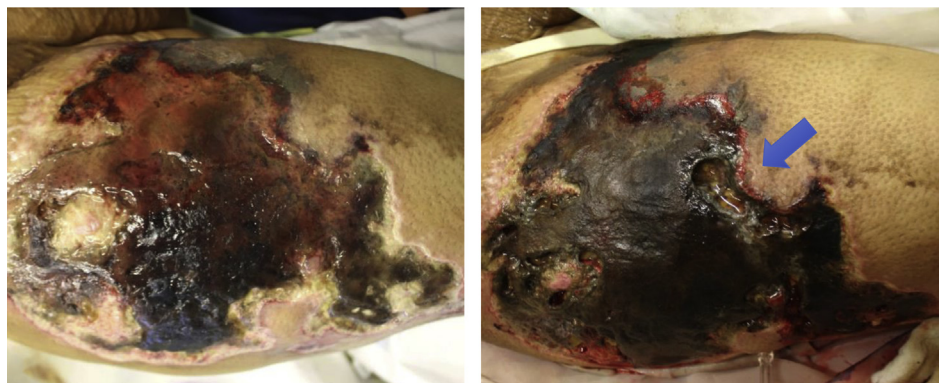
## DISCUSSION

Calciphylaxis is associated with several conditions.<sup>1</sup> Our patient's calciphylaxis risk factors included obesity, alcoholic liver disease, hypoalbuminemia, and being a white woman. Although no standardized or US Food and Drug Administration–approved calciphylaxis treatments exist, reported therapies include intravenous or intralesional STS, hyperbaric oxygen, pentoxifylline, low-dose tissue plasminogen activator, bisphosphonates, vitamin K, and debridement.<sup>1</sup> After extensive discussion of the risks and benefits with the patient, we conducted the first use of maggot therapy debridement at our institution.

Maggot therapy involves the application of live, pathogen-free green bottle fly (*Lucilia sericata*) larvae to debride wounds. Although maggots were used during the Civil War, clinical trials began in 1990.<sup>2</sup> Currently, maggot therapy is US Food and Drug Administration regulated and used primarily for diabetic and pressure ulcers.<sup>3</sup> Applied at 10/cm<sup>2</sup> for up to 72 hours, the larvae liquefy and ingest 15 g/d of necrotic tissue, expanding 4 to 5 times in the process. As such, excessive pressure and occlusive dressings that restrict oxygen flow should be avoided.<sup>2</sup> Maggots can decrease wound size an average of 4.1 cm and 33% by 4 weeks.<sup>4</sup> Although trials are limited, 3 randomized and 5 nonrandomized studies found that maggot therapy is significantly more effective than hydrogels and hydrocolloid for ulcer debridement.<sup>5</sup>

Benefits of maggot therapy include debridement, disinfection, enhanced wound healing, avoidance of surgical complications, and lower costs than surgical debridement.<sup>3</sup> Larvae-secreted enzymes including trypsin and carboxypeptidase liquefy necrotic tissue, whereas antibacterial treatments such as phenylacetyl aldehyde kill bacteria.<sup>6</sup> Along with these secretions, maggots' physical movements stimulate granulation tissue. Maggot therapy preserves healthy tissue while minimizing risks of infection and calciphylaxis propagation during surgical debridement.<sup>1</sup> Surgical debridement in calciphylaxis is controversial. One retrospective study found improved survival in patients undergoing surgical debridement; however, uncontrolled differences in disease severity and selection for patients with limited disease may have affected results.<sup>7</sup> Another case reported calciphylaxis worsening after surgery.<sup>8</sup> Chemical rather than surgical debridement may be preferable for noninfected, stable calciphylaxis lesions with dry eschar.<sup>1</sup>

Reported risks of maggot therapy include discomfort, pain, maggot migration, and bleeding. Although generally well tolerated, it can produce itching sensations and pain, particularly as the maggots enlarge and debride toward living tissue.<sup>9</sup> Maggots migrate in up to 10% of applications, but only after completing feeding or consuming all necrotic tissue. Bleeding occurs in less than 1% of applications, but bleeding risk increases with proximity to larger-caliber blood vessels and pharmacologic anticoagulation.<sup>10</sup> In a case series of 41 patients, 3 of 4 patients who experienced bleeding were on anticoagulant or antiplatelet therapy.<sup>10</sup> In our case, the patient experienced tickling sensations and moderate pain after 1 day of maggot therapy. Her treatment was complicated by hemorrhagic shock from blood loss in maggot-treated



**Fig 3.** The right lateral thigh before (*left*) and after 24 hours of maggot therapy (*right*), showing a 3-cm-deep concavity (*blue arrow*) and palpably hollowed eschar.

areas, but she also had episodes of bleeding at untreated sites, suggesting multiple factors behind the bleeding propensity.

### CONCLUSION

We describe a case of calciphylaxis treated with maggot therapy, a first at our institution. Although therapy was ended after only 24 hours because of bleeding, noticeable debridement was achieved. Manual placement of maggots into enclosed mesh and removal were extremely time intensive. Future use of self-contained application bags may facilitate ease of use. Our case highlights the risk of hemorrhagic complications, although reportedly rare, and the potential of maggots to effectively debride necrotic tissue.

### REFERENCES

1. Nigwekar SU, Kroshinsky D, Nazarian RM, et al. Calciphylaxis: Risk factors, diagnosis, and treatment. *Am J Kidney Dis*. 2015; 66(1):133-146.
2. Chan DCW, Fong DHF, Leung JYY, Patil NG, Leung GKK. Maggot debridement therapy in chronic wound care. *Hong Kong Med J*. 2007;13(5):382-386.
3. Sherman RA. Mechanisms of maggot-induced wound healing: what do we know, and where do we go from here? *Evid Based Complement Alternat Med*. 2014;2014:592419.
4. Munir T, Malik MF, Hashim M, Qureshi MA, Naseem S. Therapeutic applications of blowfly maggots: a review. *J Entomol Zool Stud*. 2016;4(5):33-36.
5. Zarchi K, Jemec GBE. The efficacy of maggot debridement therapy—a review of comparative clinical trials. *Int Wound J*. 2012;9(5):469-477.
6. Tittelbach J, Graefe T, Wollina U. Painful ulcers in calciphylaxis - combined treatment with maggot therapy and oral pentoxifyllin. *J Dermatolog Treat*. 2001;12(4):211-214.
7. McCarthy JT, el-Azhary RA, Patzelt MT, et al. Survival, risk factors, and effect of treatment in 101 patients with calciphylaxis. *Mayo Clin Proc*. 2016;91(10):1384-1394.
8. Sato T, Ichioka S. How should we manage multiple skin ulcers associated with calciphylaxis? *J Dermatol* 2012;39(11):966-968.
9. Mumcuoglu KY. Clinical applications for maggots in wound care. *Am J Clin Dermatol*. 2001;2(4):219-227.
10. Steenvoorde P, van Doorn LP. Maggot debridement therapy: serious bleeding can occur: report of a case. *J Wound Ostomy Continence Nurs*. 2008;35(4):412-414.