

Discordance between clinical, physiological, and radiological measures in cystic fibrosis

Peter J. Barry¹ & Alex R. Horsley^{1,2}

¹Manchester Adult Cystic Fibrosis Centre, University Hospital of South Manchester, Wythenshawe, UK

²Institute of Inflammation and Repair, Education and Research Centre, University of Manchester, University Hospital of South Manchester, Manchester, UK

Keywords

Computerized tomography, cystic fibrosis, exercise testing, physiology, spirometry.

Correspondence

Alex R. Horsley, Manchester Adult Cystic Fibrosis Centre, University Hospital of South Manchester, University of Manchester, Manchester M23 9LT, UK.

E-mail: alexander.horsley@manchester.ac.uk

Received: 24 June 2014; Revised: 23 July 2014; Accepted: 24 July 2014

Respirology Case Reports 2014; 2(4): 129–131

doi: 10.1002/rccr.2.69

Abstract

There are several methods available to the clinician to assess severity of lung disease in cystic fibrosis (CF). Here we present a case where several of these modalities appeared to be discordant. As in this case, many assessments of respiratory status may be necessary to fully evaluate patients with CF. Spirometry may be insensitive to significant changes that are apparent both clinically and radiologically, but remains an important marker of short-term change, response to intervention, and prognosis. Chest computed tomography can provide valuable detailed information on the health of the lungs and is more sensitive than spirometry to the changes seen in CF. Longitudinal studies of subjects with disproportionately severe radiological changes may be important to assess whether they are more at risk of precipitous declines in pulmonary function.

Introduction

Cystic fibrosis (CF) is a complex inherited multisystem condition in which pulmonary manifestations are responsible for the majority of morbidity and mortality. Lung disease in CF is characterized as an obstructive airways disease, with co-existent pathological changes of bronchiectasis, mucus plugging, and airway inflammation. As outlined in the accompanying review of respiratory physiology in CF, there are currently several methods available to the clinician to assess the severity of lung disease [1]. On occasion, these measures may be discordant and the assimilation of these measures is essential to effective management and prognostication for each individual.

This case report is an illustration of an invited review available in *Respirology*: <http://dx.doi.org/10.1111/resp.12382>. Horsley AR, Siddiqui S. Respiratory disease and respiratory physiology: putting function into perspective. Cystic fibrosis in Adults, *Respirology*, 2014, doi: 10.1111/resp.12382.

Case Report

We report the case of a 20-year-old gentleman with CF who transitioned to adult services at the age of 18. He was homozygous for the common F508del mutation and his condition was characterized by pancreatic insufficiency, CF-related diabetes, and colonization with *Mycobacterium abscessus* for 3 years. Importantly, he had what appeared to be mild lung disease, with a forced expiratory volume in 1 s (FEV₁) of 86% predicted.

Over the course of 12 months, a number of discrepancies between his clinical presentation and the degree of his respiratory impairment as assessed by spirometry were noted:

1. He transitioned to adult services on supplemental nocturnal oxygen after identification of nocturnal hypoxia in pediatrics.
2. Moderately severe bronchiectatic changes were visualized on chest X-ray.
3. He required four courses of intravenous antibiotics for pulmonary exacerbations over the course of his first year

in adult services, without the identification of any new pathogens.

Full lung function measures were notable for well-preserved FEV₁ and forced vital capacity (FVC) (86% and

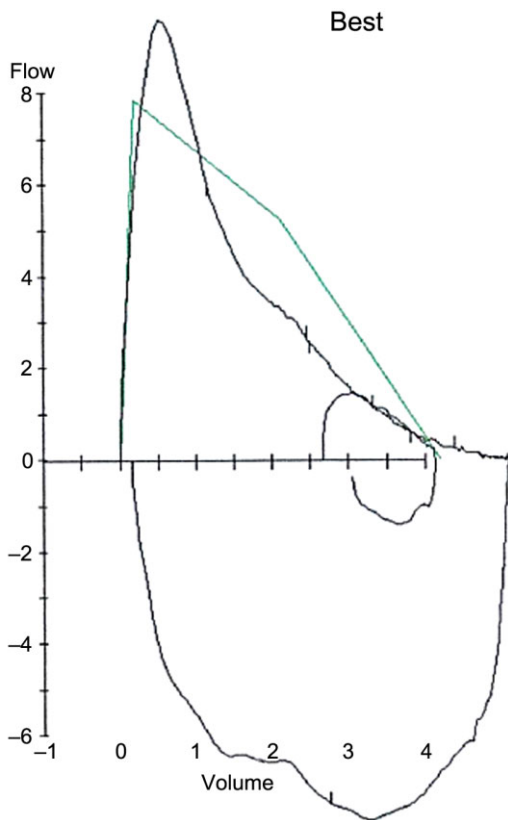


Figure 1. Flow volume loop revealing expiratory flow limitation on forced expiratory maneuver and a tidal breath. Normative curve is shown in green.

98% predicted respectively). His flow volume loop however revealed marked scalloping of the expiratory limb (see Fig. 1), without significant bronchodilator reversibility. Gas diffusion coefficient was normal, but a 1 liter (L) discrepancy was noted in total lung capacity (6.58 L vs. 7.50 L, 122% vs. 139% predicted) and functional residual capacity when comparing plethysmography to dilutional methods, suggesting both hyperinflation and air trapping.

High-resolution computed tomography (CT) revealed extensive bilateral bronchiectasis, with slight upper lobe predominance, and severe patchy air trapping indicative of widespread small airways obstruction (see Fig. 2A and B). The degree of bronchiectasis was in excess of what was anticipated from the spirometric measurements.

Overnight oximetry was performed to assess oxygenation and confirmed good nocturnal oxygenation with no evidence of episodic desaturation or hypoventilation. Inspiratory and expiratory muscle pressures were also normal and supplemental oxygen was discontinued.

A transthoracic echocardiogram was normal and formal exercise testing revealed the patient to have a depressed maximal oxygen consumption (VO₂max) (66% predicted). Marked exercise-induced oxygen desaturation from 98% to 79% was also observed. Nonetheless, he achieved a work rate of 72% predicted, and the exercise test was limited by discomfort with the mouthpiece rather than dyspnea. This relatively preserved performance from a workload viewpoint correlates well with the functional status of the patient who did not report difficulty in sporting endeavors.

Discussion

This clinical scenario identifies the complexities of combining discordant results and clinical presentations. The challenge in cases such as these is the ability to recognize when assessments may be falsely reassuring and also to effectively

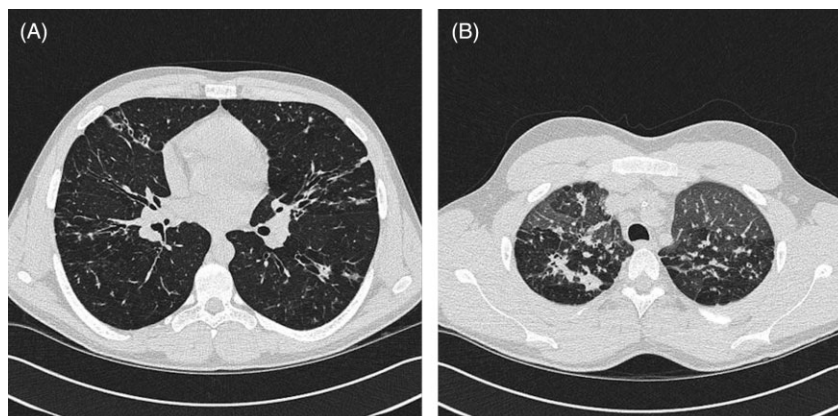


Figure 2. (A) Representative images from a computed tomography (CT) thorax of the cystic fibrosis patient, revealing significant bronchiectatic changes. (B) Expiratory images from CT thorax, revealing a mosaic pattern consistent with air trapping.

prognosticate for such individuals, particularly when the conventional prognostic markers (FEV₁ and VO₂max) are discordant [2, 3].

There are a number of potential sources of such discrepancies. The first of these relates to the use of normative parameters for lung function. As with any normal distribution, 2.5% of the population will have spirometric measures that are significantly above the mean. This patient's "preserved" FEV₁ may in fact represent a significant reduction from what would have been his destined peak lung function in the absence of lung disease. This may account for the apparent discrepancy between the percent predicted FEV₁ and VO₂max.

Second, as discussed in the accompanying review article, FEV₁ may be insensitive to significant pathological parenchymal damage in the context of CF, and other techniques such as lung clearance index (LCI) may better characterize the degree of physiological impairment [1]. The greater sensitivity of LCI to early airway disease makes it a potentially powerful tool for monitoring such patients, although detailed longitudinal studies need to be performed before its role can be clearly defined. In this case, mycobacterial infection precluded LCI testing in our center.

The radiological finding of severe bronchiectasis is consistent with the clinical observation of recurrent exacerbations. CT-based bronchiectasis scores may be superior indicators of pulmonary exacerbation rate than spirometric values [4]. High-resolution CT has also been shown to decline at an accelerated rate in comparison to spirometric measures [5]. Thus, we may be identifying deterioration radiologically which either pre-dates a decline in spirometry or which identifies different disease processes – a factor that may also explain the exercise-induced oxygen desaturation.

This case illustrates that no single marker is sufficiently powerful to completely phenotype patients and that different measures should be seen as complementary in characterizing respiratory disease in CF. Spirometry may be insensitive to significant disease that is clinically apparent, and physicians should be cautious of complacency when spirometry is well-preserved. Despite this, spirometry remains a useful monitoring tool and is also the most vali-

dated prognostic marker in CF. However, other assessments such as CT, LCI, or exercise testing may be beneficial in those patients who display clinical discordance from their spirometric findings. Longitudinal studies of subjects with disproportionate radiological change or exercise testing results may be important to assess whether they are more at risk of precipitous declines in pulmonary function or increased mortality.

Disclosure Statements

No conflict of interest declared.

Appropriate written informed consent was obtained for publication of this case report and accompanying images.

Acknowledgments

Dr. Horsley is funded by a National Institute for Health Research Clinician Scientist Award (NIHR CS012-13). The views expressed are those of the authors and not necessarily those of the United Kingdom National Health System (NHS), the NIHR, or the Department of Health.

References

1. Horsley AR, and Siddiqui S. 2014. Respiratory disease and respiratory physiology: putting function into perspective. Cystic fibrosis in adults. *Respirology*. doi: 10.1111/resp.12382; [Epub ahead of print].
2. Liou TG, Adler FR, Fitzsimmons SC, et al. 2001. Predictive 5-year survivorship model of cystic fibrosis. *Am. J. Epidemiol.* 153(4):345–352.
3. Nixon PA, Orenstein DM, Kelsey SF, and Doershuk CF. 1992. The prognostic value of exercise testing in patients with cystic fibrosis. *N. Engl. J. Med.* 327(25):1785–1788.
4. Brody AS, Sucharew H, Campbell JD, et al. 2005. Computed tomography correlates with pulmonary exacerbations in children with cystic fibrosis. *Am. J. Respir. Crit. Care Med.* 172(9):1128–1132.
5. Judge EP, Dodd JD, Masterson JB, et al. 2006. Pulmonary abnormalities on high-resolution CT demonstrate more rapid decline than FEV1 in adults with cystic fibrosis. *Chest* 130(5):1424–1432.