



The Brazilian Journal of INFECTIOUS DISEASES

www.elsevier.com/locate/bjid



Case report

Catheter-related infection due to *Papiliotrema laurentii* in an oncologic patient: Case report and systematic review



Marcos Rech Londero ^a, Crisley Dossin Zanrosso ^a, Leandro Luis Corso ^b,
Lessandra Michelin ^b, Jonathan Soldera ^{b,*}

^a Hospital Virvi Ramos (HVR), Internal Medicine, Caxias do Sul, RS, Brazil

^b Universidade de Caxias do Sul (UCS), Caxias do Sul, RS, Brazil

ARTICLE INFO

Article history:

Received 2 June 2019

Accepted 20 October 2019

Available online 16 November 2019

Keywords:

Cryptococcus

Papiliotrema

Catheter-related infections

Amphotericin B

Stomach neoplasms.

ABSTRACT

Background: *Papiliotrema laurentii* is one of several non-neoformans cryptococci that have rarely been associated with human infection, since it was previously considered saprophyte and thought to be non-pathogenic to humans. Nevertheless, increasing number of reports of human infection have emerged in recent years, mostly in oncologic patients.

Aim: To report a case of a female patient with pyloric obstructive cancer with a catheter-related *Papiliotrema laurentii* blood stream infection and systematically review the available evidence on *P. laurentii* infection in humans.

Methods: Retrieval of studies was based on Medical Subject Headings and Health Sciences Descriptors, which were combined using Boolean operators. Searches were run on the electronic databases Scopus, Web of Science, MEDLINE (PubMed), BIREME (Biblioteca Regional de Medicina), LILACS (Latin American and Caribbean Health Sciences Literature), Cochrane Library for Systematic Reviews and Opengray.eu. There was no language or date of publication restrictions. The reference lists of the studies retrieved were searched manually.

Results: The search strategy retrieved 1703 references. In the final analysis, 31 references were included, with the description of 35 cases. Every patient but one had a previous co-morbidity - 48.4 % of patients had a neoplasm. Amphotericin B was the most used treatment and only a single case of resistance to it was reported. Most patients were cured of the infection.

Conclusion: *P. laurentii* infection in humans is usually associated to neoplasia and multiple co-morbidities, and amphotericin B seems to be a reliable agent for treatment.

© 2019 Sociedade Brasileira de Infectologia. Published by Elsevier España, S.L.U. This is an open access article under the CC BY-NC-ND license (<http://creativecommons.org/licenses/by-nc-nd/4.0/>).

* Corresponding author at: School of Medicine, Universidade de Caxias do Sul (UCS), Av. Vereador Mário Pezzi, 699/601, Caxias do Sul 95084-180, Brazil.

E-mail address: jonathansoldera@gmail.com (J. Soldera).

<https://doi.org/10.1016/j.bjid.2019.10.005>

1413-8670/© 2019 Sociedade Brasileira de Infectologia. Published by Elsevier España, S.L.U. This is an open access article under the CC BY-NC-ND license (<http://creativecommons.org/licenses/by-nc-nd/4.0/>).

Introduction

The advancement of Medicine brought new medications, therapeutics, invasive diagnostic methods and surgical approaches have in different pathologies. However, new obstacles emerge to defy our scientific knowledge. Rare pathogens until then unknown take advantage of health fragility in humans to cause infections with alarming proportions.

Cryptococcus spp. other than *C. neoformans* and *C. gattii* were previously considered to be saprophytes and non-pathogenic to humans; however, opportunistic infections associated with rare *Cryptococcus spp.*, such as *Cryptococcus laurentii* and *Cryptococcus albidus*, have increased over the past four decades.¹ *Cryptococcus laurentii* belongs to the phylum basidiomycota of the fungi and is an encapsulated saprobic yeast and can be widely isolated from various types of environments.² It is widely distributed throughout the world, including the Caribbean, Antarctic and the Himalayas and can be acquired from air, water, wood, soil, pigeon excrements as well as various foods, such as cheese, fruit, pork products, bean, and wine.³ Since 2015, the species name *Cryptococcus laurentii* was replaced by *Papiliotrema laurentii*. This nomenclature was based on phylogenetic analyses based on the sequencing of seven genes and regions such as ITS rRNA gene, the D1/D2 domains of the large subunit (LSU or 26S) rRNA gene, the small subunit (SSU or 18S) rRNA gene, two subunits of RNA polymerase II (RPB1 and RPB2), translation elongation factor 1- α (TEF1) and cytochrome b (CYTB).

With increasing immunosuppression due to antineoplastic therapy, organ transplantation, catheter insertion, dialysis and other invasive diagnostic and therapeutic procedures, systemic fungal infections are observed more frequently.⁴ Non-*neoformans* cryptococci have been reported to cause infection in many organs. The bloodstream and central nervous system are the most common sites of non-*neoformans* cryptococcal infection.⁵ Due to the rarity of cases involving *P. laurentii*, a standard treatment has not yet been established. Commonly, amphotericin B with flucytosine is recommended.⁶

The aim of this paper was to report a case of a female patient with pyloric obstructive cancer with catheter-related *Papiliotrema laurentii* bloodstream infection and systematically review the available evidence on *P. laurentii* infection in humans.

Case report

A 68-year old female patient, previously diagnosed with type 2 diabetes, arterial hypertension, non-alcoholic fatty liver disease, with a previous history of breast cancer which was treated with radical mastectomy, radiotherapy and chemotherapy a decade ago, sought care due to weight loss (20 % of total body mass - over 40 pounds), incoercible vomiting, weakness, hypoglycemia and upper abdominal pain.

She was admitted to the hospital for investigation. CAT-scan showed gastric distension. Upper digestive endoscopy showed submucosal obstructive pyloric malignancy (Fig. 1), but superficial biopsies came back negative for cancer.

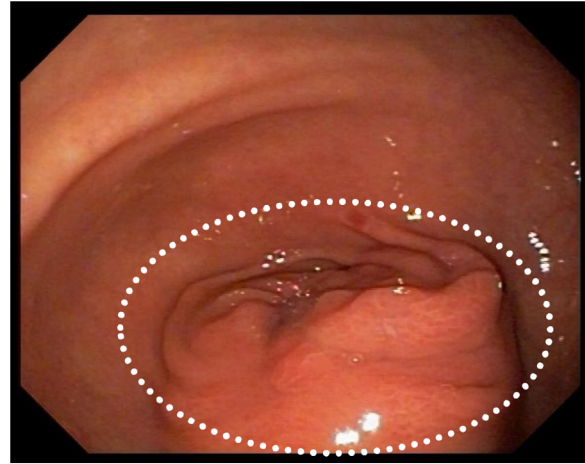


Fig. 1 – Infiltrative submucosal gastric neoplasm in the pylorus (circle).

Colonoscopy was incomplete due to inadequate colonic preparation - the patient vomited manitol. Magnetic resonance showed a pyloric-duodenal mass, suggestive of submucosal pyloric cancer. A two-week parenteral nutrition (PN) was initiated with the purpose of improving nutrition prior to surgery. Patient gained five pounds while on PN. In the 12th day of PN, the patient began to present fever. Blood cultures were drawn and ampicillin-sulbactam was initiated with little response.

Five days thereafter, the patient presented with bacteremia. Catheter and peripheral cultures drawn during fever came back positive for *Papiliotrema laurentii*, with antifungigram pending. Identification of the isolate was performed on the Vitek 2 (YST card - BioMérieux, Marcy l'Etoile, France) automated identification system, which reported *P. laurentii*. The concern regarding misdiagnosis by Vitek systems was minimized since the *P. laurentii* culture had been sent to two different laboratories and regrown for the antifungigram, which confirmed the first and second *P. laurentii* diagnosis with the same resistance profile. The isolate sent to the second lab was again identified by the same Vitek 2 (BioMérieux, Marcy l'Etoile, France) yeast identification card with testing staff blinded to previous Vitek 2 and antifungigram results. Xiao et al. cited that compared to the gold standard (identification of ITS- internal transcribed spacer), Vitek 2 can correctly identify 81.0% of *P. laurentii* isolates.⁷ Fluconazole, piperacillin-tazobactam and vancomycin replaced ampicillin-sulbactam and the site of the catheter was switched. In five days, fever subdued and after 5-day negative control blood cultures, partial gastrectomy with Y-en-Roux gastroenteric anastomosis was performed (Fig. 2). With an adequate evolution, patient began to eat orally and PN was reduced gradually.

Five days after surgery, fever was again noted and catheter and peripheral cultures were positive for *P. laurentii* and *Candida parapsilosis*. The first was susceptible to flucytosine (intermediary), fluconazole, amphotericin B, voriconazole, and resistant to micafungin and caspofungin. The latter was susceptible to flucytosine, fluconazole, amphotericin B, voriconazole, micafungin and caspofungin. Transesophageal echocardiogram was negative for infective endocarditis.



Fig. 2 – Surgical resection of neoplasm (circle).

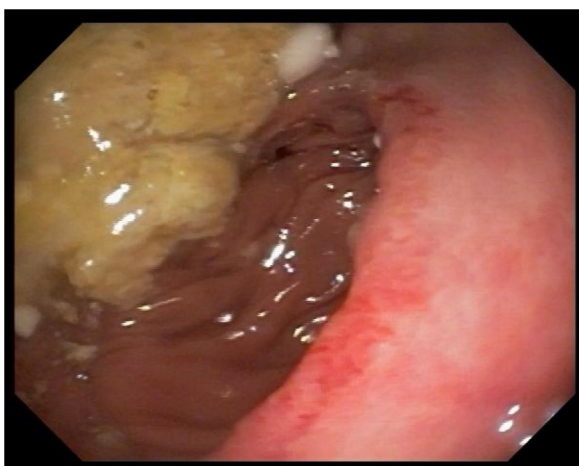

Fig. 3 – Post-operative control: gastroenteric anastomosis with no lesion or gastric food residue.

Vancomycin and piperacillin-tazobactam were already finished and patient was on monotherapy with fluconazole 800 mg once a day. Catheter site was switched again and amphotericin B 50 mg once a day was associated, with resolution of fever. After 14 days of combined therapy and negative peripheral cultures, patient was discharged with a dosage of 800 mg oral fluconazole daily. A post-operative control CAT-scan and an upper digestive endoscopy were performed, showing no signs of recurrence of the neoplasm (Fig. 3).

Materials and methods

This study was carried out in accordance with the recommendations contained in the Preferred Reporting Items for Systematic Reviews and Meta-Analysis (PRISMA-P) guidelines.⁸ Our systematic review was registered with the International Prospective Register of Systematic Reviews (PROSPERO), maintained by York University, on 14 January 2019 [registration No. CRD42019122125 (www.crd.york.ac.uk/prospero/)].

Data sources

Studies were retrieved using the term “*Cryptococcus laurentii*”. Searches were run on the electronic databases Scopus, Web of Science, Medline (PubMed), BIREME (Biblioteca Regional de Medicina), LILACS (Latin American and Caribbean Health Sci-

ences Literature), Cochrane Library for Systematic Reviews and Opengray.eu. There was no language or date of publication restrictions. The reference lists of the retrieved studies were submitted to manual search. Databases were searched January 2019.

Inclusion criteria and outcomes

Case report or case series studies were eligible for selection. If there was more than one study published using the same case, the most recent study was selected for analysis. Studies published only as abstracts were included, as long as the data available made data collection possible. The outcome measured was cure of the infection or death.

Study selection and data extraction

An initial screening of titles and abstracts was the first stage to select potentially relevant papers. The second step was the analysis of the full-length papers. Two independent reviewers extracted data using a standardized data extraction form after assessing and reaching consensus on eligible studies. The same reviewers separately assessed each study and extracted data about the characteristics of the subjects and the outcomes measured. A third reviewer was responsible for clearing divergences in study selection and data extraction.

Statistical analysis

Data was summarized using descriptive analysis – frequency and means.

Results

Systematic review

The search strategy retrieved 1703 references, 767 references were excluded because they were duplicates. After analyzing titles and abstracts, 900 references were excluded. Full texts were retrieved for 37 references. In the final analysis, 31 references were included, comprehending 35 cases. Flowchart illustrating the search strategy is shown in Fig. 4. Studies included were either a case report or a case series.

Cases from India, Slovakia, USA and Italy were the most common (19.3 %, 12.9 %, 9.7 % and 9.7 %, respectively). A total of 35 patients were included, corresponding to 17 male and 12 female (the sex of six patients was not informed). Age ranged from a 6-day-old neonate to 88 years old (mean age was 40.3 years). The most common clinical presentation was fever (25 %); 16.1 % were related to catheter infection; 67.7 % had positive blood cultures (54.8 %) or of cerebrospinal fluid (12.9 %).

Only one patient was found to have no previous comorbidity. Twenty-three patients were immunosuppressed (considering both immunologic disorders and/or use of immunosuppressive agents). Neoplasias were described in 48.4 % of the patients.

Resistance profile of *P. laurentii* was reported for most cases; one case showed resistance to fluconazole and flucytosine and another to amphotericin B. Amphotericin B was the first choice

Table 1 – Summary of systematically reviewed reported cases.

Reference	Country	Age	Sex	Clinical Presentation	Site of Infection	Co-morbidities	Immunosuppression	Mycoplasma	Resistance	Treatment	Outcome
Asano ⁹ , 2014	Japan	32	M	Fever	Peritoneal fluid	IgA nephropathy on peritoneal dialysis	Yes	None	Susceptible to amphotericin B, flucytosine, fluconazole and voriconazole	Voriconazole for 3 months	Cured
Averbuch ¹⁰ , 2002	Israel	16	M	Fever	Blood culture	Metastatic ganglioneuroblastoma	Yes	Yes	Resistance to fluconazole and 5-fluorocytosine	Amphotericin B for 3 weeks	Cured
Banerjee ¹¹ , 2013	India	76	M	Fever, shortness of breath, heart failure	Blood culture	Arterial hypertension, coronary artery disease, previous hemorrhagic stroke	None	None	Susceptible to fluconazole, amphotericin B, voriconazole. Resistance to flucytosine	Amphotericin B for 2 weeks followed by fluconazole for 2 weeks	Cured
Bauters ¹² , 2001	Belgium	45	M	Fever	Oropharynx	Erythroleukaemia	Yes	Yes	NR	Amphotericin B for 18 days	Death
Bhat ² , 2016	India	26	F	Diarrhea	Enteritis	Hodgkin's lymphoma who underwent autologous hematopoietic stem cell transplant	Yes	Yes	Susceptible to amphotericin B, fluconazole, voriconazole, and 5 flucytosine	Voriconazole for 4 weeks	Cured
Calista ¹³ , 2015	Italy	74	M	Diarrhea and neutropenia	Enteritis	Hepatitis B, colorectal cancer on chemotherapy	Yes	Yes	None	Amphotericin B for 10 days	Cured
Cheng ¹⁴ , 2015	Taiwan	88	F	Fever, neutropenia and abdominal pain	Urine and blood culture	Diffuse large B cell lymphoma on chemotherapy	Yes	Yes	NR	Amphotericin B and flucytosine for 2 weeks	Cured

– Table 1 (Continued)

Reference	Country	Age	Sex	Clinical Presentation	Site of Infection	Co-morbidities	Immunosuppression	Parasitology	Resistance	Treatment	Outcome
Conti ¹⁵ , 2015	Italy	47	F	Fever associated with weakness in the left lower limb	Lungs	Systemic lupus erythematosus and Sjogren Syndrome, treated with cyclosporine A and corticoids	Yes	None	NR	Initially amphotericin B, switched to fluconazole for 8 months due to toxicity	Cured
Ding ¹⁶ , 2018	Malaysia	35	F	Fever, supraclavicular mass	Blood culture	Hodgkin lymphoma	Yes	Yes	NR	Fluconazole for 2 weeks	Cured
Furman-Kuklinska ³ , 2009	Polonia	39	NR	Fever	Blood culture	Type I membranoproliferative glomerulonephritis, previous use of prednisone and cyclophosphamide	Yes	None	Susceptible to amphotericin B, voriconazole, itraconazole and fluconazole	Fluconazole for 3 weeks, switched to itraconazole for 4 weeks due to persistence of fungemia	Cured
Gupta ¹⁷ , 2018	India	6 days	M	Worsening of clinic condition	Blood culture	Premature, low birth weight	None	None	Susceptible to amphotericin B and fluconazole	Amphotericin B for 8 days followed by fluconazole for 24 days	Cured
James ¹⁸ , 2000	Venezuela	69	F	Fever and headache	CNS	HIV-negative idiopathic CD4 deficiency	Yes	None	NR	Amphotericin B followed by fluconazole	Cured
Johnson ¹⁹ , 1997	USA	27	F	Fever and painful cutaneous nodules	Blood culture	Intravenous drug use, pelvic inflammatory disease, infectious endocarditis and bipolar disorder	None	None	NR	Fluconazole for 4 weeks	Cured

– Table 1 (Continued)

Reference	Country	Age	Sex	Clinical Presentation	Site of Infection	Co-morbidities	Immunosuppression	Mycoplasm	Resistance	Treatment	Outcome
Johnson ¹⁹ , 1997	USA	27 days	M	Candiduria, fungus balls in both kidneys	Blood culture	Hypoplastic lungs and bilateral hydronephrosis due to posterior urethral valves	None	None	NR	Amphotericin B for 2 weeks	Cured
Kamalam ²⁰ , 1977	India	40	NR	Verrucous nodules around the ankle and left foot	Skin	NR	NR	NR	NR	Potassium iodide for 4 months, switched to amphotericin B due to iodism	Cured
Khawcharoenporn ⁵ , 2006	Thailand	35	M	Fever, headache	Blood culture and CNS	HIV	Yes	None	NR	Amphotericin B for 14 days followed by fluconazole for 3 months	Cured
Kordosis ²¹ , 1998	Greece	34	M	Dyspnea, dry cough, weight loss, fever, headache and diplopia	CNS	HIV and Kaposi's sarcoma	Yes	Yes	NR	Amphotericin B and flucytosine for 2 weeks followed by fluconazole as a maintenance therapy	Cured
Krcmery ⁴ , 1997	Slovakia	17	NR	Fever	Blood culture	Leukemia, recent bone marrow transplant	Yes	Yes	NR	Fluconazole for 2 weeks	Cured
Krcmery ²² , 1998	Slovakia	NR	M	Catheter-related	Blood culture	Solid tumor	None	Yes	None	Fluconazole for 10 days	Cured
Krcmery ²² , 1998	Slovakia	NR	M	Catheter-related	Blood culture	Non-Hodgkin lymphoma, corticoids	Yes	Yes	NR	Amphotericin B for 20 days	Death
Kunova ²³ , 1999	Slovakia	NR	NR	Fever, catheter-related	Blood culture	Neutropenia	Yes	Yes	NR	Amphotericin B for 14 days	Cured

- Table 1 (Continued)

Reference	Country	Age	Sex	Clinical Presentation	Site of Infection	Co-morbidities	Immunosuppression	Mycoplasma	Resistance	Treatment	Outcome
Kunova ²³ , 1999	Slovakia	NR	NR	Fever, catheter-related	Blood culture	Neutropenia	Yes	Yes	NR	Fluconazole for 10 days	Cured
Kunova ²³ , 1999	Slovakia	NR	NR	Fever	Blood culture	Neutropenia	Yes	Yes	NR	NR	Death
Lynch ²⁴ , 1980	USA	55	F	Skin rash and proximal muscle weakness	Lungs	Dermatomycosis, chronic use of corticoids	Yes	None	Susceptible to amphotericin B and flucytosine	Amphotericin B for 6 weeks	Cured
Manfredi ²⁵ , 2006	Italy	34	M	Fever and headache	CNS	Intravenous drug user, HIV	Yes	None	Resistance to both amphotericin B and flucytosine	Fluconazole for 46 days	Cured
Martinez ²⁶ , 2016	Mexico	65	M	Skin ulcer	Skin	Cutaneous leishmaniosis	None	None	NR	Itraconazole	Cured
Mittal ²⁷ , 2015	India	30	F	Post-partum, headache and drowsiness	Blood culture	Recent C-section due to fetal distress	None	None	NR	Amphotericin B	Death
Molina-leyva ²⁸ , 2013	Spain	8	F	Skin lesion in the right forearm	Skin	None	None	None	Susceptible to amphotericin B and fluconazole	Fluconazole for 2 weeks	Cured
Neves ⁶ , 2015	Brazil	42	M	Fever episodes, severe abdominal pain, weakness and respiratory distress	Blood culture	Cervical cancer treated with chemotherapy and radiotherapy 1 year prior to the hospitalization	None	Yes	Susceptible to amphotericin B and fluconazole	Fluconazole for 22 weeks	Cured

– Table 1 (Continued)

Reference	Country	Age	Sex	Clinical Presentation	Site of Infection	Co-morbidities	Immunosuppression	Co-plasm	Resistance	Treatment	Outcome
Park ¹ , 2017	Korea	47	F	Fever, erythematous papules	Blood culture	Refractory acute myeloid leukemia after allogenic hematopoietic stem cell transplantation, on chemotherapy	Yes	Yes	NR	Amphotericin B for 3 weeks	Cured
Rodriguez ²⁹ , 2012	Colombia	3 months	M	Bronchiolitis due to adenovirus, catheter-related	Blood culture	Premature baby with down syndrome	None	None	NR	Amphotericin B	Death
Shankar ³⁰ , 2006	India	35	F	Fever, night sweats, pleuritic chest pain and dyspnea	Peritoneal fluid	HIV, diabetes	Yes	None	NR	Fluconazole for 5 weeks	Cured
Simon ³¹ , 2005	Hungary	9	M	Enlarged lymph nodes and hepatosplenomegaly	CNS	x-linked hyper-immunoglobulin M syndrome	Yes	None	Susceptible to amphotericin B and fluconazole	Fluconazole for 9 months with titrating of dosage	Cured
Sinnott ³² , 1989	USA	13	F	Abdominal pain and fever	Peritoneal fluid	Chronic renal failure in peritoneal dialysis	Yes	None	NR	Flucytosine and miconazole, switched to amphotericin B for 2 months	Cured
Vlchкова-Lashkoska ³³ , 2004	Slovakia	51	M	Skin lesion on the back	Skin and CNS	Alcoholism	None	None	Susceptible to amphotericin B and flucytosine	NR	NR

M: Male; F: Female; NR: not reported; HIV: Human Immunodeficiency Virus; CNS: Central nervous system.

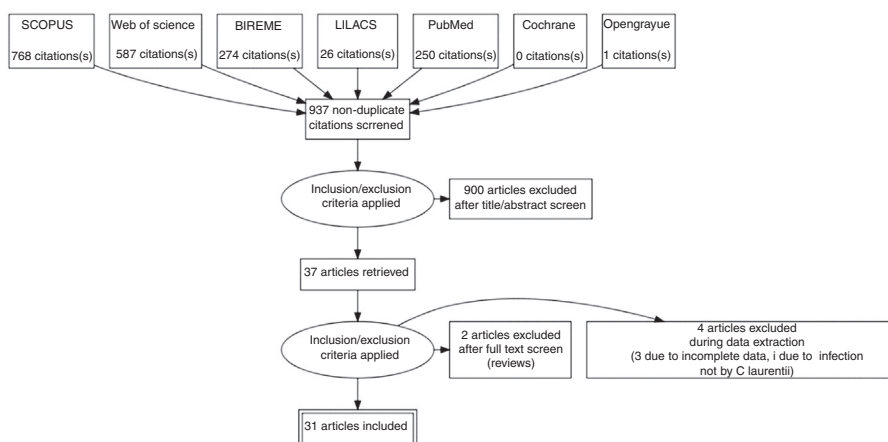


Fig. 4 – Study selection flowchart.

of treatment for 51.6 % of the patients, followed by fluconazole in 35.5 % of the cases. Fluconazole was the choice for maintenance treatment for a longer period. Cure was achieved in 82.8 % of the patients included on this study after proper treatment. These results are summarized in Table 1.

Discussion

P. laurentii has a high degree of interspecies heterogeneity and has been divided into phylogenetic groups I and II. Physiologic and biochemical characteristics of the species in the complex are similar. Nevertheless, the species in phylogenetic group I, such as *Cryptococcus flavescens* and *Cryptococcus aureus*, can be distinguished from phylogenetic group II by their combination of assimilation patterns of D-glucosamine, Nacetyl-D-glucosamine, DL-lactic acid, 1,2-propanediol and sodium nitrite and vitamin requirements.³⁴ *Cryptococcus neoformans* and *P. laurentii* share many common traits and structures – the hemolytic capacity of *P. laurentii* is an intrinsic characteristic that optimizes its infective capacity and increases its growth in blood.³⁵

The likelihood of cryptococcal infection is highly increased in patients with impaired cell-mediated immunity, including lymphoproliferative disorders, HIV infection (CD4 counts < 100 cells/ μ l) and hematologic malignancies.³⁶ Other risk factors are: use of steroid or chemotherapy,³⁷ organ transplantation, impaired humoral immunity such as hyper-IgM syndrome,³⁸ non-HIV lymphopenia,³⁹ invasive devices⁴⁰ and direct or indirect exposures to pigeon excreta.⁴¹ From our analysis, the presence of invasive catheters, immunosuppression and neoplasms were significant risk factors associated to *P. laurentii* infection.

P. laurentii has been reported to cause infections in many organ systems.⁴² The bloodstream and central nervous system were the most common sites of infection, although some other sites such as keratitis⁴³ have been reported. Fever was the most common clinical finding, present in most cases. Choices and duration of treatment for *P. laurentii* infections depended on the anatomical involvement, host-immune status, and severity of infection. Recommendations

regarding treatment for infections are limited, due to the small number of empirically treated cases and the absence of controlled trial data. Amphotericin B alone was used for most treatments, with a high rate of cure (80 %). The most used regimen was an induction period of 14 days followed by maintenance fluconazole, with a cure rate of 75 %. Nonetheless, 10 patients were treated with monotherapy with fluconazole, with a cure rate of 90 %.

A joint clinical guideline published in 2013 by the European Society of Clinical Microbiology and Infectious Diseases Fungal Infection Study Group (ESCMID) and the European Confederation of Medical Mycology (ECMM) for the diagnosis and management of rare invasive yeast infections is the available consensus on how to manage these infections. For *non-neoformans* and *non-gattii* *Cryptococcus* infections it is recommended the use of amphotericin B with or without flucytosine for the induction of CNS and severe infections or fluconazole in a dose over 400 mg daily if demonstrated *in-vitro* sensitivity. For non-CNS and non-severe infections, 400 mg of daily fluconazole can be used for induction and maintenance treatment, reserving amphotericin B for less azole susceptible species. Due to intrinsic resistance, echinocandins are not recommended.⁴⁴

Susceptibility testing was reported for only 13 isolates, including our isolate. One was found to be resistant *in vitro* to amphotericin B and other to fluconazole. Although our isolate was not resistant *in vitro* to fluconazole, monotherapy failed, justifying a switch to amphotericin B followed by maintenance therapy with fluconazole. Clinical correlations between susceptibility testing results and treatment outcome are lacking.¹⁹

The cure rate of the infection was 82.8 %, and the most effective drug was amphotericin B, used in 44.8 % of the cured cases. Although this infection generally occurs in patients with multiple co-morbidities, it does not appear to be very severe, with a high response rate to commonly used therapy for resistant yeast.^{22,45}

A very important concern regarding our reported case must be brought into attention: there is a report of misdiagnosis by Vitek systems, confounding candida species, such as *C. parapsilosis*, with *P. laurentii*.⁷ We do not believe this was the case,

since the culture had to be sent to a different lab and regrown for the antifungigram, which confirmed the first and second *C. laurentii* diagnosis with the same resistance profile and the *C. parapsilosis* diagnosis in a different system.

In conclusion, *P. laurentii*, generally considered a non-infective saprobe, may cause relevant fungemia and other infections, especially in immunocompromised and oncologic patients. Central catheters seem to be a particular risk factor for fungemia with this yeast. The main clinical manifestation is fever, blood cultures are useful for diagnosis, and induction treatment with amphotericin B followed by maintenance fluconazole seems to achieve a significant success rate.

Conflict-of-interest statement

All authors have nothing to disclose.

Author contributions

All authors contributed to study concept and design, and drafting of the manuscript; All authors contributed to acquisition of data, analysis and interpretation of data; Michelin L contributed in revising the final manuscript; Soldera J and Corso LL contributed to statistical analysis; Soldera J contributed to study supervision; all authors contributed to critical revision of the manuscript for important intellectual content.

REFERENCES

- Park SS, Lee H, Park WS, Hwang SH, Choi SI, Choi MH, et al. A case of disseminated infection with skin manifestation due to non-neoformans and non-gattii cryptococcus in a patient with refractory acute myeloid leukemia. *Infect Chemother.* 2017;49:142-5.
- Bhat V, Vira H, Khattry N, Toshniwal M. Cryptococcus laurentii diarrhea post hematopoietic stem cell transplant. *Transpl Infect Dis.* 2017;19:e12663.
- Furman-Kuklinska K, Naumnik B, Mysliwiec M. Fungaemia due to cryptococcus laurentii as a complication of immunosuppressive therapy—a case report. *Adv Med Sci.* 2009;54:116-9.
- Krcmery VJ, Kunova A, Mardiak J. Nosocomial cryptococcus laurentii fungemia in a bone marrow transplant patient after prophylaxis with ketoconazole successfully treated with oral fluconazole. *Infection.* 1997;25:130.
- Khawcharoenporn T, Apisarnthanarax A, Kiratisin P, Mundy LM, Bailey TC. Evaluation of cryptococcus laurentii meningitis in a patient with hiv infection: A case report and review of the literature. *Hawaii Med J.* 2006;65:260-2.
- Neves RP, Lima Neto RG, Leite MC, Silva VK, Santos Fde A, Macedo DP. Cryptococcus laurentii fungaemia in a cervical cancer patient. *Braz J Infect Dis.* 2015;19:660-3.
- Xiao M, Fan X, Chen XX, Wang H, Zhang L, Xu ZP, et al. Misidentification of a Rare Species, *Cryptococcus laurentii*, by Commonly Used Commercial Biochemical Methods and Matrix-Assisted Laser Desorption Ionization-Time of Flight Mass Spectrometry Systems: Challenges for Clinical Mycology Laboratories. *J Clin Microbiol.* 2016;54(1):226-9.
- Shamseer L, Moher D, Clarke M, Ghersi D, Liberati A, Petticrew M, et al. PRISMA-P Group. Preferred reporting items for systematic review and meta-analysis protocols (prisma-p) 2015: Elaboration and explanation. *Bmj.* 2015;350:G7647.
- Asano M, Mizutani M, Nagahara Y, Inagaki K, Kariya T, Masamoto D, et al. Successful treatment of cryptococcus laurentii peritonitis in a patient on peritoneal dialysis. *Intern Med.* 2015;54:941-4.
- Averbuch D, Boekhout T, Falk R, Engelhard D, Shapiro M, Block C, et al. Fungemia in a cancer patient caused by fluconazole-resistant cryptococcus laurentii. *Med Mycol.* 2002;40:479-84.
- Banerjee P, Haider M, Trehan V, Mishra B, Thakur A, Dogra V, et al. Cryptococcus laurentii fungemia Indian. *J Med Microbiol.* 2013;31:75-89.
- Bauters TGM, Swinne D, Boekhout T, Noens L, Nelis HJ. Repeated isolation of cryptococcus laurentii from the oropharynx of an immunocompromized patient. *Mycopathologia.* 2002;153:133-5.
- Calista F, Tomei F, Assalone P, Traficante D, Di Pilla G, Pepe C, et al. Cryptococcus laurentii diarrhea in a neoplastic patient. *Case rep Oncol Med.* 2015;2015:216458.
- Cheng M-W, AY-J Wu, Liu C-P, Lim K-H, Weng S-L, Tseng H-K. Cryptococemia in an elderly woman with retroperitoneal diffuse large b-cell lymphoma after rituximab-containing chemotherapy. *International Journal of Gerontology.* 2016;10:112-6.
- Conti F, Spinelli F, Colafrancesco S, Truglia S, Ceccarelli F, Fattapposta F, et al. Acute longitudinal myelitis following cryptococcus laurentii pneumonia in a patient with systemic lupus erythematosus. *Lupus.* 2015;24:94-7.
- Ding CH, Kamarudin N. Non-neoformans cryptococemia in a patient with hodgkin's lymphoma. *Asian Journal of Pharmaceutical and Clinical Research.* 2018;11:7-8.
- Gupta M, Mishra AK, Singh SK. Cryptococcus laurentii fungemia in a low birth weight preterm neonate: India. *Journal of infection and public health.* 2018;11:896-7.
- James M, Arias A, Roselli E, Tirado M, Eclavarría P. Meningitis por cryptococcus laurentii caso clinico en una paciente con linfopenia cd4 idiopática: reporte de un caso. *Centro Médico.* 2000;45:138-40.
- Johnson LB, Bradley SF, Kauhan CA. Fungaemia due to cryptococcus laurentii and a review of non-neoformans cryptococcaemia. *Mycoses.* 1998;41:277-80.
- Kamalam A, Yesudian P, Thambiah AS. Cutaneous infection by cryptococcus laurentii. *BJD.* 1977;97:221-3.
- Kordossis T, Avlami A, Velegraki A, Stefanou I, Georgakopoulos G, Papalambrou C, et al. First report of cryptococcus laurentii meningitis and a fatal case of cryptococcus albidus cryptococcaemia in aids patients. *Medical Mycology.* 1998;36:335-44.
- Krcmery VJ, Oravcovab E, Spanikc S, Mrazova-Studena M, Truplc J, Kunovac A, et al. Nosocomial breakthrough fungaemia during antifungal prophylaxis or empirical antifungal therapy in 41 cancer patients receiving antineoplastic chemotherapy: Analysis of aetiology risk factors and outcome. *J Antimicrob Chemother.* 1998;41:373-80.
- Kunova A, Krcmery V. Fungaemia due to thermophilic cryptococci: 3 cases of cryptococcus laurentii bloodstream infections in cancer patients receiving antifungals. *Scand J Infect.* 1999;31:328.
- Lynch J, Schaberg D, Kissner D, Kauffman C. Cryptococcus laurentii lung abscess. *Am Rev Resp Dis.* 1981;123:135-43.
- Manfredi R, Fulguro C, Sabbatani S, Legnani G, Fasulo G. Emergence of amphotericin b-resistant cryptococcus laurentii meningoencephalitis shortly after treatment for cryptococcus neoformans meningitis in a patient with aids. *Aids Patient Care STDS.* 2006;20:227-32.

26. Martínez E, Torres-Guerrero E, Cortes E, Tejada D, Arenas R. *Cryptococcus laurentii* infection in a patient with cutaneous leishmaniasis. *Int J Dermatol*. 2017;56:e56-7.
27. Mittal N, Vatsa S, Minz A. Fatal meningitis by *cryptococcus laurentii* in a post-partum woman: A manifestation of immune reconstitution inflammatory syndrome. *Indian J Med Microbiol*. 2015;33:590-3.
28. Molina-Leyva A, Ruiz-Carrascosa JC, Leyva-García A, Husein-Elahmed H. Cutaneous *cryptococcus laurentii* infection in an immunocompetent child. *Int J Infect Dis*. 2013;17, e1232-1233.
29. Rodríguez DA, Pinilla AP. Infección asociada a catéter central por *cryptococcus laurentii* en niño críticamente enfermo: A propósito de un caso y revisión del tema. *Infection*. 2012;16:72-4.
30. Shankar EM, Kumarasamy N, Bella D, Renuka S, Kownhar H, Suniti S, et al. Pneumonia and pleural effusion due to *cryptococcus laurentii* in a clinically proven case of aids. *Can Resp J*. 2006;13:275-8.
31. Simon G, Simon G, Erdos M, Marodi L. Invasive *cryptococcus laurentii* disease in a nine-year-old boy with x-linked hyper-immunoglobulin m syndrome. *Pediatr Infect Dis J*. 2005;24:935-42.
32. Sinnott J, Rodnite J, Emmanuel P, Campos A. *Cryptococcus laurentii* infection complicating peritoneal dialysis. *Ped Infect Dis J*. 1989;8:803-8.
33. Vlchkova-Lashkoska M, Kamberova S, Starova A, Goleva L. Cutaneous *cryptococcus laurentii* infection in a human immunodeficiency virus-negative subject. *J Eur Acad Dermatol Venereol*. 2004;18:99-100.
34. Tashima M, Sugita T, Shinoda T, Nakase T. Three new combinations from the *Cryptococcus laurentii* complex: *Cryptococcus aureus*, *Cryptococcus carnescens* and *Cryptococcus peneaus*. *Int J Syst Evol Microbiol*. 2003;53:1187-94.
35. Ferreira-Paim K, Andrade-Silva L, Mora DJ, Lages-Silva E, Pedrosa AL, da Silva PR, et al. Antifungal susceptibility, enzymatic activity, PCR-fingerprinting and ITS sequencing of environmental *Cryptococcus laurentii* isolates from Uberaba, Minas Gerais, Brazil. *Mycopathologia*. 2012;174(1):41-52.
36. Perfect JR. *Cryptococcus neoformans*. In: Mandell GL, Bennett JE, Dolin R, editors. *Principles and Practice of Infectious Diseases*. New York: Churchill Livingstone; 2005. p. 2997-3009.
37. Perfect JR, Casadevall A. *Cryptococcosis*. *Infect Dis Clin North Am*. 2002;16:837-74.
38. Iseki M, Anzo M, Yamashita N, Matsuo N. Hyper-IgM immunodeficiency with disseminated cryptococcosis. *Acta Paediatr*. 1994;83:780-2.
39. Dev D, Basran GS, Slater D. Consider: HIV negative immunodeficiency in cryptococcosis. *BMJ*. 1994;308:1436.
40. Mocani H, Murphy AV, Beattie TJ, McAllister TA. Fungal peritonitis in children on continuous ambulatory peritoneal dialysis. *Scot Med J*. 1989;34:494-6.
41. da Cunha T, Lusins J. *Cryptococcus albidus* meningitis. *South Med J*. 1973;66:1230.
42. Khawcharoenporn T, Apisarnthanarak A, Mundy LM. Non-neoformans *Cryptococcal* Infections: a Systematic Review. *Infection*. 2007;35:51-8.
43. Ritterband DC, Seedor JA, Shah MK, Waheed S, Schorr I. A unique case of *cryptococcus laurentii* keratitis spread by a rigid gas permeable contact lens in a patient with onychomycosis. *Cornea*. 1998;17(1):115-8.
44. Arendrup MC, Boekhout T, Akova M, Meis JF, Cornely OA, Lortholary O, et al. ESCMID and ECMM joint clinical guidelines for the diagnosis and management of rare invasive yeast infections. *Clin Microbiol Infect*. 2014;20 Suppl 3:76-98.
45. Kovacicova G, Lovaszova M, Hanzen J, Roidova A, Mateicka F, Lesay M, et al. Persistent fungemia – Risk factors And outcome in 40 episodes. *J Chemother*. 2001;13(4):429-33.