



Case report

Clinical manifestation and outcomes of multi-drug resistant (MDR) *Raoultella terrigena* infection – A case series at Indus Health Network, Karachi, Pakistan

Pushpa Bhawan Mal^{a,*}, Samreen Sarfaraz^b, Fivzia Herekar^c, Rakhshinda Ambreen^d

^a Department of Microbiology, The Indus Hospital, Karachi, Pakistan

^b Department of Infectious Disease, The Indus Hospital, Karachi, Pakistan

^c Department of Internal Medicine, The Indus Hospital, Karachi, Pakistan

^d Indus Hospital Research Center, Indus Health Network, Karachi, Pakistan

ARTICLE INFO

Article history:

Received 14 May 2019

Received in revised form 18 August 2019

Accepted 18 August 2019

Keywords:

Raoultella terrigena

Extensively drug resistant

Nosocomial infection

ABSTRACT

Background and objectives: There is paucity of literature available on *Raoultella terrigena* infection. Microbiological identification of *Raoultella terrigena* is difficult and isolates are frequently misidentified as *Klebsiella species*. This series of 3 cases with *Raoultella terrigena* septicemia provides a description of the pitfalls and challenges in the diagnosis and management of the highly resistant strains isolated and to the best of our knowledge, is the first report from Pakistan.

Methods: The medical records of 3 cases of *R. terrigena* reported in the hospital over two months were reviewed retrospectively to record all relevant clinical information. Organism was identified by using Analytical profile index (API) 20 E with 90–95% successful identification and the sensitivity testing was performed by disc diffusion method.

Results: This organism caused fulminant sepsis in case 2 resulting in mortality and complicated urinary tract infection in the third, while in case 1 it preceded the fatal candidemia. All three patients were females who had multiple co-morbid and had a history of protracted hospital stay and antibiotic usage elsewhere before being shifted to our hospital. The isolates were resistant to all beta lactams and were even colistin resistant in two patients, creating challenges and suboptimal response for effective antibiotic therapy.

Conclusions: The purpose of this case series is to highlight the highly drug resistant profile of this organism and the fulminant infection it can cause, which if spreads in our hospitals due to breaches in infection control practices, can pose risk as a deadly and untreatable nosocomial infection.

© 2019 The Authors. Published by Elsevier Ltd. This is an open access article under the CC BY-NC-ND license (<http://creativecommons.org/licenses/by-nc-nd/4.0/>).

Introduction

Raoultella terrigena (formally identified as *Klebsiella terrigena*) are gram-negative, non-motile, facultative anaerobic, encapsulated bacilli belonging to family Enterobacteriaceae and closely linked to genus *Klebsiella* [1]. *Raoultella* includes four species: *Raoultella ornithinolytica*, *Raoultella planticola*, *Raoultella terrigena* and *Raoultella electrica*. They are principally found in water, plants and soil. *Raoultella ornithinolytica* and *Raoultella planticola* are frequently isolated and reported from human samples but *Raoultella terrigena* and *Raoultella electrica* are rarely reported

from clinical samples [2]. There is scanty data available on *R. terrigena* septicemia [3]. Moreover, exact identification of *R. terrigena* is difficult in many clinical microbiology laboratories, and isolates can be simply misidentified as *Klebsiella species* [4]. Up till now, only four case reports with clinically important infections caused by *R. terrigena* have been published. First case was *R. terrigena* infective endocarditis in a forty five year-old liver transplant recipient [5]. In the second case, *R. terrigena* caused sepsis in a sixty nine year-old male who underwent major surgery (Whipple's procedure). Third reported case showed urinary tract infection in a premature newborn caused by *R. terrigena*. (3)The fourth case described a subdural abscess due to *R. terrigena* [6]. The isolates in all these cases were sensitive to multiple antibiotics and easily treatable. No other case reports of infections caused by this organism have been published, and there is limited data about the disease spectrum and pathogenesis caused by this bacteria [7]. Over a period of 2 months (December 2018 to January 2019), three

* Corresponding author at: Department of Microbiology, The Indus Hospital, Plot C-76, Sector 31/5, Opposite Darussalam Society, Korangi Crossing, Karachi, 75190, Pakistan.

E-mail address: pushpa.sajaan@gmail.com (P.B. Mal).

cases of *R. terrigena* infection, with a multidrug resistant profile, were diagnosed and treated at our institute, two of whom expired. The aim of this case series study is to share our experiences of the difficulties encountered in the diagnosis and management of *R. terrigena* infection and to provide a thorough review of the literature.

Case history

Case 1

A thirty years old female with uncontrolled diabetes and history of recurrent miscarriages presented with altered mentation and sepsis. Two months back she had been managed elsewhere for diabetic ketoacidosis and urosepsis. Post discharge she became bed bound with worsening generalized weakness, undocumented intermittent fever, anorexia and mental obtundation with delayed responses and difficulty to recognize family members. She was initially managed as diabetic ketoacidosis with acute kidney injury and septic shock and later diagnosed as having acute motor-sensory axonal neuropathy subtype of Guillain-Barré syndrome for which 5 alternate day sessions of plasmapheresis were conducted with no resulting improvement in lower limb power. Her blood and urine cultures sent on admission reported *Raoultella terrigena* sensitive only to fosfomycin and co-trimoxazole with intermediate zone for tigecycline. She was started on IV fosfomycin, tigecycline and co-trimoxazole as targeted therapy. She temporarily improved, achieved blood culture clearance but subsequently succumbed to candidaemia. Her terminal event was refractory hypocalcemia due to plasmapheresis leading to cardiac arrhythmias and death on her fourteenth day of admission.

Case 2

A sixty three years old female known case of diabetes, hypertension, rheumatoid arthritis and iatrogenic Cushing's syndrome due to steroid self-medication, recently treated for falciparum malaria, became bed bound for eight days due to generalized oedema. She subsequently presented elsewhere with shortness of breath and left lower limb swelling and was diagnosed with deep venous thrombosis leading to saddle shaped pulmonary embolism involving bilateral pulmonary arteries. She was ventilated and underwent cardiac catheterization with tissue plasminogen activator (TPA) for thrombolysis followed by streptokinase infusion. Subsequently the patient had bleeding from multiple orifices and had to be given cryoprecipitate and fresh frozen plasma (FFP) infusions. She contracted ventilator associated pneumonia caused by *Acinetobacter* spp. for which meropenem and colistin were administered. The patient was, there off transferred to the Indus hospital due to affordability issues. Her femoral line was removed and the catheter tip grew *Candida non albicans* spp, while her peripheral blood cultures sent on admission, and grew *Raoultella terrigena* sensitive only to colistin and tigecycline and *Stenotrophomonas* sensitive to co-trimoxazole. Her tracheal aspirate also grew *Raoultella terrigena* with same sensitivities as the blood isolate. She was started on IV colistin, tigecycline, co-trimoxazole and fluconazole. Her line was replaced, following which *Stenotrophomonas* cleared immediately. Delayed clearance was observed for *Raoultella* bacteremia, as the blood showed no growth of the organism on the 9th day of antibiotics. The possibility of infected thrombus could not be ruled out. The patient remained septic despite culture clearance and expired from disseminated intravascular coagulation (DIC) and multiple organ dysfunction syndrome (MODS) on the 26th day of admission.

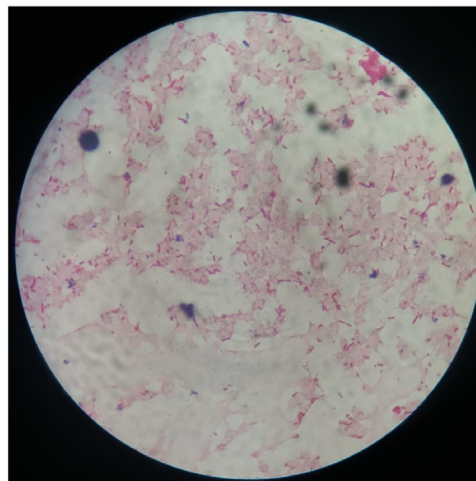


Fig. A1. Gram stain of blood sample showing Gram negative rods.

Case-3

A sixty three years old female known case of hypertension, ischemic heart disease with heart failure (ejection fraction of 35%), chronic obstructive pulmonary disease (requiring long term oxygen therapy and BIPAP) with secondary pulmonary artery hypertension and chronic kidney disease, had a recent prolonged admission of 2 months elsewhere, for lower respiratory tract and urinary tract infections. During the course of this illness she underwent seven sessions of hemodialysis through perma catheter for acute on chronic kidney injury complicated by pulmonary oedema and received meropenem and vancomycin. She was shifted to the Indus hospital due to financial constraints. Two blood cultures from perma catheter on admission at our hospital grew methicillin resistant *Staphylococcus epidermidis* (MRSE) for which vancomycin was continued. Peripheral blood culture grew *Pseudomonas* spp and based on the sensitivity pattern antibiotic was de-escalated from meropenem to ceftazidime. Urine culture grew *Raoultella terrigena* sensitive only to colistin and fosfomycin, hence considering her recent hospitalization, catheterization history and acute on chronic kidney injury, oral fosfomycin was started to treat *Raoultella* infection. She cleared all 3 cultures but deteriorated due to multiple comorbidities and patient's attendants shifted her to another tertiary care hospital.

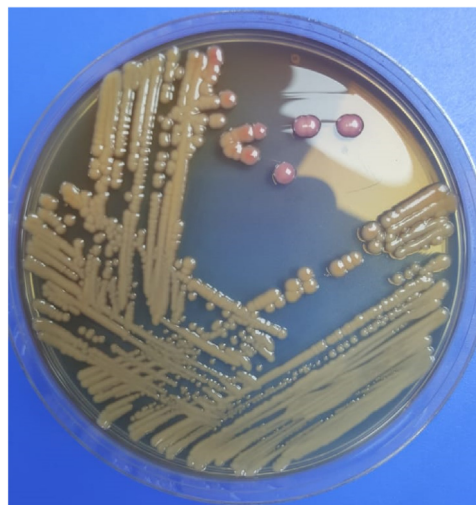

Fig. A2. Growth of lactose fermenter on MacConkey agar.

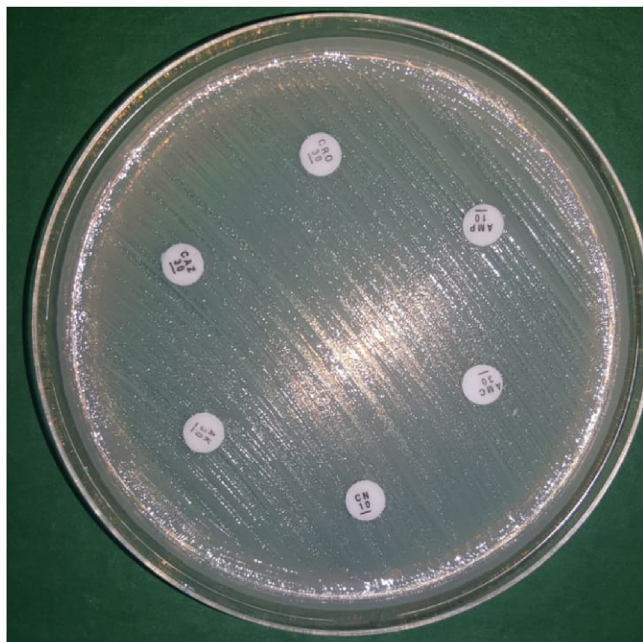


Fig. A3. Sensitivity testing by disc diffusion method.

Microbiological analysis

Microbiological culture and sensitivities were performed as per the standard operating procedures. Blood gram staining showed gram negative rods as shown in Fig. A1. Positive blood culture was inoculated on chocolate, blood agar and MacConkey agar (Oxoid, UK). Chocolate blood agar and MacConkey agar were incubated at 37 °C aerobically for 24–48 hours. After 24 h of incubation there were lactose fermenter mucoid colonies on MacConkey agar Fig. A2. Biochemical tests showed citrate utilization was positive but indole, motility, hydrogen sulphide production as well as urease was negative and acidic / acidic on triple sugar iron test (Oxoid, UK). For further identification API 20 E (bioMérieux) was set and incubated at 37°C for 24 h. This gram negative rod was identified as *Raoultella terrigena* 91% in two cases and 95% in third case by standard conventional biochemical method.

Antibiotic susceptibility

Antimicrobial susceptibility was performed on Mueller-Hinton agar using Kirby-Bauer disk diffusion method and the results were determined according to the Clinical and Laboratory Standards Institute (CLSI) antibiotic guideline as shown in Fig. A3. The antimicrobial tests and the disc content used included,

trimethoprim-sulfamethoxazole (1.25ug/23.75ug), chloramphenicol (30 µg), Ciprofloxacin (10 µg), Fosfomycin (200 µg), Gentamicin (10 µg), amikacin (30 µg), ampicillin (10 µg) ceftriaxone (30 µg), meropenem (30 µg), imipenem (10 µg), ertapenem (10 µg), piperacillin-tazobactam (100/10 µg), tigecycline (15 µg), ceftazidime-sulbactam (30/10 µg) and colistin (10 µg). All plates for antimicrobial susceptibility testing were incubated at 35–37 °C in 5% CO₂ for 24 h. *E.coli* (ATCC 25,922) was used as control strain. Zone diameters were measured and interpreted as per Clinical and Laboratory Standards Institute (CLSI 2018) guidelines.

Discussion

Literature review of data from Pakistan revealed no previous reporting of *R. terrigena*. In fact there is limited relevant clinical data for *R. terrigena* globally. The main purpose of reporting this case series was to highlight the limited antibiotic options available for treatment and the suboptimal response and high mortality observed despite targeted therapy. This organism was originally called *Klebsiella terrigena*, reclassified as *R. terrigena* in 2001 after 16SrDNA and rpoB gene sequencing studies [3]. Current gold standard for identification of this species is gene sequencing, however, in this case series due to resource limitations, conventional identification by using API 20 E was done with 91 to 95% successful identification.

Our two cases developed sepsis due to *R. terrigena* and one case developed urinary tract infection by this organism (shown in Table A1). All three cases grew extensively drug resistant isolate. First case was sensitive only to fosfomycin and co-trimoxazole, second case was sensitive only to tigecycline and colistin whereas third case was resistant to all antibiotics except fosfomycin as shown in Table A2. Literature review revealed that previously reported *R. terrigena* were more sensitive as compared to our study [3–7]. This highlights the threat posed by rising antimicrobial resistance (AMR) where the antimicrobial arsenal to treat extensively drug resistant bacteria is fast depleting with an imminent post antibiotic era in sight. Rampant injudicious use of broad spectrum empirical antibiotics is a major contributor to AMR. Broad spectrum antibiotics coupled with a prolonged ICU stay causes a number of bacteria to develop resistance genes which they readily transfer to other bacteria, increasing chances of colonization and subsequent infection with different multi drug resistant organisms (MDRO's) [3]. All patients in our case series had been transferred from various high dependency or intensive care units and had been heavily pretreated with multiple broad spectrum antimicrobials.

Raoultella spp carries a chromosomal beta- lactamase that makes this agent inherently resistant to several antimicrobial agents [8]. All our patients were put on contact precaution by our infection control department to prevent its transmission to other

Table A1

Table showing different characteristics of patients.

Identified cases	Age (years)	Gender	Comorbid	Previous hospitalization	Source of <i>Raoultella</i>	Outcome
Case 1	30	Female	Uncont. DM*	Multiple prolong hospitalization	Blood and urine culture	Expired
Case 2	63	Female	DM* HTN* RA* CS*	Multiple prolong hospitalization	Blood	Expired
Case 3	63	Female	HTN* IHD* COPD* CKD*	Multiple prolong hospitalization	Urine	Patient shifted to other hospital

* Uncont. DM: Uncontrolled diabetes mellitus, DM: Diabetes Mellitus, HTN: hypertension, RA: rheumatoid arthritis, CS: Cushing syndrome, IHD: ischemic heart disease, COPD: chronic pulmonary disease, CKD: chronic kidney disease.

Table A2

Antibiotics susceptibility pattern of the three isolates of organism. *Raoultella terrigena* from disc diffusion testing.

no	Antibiotics	Case 1	Case2	Case3
1	Ampicillin	R	R	R
2	Co-Amoxiclav	R	R	R
3	Piperacillin-Tazobactam	R	R	R
4	Sulbactam-Cefperazone	R	R	R
5	Ceftriaxone	R	R	R
6	Imipenem	R	R	R
7	Meropenem	R	R	R
8	Ertapenem	R	R	R
9	Amikacin	R	R	R
10	Gentamicin	R	R	R
11	Ciprofloxacin	R	R	R
12	Levofloxacin	R	R	R
13	Tigecycline	R	S	S
14	Co-trimoxazole	S	R	R
15	Chloramphenicol	S	R	–
16	Fosfomycin	S	R	S
17	Nitrofurantoin	–	–	R
18	Colistin	R (MIC > 16 µg/ml)	S	R

S: Sensitive, R: Resistant.

All cases have extensively drug resistant profile.

* Colistin Minimum Inhibitory Concentration was performed by broth micro-dilution method from Aga Khan Laboratory only on one case.

patients. Yu Wang et al described case of subdural abscess due to *R. terrigena* in 2016 and this patient recovered with imipenem. This isolate was pan sensitive [6]. Demiray Tet al published three case report with *R. terrigena*. Two cases were extended -spectrum beta-lactamase (ESBL) negative and both cases were recovered with targeted therapy but one case was ESBL positive which was not responded to therapy and patient died. In contrast to our cases whereby two ended in mortalities, all of Demiray's cases responded well with cefoperazone/sulbactam, piperacillin/tazobactam [3]. Conversely, our patients were not responding adequately to given treatment because of highly resistant antibiotics profile of this bug which left limited option for cure and eradication of infection. Clinical course and outcome of human infection cannot be predicted with very few case reports [6]. Infections with rare bacteria and high antibiotic resistance profile should always be dealt with collaboration of microbiology and infectious diseases as there is no clear understanding of their behaviour and pathogenesis in vivo while specimen reporting. Laboratory staff should be on alert to find out source of the specimen and interpret bacterial identification with the utmost care wherever a rare organism is concerned [3]. There is need to actively monitor and identify such organisms to establish its pathogenic role and antibiotics resistance profile.

Limitations

Due to limited resources our study cannot identify *R. terrigena* by genome sequencing and sensitivity testing was performed by

disk diffusion testing. It was desirable to have minimum inhibitory concentration (MIC) in all cases but we could outsource and perform colistin MIC in only one case

Conclusion

R. terrigena is a potential emerging pathogen and its incidence and pathogenic role is not well reported. There is need of active monitoring and reporting of this bug to establish its antibiogram and clinical significance.

Sources of funding

None.

Declaration of Competing Interest

There are no conflict of interests in this study.

Acknowledgements

There are no acknowledgements.

Appendix A.

References

- [1] Drancourt M, Bollet C, Carta A, Rousselier P. Phylogenetic analyses of *Klebsiella* species delineate *Klebsiella* and *Raoultella* gen. nov., with description of *Raoultella ornithinolytica* comb. nov., *Raoultella terrigena* comb. nov. and *Raoultella planticola* comb. nov. *Int J Syst Evol Microbiol* 2001;51(Pt 3):925–32.
- [2] Ponce-Alonso M, Rodriguez-Rojas L, Del Campo R, Canton R, Morosini M. Comparison of different methods for identification of species of the genus *Raoultella*: report of 11 cases of *Raoultella* causing bacteraemia and literature review. *Clin Microbiol Infect* 2016;22(3):252–7.
- [3] Demiray T, Koroglu M, Ozbek A, Hafizoglu T, Altindis M. The first case of *Raoultella terrigena* infection in an infant. *Turk J Pediatr* 2015;57(6):624–8.
- [4] Monnet D, Freney J. Method for differentiating *Klebsiella planticola* and *Klebsiella terrigena* from other *Klebsiella* species. *J Clin Microbiol* 1994;32(4):1121–2.
- [5] Goegle H, Ruttman E, Aranda-Michel J, Kafka R, Stelzmueller I, Hausdorfer H, et al. Fatal endocarditis due to extended spectrum betalactamase producing *Klebsiella terrigena* in a liver transplant recipient. *Wien Klin Wochenschr* 2007;119(11):385–6.
- [6] Wang Y, Jiang X, Xu Z, Ying C, Yu W, Xiao Y. Identification of *Raoultella terrigena* as a rare causative agent of subungual abscess based on 16S rRNA and housekeeping gene sequencing. *Can J Infect Dis Med Microbiol* 2016;2016:.
- [7] Shaikh MM, Morgan M. Sepsis caused by *Raoultella terrigena*. *JRSM Short Rep* 2011;2(6):1–3.
- [8] Podschun R. Isolation of *Klebsiella terrigena* from human feces: biochemical reactions, capsule types, and antibiotic sensitivity. *Zentralblatt fur Bakteriologie* 1991;275(1):73–8.