

Anesthetic considerations and difficult airway management in a case of Noonan syndrome

Sukhminder Jit Singh Bajwa,
Sachin Gupta,
Jasbir Kaur, Aparajita Panda,
Sukhwinder Kaur Bajwa¹,
Amarjit Singh, S. S. Parmar,
Seema Prasad

Departments of Anaesthesiology & Intensive Care and ¹Obstetrics and Gynaecology, Gian Sagar Medical College & Hospital, Ram Nagar, Banur, Punjab, India

Address for correspondence:

Dr. Sukhminder Jit Singh Bajwa,
Department of Anaesthesiology and Intensive Care, Gian Sagar Medical College & Hospital, Ram Nagar, Banur, Punjab, India.
E-mail: sukhminder_bajwa2001@yahoo.com

ABSTRACT

Noonan syndrome is a genetically transmitted autosomal dominant disorder characterized by various anatomic anomalies and pathophysiologic derangements. Anesthetic management in such cases poses a multitude of challenges, especially related to the airway management and maintenance of cardiovascular stability. We report a case of a 9-year-old male child weighing 24 kg, who was diagnosed as a case of Noonan syndrome and had undergone ligation of patent ductus arteriosus during early childhood. The child was operated on for release of bilateral neck bands under general anesthesia. The case report pertains to the successful airway and anesthetic management in the background of difficult airway and existence of various cardiac lesions.

Key words: Hypertrophic cardiomyopathy, Noonan syndrome, pulmonary stenosis, webbed neck

INTRODUCTION

The incidence of Noonan syndrome (NS) is estimated at 1 in 1000 to 1 in 2500 births, with equivalent distribution in both the genders.^[1,2] A gene for NS has been mapped to chromosome number 12.^[3] The cardinal features of NS include unusual facies, such as hypertelorism, down-slanting eyes with a webbed neck, congenital heart disease, short stature, and chest deformity. Approximately 25% of individuals with NS have mental retardation. Bleeding diathesis is present in as many as half of all patients with NS. Skeletal, neurologic, genitourinary, lymphatic, eye, and skin findings may be present to varying degrees.^[1,2]

CASE REPORT

A 9-year-old male child was brought to the plastic surgery

outpatient department by his parents with chief complaints of deformity in the neck region. On first inspection, it seemed to be a case of torticollis. But complete examination enabled us to diagnose it as a case of webbed neck with bilateral contracture more on the right side [Figure 1]. There was no family member with characteristics of NS. On elicitation of past history, it was revealed that the child had undergone some cardiac intervention at the age of 2 years. Examination of past medical record revealed that he had undergone ligation of patent ductus arteriosus (PDA) under general anesthesia. Thereafter, the child had normal growth with no significant medical history. Presently, the patient had no symptoms pointing toward any cardiac decompensation. His exercise tolerance was good. He was not receiving any medication and parents did not convey any untoward incident of drug allergy or any other systemic medical disease. The hemoglobin level was 12.8 g/dL and the serum electrolytes, creatinine, blood glucose, and rest of the investigations were within normal limits. Hematologic investigations revealed no coagulation or platelet defects.

On local examination, we found bilateral neck bands with short webbed neck and low posterior hairline. On clinical examination, pulse rate was 94/min and regular and blood pressure was recorded to be 104/68 mmHg. Mallampatti

Access this article online

Quick Response Code:



Website:

www.saudija.org

DOI:

10.4103/1658-354X.84121

score was labeled as grade 3 with mouth opening of approximately 1.5 cm and the weight of the child was 24 kg. On auscultation, a pan systolic murmur was heard at pulmonary and aortic area. Chest X-ray showed normal bronchovascular markings with a radio-opaque ligature of PDA [Figure 2]. Lateral view of the cervical spine revealed a short base of skull with a steep angle, basilar invagination, atlanto-occipital fusion, as well as the fusion of 2nd, 3rd, 4th, and 5th cervical vertebrae [Figure 3].

The electrocardiogram (ECG) showed T-wave inversion in L3, V1, V2, and V3 leads with no any other abnormality. Echocardiographic findings revealed normal left ventricular function, mild aortic stenosis with bicuspid aortic valves, pulmonary stenosis with thickened cusps, and small PDA of approximately 2.5 mm. The child was reviewed by a cardiologist and was advised infective endocarditis prophylaxis before the scheduled elective surgery for the release of bilateral neck bands.

On the day of surgery, the child received 75 mg of ranitidine and 12.5 mg of oral promethazine syrup 1 h before the scheduled surgical procedure. The child was very cooperative inside the operation theater and a peripheral venous access was secured using 20G cannula. Resuscitation and difficult airway management trolley was kept by the side and the equipment for tracheostomy was made available. An ENT surgeon had already scrubbed and was ready in case for any eventuality. The child was preoxygenated with 100% O₂ for 5 min.

Induction of anesthesia was achieved with Fentanyl 50 µg, glycopyrrolate 0.1 mg, propofol 50 mg, and 2% sevoflurane. After establishing a successful bag mask ventilation, 2.5 mg vecuronium bromide was administered. After 3 min of ventilation, fiberoptic bronchoscopy was carried out. It was a little difficult negotiating the pharyngeal curves but within a minute we were able to view the glottis and a cuffed endotracheal tube number 5.5 mm internal diameter was safely placed into the trachea. Thereafter, surgery was performed in a prone position and throughout the procedure strict vigil monitoring was carried out, which included heart rate, ECG, end-tidal carbon dioxide, pulse oximetry, and noninvasive blood pressure. Maintenance of anesthesia was achieved with oxygen, nitrous oxide, sevoflurane, and vecuronium bromide. The entire procedure lasted for 2 h. At the end of surgical procedure, neuromuscular blockade was reversed with injection neostigmine and glycopyrrolate. Extubation was done after the onset of rhythmic breathing and return of protective airway reflexes. The child was given postoperative oxygenation for 5 min and after that kept in postanesthesia care unit for 2 h and strict monitoring was carried out. Diclofenac

sodium was given as postoperative analgesic as infusion. The postoperative period was uneventful and the child was discharged on 8th postoperative day in a satisfactory condition.

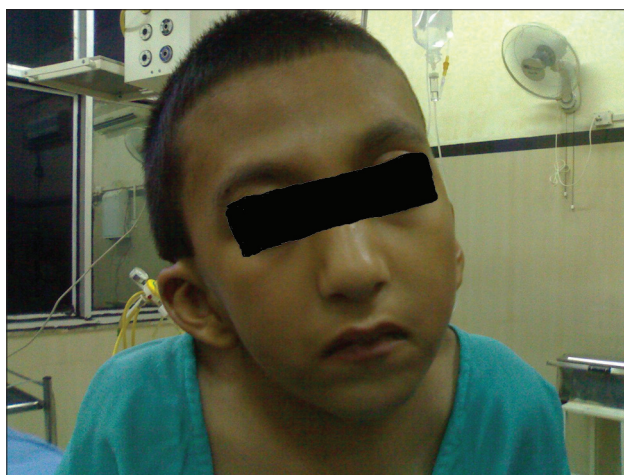

Figure 1: Frontal view of the patient showing the neck contracture and difficult airway

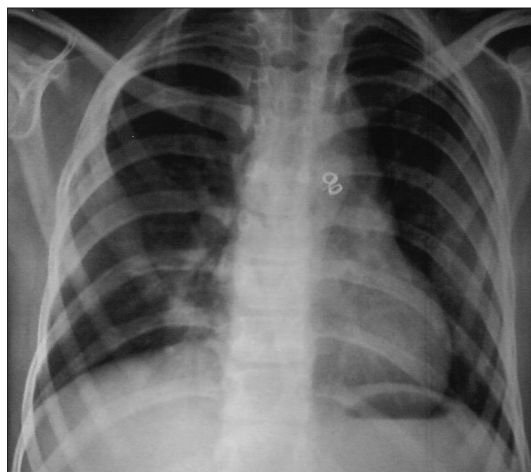


Figure 2: Chest X-ray showing the old PDA clip in place

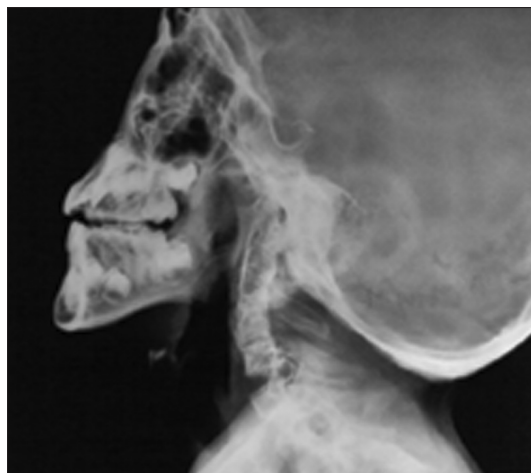


Figure 3: Lateral view of the cervical spine showing the fusion of cervical vertebrae

DISCUSSION

NS is an autosomal dominant disorder resembling Turner syndrome in many ways, with abnormally shaped chest and webbed neck, but differs from it in having normal sex chromatin, gender distribution, the site of the cardiac lesion, the facial appearance, and the presence of mental retardation.^[4] Facial appearances are not always conclusive in identifying with precision the diagnosis of NS in adult patients, although they can be more strikingly helpful in early childhood.^[5]

The most common congenital cardiac lesion is the presence of pulmonary valve stenosis in almost 50%–60% of patients as was also the presence of this lesion in our case.^[6] The incidence of hypertrophic obstructive cardiomyopathy, atrial septal defects, ventricular septal defects, and PDA is approximately 20%, 8%, 5%, and 3%, respectively.^[7,8] Although our patient also presented with a rare PDA anomaly but fortunately it had been taken care of in early childhood. NS is characterized by a mutation on *PTPN11* gene on chromosome 12, which encodes for tyrosine phosphatase, in nearly about half of the cases of NS. Tyrosine phosphatase is responsible for many enzymatic reactions which involve the interaction of various growth factors and hormones in the various stages of physical and mental developmental processes.^[9] There are numerous syndromes, which resemble the symptomatology of NS and have to be excluded before the final diagnosis.^[10] In the background of these cardiac lesions, prophylaxis for infective endocarditis was administered with injection ampicillin 50 mg/kg and gentamicin 1.5 mg/kg 1 h prior to the surgical procedure. The main challenges in our case were the airway management due to webbed neck and cervical spine anomalies as well as cardiac considerations due to an operated PDA, pulmonary stenosis, and aortic stenosis with hypertrophic cardiomyopathy. Prevention of tachycardia due to sympathetic stimulation and stress response of anesthesia and surgery was our prime motive along with decrease of after load to prevent any complication.^[11-13] We had planned for fiberoptic bronchoscopy and intubation. After induction of anesthesia with propofol.

We checked for ventilation and after establishing successful bag mask ventilation we administered vecuronium bromide for muscle relaxation. Fiberoptic intubation in awake state is recommended in such cases with difficult airway, but owing to the risks of detrimental effects of stress response on cardiac tissue in an awake state we decided to proceed with intubation after establishing adequate depth of anesthesia and profound muscle relaxation. Second, it is extremely difficult in a pediatric patient to achieve the highest level of co-operation during awake procedures on the airway. The airway trolley was made ready with all the equipment necessary for difficult airway management. Arterial hypoxemia can occur very rapidly in such patients in view of the decreased functional residual capacity. Therefore, preoperative, intraoperative, and postoperative

pharmacology has to be given an indepth consideration to avoid any incidence of hypotension and hypoxemia. Fentanyl was used for achieving analgesia because it has a relative benign effect on myocardial contractility avoiding drug-induced myocardial depression, short duration of action, and lesser propensity for respiratory depression postoperatively.

The dose-dependent myocardial depression of inhalational anesthetic agents are in fact helpful in generating a slight negative inotropic response and maintaining a low left ventricular pressure gradient in cases of hypertrophic cardiomyopathy.^[14,15] To summarize, we can conclude that for successful airway and anesthetic management in a case of NS, one should have thorough and deep knowledge about the various anatomic anomalies and pathophysiologic considerations so as to prevent any clinical disaster in the operation theater, especially for an elective surgery.

REFERENCES

- Allanson JE. Noonan syndrome. *J Med Genet* 1987;24:9-13.
- Sharland M, Burch M, McKenna WM, Patton MA. A clinical study of Noonan syndrome. *Arch Dis Child* 1992;67:178-83.
- Jamieson CR, van der Burgt I, Brady AF, van Reen M, Elsawi MM, Hol F, et al. Mapping a gene for Noonan syndrome to the long arm of chromosome 12. *Nat Genet* 1994;8:357-60.
- Dadabhoj ZP, Winnie AP. Regional anesthesia for cesarean section in a parturient with Noonan's syndrome. *Anesthesiology* 1988;68:636-8.
- Allanson JE, Hall JG, Hughes HE, Preus M, Witt RD. Noonan syndrome: The changing phenotype. *Am J Med Genet* 1985;21:507-14.
- Lin AE. Noonan syndrome. *J Med Genet* 1988;25:64-5.
- Sharland M, Burch M, McKenna WM, Patton MA. A clinical study of Noonan syndrome. *Arch Dis Child* 1992;67:178-83.
- Marino B, Digilio MC, Toscano A, Giannotti A, Dallapiccola B. Congenital heart diseases in children with Noonan syndrome: An expanded cardiac spectrum with high prevalence of atrioventricular canal. *J Pediatr* 1999;135:703-6.
- Neel BG, Gu H, Pao L. The "Shp"ing news: SH2 domain-containing tyrosine phosphatases in cell signaling. *Trends Biochem Sci* 2003;28:284-93.
- Preus M. Differential diagnosis of the Williams and the Noonan syndromes. *Clin Genet* 1984; 25:429-34.
- Morgan GE Jr, Mikhail MS, Murray MJ. *Clinical anesthesiology*. 4th ed. USA: McGraw-Hill; 2006. p. 475.
- Autore C, Brauneis S, Apponi F, Commisso C, Pinto G, Fedele F. Epidural anesthesia for cesarean section in patients with hypertrophic cardiomyopathy: A report of three cases. *Anesthesiology* 1999;90:1205-7.
- Collins E, Turner G. The Noonan syndrome - a review of the clinical and genetic features of 27 cases. *J Pediatr* 1973;83:941-50.
- Schwartz N, Eisenkraft JB. Anesthetic management of a child with Noonan's syndrome and idiopathic hypertrophic subaortic stenosis. *Anesth Analg* 1992;74:464-6.
- Campbell AM, Bousfield JD. Anaesthesia in a patient with Noonan's syndrome and cardiomyopathy. *Anaesthesia* 1992;47:131-3.

How to cite this article: Bajwa SJ, Gupta S, Kaur J, Panda A, Bajwa SK, Singh A, Parmar SS, Prasad S. Anesthetic considerations and difficult airway management in a case of Noonan syndrome. *Saudi J Anaesth* 2011;5:345-7.

Source of Support: Nil, **Conflict of Interest:** None declared.