



Clinical outcomes following reverse total shoulder arthroplasty with tuberosity excision for treatment of proximal humerus fractures: a case series



Taylor A. VanHelmond, BS^{a,*}, Hari Iyer, MD^b, Brandon E. Lung, MD^b, Kevin I. Kashanchi, BS^b, Matthew Pearl, MD^b, David E. Komatsu, PhD^b, Edward D. Wang, MD^b

^aFlorida Atlantic University School of Medicine Department of Surgery, Charles E. Schmidt College of Medicine, Florida Atlantic University, Boca Raton, FL, USA

^bStony Brook University School of Medicine, Department of Orthopedic Surgery, Renaissance School of Medicine, Stony Brook University, Stony Brook, NY, USA

ARTICLE INFO

Keywords:

Tuberosity excision
Reverse shoulder arthroplasty
Proximal humerus fracture
Clinical outcomes
ASES
Range of motion

Level of evidence: Level IV; Treatment Study

Background: Reverse total shoulder arthroplasty (RTSA) has become an increasingly popular treatment option for complex 3- and 4-part proximal humerus fractures in elderly patients. The literature has demonstrated that tuberosity repair likely improves postoperative range of motion (ROM). However, the difference between tuberosity repair and excision may not be appreciable to patients in their day-to-day lives. This case series reports both objective and subjective clinical outcomes of patients who underwent RTSA with tuberosity excision for proximal humerus fractures.

Methods: We reviewed the records of 41 patients who underwent RTSA for complex 3- and 4- part proximal humerus fractures. All RTSA procedures were performed by a single surgeon between 2014 and 2017. All patients underwent RTSA with extended proximal stem cementation and tuberosity excision. Postoperative outcomes were measured at least 2 years postoperatively and included ROM measurements for forward flexion, internal rotation, abduction, and external rotation. Patient-reported outcome measures included Simple Shoulder Test scores, American Shoulder and Elbow Surgeons scores, and Penn Shoulder Score were also reported.

Results: In this case series, we report on 41 patients, 33 females and 8 males. Objective measurements of ROM for forward flexion, abduction, and external rotation were 125, 95, and 36 degrees, respectively. On average, patients had an internal rotation score of 2.06 and were able to get their thumb to their iliac crest. Clinical outcome scores of these patients were 9.11, 77.79, and 74.12 for the Simple Shoulder Test, American Shoulder and Elbow Surgeons, and Penn Shoulder Score, respectively. Strength of the deltoid was 5/5 in all 41 patients.

Conclusions: When compared with the current literature, our tuberosity excision patients demonstrated deficits in forward flexion and abduction, with preserved external rotation. Our clinical outcome score measurements were consistent with clinical outcome measurements from previous studies of patients undergoing RTSA with tuberosity repair. We believe that tuberosity excision may be a reasonable and simpler surgical option for surgeons with lower volumes of shoulder fractures and patients with multiple comorbidities and higher surgical risk, owing to the similarity of outcome scores between our cohort and previous tuberosity repair groups.

© 2021 The Author(s). Published by Elsevier Inc. on behalf of American Shoulder & Elbow Surgeons. This is an open access article under the CC BY-NC-ND license (<http://creativecommons.org/licenses/by-nc-nd/4.0/>).

Address¹: Edward Wang, MD, Department of Orthopedics, T18, Room 020, Renaissance School of Medicine, Stony Brook University, Stony Brook, NY 11794-8181, USA.

¹ Present author address: Taylor VanHelmond, 6760 Congress Avenue, PH9, Boca Raton, FL, 33487, USA.

This study was approved by Stony Brook University's Institutional Review Board (study number: 1248796-2; CORIHS: 2018-4599-F).

*Corresponding author: Taylor A. VanHelmond, BS, 6760 Congress Avenue, PH9, Boca Raton, FL 33487, USA.

E-mail address: Tvanhelmond2019@health.fau.edu (T.A. VanHelmond).

<https://doi.org/10.1016/j.xrrt.2021.10.003>

2666-6391/© 2021 The Author(s). Published by Elsevier Inc. on behalf of American Shoulder & Elbow Surgeons. This is an open access article under the CC BY-NC-ND license (<http://creativecommons.org/licenses/by-nc-nd/4.0/>).

Proximal humerus fractures account for approximately 4%-6% of fractures and are the third most common fracture type among elderly patients.⁸ Although a majority of these fractures may be treated nonoperatively, complex 3- and 4-part fractures often require surgery.^{10,23} A recent retrospective review noted no significant difference in subjective outcome scores and range of motion (ROM) between nonoperative treatment and reverse total shoulder arthroplasty (RTSA) in the treatment of proximal humerus fractures. However, previous studies have shown low ROM and

subjective outcome scores specifically for 3- and 4-part proximal humerus fractures treated nonoperatively leading to the current recommendation of surgical management.²³ Furthermore, complex proximal humerus fractures account for 5%-15% of all proximal humerus fractures.⁵ Although open reduction and internal fixation (ORIF) with plate and screw constructs remains a mainstay of operative treatment, complications such as humeral head necrosis, loss of fixation, and screw penetration in the setting of osteoporotic bone represent significant challenges in managing these types of fractures.¹⁹ Additionally, older adults may have pre-existing arthritis in the setting of a 3- or 4- part fracture, making the decision between ORIF and arthroplasty more difficult with increased need to personalize treatment for each patient. Arthroplasty has become an attractive option for patients in whom osteosynthesis is not ideal. Hemiarthroplasty (HA), as first introduced by Neer, has been a good solution for these types of patients.²⁰ However, HA relies on healing of the tuberosities to allow for a functional rotator cuff and good functional outcomes.^{3,5} In a prospective multicenter study evaluating HA in the treatment of proximal humerus fractures, there were tuberosity nonconsolidation rates of up to 50%. This same study found nonconsolidation resulting from malpositioning and migration of the greater tuberosity. Furthermore, this study found that failure for tuberosity healing yielded reduced ROM, lower patient satisfaction, and decreased ability to complete common activities of daily living (ADLs).³ In the setting of nonanatomic consolidation, nonunion, or resorption of the tuberosities after HA, previous studies have reported good pain relief but poor postoperative forward flexion, external rotation, and internal rotation owing to rotator cuff deficiency.^{3,27}

RTSA was initially introduced as a possible solution to these poor postoperative functional outcomes observed with HA and in the setting of rotator cuff deficiency. Neer found that patients with rotator cuff failure who underwent HA consistently reported superior subluxation of the humerus with limited ROM in all planes.⁹ RTSA was created to balance joint stability with satisfactory ROM outcomes by increasing utilization of the deltoid.⁹ The current biomechanical aspects of the prosthesis are based on a semiconstrained joint and the original Grammont principles emphasizing (1) an inherently stable prosthesis; (2) a weight-bearing part that is convex and a supported part that is concave; (3) a center of the sphere that is at or within the glenoid neck; and (4) a center of rotation that is medialized and distalized.⁹ While RTSA was initially used to treat rotator cuff tear arthropathy, there have been increasing surgical indications for which the RTSA has shown clinical benefits.⁹

In comparison with HA, previous studies suggest that tuberosity healing is of less importance for good functional outcome after an RTSA.^{3,14} Thus, RTSA has become a mainstay of treatment for patients with rotator cuff tear arthropathy.¹⁷ Furthermore, given the prevalence of osteoporosis and poor rotator cuff tissue quality among elderly patients with complex 3- and 4-part proximal humerus fractures, RTSA has become increasingly popular for the management complex 3- and 4-part proximal humerus fractures in the elderly.^{4,6} Surgical technique for RTSA with tuberosity repair have been well documented in the literature.^{7,13,22} However, few studies provide in-depth descriptions of the surgical technique used and any changes that are made when the tuberosities are excised.²²

Current recommendations for RTSA for the treatment of proximal humerus fractures surgical technique include tuberosity repair after implantation of the humeral component.¹⁸ Tuberosity repair with successful osteosynthesis has been shown to have better ROM in forward flexion and external rotation after RTSA.^{1,12} However, retrospective reviews have shown variable rates of tuberosity osteosynthesis with many patients' imaging demonstrating

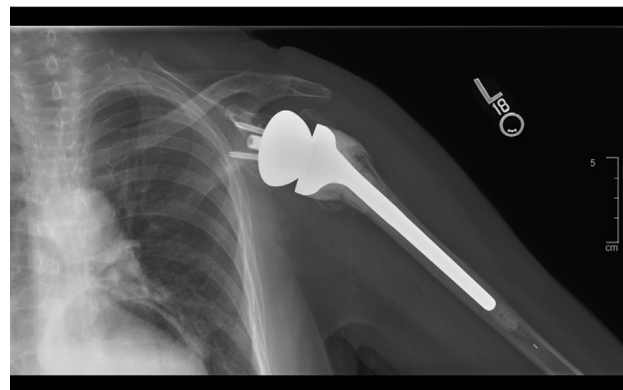


Figure 1 AP view of Dupuy RTSA with tuberosity excision. AP, anteroposterior; RTSA, reverse total shoulder arthroplasty.

tuberosity nonunion or full resorption at 2 and 5 years postoperatively.¹⁷ Reported healing rates of repaired tuberosities after RTSA range from 40 to 84%.^{2-4,7} Furthermore, successful tuberosity repair may be hindered in the setting of osteoporotic bone and small or comminuted fracture fragments.² In the literature, there has been a general consensus of improved forward flexion and external rotation of the shoulder with tuberosity repair when compared with tuberosity excision.^{1,12,18,22} However, Ohl et al found that when directly compared against patients with malunited or migrated tuberosities, patients with tuberosity excision did not show statistically significant ROM or Constant-Murley score differences.²² In circumstances of tuberosity malunion or migration, tuberosity repair may not improve functional outcome after RTSA for surgical treatment of proximal humerus fractures.²²

Tuberosity repair usually requires protection of the repair. This generally means prohibition of active range of motion (AROM) in the immediate postoperative period. In the patients included in this reported case series, the tuberosities were excised to allow immediate AROM, early return to function, and possibly less stiffness. This is desirable as immediate early AROM may be beneficial to postoperative outcomes.¹⁶ This case series documents the functional and clinical outcomes in 41 patients who underwent RTSA with tuberosity excision in the surgical treatment of proximal humerus fractures.

Materials and methods

Study population

From 2014 to 2017, 41 patients met treatment criteria and underwent RTSA with tuberosity excision by a single board-certified upper extremity orthopedic surgeon. All procedures were performed at a level I trauma center. The indication for RTSA in this study included patients who had a (1) displaced acute 3- or 4- part fracture according to the Neer classification or (2) comminuted proximal humerus fracture in the setting of poor bone quality for osteosynthesis. Patients discussed postoperative goals with the surgeon to determine that an RTSA with tuberosity excision was best for their desired functional outcome and adherence to postoperative protocol. Patients were given a neurologic assessment for function of the deltoid before surgery with strength measured 5/5. The operating surgeon preferred operating within 10-14 days of the injury to allow for the reduction of swelling of the soft tissue. All patients had a significant mechanism of injury for a ground-level slip and fall or other type of trauma. Patients who underwent

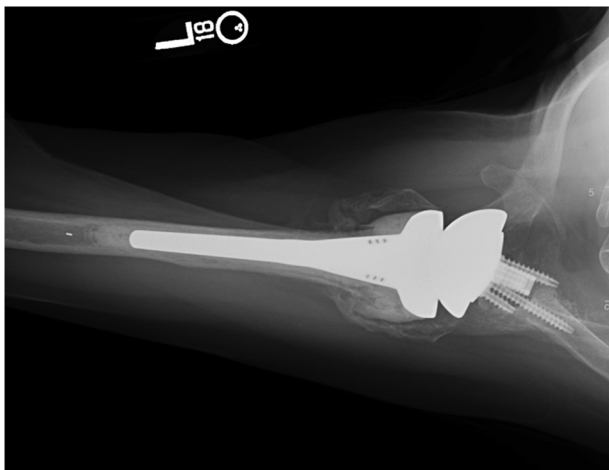


Figure 2 Axillary view of Dupuy RTSA with tuberosity excision. RTSA, reverse total shoulder arthroplasty.

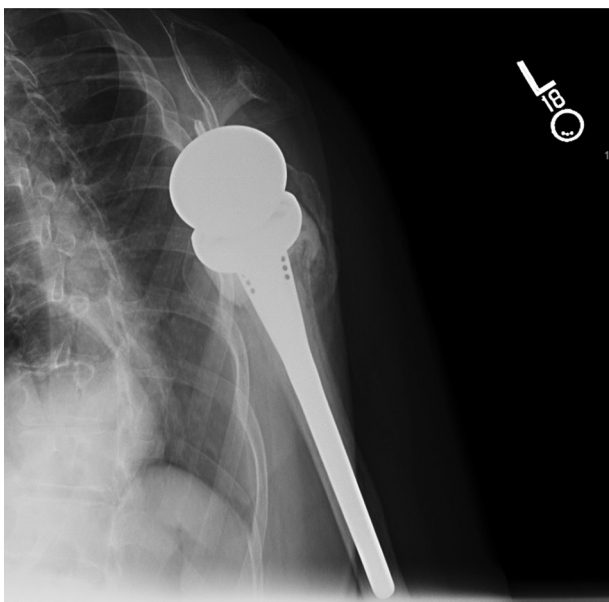


Figure 3 Y view of Dupuy RTSA with tuberosity excision. RTSA, reverse total shoulder arthroplasty.

RTSA for fracture revision, previous fracture and malunion of the tuberosity, failed previous ORIF, fractures older than 6 weeks, or failed previous HA for fractures were excluded from this study. Two patients were deceased at the time of follow-up. Of the 41 patients included, there were no complications such as infections, fractures, or dislocations at the time of data collection. All patients selected had undergone RTSA with tuberosity excision and incorporation of an extended cement mantle. The rationale for the extended cement mantle in the setting of a proximal humerus fracture is to decrease the torsional stress on the implant. Increased torsional strength is achieved by extending the cement onto the proximal portion of the implant which can interdigitate with the proximal portion of the fracture component decreasing rotational forces on the implant itself.¹⁵ Depuy reverse prosthesis was used on the first 24 patients, which had a 155-degree humeral neck angle (Figs. 1-3). Implants

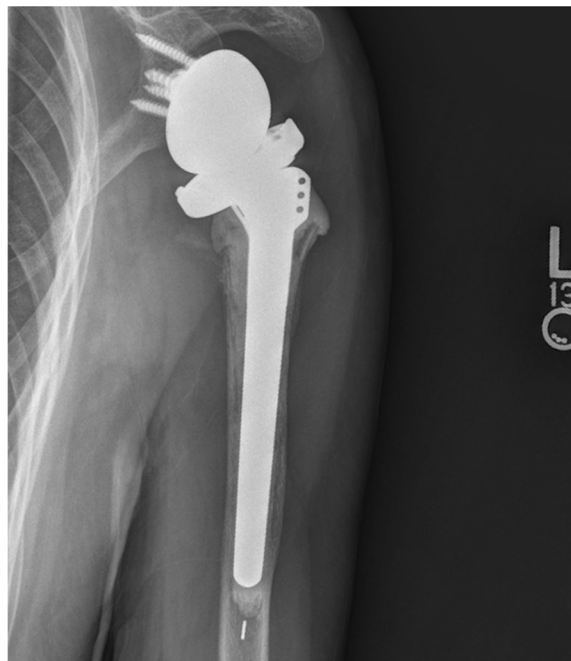


Figure 4 AP view of Biomet RTSA with tuberosity excision. AP, anteroposterior; RTSA, reverse total shoulder arthroplasty.

were switched to Biomet with a 135-degree humeral neck angle in our final 17 patients (Figs. 4-6). Our reason for switching implants was increased implant options. In both prostheses, the lateralization of the component was able to be fit to the patient to maximize stability of the prosthesis. A retrospective review and telephone follow-up of patients having undergone RTSA for proximal humerus fractures were approved by our university's institutional review board.

Clinical assessment

AROM including forward flexion, abduction, and external rotation was measured at least 24 months postoperatively in an office setting. Measurements were taken by the operating surgeon, physician assistant, and resident physician using a goniometer. Measurement methods utilizing the goniometer were reviewed in office with the participating surgeon, physician assistant, and resident physician to standardize ROM measurements. Only AROM was taken, and the highest measurement was recorded for forward flexion, abduction, internal rotation, and external rotation. External rotation was measured with the patient's elbow at their side using the goniometer. Internal rotation was measured by the spinal level that the patient's thumb reached.²⁵ In documenting patients' active range of internal rotation, we assigned the level of the sacrum a numerical value of 1; the iliac crest, a value of 2; levels L2-L3, a value of 3; and T12 and higher, a 4 similar to the Constant-Murley scoring system. Strength of the deltoid was assessed both preoperatively and postoperatively.

Clinical outcome survey

Our patient cohort was also subjectively measured by a survey which compiled questions from the Simple Shoulder Test (SST), American Shoulder and Elbow Surgeons (ASES) score, and Penn Shoulder Score (PSS) clinical outcome scores. This survey was completed at 24 months postoperatively along with the ROM

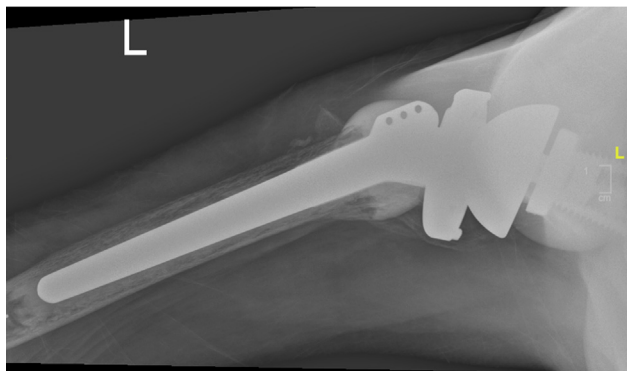


Figure 5 Axillary view of Biomet RTSA with tuberosity excision. RTSA, reverse total shoulder arthroplasty.

measurements. The questionnaire was crafted with all of the SST, ASES, and PSS questions combined and then scored individually. Surveys were collected via mail, telephone follow-up, and attempts to bring patients back for their two-year follow-up evaluation.

Surgical technique

Patients are initially given both regional and general anesthesia. Intravenous antibiotics are also given preoperatively. The correct shoulder is prepped and draped in a sterile fashion. Patients are placed in a beach chair position with an anterior incision starting at the coracoid process and extending down toward the insertion of the pectoralis major tendon. The subcutaneous tissues are dissected by electrocautery. The cephalic vein is identified and protected with lateral retraction. The deltopectoral interval is then opened, and the fracture is identified. The pectoralis major tendon is partially released for a distance of 10 mm, exposing the biceps tendon which is tenotomized and then tenodesed to the pectoralis tendon insertion. The bicipital sheath is opened, and the biceps tendon is excised. Starting at the bicipital groove, the rotator cuff tendons are gently peeled off of the bone fragments, exposing the humeral head and its fracture components.

The humeral head and greater and lesser tuberosity fragments are removed, facilitating exposure of the glenoid. The residual glenoid labrum is then removed. Residual cartilage is curetted away from the glenoid. Using an appropriate drill guide, a guide pin is drilled into the center of the inferior circular portion of the glenoid at a five-degree inferior tilt. This is followed by the appropriate cannulated reamer, which is used to ream the center peg hole and also to remove a minimal amount of subchondral bone on the superior aspect and to expose some cancellous bone inferiorly. The mini baseplate is impacted into position. The center screw is placed, followed by 4 peripheral locking screws. The glenosphere is placed into position onto the baseplate.

The medial calcar fragments are reconstituted to aid in judging the correct height for the humeral prosthesis. Humeral reamers are used to hand ream up to the appropriate endosteal fit. The trial humeral stem is placed into position. A trial reduction is performed to confirm the correct height for the prosthesis and correct soft-tissue tension. Version is placed at 30 degrees retroversion. The trial is removed from the humerus. The cement restrictor is placed. The proximal canal is thoroughly irrigated with betadine-containing saline and bacitracin-containing saline. It is thoroughly dried with an endotracheal suction tube and a vaginal packing. Using a cement gun, the intramedullary canal is filled in a retrograde fashion with methylmethacrylate cement.

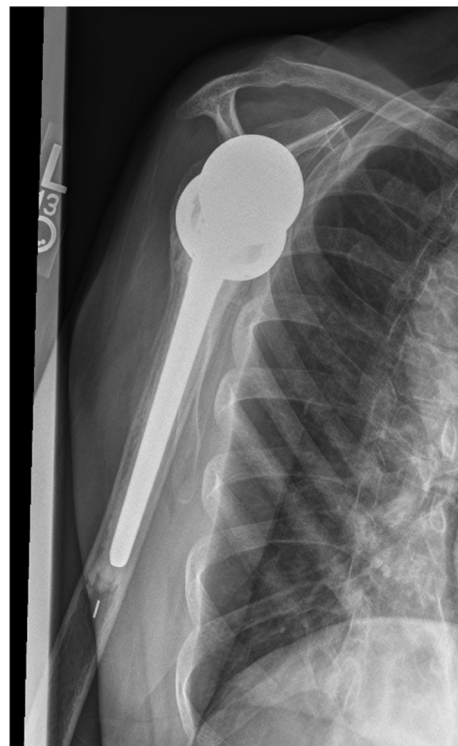


Figure 6 Y view of Biomet RTSA with tuberosity excision. RTSA, reverse total shoulder arthroplasty

The appropriate fracture stem is placed into position at the pre-determined height and retroversion. This is placed in approximately 30 degrees retroversion, and it is held in place until the cement has hardened. The medial calcar fragments are also reduced anatomically and held in place with cerclage sutures as needed. A trial humeral tray is used in trial reductions to determine the correct polyethylene thickness. The trial insert is removed, and the final humeral tray is assembled with the proper polyethylene component and placed into position. The shoulder is reduced again. There is usually a noticeable clunk as the shoulder is reduced, and it is confirmed to be stable and balanced with the soft tissues. The rotator cuff is not reattached to the proximal humerus. Passive ROM testing is completed with full forward flexion, external rotation, and abduction. The patient is able to touch the opposite shoulder. The axillary nerve is palpated. The deltoid traction test is used to confirm that the axillary nerve is intact. Excellent homeostasis is maintained during the procedure. Intraoperative fluoroscopy confirms congruent joint reduction and proper placement of shoulder implant. The wound is copiously irrigated with betadine-containing saline and bacitracin-containing saline. The wound is closed. A shoulder immobilizer and ice machine are applied. The patient is then extubated and transferred to the recovery room.

Postoperative protocol

Patients are initially placed in a sling until the nerve block subsides. Patients are advised to begin gentle AROM exercises within 1-2 days of surgery (recommended for 5 minutes several times per day). Patients are advised not to weight-bear on the arm until 6 weeks postoperatively. Patients are allowed to return to

Table I
Patient characteristics.

Characteristic	Average	Standard deviation
Age (years)	70.17	8.58
BMI (kg/m ²)	28.55	6.11
Time between injury and surgery (days)	14.27	6.75
Operative time (minutes)	131.58	22.94

BMI, body mass index.

Table II
Patient comorbidities.

Characteristic	N	Percentage (%)
Female gender	33	80.5
Smoking status	10	24.4
Pre-existing osteoarthritis	16	39.0
Diabetes	10	24.4
Lung disease	11	26.8
Thyroid disease	7	17.1
Heart disease	30	73.2
Workers compensation/No-fault	4	9.5

normal activities as tolerated. Patients are advised not to lift more than 25 pounds with each arm for the life of the prosthesis.

Data analysis

Patient demographics and comorbidities were calculated as a percentage of our cohort of 41 patients. Numeric demographics such as age, body mass index, time between injury and surgery, and operative time were averaged and reported along with standard deviations (SDs). The mean ROM measurements of forward flexion, abduction, external rotation, and internal rotation were calculated along with their SDs. Clinical outcome scores of the SST, ASES, and PSS were also averaged, and SDs reported. Using the range, average, and 25th and 75th quartile measurements, we constructed box plots demonstrating the quartile measurements of the ROM and clinical score data.

Results

Forty-one consecutive patients met inclusion criteria and were included in this case series. All of these patients underwent RTSA with tuberosity excision with an extended cement mantle between 2014 and 2017. The average age of our study sample was 70.17 years (SD: 8.58, range: 50-88 years) (Table I). Thirty-three (80.5%) patients were female, and eight (19.5%) patients were male. The average body mass index of these patients was 28.55 kg/m² (SD: 6.11, range: 18.6-43.6 kg/m²). The average operative time was 131.58 minutes (SD: 22.94, range: 88-176 minutes) (Table I). The average time between injury and surgery was 14.27 days (SD: 6.75, range: 3-29 days) (Table I). Comorbidities of our patient cohort were also assessed. Ten (24.4%) were smokers. Sixteen (39.0%) had pre-existing osteoarthritis of the glenohumeral joint. Ten (24.4%) had diabetes. Eleven (26.8%) had lung disease. Seven (17.1%) had thyroid disease. Thirty (73.2%) had heart disease. Finally, Four (9.5%) were under worker's compensation or No-fault insurance coverage (Table II).

ROM and clinical outcome score data were collected at least 24 months postoperatively. The average measurements of forward flexion, abduction, and external rotation were 125 (SD: 25.64), 95 (SD: 18.78), and 36 degrees (SD: 29.90), respectively (Table III). The average level of postoperative internal rotation was 2.06 (SD: 0.86). A postoperative internal rotation of 2.06 represents the ability for

Table III
ROM at 24 months.

Motion	N	Average (degrees)	Standard deviation
Forward flexion	37	125	25.64
Abduction	30	95	18.78
Internal rotation	30	2.06	0.86
External rotation	34	36	29.90

ROM, range of motion.

patients to get their thumb to the level of the iliac crest. The range of forward flexion measurements was 45-160 degrees, with the 25th percentile at 107.5 degrees and 75th percentile at 140 degrees (Fig. 7). Abduction range was 45-135 degrees, with 25th percentile at 90 degrees and 75th percentile at 105 degrees (Fig. 7). The range of external rotation measurements was -5-90 degrees, with the 25th percentile at 10 degrees and the 75th percentile at 45 degrees (Fig. 7). Additionally, all patients had 5/5 strength of the deltoid on their operative side at the time of follow-up.

Forty-one patients were contacted via phone call, mail, and office visits to obtain consent and completion of the outcome surveys. Twenty-seven (65.9%) patients completed the clinical outcome score surveys. The clinical outcome measures reported outcomes of 9.11 (SD: 2.24), 77.79 (SD: 11.77), and 74.12 (SD: 13.83) and averages for the SST, ASES, and PSS, respectively (Table IV). The range of SST values was 4-12, with a 25th percentile score of 7.25 and 75th percentile with a score of 11 (Fig. 8). The range for our ASES scores was 53.3-98.3, with the 25th percentile at 70.4 and 75th percentile at 87.88 (Fig. 8). PSS score ranges were from 49 to 99, with a 25th percentile score at 64.25 and 75th percentile at 85.10 (Fig. 8).

Discussion

In this case series, we report on 41 patients who underwent RTSA with tuberosity excision in the treatment of 3- and 4- part proximal humerus fractures. Our patients had an average AROM of 125 degrees of forward flexion, 95 degrees of abduction, and 36 degrees of external rotation. The average patient in our cohort was able to internally rotate to the iliac crest with an average score of 2.06. Clinical outcomes scores were measured via the SST, ASES, and PSS tests. The average scores were 9.11, 77.79, and 74.12, respectively.

RTSA has become a leading treatment for the treatment of proximal humerus fractures in elderly patients.¹³ Some studies have shown increased ROM outcomes for those with tuberosity repair compared with those with resorption or excision.^{3,27} However, with rates of tuberosity migration, malunion, or resorption up to 50%, clinical outcomes in cases of tuberosity migration, malunion, or resorption may be similar to those of tuberosity excision.^{2,22} Another study showed tuberosity healing rates of 71%, with 57% in anatomic position and 14% in abnormal position.²⁵ In patients with poor tendon quality, pre-existing rotator cuff tears, and osteoporotic tuberosities, RTSA with tuberosity excision may be a reasonable option.

The twofold rationale for excising the tuberosities and extending the cement mantle above the level of the humeral shaft was to allow for immediate AROM and to possibly increase the support for the humeral implant and allow for immediate AROM. By extending the cement mantle to the proximal portion of the fracture site, there is increased rotational control and increased ability of the implant to resist torsional stress (Figs. 1-6). Because suture fixation of proximal cancellous and often osteopenic bone is not rigid, micromotion can potentially contribute to postoperative pain which could limit a patient's ability to tolerate early mobilization. Early AROM can potentially cause loss of fixation of the tuberosities

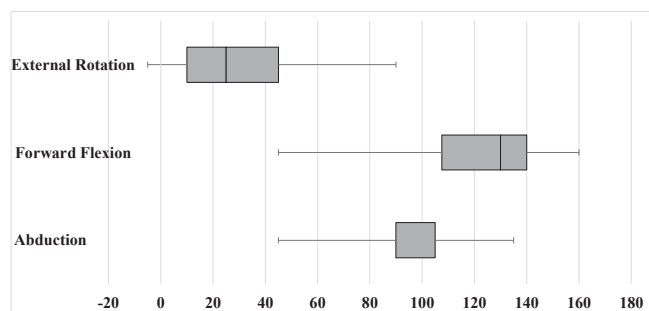


Figure 7 Boxplots of ROM at 24 months. ROM, range of motion.

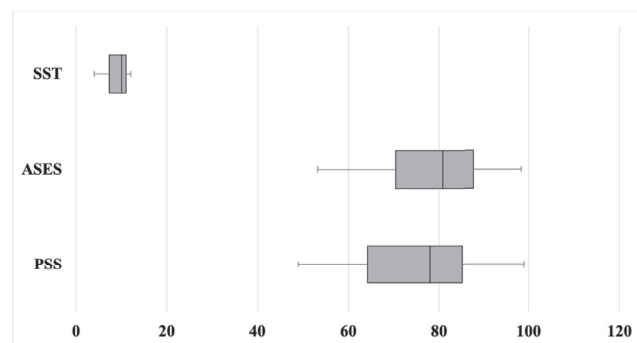


Figure 8 Boxplots of patient-reported outcomes at 24 months.

Table IV
Patient-reported outcome scores at 24 months.

Outcome score	N	Average	Standard deviation
SST	27	9.11	2.24
ASES	27	77.79	11.77
PSS	27	74.12	13.83

ASES, American Shoulder and Elbow Surgeons; PSS, Penn Shoulder Score; SST, Simple Shoulder Test.

when repaired. Excising the tuberosities allows for early mobilization without concerns for loss of tuberosity fixation or tuberosity pain. Early active mobilization after open shoulder surgery can potentially decrease the incidence of postoperative stiffness, increase ROM, and improve function.^{11,16} A potential advantage for the orthopedic surgeon whose practice may not include a high volume of operative proximal humerus fractures treated with reverse total shoulder is that tuberosity excision could be more predictable and expedient than tuberosity repair. Furthermore, implant longevity may benefit from the increased length of cement mantle with contact up to the calcar of the implanted stem.¹⁵ This might be preferred over a cement mantle covering only the distal two-third to one-half of the stem. Moreover, the repaired tuberosities heal to the bone of the humeral shaft but not to the proximal metal surface of the stem. Failure of tuberosity healing to the proximal exposed metal stem may compromise long-term stability of the humeral stem by increasing stress on the “shortened” cement mantle distally.

Our AROM measurements indicated averages of 125, 95, and 36 degrees of forward flexion, abduction, and external rotation, respectively, with internal rotation to the area of the iliac crest. A recent meta-analysis of 381 patients found tuberosity healing rates of 70.5% with AROM outcomes of 134.1 degrees forward flexion, 114.8 degrees of abduction, and 27.8 degrees of external rotation.¹⁷ In comparison with that data set, our data from patients undergoing tuberosity excision demonstrates lesser forward flexion and abduction with greater external rotation. Of the recent studies documenting ROM differences between tuberosity excision versus repair groups, there is a trend of decreased forward flexion ranging from 20 to 25 degrees, abduction deficits of approximately 20 degrees, and external rotation deficits of 10–20 degrees.^{1,2,17} Chun et al reported no significant difference in forward flexion and internal rotation in those with healed versus nonhealed tuberosities.⁷ Internal rotation is sparsely reported in the literature, and in the few articles that it is mentioned, the measurement is converted into a

scoring technique that is inconsistent across studies. Sheilds et al created an internal rotation scale based on the Constant-Murley score with an average of 4.0 points at two years postoperatively, demonstrating that patients could reach to about L3 on average.²⁵ Another study compared tuberosity repair with tuberosity excision and reported an average internal rotation to the sacrum with excision and L4 with tuberosity repair.¹² Much of the current literature cites improvement in forward flexion and external rotation with tuberosity fixation despite the risk of migration and nonunion.^{2,22,25}

However, there are little long-term data available regarding implant loosening that might occur because of limited proximal bonding between the metal implant and repaired tuberosities combined with a shortened distal cement mantle. In regards to ROM differences, specific postoperative rehabilitation protocols must also be considered. The orthopedic surgeon in this study allowed patients to begin AROM as tolerated within days after surgery, as the tuberosity excision did not necessitate protection to allow for the tuberosities to heal. This may have contributed to our finding of greater external rotation in our patients than in the previous studies with tuberosity repair.

Our mean outcome scores were 9.11, 77.79, and 74.12 averages for the SST, ASES, and PSS, respectively. Chun et al measured the average ASES score of 74.3 in those with healed tuberosities and 70.7 in those with tuberosity malunion, noting no statistical significance.⁷ Our cohort had similar ASES results to Chun et al, for their tuberosity repair group.⁷ A study in patients younger than 60 years with a mean age of 54 years old showed an average SST of 6.2 and ASES of 65.8.²⁴ Our cohort had higher SST and ASES scores despite their advanced age and tuberosity excision. However, the surgical indications for these younger patients were not exclusive to proximal humerus fractures.²⁴ Sheilds et al showed an average ASES score of 81 at two years postoperatively, with multiple indications for RTSA.²⁵ When compared with the final ASES measurements in this study, and considering the minimal clinically important difference of 6.2 points, it could be concluded that the difference between our studies would likely not be significant.^{25,26} Another study with RTSA and tuberosity repair noted an average ASES score of 65 when treating their cohort of patients with proximal humerus fracture.²⁸ Tuberosity repair may improve forward flexion and shoulder rotation; however, it may not provide superior enough improvement in ADLs for patients to notice a significant difference. Satisfactory clinical outcomes may still be achieved without tuberosity repair.

Our patients in this study did not have any dislocations or signs of instability. Two studies have demonstrated increased instability and/or dislocation rates in those with tuberosity excision when

compared with patients with tuberosity fixation.^{2,22} However, a recent retrospective observational study was unable to find a significant difference in complications in the tuberosity excision group when compared with the normal population.¹³ Few studies take into consideration the time between injury and surgery as a factor affecting dislocation rates, especially when comparing tuberosity repair versus excision. We think that surgical timing from injury may be an important factor because swelling in the early postinjury period may predispose these patients to later dislocation, by temporarily altering soft-tissue tension.

The shortened length of surgical time with tuberosity excision may also be an advantage for patients with multiple comorbidities. Our average surgical time was 131.58 minutes. Decreasing the operative time by excising instead of repairing the tuberosities may simplify the RTSA.

Our study is limited by our low sample size. It is possible that in the future, we may be able to further expand our patient cohort and report more representative data for both the ROM and clinical outcome score measurements. Our operating surgeon started tuberosity excision in 2014 and gained experience during this time period, which may have also biased our results. The switch between prostheses is another limitation. Differing neck shaft angles can impact stability and dislocation rates.²¹ However, we did not see that in our case series. Additionally, our data could have benefitted as a comparison between tuberosity repair, tuberosity excision, and nonoperative treatment groups. There are studies specific to proximal humerus fracture indications for RTSA that utilize the subjective shoulder value percentage which would have been a helpful measure for comparison in our cohort.^{2,22} The literature lacks data on PSS scores after RTSA with and without tuberosities and would benefit from further research in this area. More research comparing these groups may be necessary in the future to substantiate the ROM and clinical outcome differences that the tuberosity repair provides.

RTSA with tuberosity excision for proximal humerus fractures could be a reasonable option for those with pre-existing poor tendon quality, underlying arthritis, osteoporosis, and rotator cuff tears. It may also confer an improved option for those with surgically prohibitive comorbidities by decreasing the operative time required for repair. Decreased surgical complexity may benefit lower volume shoulder fracture surgeons as well. Many studies have shown that tuberosity excision may have lower forward flexion, abduction, and external rotation when compared with tuberosity repair groups.^{1,2,17} However, our data demonstrated higher external rotation. Perhaps this is due to early ROM exercises. Our cohort of patients had ASES and SST scores similar to RTSA with tuberosity repair when compared with the current literature. Additionally, surgical timing of 10–14 days after injury may have contributed to our absent dislocation rate. Longer term studies comparing implant loosening rates for tuberosity repair versus tuberosity excision may be a valuable area of future study.

Conclusion

In this study, we report on our patient population undergoing an RTSA with tuberosity excision for proximal humerus fractures. Our cohort of 41 patients undergoing RTSA and tuberosity excision showed favorable outcomes in both ROM and clinical outcomes categories. When compared with the literature, our ROM data were similar to those of previous studies with tuberosity excision and tuberosity migration.⁷ Our clinical scoring results were similar to several other studies that reported on tuberosity repair patients.^{7,24,28} We believe that tuberosity excision without repair can

result in positive clinical outcome scores. Therefore, tuberosity excision could be a reasonable and simpler surgical option for surgeons with lower volumes of operative shoulder fractures and patients with increased comorbidities and higher surgical risk.

Disclaimers

Funding: No funding was disclosed by the authors.

Conflicts of interest: The authors, their immediate families, and any research foundation with which they are affiliated have not received any financial payments or other benefits from any commercial entity related to the subject of this article.

References

- Anakwenze OA, Zoller S, Ahmad CS, Levine WN. Reverse shoulder arthroplasty for acute proximal humerus fractures: a systematic review. *J Shoulder Elbow Surg* 2014;23:e73–80. <https://doi.org/10.1016/j.jse.2013.09.012>.
- Boileau P, Alta TD, Decroocq L, Sirveaux F, Clavert P, Favard L, et al. Reverse shoulder arthroplasty for acute fractures in the elderly: is it worth reattaching the tuberosities? *J Shoulder Elbow Surg* 2019;28:437–44. <https://doi.org/10.1016/j.jse.2018.08.025>.
- Boileau P, Krishnan SG, Tinsi L, Walch G, Coste JS, Mole D. Tuberosity malposition and migration: reasons for poor outcomes after hemiarthroplasty for displaced fractures of the proximal humerus. *J Shoulder Elbow Surg* 2002;11:401–12. <https://doi.org/10.1067/jse.2002.124527>.
- Buquin T, Hersan A, Hubert L, Massin P. Reverse shoulder arthroplasty for the treatment of three- and four-part fractures of the proximal humerus in the elderly: a prospective review of 43 cases with a short-term follow-up. *J Bone Joint Surg Br* 2007;89:516–20. <https://doi.org/10.1302/0301-620X.89B418435>.
- Cadet ER, Ahmad CS. Hemiarthroplasty for three- and four-part proximal humerus fractures. *J Am Acad Orthop Surg* 2012;20:17–27. <https://doi.org/10.5435/jaaos-20-01-017>.
- Cazeneuve JF, Cristofari DJ. The reverse shoulder prosthesis in the treatment of fractures of the proximal humerus in the elderly. *J Bone Joint Surg Br* 2010;92:535–9. <https://doi.org/10.1302/0301-620X.92B4.22450>.
- Chun YM, Kim DS, Lee DH, Shin SJ. Reverse shoulder arthroplasty for four-part proximal humerus fracture in elderly patients: can a healed tuberosity improve the functional outcomes? *J Shoulder Elbow Surg* 2017;26:1216–21. <https://doi.org/10.1016/j.jse.2016.11.034>.
- Court-Brown CM, Garg A, McQueen MM. The epidemiology of proximal humeral fractures. *Acta Orthop Scand* 2001;72:365–71.
- Flatow EL, Harrison AK. A history of reverse total shoulder arthroplasty. *Clin Orthop Relat Res* 2011;469:2432–9. <https://doi.org/10.1007/s11999-010-1733-6>.
- Gaebler C, McQueen MM, CourtBrown CM. Minimally displaced proximal humeral fractures: epidemiology and outcome in 507 cases. *Acta Orthop Scand* 2003;74:580–5. <https://doi.org/10.1080/00016470310017992>.
- Gallagher BP, Bishop ME, Tjoumakaris FP, Freedman KB. Early versus delayed rehabilitation following arthroscopic rotator cuff repair: A systematic review. *Phys Sportsmed* 2015;43:178–87. <https://doi.org/10.1080/00913847.2015.1025683>.
- Gallinet D, Adam A, Gasse N, Rochet S, Obert L. Improvement in shoulder rotation in complex shoulder fractures treated by reverse shoulder arthroplasty. *J Shoulder Elbow Surg* 2013;22:38–44. <https://doi.org/10.1016/j.jse.2012.03.011>.
- Gallinet D, Cazeneuve JF, Boyer E, Menu G, Obert L, Ohl X, et al. Reverse shoulder arthroplasty for recent proximal humerus fractures: Outcomes in 422 cases. *Orthop Traumatol Surg Res* 2019;105:805–11. <https://doi.org/10.1016/j.otsr.2019.03.019>.
- Gallinet D, Clappaz P, Garbuio P, Tropet Y, Obert L. Three or four parts complex proximal humerus fractures: hemiarthroplasty versus reverse prosthesis: a comparative study of 40 cases. *Orthop Traumatol Surg Res* 2009;95:48–55. <https://doi.org/10.1016/j.otsr.2008.09.002>.
- Grogan B, Song DJ, Jobin CM. Cemented humeral shoulder arthroplasty: because it works! *Semin Arthroplasty* 2018;29:100–7. <https://doi.org/10.1053/j.sart.2018.10.009>.
- Hagen MS, Allahabadi S, Zhang AL, Feeley BT, Grace T, Ma CB. A randomized single-blinded trial of early rehabilitation versus immobilization after reverse total shoulder arthroplasty. *J Shoulder Elbow Surg* 2020;29:442–50. <https://doi.org/10.1016/j.jse.2019.10.005>.
- Jain NP, Mannan SS, Dharmarajan R, Rangan A. Tuberosity healing after reverse shoulder arthroplasty for complex proximal humeral fractures in elderly patients—does it improve outcomes? A systematic review and meta-analysis. *J Shoulder Elbow Surg* 2019;28:e78–91. <https://doi.org/10.1016/j.jse.2018.09.006>.

18. Jobin CM, Galdi B, Anakwenze OA, Ahmad CS, Levine WN. Reverse shoulder arthroplasty for the management of proximal humerus fractures. *J Am Acad Orthop Surg* 2015;23:190–201. <https://doi.org/10.5435/jaaos-d-13-00190>.
19. Kancherla VK, Singh A, Anakwenze OA. Management of acute proximal humerus fractures. *J Am Acad Orthop Surg* 2017;25:42–52. <https://doi.org/10.5435/JAAOS-D-15-00240>.
20. Neer CS II. Articular replacement for the humeral head. *J Bone Joint Surg Am* 1955;37:215–28.
21. Oh JH, Shin SJ, McGarry MH, Scott JH, Heckmann N, Lee TQ. Biomechanical effects of humeral neck-shaft angle and subscapularis integrity in reverse total shoulder arthroplasty. *J Shoulder Elbow Surg* 2014;23:1091–8. <https://doi.org/10.1016/j.jse.2013.11.003>.
22. Ohl X, Bonnevalle N, Gallinet D, Ramdane N, Valenti P, Decroocq L, et al. How the greater tuberosity affects clinical outcomes after reverse shoulder arthroplasty for proximal humeral fractures. *J Shoulder Elbow Surg* 2018;27:2139–44. <https://doi.org/10.1016/j.jse.2018.05.030>.
23. Roberson TA, Granade CM, Hunt Q, Griscom JT, Adams KJ, Momaya AM, et al. Nonoperative management versus reverse shoulder arthroplasty for treatment of 3- and 4-part proximal humeral fractures in older adults. *J Shoulder Elbow Surg* 2017;26:1017–22. <https://doi.org/10.1016/j.jse.2016.10.013>.
24. Sershon RA, Van Thiel GS, Lin EC, McGill KC, Cole BJ, Verma NN, et al. Clinical outcomes of reverse total shoulder arthroplasty in patients aged younger than 60 years. *J Shoulder Elbow Surg* 2014;23:395–400. <https://doi.org/10.1016/j.jse.2013.07.047>.
25. Shields E, Koueiter D, Wiater MJ. Rate of improvement in outcomes measures after reverse total shoulder arthroplasty: a longitudinal study with 2 year follow-up. *J Shoulder Elbow Arthroplasty* 2019;3:1–7. <https://doi.org/10.1177/2471549219861446>.
26. Werner BC, Chang B, Nguyen JT, Dines DM, Gulotta LV. What change in American Shoulder and Elbow Surgeons score represents a clinically important change after shoulder arthroplasty? [published correction appears in *Clin Orthop Relat Res*. 2017 Jan;475(1):293]. *Clin Orthop Relat Res* 2016;474:2672–81. <https://doi.org/10.1007/s11999-016-4968-z>.
27. Wretenberg P, Ekelund A. Acute hemiarthroplasty after proximal humerus fracture in old patients. A retrospective evaluation of 18 patients followed for 2–7 years. *Acta Orthop Scand* 1997;68:121–3.
28. Young SW, Segal BS, Turner PC, Poon PC. Comparison of functional outcomes of reverse shoulder arthroplasty versus hemiarthroplasty in the primary treatment of acute proximal humerus fracture. *ANZ J Surg* 2010;80:789–93. <https://doi.org/10.1111/j.1445-2197.2010.05342>.