

# Vesical schistosomiasis and squamous cell carcinoma associated with schistosoma haematobium: A re-emerging neglected tropical disease in Tehran, Iran

Leila Haghighi<sup>a</sup>, Mohsen Akbaribazm<sup>b,\*</sup>, Zahra Arab-Mazar<sup>c,d</sup>, Mohsen Rahimi<sup>e,\*</sup>

<sup>a</sup> Department of Parasitology and Mycology, School of Medicine, Iran University of Medical Sciences, Tehran, Iran

<sup>b</sup> Anatomical Sciences, Fertility and Infertility Research Center, Kermanshah University of Medical Sciences, Kermanshah, Iran

<sup>c</sup> Department of Medical Parasitology and Mycology, School of Public Health, Tehran University of Medical Sciences, Tehran, Iran

<sup>d</sup> Infectious Diseases and Tropical Medicine Research Center, Shahid Beheshti University of Medical Sciences, Tehran, Iran

<sup>e</sup> Department of Parasitology and Mycology, School of Medicine, Student Research Committee, Shahid Beheshti University of Medical Sciences, Tehran, Iran

## ARTICLE INFO

### Keywords:

Bladder biopsy  
Cystoscopy  
Re-emerging disease  
Squamous cell carcinoma  
Schistosoma haematobium

## ABSTRACT

Hematobium species of this parasite tends to bladder and mesenteric arteries and it causes lesions in the bladder wall, urethra, and renal tubes. A 25-year-old man living in Tehran (a non-endemic and very rare area for schistosoma) suffers from symptoms such as hematuria with suprapubic pain, dysuria, fever, nausea and vomiting. Urine analysis showed a lot of red blood cells, after using cystoscopy of the area and receiving a bladder biopsy, a definitive diagnosis of schistosomiasis was made and after determining the extent of damage to the urinary tract, appropriate treatment with surgery and praziquantel (40 mg/kg) were prescribed.

## Introduction

Schistosomiasis is a water borne parasitic infection and after malaria, the most common tropical diseases in the world. It is endemic in 5 developing countries and 2 million people, most of them in rural and suburban areas, have this parasitic infection.<sup>1</sup> There are two main human Schistosoma species in EMR (Eastern Mediterranean Region) countries, Schistosoma haematobium and Schistosoma mansoni. Schistosoma mansoni has been identified in 9 of the 23 and S. haematobium in 15 of the 23 the EMR countries (including Iran). In Iran, Khuzestan is the only province from which urogenital schistosomiasis have been reported. Of all the species of Schistosoma, S. haematobium was the only cause of the disease in this region.<sup>2</sup>

S. haematobium lives in the vessels surrounding the bladder. Clinical signs of the disease include acute hematuria, urinary pain, fever, diarrhea and nausea. In long-term and untreated disease, ultrasound and cystoscopy show bladder thickening and mass (cancer) in the bladder and even in the prostate. After the parasite release from the Bulinus snail enters the human skin, it enters the vessels around the bladder through the circulatory system and eventually adult worm's causes vesical schistosomiasis.<sup>3</sup>

## Case report

A 25-year-old man was admitted to a military hospital on 9-May-2019 with suprapubic pain, dysuria and hematuria. He was conscious with no history of surgery; BMI 22.5; Blood pressure 112/59 mm/Hg; Respiratory rate 18/minute; Pulse 70/minute and Temperature 36.8 °C. Blood sugar 113 mg/dL; hemoglobin 12.1 g/dL; WBC count 7700/mm<sup>3</sup> (3% eosinophilia), so many RBC and 5–10 WBC in urinary sediment.

The ultrasonography of the liver parenchyma, spleen, prostate and kidneys were normal; no dilatation in the pilocalix system. The bladder mucosa was slightly thick and irregular (4 mm); Cystoscopy showed four tumors in the bladder and chronic granulomatous cystitis (1.5 × 1 × 0.5 cm).

Histopathological examination confirmed S. haematobium (Male and Female) were found together on the bladder wall (Fig. 1) and calcified S. haematobium eggs (175–190 μm long by 30–45 μm wide) and eggs with terminal spine (160–180 μm long by 35–55 μm wide) could be seen in the section. Early active granulomas with intense inflammatory infiltration mainly of polymorphonuclear cells (most of which were eosinophils, neutrophils, macrophages giant cells (Langhan's giant cells) and lymphocytes), fibrosis and central necrosis were

\* Corresponding authors.

E-mail addresses: [L.haghighi@yahoo.com](mailto:L.haghighi@yahoo.com) (L. Haghighi), [Akbarimohsen64@gmail.com](mailto:Akbarimohsen64@gmail.com) (M. Akbaribazm), [Z.arabmazar@gmail.com](mailto:Z.arabmazar@gmail.com) (Z. Arab-Mazar), [Mohsen1rahimi@yahoo.com](mailto:Mohsen1rahimi@yahoo.com) (M. Rahimi).

<https://doi.org/10.1016/j.eucr.2020.101140>

Received 19 January 2020; Accepted 18 February 2020

Available online 21 February 2020

2214-4420/© 2020 Published by Elsevier Inc. This is an open access article under the CC BY-NC-ND license (<http://creativecommons.org/licenses/by-nc-nd/4.0/>).

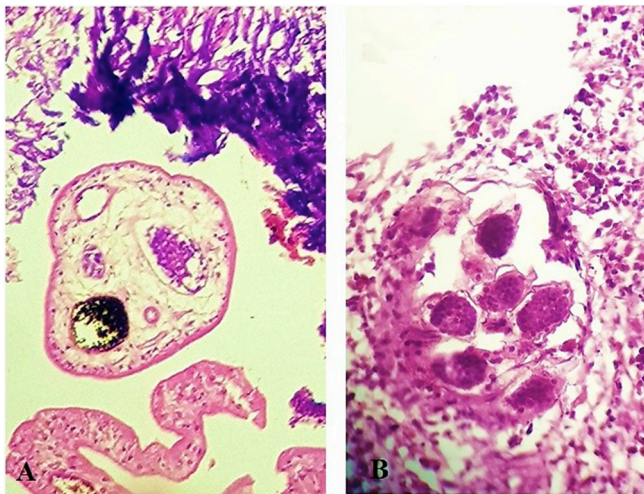


Fig. 1. (A) Adult *S. haematobium* in a urinary bladder biopsy specimen. (B) Calcification progress of the *S. haematobium* eggs.

present (Fig. 2A–F). During retrograde radiographic evaluations, thickening and linear calcification of the bladder and left unilateral dilation of the ureter were observed (Fig. 3).

Following treatment (surgery and oral dose of praziquantel 40 mg/kg (the patient was discharged with foley catheter for 7 days. After 6 weeks the patient stated that the suprapubic pain and dysuria had decreased and that blood was not seen in his urine, cystoscopy showed that the granulomatous lesion volume was significantly reduced and the bladder wall was normal.

**Discussion**

In Iran, the only city reported from schistosoma is Khuzestan and its counties. Although previous reports from Iran indicate that urinary schistosomiasis have been eradicated in Iran, other disorders, including transitional bladder cell carcinoma and schisto-granuloma of the fallopian tubes, have been reported from these areas. But given the endemic of the disease in Iraq, it is possible to report some cases in Iran due to the similarity of weather conditions in both countries. Reports indicate that the recommendations of the WHO over the past five decades have made

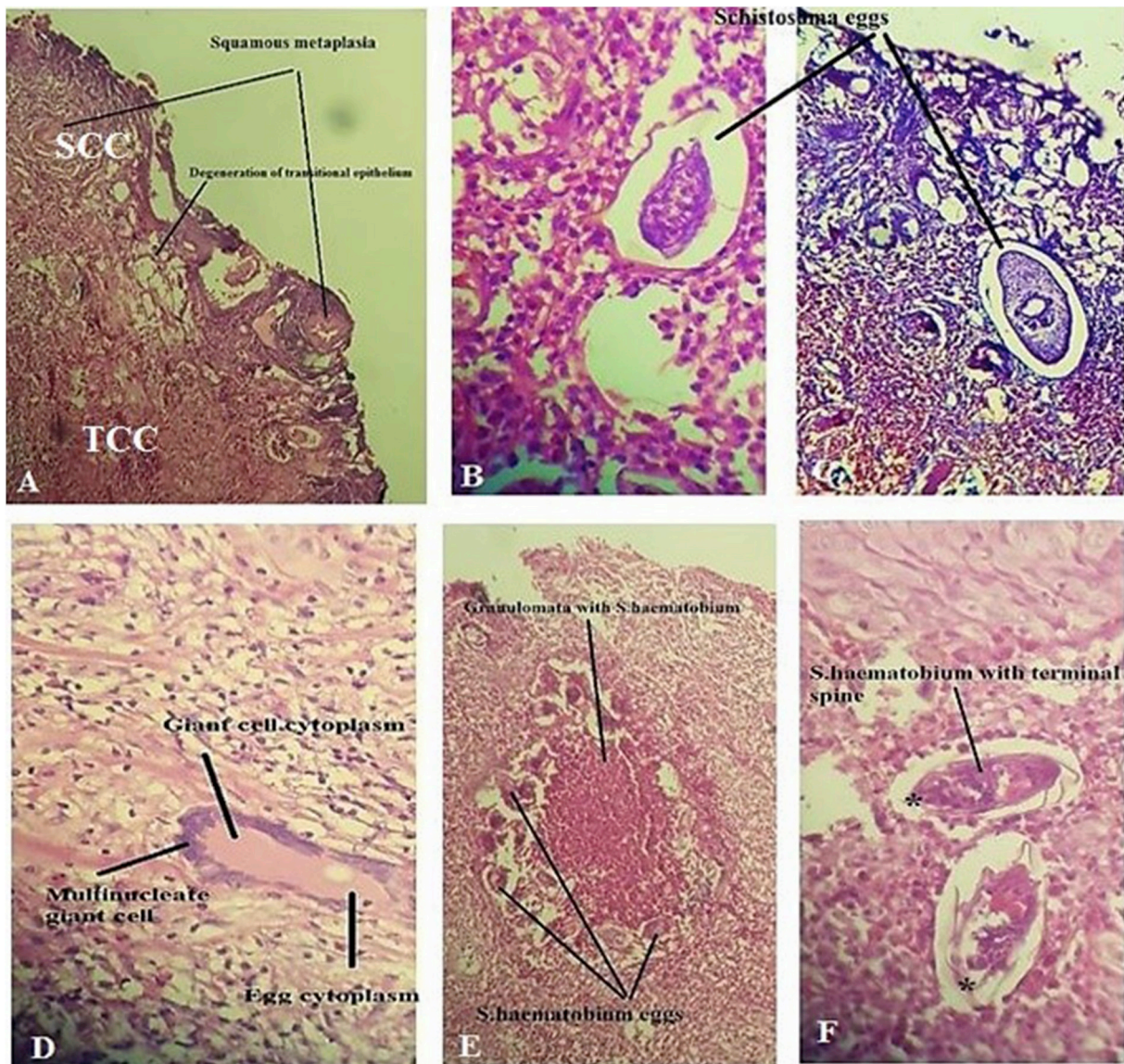
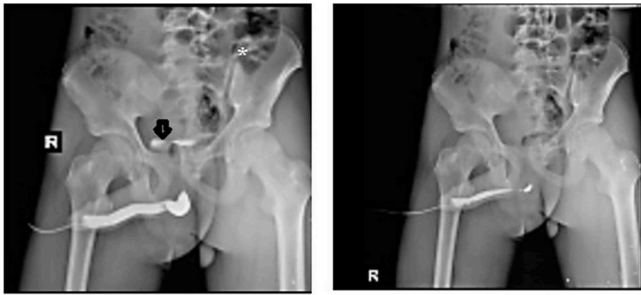


Fig. 2. (A) Squamous cell carcinoma (SCC) (superficial), transitional cell carcinoma (TCC) (in deeper layer). (B, C, and F) Calcified egg of *S. haematobium* in fibro muscular stroma of urinary bladder biopsy specimen with characteristic terminal spine (\*), (D) *S. haematobium* eggs surrounded by giant cells (Langhan's giant cells) displaying numerous nuclei arranged in horseshoe pattern found in granulomatous lesion. (E) Chronic fibrotic granuloma with central necrosis characterized by central epitheloid, foamy macrophages and presence of giant cells with many calcified eggs and cellular infiltration mainly of polymorphonuclear cells, most of which are eosinophils.





**Fig. 3.** Retrograde radiographic appearances in advanced urinary schistosomiasis: Linear calcifications of the urinary bladder (arrow) with left unilateral dilation of the ureter (\*).

it successful in controlling in EMR countries (including Iran).<sup>2</sup>

One of the strategies put forward by the WHO that has eradicated the disease in countries such as Lebanon, Tunisia, Morocco and Iran is the use of niclosamide molluscicide against snails (*B. truncatus*). In Iran, comprehensive programs (using a combination of chemotherapy with different anti-schistosomal drugs, snail control programs and environmental improvements) for the control of this disease have been running since the beginning of the year 1958. However, swimming in areas with snails (especially coastal areas of southern Iran) have reported cases of the disease. After being attached to the skin, the parasite larvae migrate to the liver and lungs and mature and develop into adult pelvic veins. The eggs then deposits into the wall of the bladder artery and in addition to the parasite's egg being found in the urine of the affected person, it causes acute inflammatory responses, granuloma formation, and also rarely cause metaplasia of the bladder epithelium resulting in squamous cell carcinoma.<sup>4</sup>

Laboratory findings, such as observation of parasitic eggs in the urine, white granuloma and nodular thickening of the bladder wall in acute phase, also fibrotic lesions associated with severe inflammation, ureteric dilatation and curvilinear calcifications with multiple calcified dead eggs, are seen along the bladder wall in chronic phase in cystoscopy, urography or contrast-enhanced computerised tomography help diagnose the disease. Today, depending on the patient, medical and surgical treatments are suggested. Praziquantel, the drug of choice against adult worms, cures 80–90% of patients with a 90% reduction in egg excretion. Some damage to the walls of the bladder, urethra and renal parenchyma tissue is not repaired and the patient is examined every 6 months to prevent recurrence of symptoms and complete parasite egg cleansing.<sup>5</sup>

#### Declaration of competing interest

None.

#### References

1. Colley DG, Bustinduy AL, Secor WE, King CH. Human schistosomiasis. *Lancet*. 2014; 383:2253–2264.
2. Hamidinia D, Maraghi S, Azimi F, Ai A, Shirian S. The role of climate on prevalence or eradication of vesical schistosomiasis in Khuzestan Province of Iran. *J Parasit Dis*. 2016;40:387–389.
3. Botelho MC, Alves H, Richter J. Halting *Schistosoma haematobium*-associated bladder cancer. *Int J Cancer Manag*. 2017;10:e9430.
4. Ahmed NS, Mahmoud Sf, Mohamed ER, Khalifa RM. Histopathological analysis of *Schistosoma haematobium* metaplasia of the urinary bladder. *J Egypt Soc Parasitol*. 2017;47:211–218.
5. Vale N, Gouveia MJ, Rinaldi G, Brindley PJ, Gärtner F, da Costa JM. Praziquantel for schistosomiasis: single-drug metabolism revisited, mode of action, and resistance. *Antimicrob Agents Chemother*. 2017;61. e02582-1.