

Intraplental choriocarcinoma and fetomaternal haemorrhage and maternal disseminated intravascular coagulopathy in a term pregnancy: A case report

B. Hookins*, A. Vatsayan

Hornsby Kuringai Hospital, Northern Sydney Local Health District, Sydney, Australia.

ARTICLE INFO

Article history:

Received 13 April 2020

Received in revised form 3 May 2020

Accepted 5 May 2020

Keywords:

Choriocarcinoma

Fetomaternal haemorrhage

Neonatal anaemia

Disseminated intravascular coagulopathy

ABSTRACT

Background: Intraplental choriocarcinoma (ICC) is a rare form of gestational trophoblastic disease that has been documented as complicating near-term pregnancies with massive fetomaternal haemorrhage (FMH), intrauterine fetal demise, neonatal anaemia, and disseminated disease of both mother and child.

Case: A 31-year-old woman at 38 weeks of gestation underwent caesarean section due to reduced fetal movements. The caesarean section was complicated by disseminated intravascular coagulopathy (DIC). Massive FMH and choriocarcinoma were diagnosed after delivery.

Discussion: Review of the literature demonstrated this to be the first published case of DIC associated with choriocarcinoma, a rare complication. The literature suggests post-partum serial measurement of beta human chorionic gonadotropin (β -HCG) in women with unexplained massive FMH. This case demonstrates the potential to reduce morbidity and mortality by earlier diagnosis of choriocarcinoma by means of surveillance of serial β -HCG levels in patient and child.

Outcome: The patient underwent 4-agent chemotherapy after methotrexate alone failed to achieve remission. β -HCG levels were undetectable at the time of publishing this case report and the child is healthy with no complications.

© 2020 Published by Elsevier B.V. This is an open access article under the CC BY-NC-ND license (<http://creativecommons.org/licenses/by-nc-nd/4.0/>).

1. Background

Choriocarcinoma is a rare malignancy. It is a form of gestational trophoblastic disease usually arising in the placenta. Choriocarcinoma discovered following delivery of the fetus is the rarest form of the disease, with the majority of disease discovered after molar pregnancies or early miscarriages. A few cases have been identified in the antenatal period, associated with unusually elevated levels of biochemical markers, or due to fetal growth abnormalities or fetal distress. Massive fetomaternal haemorrhage (FMH) has been described in case reports as being secondary to intraplental choriocarcinoma (ICC). There have been no published case reports of an ICC associated with massive FMH and maternal disseminated intravascular coagulopathy (DIC).

2. Case Presentation

At 38 weeks and 1 day of gestation, a 31-year-old woman, G1P0000, presented to the antenatal clinic with reduced fetal movements. The patient had reported reduced movements twice in the fortnight leading up to her presentation to the clinic. She had no significant past medical

history and had an uncomplicated pregnancy with normal antenatal investigations. Fetal cardiotocography was commenced as per local guidelines, and an abnormal heart rate pattern was demonstrated, consisting initially of absent variability with broad shallow decelerations, and later a sinusoidal pattern, without the presence of uterine activity (Fig. 1).

An emergency caesarean section was performed within 3 h and a 3.05 kg live male was born with APGAR scores of 8, 7, 6 at one minute, five minutes and ten minutes respectively. The neonate was pale and had significant anaemia with an initial haemoglobin of 47 g/L. Flow cytometric analysis of maternal blood demonstrated an FMH with 3.14% of red blood cells detected, the equivalent of 69 mL of packed fetal red blood cells. The newborn required blood transfusion and admission to the special-care nursery.

The estimated blood loss at caesarean section was 500 mL, and the pre-operative haemoglobin level was 127 g/L. Two hours following the caesarean section the patient's systolic blood pressure was noted to be 70 mmHg, and she was given a 500 mL intravenous fluid bolus of normal saline. Coagulation studies were immediately performed demonstrating an acute disseminated intravascular coagulopathy with a prothrombin time of 45.4 s, an international normalised ratio of 3.3, APTT of 54.7 s, and a fibrinogen level of 0.24 g/L. A massive transfusion protocol was initiated to treat the DIC with the patient receiving 5 units of packed red blood cells, 26 units of cryoprecipitate, 6 units of fresh

* Corresponding author.

E-mail address: brodie.hookins@health.nsw.gov.au (B. Hookins).

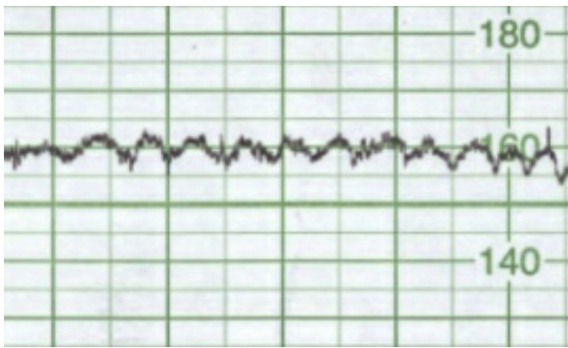


Fig. 1. Cardiocography from the patient, demonstrating a sinusoidal pattern.

frozen plasma, and 1 unit of platelets. The patient was taken back to theatre for insertion of a Bakri balloon. The total estimated blood loss was 2400 mL. The patient was admitted to the intensive care unit for post-operative management, and discharged home on post-operative day 6. Initial histopathological examination of the placenta was normal.

The patient presented to the emergency department twice within three weeks following her discharge from hospital with vaginal bleeding. The patient was initially managed for post-partum endometritis and commenced on oral antibiotics. At three weeks post-partum the patient underwent hysteroscopy with dilation and curettage of the uterus due to persistent vaginal bleeding. Histopathology from the curetting demonstrated expected post-partum endometrial changes. However, her serum beta human chorionic gonadotropin (β -HCG) level on the day of hysteroscopy was $>1,000,000$ U. On request, the placenta was re-examined by the pathology department which demonstrated a histological diagnosis of ICC. The lesion was measured at 11 mm and was characterised by proliferation of markedly abnormal and pleomorphic cytotrophoblasts and syncytiotrophoblasts on villous surface with extensive necrosis. Mitoses including atypical forms were present. It was seen focally in the villous stroma and in a villous capillary.

The patient was transferred to the medical oncology team. A computed tomography scan of her chest, abdomen and pelvis four weeks post-partum demonstrated a large soft-tissue mass distending the uterine cavity, with possible extension into the right adnexa, without evidence of distant metastatic disease (Fig. 2). The patient was commenced on methotrexate therapy and serum β -HCG levels were monitored. Although the β -HCG level initially decreased appropriately,

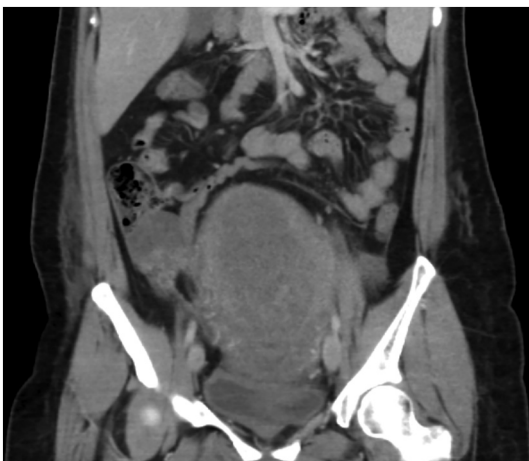

Fig. 2. Abdominal computed tomography (CT) scan demonstrating a large soft-tissue mass distending the uterus.

the level began to rise after seven weeks of methotrexate therapy. The patient was therefore commenced on a regime of topotecan, dacarbazine, methotrexate, cyclophosphamide, and vincristine. At the time of publishing this case report her β -HCG level was undetectable and her child was healthy with no complications.

3. Discussion

ICC is a rare complication of pregnancy, with an estimated incidence of 1/50,000 pregnancies [1]. Case reports have described the association between ICC and massive FMH, intrauterine fetal demise, neonatal death secondary to severe fetal anaemia, and metastatic choriocarcinoma of both the mother and the infant [2–5]. This is the first case report in the literature which describes not only a massive FMH in a term fetus with post-partum metastatic choriocarcinoma, but of the immediate complication of DIC.

Currently there have been no published studies or case reports that demonstrate the connection between massive FMH and DIC. In the obstetric and gynaecology literature, DIC has been noted to occur secondary to intrauterine fetal demise, and other obstetric conditions such as acute fatty liver disease of pregnancy, pre-eclampsia, and amniotic fluid embolism [6]. The current understanding of DIC is that it involves dysregulation of the coagulation cascade, and in an obstetric population can be caused by cancer, surgery, placental abruption, or transfusion reaction, to name a few. A known mediator of dysregulation of the coagulation cascade is release of tissue factor (TF), which is known to be highly expressed in the placenta and amniotic fluid [7]. It is difficult to ascertain the precise cause of DIC in the presented case. It is likely to be a combination of the massive FMH, emergency caesarean section, choriocarcinoma and release of triggers such as tissue factor. In this case the DIC was managed quickly and responded positively with standard massive transfusion protocols and replacement of coagulation factors.

Previous case reports have shown that in the presence of unexplained massive FMH, careful histopathological examination of the placenta occasionally reveals ICC [4,8–13]. In this case report, and in previous case reports, the histological diagnosis of ICC was made only upon careful re-examination of the placenta by the pathology service [1,9]. This may be due to the finding that ICC can represent only a small section of the placental tissue and is not always macroscopically evident and can be missed if the diagnosis is not specifically sought. In this case, the placenta was initially examined without discovery of ICC. The placenta was re-examined following a presumed diagnosis of gestational trophoblastic disease due to persistent vaginal bleeding and the significantly elevated β -HCG level. This case highlights the limitations of reliance on placental histopathology for diagnosis of ICC. The lesion in this case measured only 11 mm and represented only a small fraction of the total size of the placenta, which could easily be missed when routine sectioning and staining of the placenta is performed. A learning point from this case is that other means of diagnosis, such as serial surveillance of β -HCG levels, may be more productive than reliance on placental histopathology.

In previous case reports, it has been suggested that post-partum serial β -HCG levels should be measured in the mother and child if there has been a massive FMH [11,12,14–16]). This has been suggested due to the accumulating number of case reports of ICC as the cause of the unexplained massive FMH and the utility of using β -HCG to aid in the differential diagnosis. Although no studies have been performed to demonstrate a reduction in morbidity or mortality with the use of surveillance of β -HCG levels, it does seem reasonable that the early diagnosis of choriocarcinoma may reduce the complications due to metastatic spread of the disease in both mother and child. There is a published case report that demonstrates successful subsequent pregnancy following timely management of ICC [17]. In the presented case, earlier detection of ICC may have decreased tumour burden and so reduced the length of

treatment, and possibly avoided the need for second-line chemotherapy agents; however, this is not certain.

In conclusion, this case is an important example of the need to highlight the rare, but potentially devastating condition, of choriocarcinoma. It demonstrates the need to be aware of the potential for ICC as the cause for unexplained massive FMH, as well as the importance of post-partum BHCG surveillance for the woman and child. This case has also demonstrated the potential association between ICC, massive FMH and the development of acute DIC.

Contributors

B Hookins drafted the case report.

A Vatsayan provided guidance and supervision in writing the case report.

Conflicts of Interest

The authors declare that they have no conflict of interest regarding the publication of this case report.

Funding

No funding from an external source supported the publication of this case report.

Patient Consent

Obtained.

Provenance and Peer Review

This case report was peer reviewed.

Acknowledgements

The authors acknowledge the patient and her family in allowing us to present the case.

References

- [1] L. Jiao, et al., Intraplental choriocarcinoma: systematic review and management guidance, *Gynecol. Oncol.* 141 (3) (2016) 624–631.
- [2] A.E. Andreitchouk, et al., Choriocarcinoma in infant and mother: a case report, *J. Obstet. Gynaecol. Res.* 22 (6) (1996) 585–588.
- [3] K. Aso, et al., Prenatal findings in a case of massive fetomaternal hemorrhage associated with intraplental choriocarcinoma, *Fetal Diagn. Ther.* 25 (1) (2009) 158–162.
- [4] A.J. Duleba, et al., Expectant management of choriocarcinoma limited to placenta, *Gynecol. Oncol.* 44 (3) (1992) 277–280.
- [5] H. Fox, R.N. Laurini, Intraplental choriocarcinoma: a report of two cases, *J. Clin. Pathol.* 41 (10) (1988) 1085–1088.
- [6] M. Montagnana, et al., Disseminated intravascular coagulation in obstetric and gynecologic disorders, *Semin. Thromb. Hemost.* 36 (4) (2010) 404–418.
- [7] F.G. Cunningham, D.B. Nelson, Disseminated intravascular coagulation syndromes in obstetrics, *Obstet. Gynecol.* 126 (5) (2015) 999–1011.
- [8] A.K. Henningsen, et al., Massive fetomaternal hemorrhage caused by an intraplental choriocarcinoma: a case report, *Case Rep. Med.* 2010 (2010) 767218.
- [9] H.T. Nagel, et al., Intraplental choriocarcinoma as an unexpected cause of intrauterine death at term, *Int. J. Gynecol. Cancer* 17 (6) (2007) 1337–1339.
- [10] M. Santamaria, et al., Transplental hemorrhage associated with placental neoplasms, *Pediatr. Pathol.* 7 (5–6) (1987) 601–615.
- [11] Q. She, et al., Intraplental choriocarcinoma coexisting with fetomaternal hemorrhage: case report, chemotherapy management, and literature review, *Medicine (Baltimore)* 97 (14) (2018), e9977.
- [12] H. Takahashi, et al., Intraplental choriocarcinoma with fetomaternal hemorrhage: a case study and literature review, *J. Perinat. Med.* 36 (2) (2008) 178–181.
- [13] N. Takai, et al., Intraplental choriocarcinoma with fetomaternal transfusion, *Pathol. Int.* 50 (3) (2000) 258–261.
- [14] M.E. Blohm, U. Gobel, Unexplained anaemia and failure to thrive as initial symptoms of infantile choriocarcinoma: a review, *Eur. J. Pediatr.* 163 (1) (2004) 1–6.
- [15] J.G. Hensley, B.A. Shviraga, Metastatic choriocarcinoma in a term pregnancy: a case study, *MCN Am. J. Matern. Child Nurs.* 39 (1) (2014) 8–15(quiz 16–7).
- [16] M. Mangla, et al., Unusual clinical presentations of choriocarcinoma: a systematic review of case reports, *Taiwan J. Obstet. Gynecol.* 56 (1) (2017) 1–8.