

Recovery from hemidiaphragmatic paralysis with improved respiratory function following cervical laminoplasty and foraminotomy: illustrative case

Kazushi Kitamura, MD, Hideki Hayashi, MD, PhD, Ryota Ishibashi, MD, and Hiroki Toda, MD, PhD

Department of Neurosurgery, Tazuke Kofukai Medical Research Institute and Kitano Hospital, Osaka, Japan

BACKGROUND Hemidiaphragmatic paralysis can occasionally be caused by cervical canal and foraminal stenosis. Rarely is the effect of surgical decompression on hemidiaphragmatic paralyzed patient respiratory function recorded. This report details a case of postoperative respiratory function restoration in a patient with cervical spondylosis-related hemidiaphragmatic paralysis.

OBSERVATIONS A 77-year-old woman suffered hemidiaphragmatic paralysis caused by cervical canal and foraminal stenosis. The phrenic nerve palsy was thought to be caused by compression of the cervical spinal cord and its nerve root. The patient received a C3 laminectomy, a C4–6 laminoplasty, and a left C3–4 and C4–5 posterior foraminotomy. After surgery, she improved her maximum inspiratory pressure and respiratory function.

LESSONS Cervical canal and foraminal stenosis may cause hemidiaphragmatic paralysis due to radiculopathy-induced phrenic nerve palsy. Laminoplasty and posterior foraminotomy can restore respiratory dysfunction related to diaphragmatic paralysis by decompressing the ventral horn of the spinal cord and spinal nerve root.

<https://thejns.org/doi/abs/10.3171/CASE22282>

KEYWORDS diaphragmatic paralysis; cervical foraminal stenosis; exoscope; respiratory function

Hemidiaphragmatic paralysis may occur from direct trauma and phrenic nerve damage due to an adjacent tumor, neuropathy, inflammation, or iatrogenic procedure.¹ Cervical spondylosis is a rare cause of phrenic nerve palsy and hemidiaphragmatic paralysis.² We encountered a woman with cervical spondylosis with foraminal stenosis who experienced symptomatic hemidiaphragmatic paralysis. The patient received cervical laminoplasty and foraminotomy using an exoscope.

Illustrative Case

History

A 77-year-old woman experienced numbness in both arms and hands with hand clumsiness for a few years. Two months before her presentation to our hospital, the patient had difficulty raising her left arm. In addition, she developed dyspnea on exertion. Her medical history included hypertension and diabetes mellitus. She

had undergone carpal tunnel release for right carpal tunnel syndrome 15 years earlier. Additionally, the patient had undergone a right C6–7 uncovertebrectomy for right cervical radiculopathy 10 years earlier. She had a history of smoking 20 cigarettes per day until 17 years earlier.

Examination

The patient had left arm weakness. Her Medical Research Council grades were 3/5, 4/5, and 4/5 for the left deltoid, left biceps, and left triceps, respectively. The bilateral biceps and brachioradialis reflexes and right triceps reflex were diminished. Dysesthesia was observed in the bilateral C5–7 dermatome. The gait was spastic.

Cervical computed tomography (CT) revealed left C3–4 and C4–5 foraminal stenosis due to osteophytes (Fig. 1A and B). Magnetic resonance imaging (MRI) demonstrated significant compression of the cervical spinal cord at C3–6, most prominent at C3–4. The left C4

ABBREVIATIONS CT = computed tomography; MEP = maximal expiratory pressure; MIP = maximal inspiratory pressure; MRI = magnetic resonance imaging; 3D = three-dimensional; 4K = high-definition.

INCLUDE WHEN CITING Published October 10, 2022; DOI: 10.3171/CASE22282.

SUBMITTED June 29, 2022. **ACCEPTED** September 6, 2022.

© 2022 The authors, CC BY-NC-ND 4.0 (<http://creativecommons.org/licenses/by-nc-nd/4.0/>).

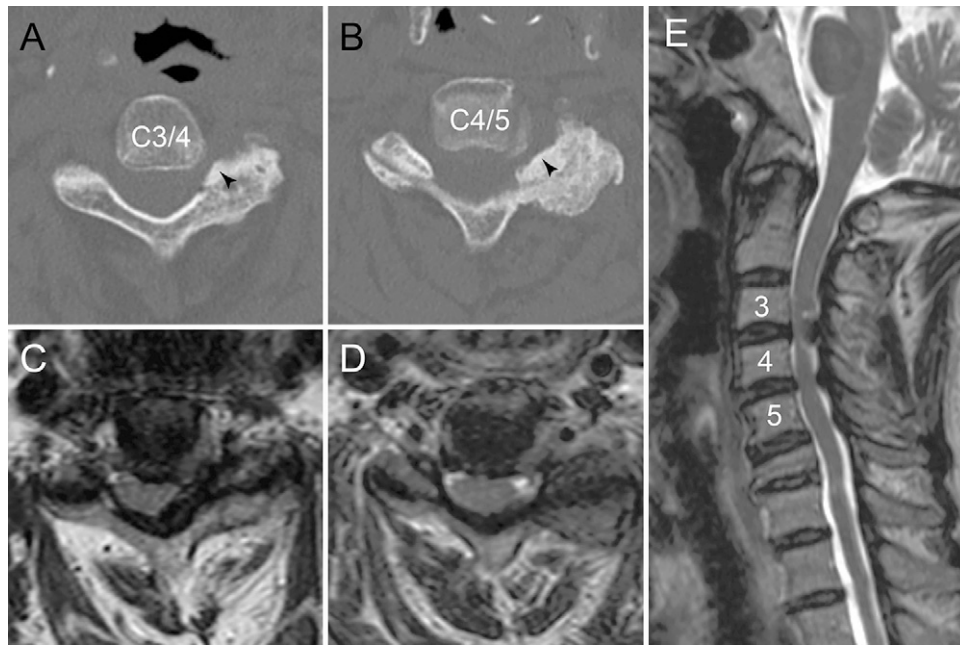


FIG. 1. Preoperative cervical CT shows foraminal stenosis at the C3–4 (A) and C4–5 levels (B) due to excessive osteophytes (arrowheads). The spinal nerve roots and spinal cord are compressed in the corresponding axial (C and D) and sagittal (E) MRI.

nerve root was compressed due to the thickening of the facet at the left C3–4 foraminal space (Fig. 1C–E).

An inspiration chest radiograph showed elevation of the left dome of the diaphragm (Fig. 2A). Pulmonary function tests using a spirometer (DISCOM 21FXIII, Chest MI) demonstrated respiratory dysfunction. The values of respiratory function parameter (percentage predicted values) were as follows: vital capacity, 1.63 L (76.5%); tidal volume, 0.38 L; and forced vital capacity, 1.56 L (78.8%). These values also comprised forced expiratory volume in 1 second (0%, 71.79% (91.3%); maximal inspiratory pressure (MIP), 38.6 cm H₂O (78.9%); and maximal expiratory pressure (MEP), 53.2 cm H₂O (78.7%).

The patient was diagnosed with cervical spondylotic myelopathy and left C4 and C5 radiculopathy, which induced hemidiaphragmatic paralysis.

Operation

The patient received C3 laminectomy, C4–6 open-door laminoplasty, C2 and C7 dome laminectomy, and left C3–4 and C4–5 posterior foraminotomy under a high-definition (4K) three-dimensional (3D) exoscope orbital camera system (ORBEYE, Olympus; Fig. 3A). The foraminotomy decompressed the left C4 and C5 nerve root sleeves (Fig. 3B).

Postoperative Course

After the operation, symptoms of hand clumsiness, spastic gait disturbance, and dyspnea improved. Postoperative cervical CT (Fig. 3C and D) and MRI (Fig. 3E and F) revealed an expansion of the cervical spinal canal and left C3–4 and C4–5 foraminal spaces. Chest radiography 1 week after the operation showed improvement in the left diaphragm paralysis (Fig. 2B). Respiratory

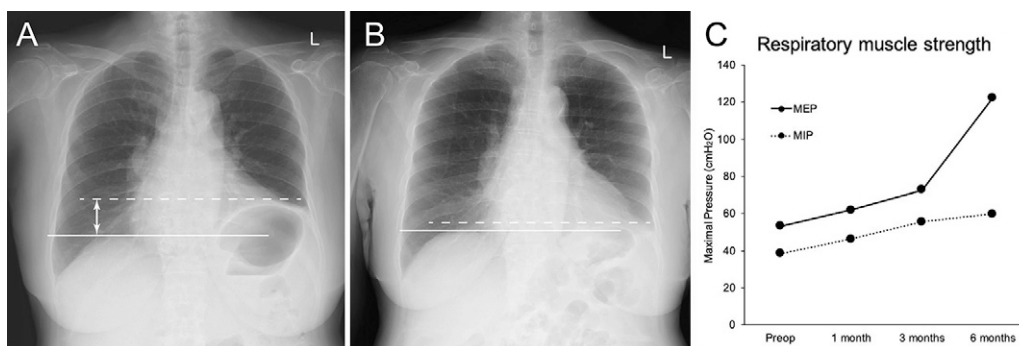


FIG. 2. A: Preoperative inspiration chest radiograph shows that the left diaphragm (dashed line) is elevated (double arrow) in comparison to the right diaphragm (solid line). B: The left diaphragm elevation has resolved on postoperative inspiration chest radiograph. C: Respiratory muscle strength graph showing that compared to the preoperative condition (preoperative), respiratory muscle strength increased at 1, 3, and 6 months after surgery.

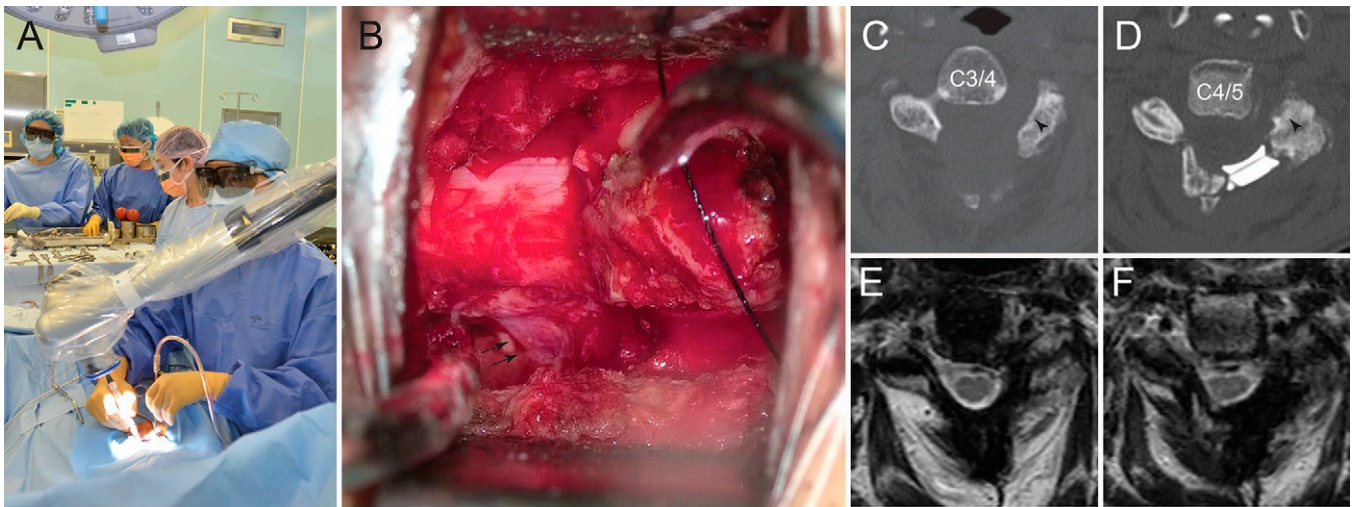


FIG. 3. Overview of foraminotomy using an exoscope in look-up surgery (A). After a foraminotomy, the C4 nerve root is exposed in an intraoperative view (B). Postoperative CT demonstrating C3 laminectomy (C), C4 laminoplasty (D), and foraminotomy (arrowheads). MRI reveals decompression of the spinal nerve roots and spinal cord at the C3 (E) and C4 (F) levels.

function recovery was confirmed using a spirometer at 1, 3, and 6 months after surgery. The MIP and MEP recovered well postoperatively. The MIP values (percentage predicted values) at 1 month, 3 months, and 6 months postoperatively were 46.4 cm H₂O (94.9%), 55.7 cm H₂O (113.9%), and 59.8 cm H₂O (124.1%), respectively (Fig. 2C). Similarly, MEP values were 62.0 cm H₂O (91.7%), 72.7 cm H₂O (107.5%), and 122.3 cm H₂O (181.7%), respectively.

Discussion

Observations

Cervical spondylosis is a rare cause of hemidiaphragmatic paralysis.²⁻⁴ A literature search identified seven cases of hemidiaphragmatic paralysis related to cervical spondylosis⁵⁻¹¹ (Table 1). These patients had dyspnea with motor and sensory symptoms from cervical myelopathy and radiculopathy.^{5-7,9-11} A case that solely exhibits dyspnea and

TABLE 1. Literature review of cases of hemidiaphragmatic paralysis in patients with cervical spondylosis

Authors & Year	Age (yrs)/Sex	Diaph Side	Weakness/Pain/Dyspnea	Canal/Foraminal Stenosis	Surgery	Time to Diaph Recovery	FU
Hayashi et al., 2005 ⁹	64/M	Lt	Rt C5, lt C5-7/ lt C4/Y	C2-3/NA	C3-7 lam	6 wks	2 yrs
Weiss et al., 2011 ⁵	59/M	Lt	NA/lt arm/NA	NA/lt C2-3, C3-4	C2-3, 3-4 foram	~10 mos	10 mos
Yu et al., 2016 ¹⁰	82/M	Rt	UE/bilat UE/Y	C2-7/NA	C2-6 lam & fusion	Gradual relief	12 mos
Singleton et al., 2018 ⁶	64/M	Rt	Rt UE/NA/Y	NA/rt C3-4, C4-5	C3-4, 4-5 foram	~3 mos	3 mos
Manabe et al., 2018 ⁷	70/M	Rt	Bilat deltoid, rt biceps/Rt C5/ NA	C3-4/rt C3-4, lt C4-5	Rt C3-4, lt C4-5 foram, C2-5 fusion	2 wks	2 yrs
Park et al., 2020 ⁸	59/M	Rt	None/none/Y	None/rt C3-4, C4-5	C3-4, 4-5 foram	3 mos	3 mos
Durand & Daniels, 2020 ¹¹	50/M	Rt	None/shoulder/Y	NA/rt C3-4	C3-4 ACDF	Resolved, not specified	NA
Present case	77/F	Lt	Bilat UE/ bilat UE/Y	C3-6/rt C3-4, C4-5	C3-6 lam, C3-4, 4-5 foram	1 wk	6 mos

ACDF = anterior cervical discectomy and fusion; bilat = bilateral; diaph = hemidiaphragmatic paralysis; foram = foraminotomy; FU = follow up; lam = laminoplasty or laminectomy; NA = not available; UE = upper extremity; Y = yes; ~ = within.

no other accompanying spinal symptoms may create a diagnostic challenge.⁸

In these cases, as well as the present case, phrenic nerve palsy is considered to cause hemidiaphragmatic paralysis. The phrenic nerve originates mostly from the C4 nerve root but also occasionally from the C3 and C5 nerve root; hence, spinal nerve root compression at the C4 level, and maybe at the C3 and C5 levels, is the cause of phrenic nerve palsy.¹² Phrenic nerve palsy may also result from compression of the spinal cord's ventral horn cells.^{9–11}

It is challenging to pinpoint the precise location of the stenotic lesion that is causing the phrenic nerve palsy. In most of these instances, the cervical canal and numerous levels of the cervical foramina developed spondylotic stenosis. As a result, some patients had multilevel foraminotomies^{5–8} and cervical laminoplasty with foraminotomy.^{7,9,10} It is advised to decompress both the spinal nerve roots consisting of the phrenic nerve and the ventral horn cells of the spinal cord to cover the potential pathogenetic regions. The posterior foraminotomy frequently necessitates the angled surgical trajectory. A 4K 3D exoscope,¹³ like other surgical illumination modalities, is suitable for such observation in a constrained surgical field.¹⁴

In our patient, hemidiaphragmatic paralysis resolved postoperatively within a week, and respiratory muscle strength improved concurrently. Repeated chest radiography¹⁵ and spirometry² demonstrated recovery from hemidiaphragmatic paralysis and improved respiratory function following surgery. Repeated MIP and MEP readings on the spirometry indicated that the respiratory muscle strength had recovered. The MEP measures that for the chest and abdominal wall whereas MIP measures a mobility index for the diaphragm (Fig. 2C). Therefore, the overall respiratory function may benefit from hemidiaphragmatic paralysis recovery.

In the reported cases, it took between 2 weeks and 10 months after surgery to recover respiratory function.^{5–11} A continuing recovery and rehabilitation program may be required because some patients need more time to regain their respiratory function.

Lessons

Although a single case report limits the significance of the observations, the lesson is that cervical canal and foraminal stenosis may cause hemidiaphragmatic paralysis due to radiculopathy-induced phrenic nerve palsy. Laminoplasty and posterior foraminotomy can restore respiratory dysfunction related to diaphragmatic paralysis by decompressing the ventral horn of the spinal cord and spinal nerve root.

Acknowledgments

We would like to thank Editage for English language editing.

References

1. O'Toole SM, Kramer J. Unilateral diaphragmatic paralysis. Accessed May 14, 2022. <https://www.ncbi.nlm.nih.gov/books/NBK557388/>.
2. McCool FD, Tzelepis GE. Dysfunction of the diaphragm. *N Engl J Med*. 2012;366(10):932–942.
3. Abbed KM, Coumans JV. Cervical radiculopathy: pathophysiology, presentation, and clinical evaluation. *Neurosurgery*. 2007;60 (suppl 1):S28–S34.
4. O'Beirne SL, Chazen JL, Cornman-Homonoff J, Carey BT, Gelman BD. Association between diaphragmatic paralysis and ipsilateral cervical spondylosis on MRI. *Lung*. 2019;197(6):727–733.

5. Weiss C, Witt T, Grau S, Tonn JC. Hemidiaphragmatic paralysis with recurrent lung infections due to degenerative motor root compression of C3 and C4. *Acta Neurochir (Wien)*. 2011;153(3): 597–599.
6. Singleton N, Bowman M, Bartle D. Resolution of right hemidiaphragm paralysis following cervical foraminotomies. *Case Rep Orthop*. 2018;2018:6195179.
7. Manabe H, Sakai T, Tezuka F, et al. Hemidiaphragmatic paralysis due to cervical spondylosis: a case report. *Spine Surg Relat Res*. 2018;3(2):183–187.
8. Park HY, Kim KW, Ryu JH, Lim CR, Han SB, Lee JS. Cervical foraminal stenosis causing unilateral diaphragmatic paralysis without neurologic manifestation: a case report and review of the literature. *Medicine (Baltimore)*. 2020;99(37):e21349.
9. Hayashi H, Kihara S, Hoshimaru M, Hashimoto N. Diaphragmatic paralysis caused by cervical spondylosis. Case report. *J Neurosurg Spine*. 2005;2(5):604–607.
10. Yu E, Romero N, Miles T, Hsu SL, Kondrashov D. Dyspnea as the presenting symptom of cervical spondylotic myelopathy. *Surg J (NY)*. 2016;2(4):e147–e150.
11. Durand WM, Daniels AH. C4 root compression leads to phrenic nerve palsy with shortness of breath, chest pain, and elevated hemidiaphragm. *Lancet*. 2020;396(10257):1101.
12. Mendelsohn AH, Deconde A, Lambert HW, et al. Cervical variations of the phrenic nerve. *Laryngoscope*. 2011;121(9):1920–1923.
13. Siller S, Zoellner C, Fuetsch M, Trabold R, Tonn JC, Zausinger S. A high-definition 3D exoscope as an alternative to the operating microscope in spinal microsurgery. *J Neurosurg Spine*. Published online July 10, 2020. doi: 10.3171/2020.4.SPINE20374.
14. Kihara S, Umabayashi T, Hoshimaru M. Technical improvements and results of open-door expansive laminoplasty with hydroxyapatite implants for cervical myelopathy. *Neurosurgery*. 2005;57 (suppl 4):348–356.
15. Pornrattanamaneewong C, Limthongthang R, Vathana T, Kaewpornawan K, Songcharoen P, Wongtrakul S. Diaphragmatic height index: new diagnostic test for phrenic nerve dysfunction. *J Neurosurg*. 2012;117(5):890–896.

Disclosures

The authors report no conflict of interest concerning the materials or methods used in this study or the findings specified in this paper.

Author Contributions

Conception and design: Hayashi, Kitamura. Acquisition of data: Hayashi, Kitamura, Ishibashi. Analysis and interpretation of data: Hayashi, Kitamura. Drafting the article: Hayashi, Kitamura, Toda. Critically revising the article: Hayashi, Kitamura, Toda. Reviewed submitted version of manuscript: Hayashi, Toda. Approved the final version of the manuscript on behalf of all authors: Hayashi. Study supervision: Hayashi.

Supplemental Information

Previous Presentations

This case was presented at the 36th Annual Meeting of the Neurospinal Society of Japan, Kyoto, Japan, April 3, 2021.

Correspondence

Hideki Hayashi: Tazuke Kofukai Medical Research Institute and Kitano Hospital, Osaka, Japan. nrsrghd@gmail.com.