

## Case report

## Total Knee Arthroplasty as the Primary Surgical Treatment After Knee Dislocation

Mathias Barslund Gregersen, MD<sup>\*</sup>, Knud Gade Freund, MD

Department of Orthopedic Surgery, Southwest Jutland Hospital Esbjerg, Esbjerg, Denmark

## ARTICLE INFO

## Article history:

Received 12 February 2022

Received in revised form

12 April 2022

Accepted 23 April 2022

Available online xxx

## Keywords:

Traumatic knee dislocation

Knee dislocation

Total knee arthroplasty

TKA after knee dislocation

## ABSTRACT

Traumatic knee dislocation (KD) is a rare but serious injury, and a missed diagnosis or incorrect treatment can be limb-threatening due to a significant risk of neurovascular injury. The mechanism of injury is often high-energy trauma, but there is a rising tendency of KD after low-energy trauma in the obese patient. KD often results in multiligament injury which can be a complicated surgical task with long recovery time, especially in older patients. This report presents 4 cases where patients older than 50 years with traumatic KD have been treated with a total knee arthroplasty of revision type as an alternative to multiligament reconstruction.

© 2022 The Authors. Published by Elsevier Inc. on behalf of The American Association of Hip and Knee Surgeons. This is an open access article under the CC BY-NC-ND license (<http://creativecommons.org/licenses/by-nc-nd/4.0/>).

## Introduction

Traumatic knee dislocation (KD) is a rare but serious injury, and a missed diagnosis or incorrect treatment can be limb-threatening. The incidence rate of KD has been estimated to account for 0.02%–0.2% of all orthopedic injuries [1] and comes with a significant risk of neurovascular injury with reported incidence rates from 3.3 to as high as 25% [2,3]. The mechanism of injury is often high-energy trauma, but a rising tendency of KD after low-energy trauma (eg, fall of standing height or pivoting injury) is seen in the obese patient [4–6]. The severity of KD was first categorized by Kennedy's [7] and later Schenck's classification [8] (Table 1). The direction of displacement of the tibia indicates the direction of the dislocation. Most common is anterior dislocation (30%–50%), followed by posterior dislocation (30%–40%), with lateral, medial, and rotatory dislocations occurring less frequently. Anterior dislocation comes with the highest risk of nerve injury (common peroneal nerve), and posterior dislocation with the highest risk of vascular injury (popliteal artery). After any vascular injury has been addressed, standard treatment is multiligament reconstruction of anterior cruciate ligament (ACL), posterior cruciate ligament (PCL), and collateral ligaments depending on the extent of injury [9,10].

The literature concerning multiligament reconstruction after KD is abundant, but to our knowledge, few studies have focused on an alternative operative treatment.

We present 4 cases where patients have been primarily treated with a total knee arthroplasty (TKA) after traumatic KD. Within a year, our institution admitted 8 patients with traumatic KD. Four patients were older than 50 years and were treated with TKA as definitive care. The patients were treated with a revision prosthesis of constrained condylar knee type. A constrained condylar knee prosthesis helps with the stability of the cruciate and collateral ligaments of the knee, whereas a regular TKA, apart from the ACL, is ligament-sparing. The Vanguard SSK (Zimmer Biomet, Warsaw, IN) was the preferred revision prosthesis system at our institution until being replaced with Triathlon TS (Stryker Corporation, Kalamazoo, MI) in 2018. The Vanguard SSK system had different levels of constraints, with  $\pm 1^\circ$  varus/valgus lift-off and  $\pm 5^\circ$  rotational constraint being the lead surgeon's standard choice. The Triathlon system provides a semi-constrained prosthesis, the lead surgeon's standard being the total stabilized option.

All surgeries were performed by the same orthopedic surgeon with 25 years of experience in knee replacement surgery. It was decided early after injury that it would be appropriate for all 4 patients to have a definitive surgical treatment. While preparing the knee for surgery, a standard regimen of hinged knee brace for 5 weeks with full weight-bearing was preferred by the lead surgeon; however, the regimen was individually tailored for every patient regarding present ligamentous and bony injuries.

<sup>\*</sup> Corresponding author. Department of Orthopedic Surgery, Herlev Hospital, Duevej 16, 3rd, Right, 2000, Frederiksberg, Denmark. Tel.: +45 28436562.

E-mail address: [mathias.b.gregersen@gmail.com](mailto:mathias.b.gregersen@gmail.com)

**Table 1**  
Schenck's classification of knee dislocation (KD).

Classification	Injuries
KD-I	Single ligament injury (ACL or PCL)
KD-II	Injury to both ACL and PCL
KD-III	Injury to both ACL and PCL, and either MCL or LCL.
KD-IV	Injury to both ACL, PCL, MCL and LCL.
KD-V	Fracture dislocation

ACL, anterior cruciate ligament; LCL, lateral collateral ligament; MCL, medial collateral ligament; PCL, posterior cruciate ligament.

## Case histories

All patients have given written consent for publication.

### Case 1

A 52-year-old woman with a body mass index (BMI) of 30.4 fell during a softball game and sustained anterior dislocation of her left knee after a rotational trauma (Fig. 1a and b). An magnetic resonance angiography ruled out vascular injury. A second magnetic resonance imaging (MRI) showed rupture of the popliteal ligament, ACL and PCL ruptures, a partial medial collateral ligament lesion, and avulsion of the fibular head indicating a lateral collateral ligament (LCL) rupture (Schenck KD-V). The patient was treated with a hinge brace locked in 10°–80° for 5 weeks followed by rehabilitation. After 6 months, she could not do daily activities without a Jack PCL Brace (albrecht GmbH, Bernau, Germany). There was anterior, posterior, and varus laxity with a range of motion (ROM) of 0°–95°. Additionally, she felt pain at the fibular head and in the calf suspecting a peroneal nerve injury. There was no drop foot or muscular weakness. TKA (Zimmer Biomet, Warsaw, IN; Vanguard SSK, Constrained Bearing; ±1° varus/valgus lift-off, ±5° rotational constraint) was performed 6 months after her KD (Fig. 2a and b). At 1 year postoperatively, she had a ROM of 0°–100° and diffuse calf pain.

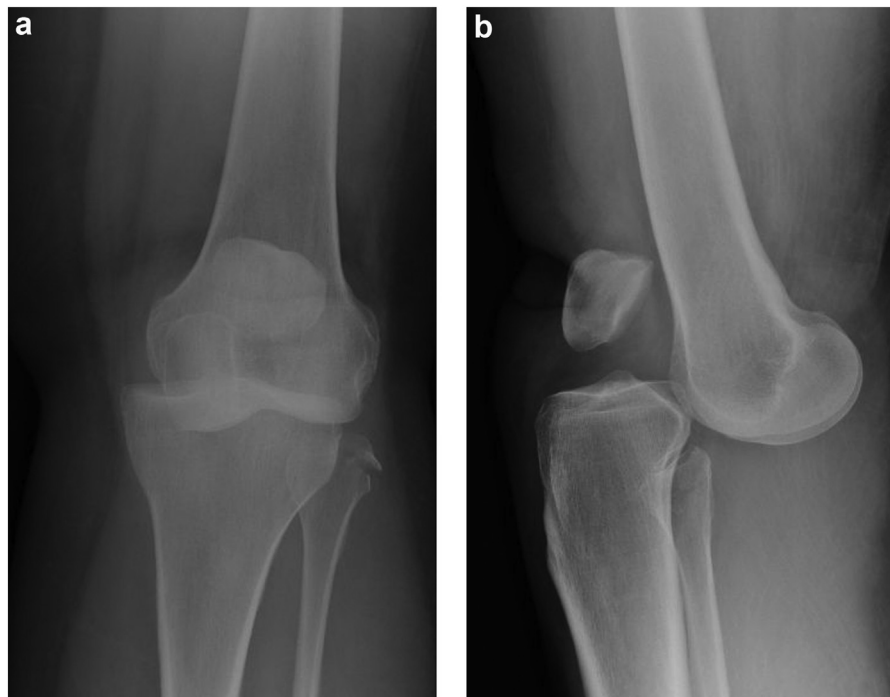
After 2 years, she continued having lower leg pain that was treated with transcutaneous electrical nerve stimulation and invasive neurostimulation to good effect. She had returned to work. The knee was stable with a ROM of 2°–125°. Radiographs showed unchanged position of the TKA and no signs of loosening.

### Case 2

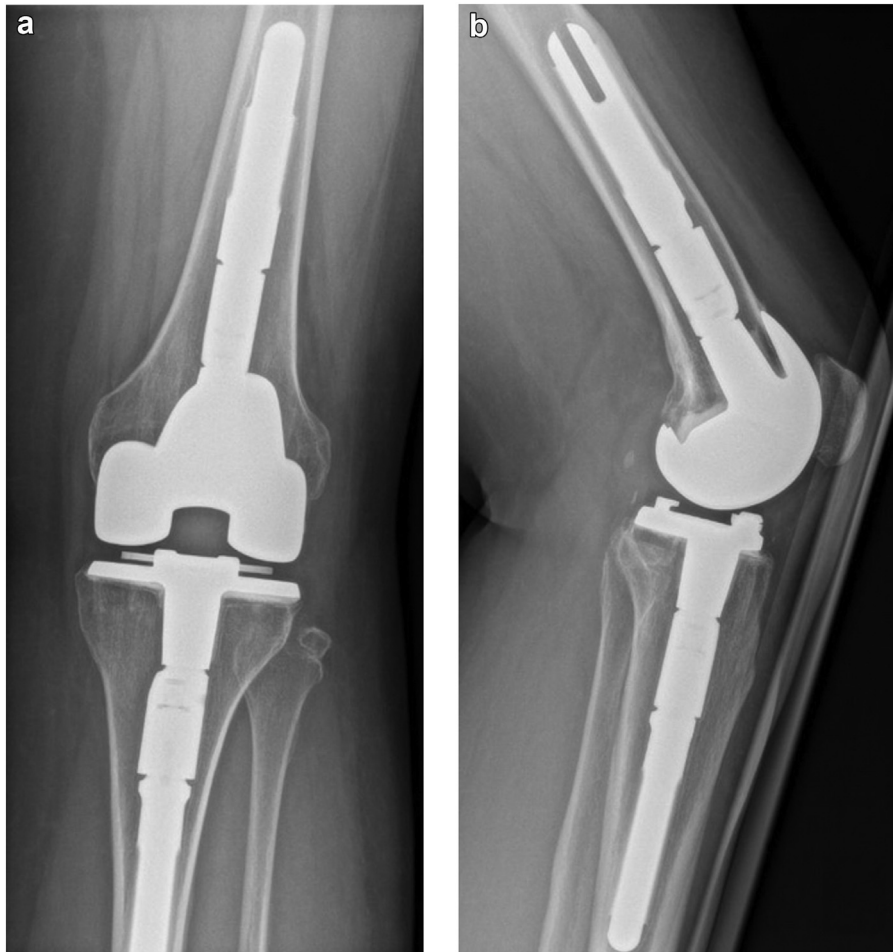A 61-year-old woman with a BMI of 33.9 sustained anterior dislocation of the left knee after twisting and subsequently falling on a slippery floor (Fig. 3a and b). Computed tomography angiography after reduction showed occlusion of the popliteal artery but acceptable collateral flow. MRI showed ACL and PCL rupture, a nondisplaced fracture of the intercondylar eminence, possible LCL lesion, and avulsion of the proximal fibula (KD-V). Initial treatment was a hinge brace locked at 10° for 6 weeks with gradual unlocking over 8 weeks and without weight-bearing due to fracture. After 6 months, there was anterior, posterior, and varus laxity with a ROM of 0°–100°. TKA (Zimmer Biomet, Warsaw, IN; Vanguard SSK, Constrained Bearing; ±1° varus/valgus lift-off, ±5° rotational constraint) was performed 7 months after her KD (Fig. 4a and b). In situ bypass surgery was considered but waived as the patient had achieved a walking distance of more than half a mile. At 2 years postoperatively, she had pain intermittently at night and when walking more than 2 miles. She had returned to work. The knee was stable with a ROM of 0°–130°. Radiographs showed unchanged position of the TKA and no signs of loosening. Peripheral vascular examination found 3+ foot pulses (normal).

### Case 3

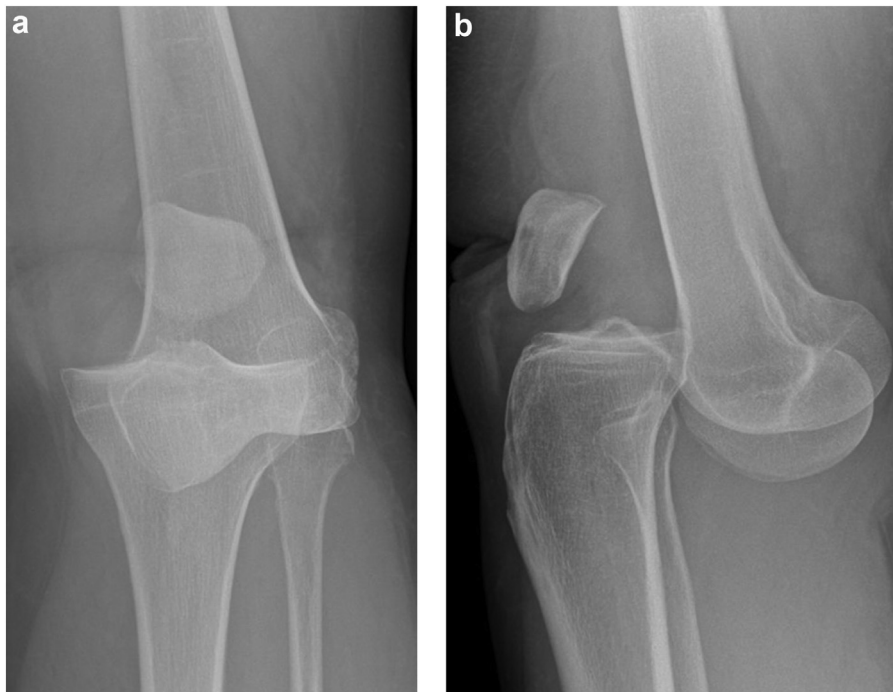A 72-year-old woman with a BMI of 36.7 sustained posterior dislocation of the right knee after a bicycle crash (Fig. 5a and b). Closed reduction of the knee was unsuccessful, and a static external fixation was applied with planned removal after 6 weeks and no weight-bearing allowed. Foot pulses were clinically assessed as 3+. MRI after 6 weeks showed ruptures of the ACL, PCL, medial



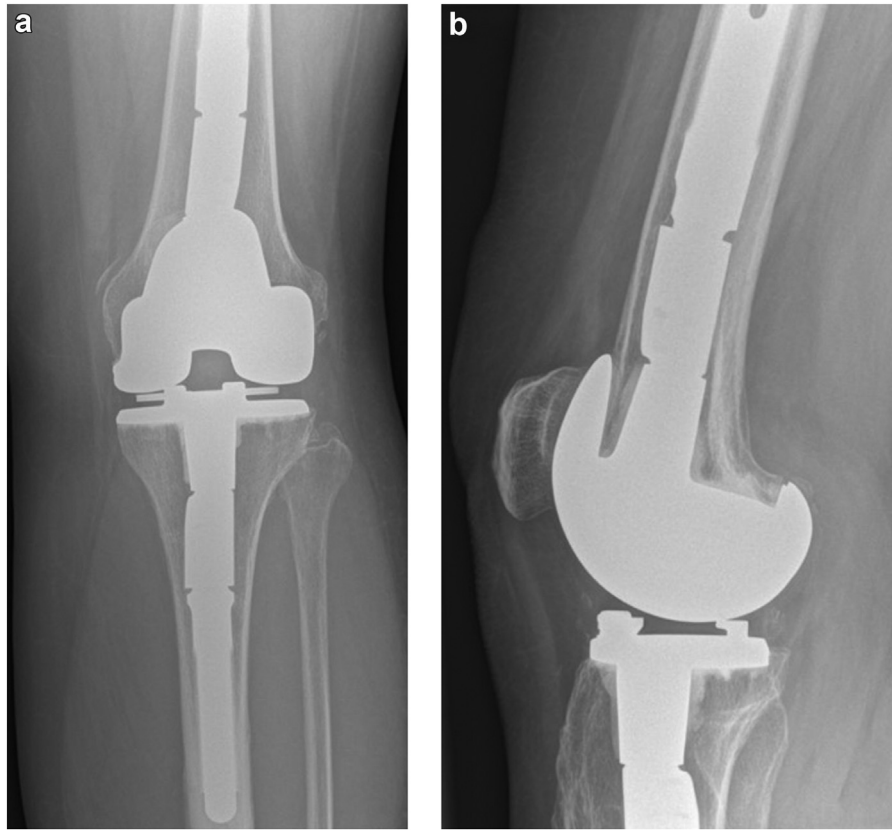
**Figure 1.** Case 1: Anterior dislocation with fibula fracture. (a) Anteroposterior view. (b) Lateral view.



**Figure 2.** Case 1: Vanguard SSK, 2 years postoperatively. (a) Anteroposterior view. (b) Lateral view.



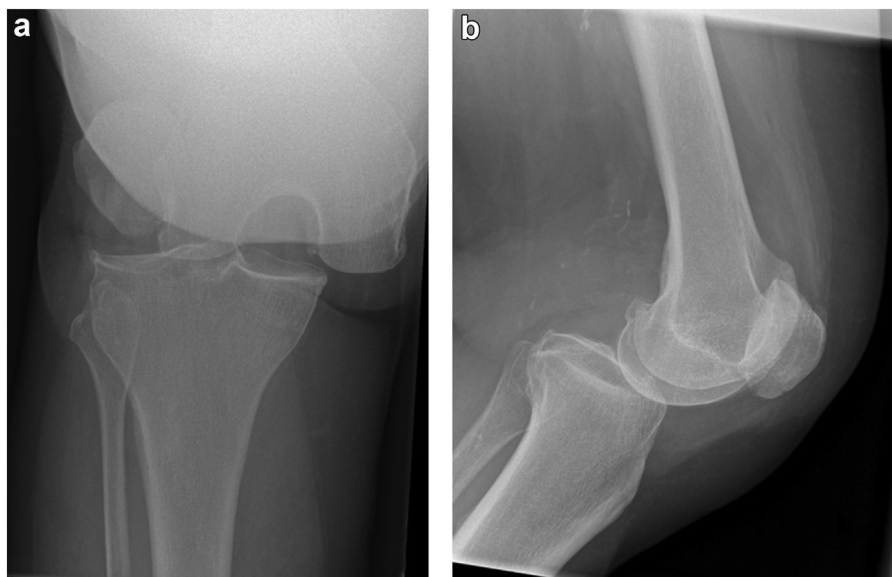
**Figure 3.** Case 2: Anterior dislocation. (a) Anteroposterior view. (b) Lateral view.



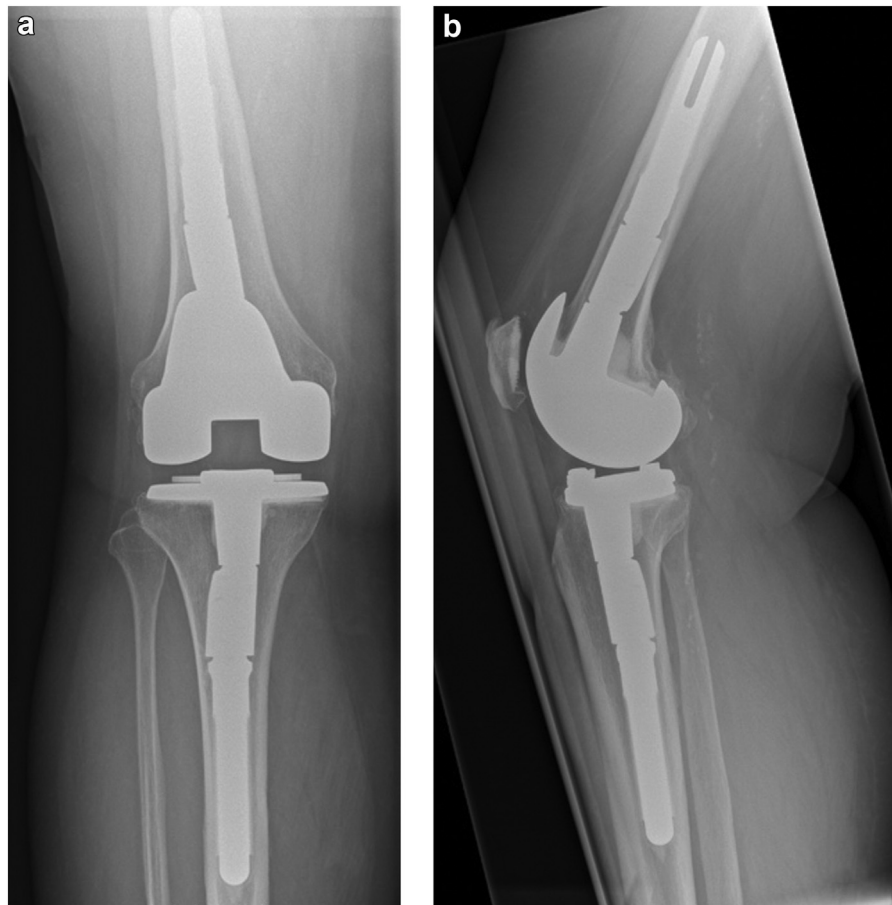
**Figure 4.** Case 2: Vanguard SSK, 2 years postoperatively. (a) Anteroposterior view. (b) Lateral view.

collateral ligament, and LCL (KD-IV); medial meniscus lesion; and focal bone contusion. The external fixation was replaced with a hinge brace locked at 10°–80° with gradual opening and increased weight-bearing over 4 weeks. After 4 months, there was anterior, posterior, and valgus laxity with a ROM of 0–60°. TKA (Zimmer Biomet, Warsaw, IN; Vanguard SSK, Constrained Bearing;  $\pm 1^\circ$  varus/valgus lift-off,  $\pm 5^\circ$  rotational constraint) was performed

4 months after her KD (Fig. 6a and b). At 4 months postoperatively, the patient had a ROM of 2°–90° and was pain-free. Four years postoperatively, she was without knee pain but had back and hip pain and had to use a walking frame for longer walks. She had retired from work before the initial trauma. The knee was stable with a ROM of 0°–85°. Radiographs showed unchanged position of the TKA and no signs of loosening.



**Figure 5.** Case 3: Posterior dislocation. (a) Anteroposterior view. (b) Lateral view.



**Figure 6.** Case 3: Vanguard SSK, 4 years postoperatively. (a) Anteroposterior view. (b) Lateral view.

#### Case 4

A 52-year-old man with a BMI of 17.7 sustained posterior dislocation of the left knee after being hit by a car while biking (Fig. 7a and b). Foot pulses were clinically assessed as 3+. MRI showed avulsion of the posterior intercondylar eminence including the PCL, ACL rupture, partial LCL rupture, and possible medial meniscus damage (KD-V). Due to subluxation of the knee, a static external fixation was applied. After 1 week, osteosynthesis of the PCL avulsion fracture via a posterior approach was performed with subsequent hinge brace treatment locked at 30° with gradual unlocking and no weight-bearing for 6 weeks. After 12 weeks, another arthroscopy was performed due to a ROM of 15°–85° and suspected meniscal pathology. Perioperatively, a displacement of the eminence fragment was found and also cyclops formation on the anterior tibial plateau. After resecting the cyclops tissue, smoothing the displaced eminence, and performing a brisement force, the perioperative ROM was 0°–125°. There was no significant cartilage damage, and the PCL was found with near-normal tension. After 5 months, there was anterior, posterior, and varus laxity; the ROM was reduced to 5°–75°; and there was significant quadriceps atrophy. TKA (Stryker Corporation, Kalamazoo, MI; Triathlon, Total Stabilized) was performed 7 months after his KD (Fig. 8a and b). At 1 year postoperatively, he had diffuse knee pain after standing 30 minutes. The ROM was 0°–95°. After 2 years, he only had soreness after walking more than 1 mile. He had not returned to work, though stating that it was not due to his knee (We raised the argument to the reviewers that not adding this phrase would imply that his knee held him from working, which was not the case. We

did not get an answer to this, and we insist on the inclusion of this phrase for the most accurate representation of the case). The knee was stable with a ROM of 0°–110°. Radiographs showed unchanged position of the TKA and no signs of loosening. There was still moderate quadriceps atrophy.

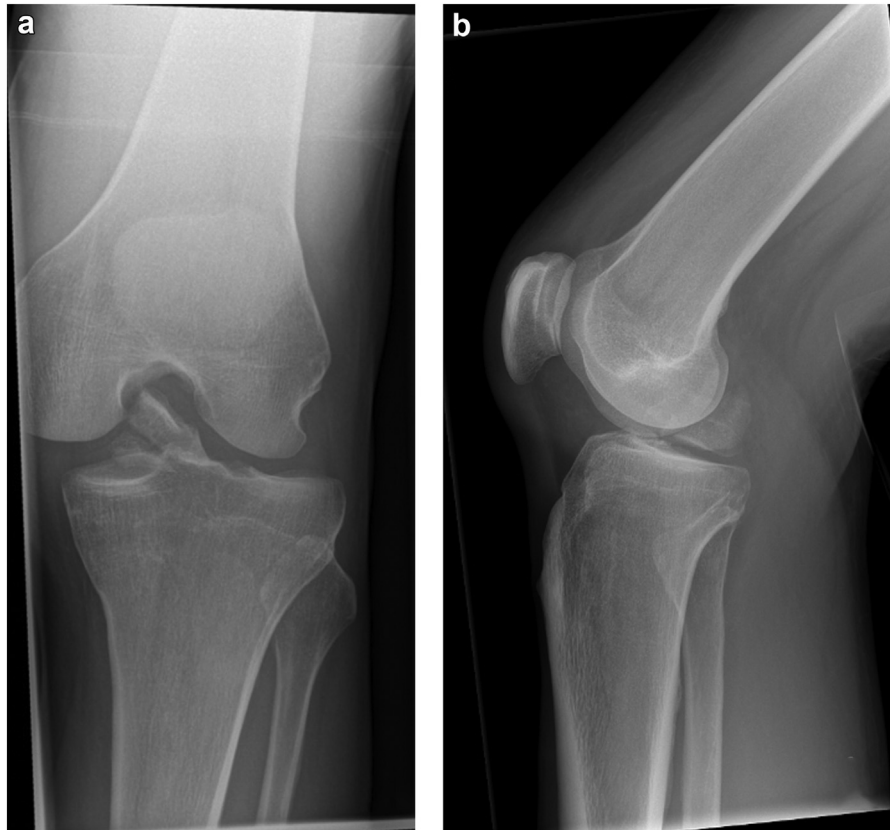
#### Discussion

The mean time from trauma to TKA surgery was 6 months (range 4–7). After a mean follow-up period of 27 months (12–48), patients averaged an improved ROM of 25.8° (20–30), predominantly in flexion. All patients had achieved full knee extension, and flexion ranged from 85° to 130°. Two patients dislocated anteriorly, and 2 posteriorly. Two patients presented as KD-IV, and 2 as KD-V in Schenk classification. At the latest follow-up, 2 patients had intermittent knee pain, while 1 patient experienced symptoms indicative of peroneal injury. All prostheses were unchanged in positioning on radiographs.

Three patients suffered their dislocations after a low-energy trauma (1 as a bike crash at low speed), and all 3 were clinically obese with a BMI >30. This patient group is described in the literature with an increased risk of KDs in low-energy trauma. In a recent review, Smith and Azar [5] found high postoperative complication rates including increased risk of posttraumatic osteoarthritis in severely obese patients after treating KD with ligament reconstruction.

There are several studies concerning KD treated with multi-ligament reconstruction [6,8,11]. Commonly, these studies found operative treatment superior to nonoperative treatment and that





**Figure 7.** Case 4: Posterior dislocation and fracture of the posterior intercondylar eminence. (a) Anteroposterior view. (b) Lateral view.

early operative treatment gives a better clinical result. However, rehabilitation after reconstruction is often a long process. An advantage of TKA is rapid mobilization and expected fast return to normal function.

To our knowledge, 1 case report has been published on TKA as a primary surgical treatment for acute KD. Bernardi et al. [12] presented an 87-year-old patient with traumatic KD where treatment with a rotating hinged TKA was chosen due to patient age and the inability to reduce the knee because of soft-tissue interposition even under general anesthesia. At 1-year follow-up, the patient had a stable knee with a ROM of 0°–120°.

Several studies have described TKA as a treatment option for chronic KD. Jabalameli et al. [13] presented 3 patients (ages 40, 48, and 52 years), 2 of whom had undergone ligament reconstruction as primary treatment and were later diagnosed with chronic dislocation. The last patient was diagnosed with a chronic dislocation 1.5 years after the insertion of a hip arthroplasty. All were treated with constrained and stemmed TKA. At follow-up (average 17 months), all patients had pain-free knees with an average ROM of 0°–110° as well as satisfaction with the result. In 2006, Liporace et al. [14] presented a case of a 52-year-old patient who, 2 years after a car accident for which she was treated 3 months with a high plaster cast, presented herself with chronic posterior dislocation, and a constrained and stemmed TKA was performed. At 2-year follow-up, the patient had 0°–85° painless ROM and no postoperative complications. In 2000, Petrie et al. [15] presented 2 patients with TKA as treatment after chronic dislocation. One patient, 72 years old, suffered posterior dislocation with popliteal artery occlusion and complete peroneal paresis. She underwent an arterial bypass and reinsertion of the LCL and the popliteal tendon without reconstruction of the cruciate ligament. Four

months later, chronic posterior dislocation was found, and surgery with constrained TKA was performed. At 9 months post-operatively, the patient had no knee pain and a ROM of 3°–95°. The other patient, 35 years old, suffered a posterior dislocation with fracture of the tibia plateau, which was primarily internally fixed, but later had to be externally fixed due to persistent posterior dislocation. Due to a major loss of substance in the proximal tibia, TKA was chosen as secondary treatment. At 8-month follow-up, the patient was mobilized with crutches and had a ROM of 10°–80°.

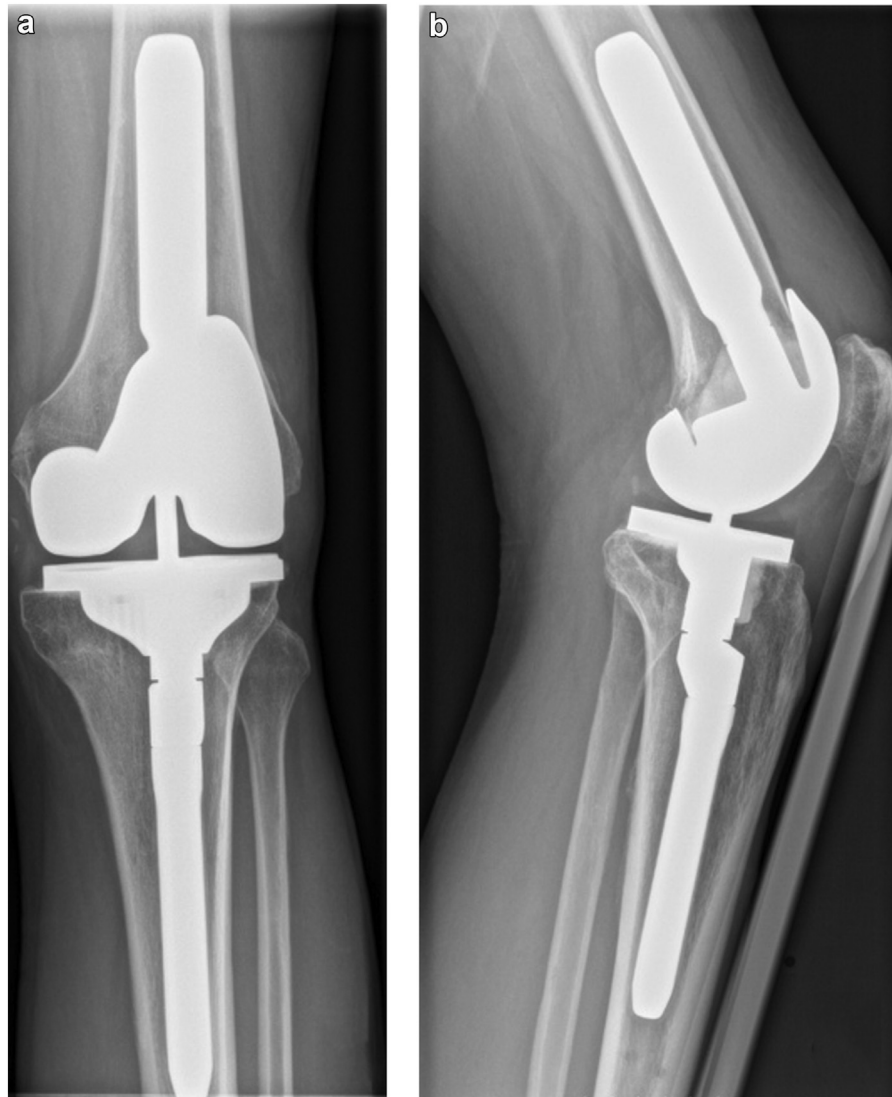### Summary

With multiligament reconstruction as the widely preferred operative treatment after KD, we propose TKA of revision type as an alternative surgical treatment in patients older than 50 years for whom requirements for ligament function are often not of the same nature as for younger patients and where a pain-free knee and rapid return to normal function may be of higher priority for the patient. However, further prospective studies should be performed to compare results for ligament reconstruction vs TKA after KD.

### Conflicts of interest

The authors declare that they have no known competing financial interests or personal relationships that could have appeared to influence the work reported in this paper.

For full disclosure statements refer to <https://doi.org/10.1016/j.artd.2022.04.012>.



**Figure 8.** Case 4: Triathlon TS, 2 years postoperatively. (a) Anteroposterior view. (b) Lateral view.

### Informed patient consent

All patients have given informed consent for publication.

### References

- [1] McKee L, Ibrahim MS, Lawrence T, Pengas IP, Khan WS. Current concepts in acute knee dislocation: the missed diagnosis? *Open Orthop J* 2014;8:162–7. <https://doi.org/10.2174/1874325001408010162>.
- [2] Medina O, Arom GA, Yerasosian MG, Petrigliano FA, McAllister DR. Vascular and nerve injury after knee dislocation: a systematic review. *Clin Orthop Relat Res* 2014;472:2621–9. <https://doi.org/10.1007/s11999-014-3511-3>.
- [3] Natsuhara KM, Yerasosian MG, Cohen JR, Wang JC, McAllister DR, Petrigliano FA. What is the frequency of vascular injury after knee dislocation? *Clin Orthop Relat Res* 2014;472:2615–20. <https://doi.org/10.1007/s11999-014-3566-1>.
- [4] Carr JB, Werner BC, Miller MD, Gwathmey FW. Knee dislocation in the morbidly obese patient. *J Knee Surg* 2016;29:278–86. <https://doi.org/10.1055/s-0036-1571432>.
- [5] Smith PJ, Azar FM. Knee dislocations in the morbidly obese patient. *Sports Med Arthrosc Rev* 2020;28:110–5. <https://doi.org/10.1097/JSA.0000000000000273>.
- [6] James EW, Wolfe I, Marx RG. Results of treatment of the multiple ligament injured (dislocated) knee. *Sports Med Arthrosc Rev* 2020;28:116–9. <https://doi.org/10.1097/JSA.0000000000000274>.
- [7] Kennedy JC. Complete dislocation of the knee joint. *J Bone Joint Surg Am* 1963;45:889–904.
- [8] Schenck RC, Richter DL, Wascher DC. Knee dislocations. *Orthop J Sports Med* 2014;2. <https://doi.org/10.1177/2325967114534387>.
- [9] Maslaris A, Brinkmann O, Bungartz M, Krettek C, Jagodzinski M, Liodakis E. Management of knee dislocation prior to ligament reconstruction: what is the current evidence? Update of a universal treatment algorithm. *Eur J Orthop Surg Traumatol* 2018;28:1001–15. <https://doi.org/10.1007/s00590-018-2148-4>.
- [10] Buyukdogan K, Laidlaw MS, Miller MD. Surgical management of the multiple-ligament knee injury. *Arthrosc Tech* 2018;7:e147–64. <https://doi.org/10.1016/j.eats.2017.08.079>.
- [11] Hohmann E, Glatt V, Tetsworth K. Early or delayed reconstruction in multi-ligament knee injuries: a systematic review and meta-analysis. *Knee* 2017;24:909–16. <https://doi.org/10.1016/j.knee.2017.06.011>.
- [12] Bernardi G, Manisera MT, Vallone A, Tudisco C. Irreducible posterolateral fracture dislocation of the knee in an elderly patient treated with rotating hinge total knee replacement. *Joints* 2019;07:209–14. <https://doi.org/10.1055/s-0041-1730980>.
- [13] Jabalamei M, Bagherifard A, Hadi H, Askari A, Ghaffari S. Total knee arthroplasty for chronic anterior knee dislocation. *Clin Med Insights Case Rep* 2018;11. <https://doi.org/10.1177/1179547618782882>.
- [14] Liporace FA, Hommen JP, Su ET, Jeong GK, Dayan AJ. Semiconstrained knee arthroplasty in the setting of a chronic knee dislocation. *J Orthop Trauma* 2006;20:286–8. <https://doi.org/10.1097/00005131-200604000-00010>.
- [15] Petrie RS, Trousdale RT, Cabanela ME. Total knee arthroplasty for chronic posterior knee dislocation. *J Arthroplasty* 2000;15:380–6. [https://doi.org/10.1016/s0883-5403\(00\)90854-4](https://doi.org/10.1016/s0883-5403(00)90854-4).