



Operative Technique: Angiomatoid Fibrous Histiocytoma—Unique Case and Management

David J. Mazur-Hart¹ Brannan E. O'Neill¹ Brandi W. Pang¹ Melanie H. Hakar² Matthew D. Wood²
Sachin Gupta³ Christina M. Sayama¹ Jesse J. Liu¹ Aclan Dogan¹

¹Department of Neurological Surgery, Oregon Health and Science University, Portland, Oregon, United States

²Department of Pathology and Laboratory Medicine, Oregon Health and Science University, Portland, Oregon, United States

³Division of Otolaryngology/Neurotology/Skull Base Surgery, Department of Otolaryngology—Head and Neck Surgery, Oregon Health and Science University, Portland, Oregon, United States

Address for correspondence Aclan Dogan, MD, Department of Neurological Surgery, Oregon Health and Science University, Mail Code CH8N, 3303 South Bond Avenue, Portland, OR 97239, United States (e-mail: dogana@ohsu.edu).

J Neurol Surg Rep 2022;83:e110–e118.

Abstract

Objective We describe the first jugular foramen angiomatoid fibrous histiocytoma (AFH) case and the first treatment with preoperative endovascular embolization. AFH is a rare intracranial neoplasm, primarily found in pediatric patient extremities. With an increase in AFH awareness and a well-described genetic profile, intracranial prevalence has also subsequently increased.

Study Design We compare this case to previously reported cases using PubMed/Medline literature search, which was performed using the algorithm [“intracranial” AND “angiomatoid fibrous histiocytoma”] through December 2020 (23 manuscripts with 46 unique cases).

Patient An 8-year-old female presented with failure to thrive and right-sided hearing loss. Work-up revealed an absence of right-sided serviceable hearing and a large jugular foramen mass. Angiogram revealed primary arterial supply from the posterior branch of the ascending pharyngeal artery, which was preoperatively embolized.

Intervention Gross total resection was performed via a translabyrinthine approach.

Conclusion The case presented is unique; the first reported AFH at the jugular foramen and the first reported case utilizing preoperative embolization. Preoperative embolization is a relatively safe technique that can improve the surgeon’s ability to perform a maximally safe resection, which may decrease the need for adjuvant radiation in rare skull base tumors in young patients.

Keywords

- ▶ angiomatoid fibrous histiocytoma
- ▶ jugular foramen
- ▶ preoperative embolization
- ▶ translabyrinthine approach

Introduction

Angiomatoid fibrous histiocytoma (AFH) is a rare neoplasm. It primarily occurs in the soft tissues of extremities.¹ AFH can rarely occur as a primary lesion in the intracranial space.²

The neoplasm predominantly affects adolescents and young adults with an average age of 14 years at diagnosis.³ Considered a benign neoplasm with low metastatic potential, AFH does exhibit a high recurrence rate⁴ and a high rate of associated hemorrhage.^{4–9} Treatment is principally through

received
December 22, 2021
accepted after revision
May 11, 2022

DOI <https://doi.org/10.1055/s-0042-1754320>.
ISSN 2193-6358.

© 2022. The Author(s).

This is an open access article published by Thieme under the terms of the Creative Commons Attribution-NonDerivative-NonCommercial-License, permitting copying and reproduction so long as the original work is given appropriate credit. Contents may not be used for commercial purposes, or adapted, remixed, transformed or built upon. (<https://creativecommons.org/licenses/by-nc-nd/4.0/>)

Georg Thieme Verlag KG, Rüdigerstraße 14, 70469 Stuttgart, Germany

surgical resection. It is thought that there is a spectrum of soft tissue tumors involving the female-expressed transcript-cAMP-response element-binding (FET-CREB) protein fusion that includes AFH.³ The naming convention will change in the next World Health Organization classification system to intracranial mesenchymal tumor, FET-CREB fusion positive.¹⁰ There are rare case reports and case series describing the intracranial occurrence of AFH.^{2-9,11-24}

Intracranial AFH is most commonly associated with the meninges, usually located along the cerebral convexities or in the intraventricular space.³ Similar to most intracranial masses, AFHs present with local mass effect or obstructive hydrocephalus.³ Due to their rarity, they are often not considered in the differential diagnosis of extra-axial lesions in young patient populations. The differential diagnosis often includes more common tumors with a similar appearance, including meningioma and solitary fibrous tumor.

In this case, we present the first reported AFH located at the jugular foramen with a unique treatment plan involving preoperative transarterial embolization for devascularization to aid in tumor resection. We also provide a literature review to compare reported cases in the literature in an effort to better elucidate optimal treatment strategies.

Materials and Methods

Clinical Presentation

An 8-year-old female, with a past medical history of asthma, mild developmental delay, pseudostrabismus, and rare headaches, presented to our emergency department (ED) after approximately 2 weeks of worsening nausea and vomiting with poor oral intake. Two days prior to the presentation, the child had complained about a tingling sensation in her right eye. She was initially taken to an outside hospital's ED, where a brain magnetic resonance image (MRI) revealed an extra-axial right posterior fossa mass abutting the petrous temporal bone. The patient was transferred to our pediatric intensive care unit (PICU; ▶Fig. 1).

Upon examination, she had end gaze nystagmus in all directions, right upper and lower facial weakness (complete eye closure with significant effort and nasolabial flattening), and decreased right-sided hearing. She was started on dexamethasone. Skull base computed tomography (CT) was obtained with no obvious evidence of skull involvement or widening of skull base foramen (▶Fig. 2). An audiogram was obtained with profound right-sided hearing loss (▶Fig. 3). She underwent a diagnostic cerebral angiogram, which demonstrated major arterial supply from the right ascending pharyngeal artery (APA) (▶Fig. 4). Her exam improved to mild right facial weakness at rest with symmetry upon activation. This improvement was attributable to steroid intake. She was transferred to the ward while awaiting a surgical date. The day prior to surgery, she underwent an ophthalmological examination with normal findings. Standard of care surgical consent was obtained. Institutional Review Board approval was not required for single cases. An institutional authorization to use and disclose protected health information was obtained.

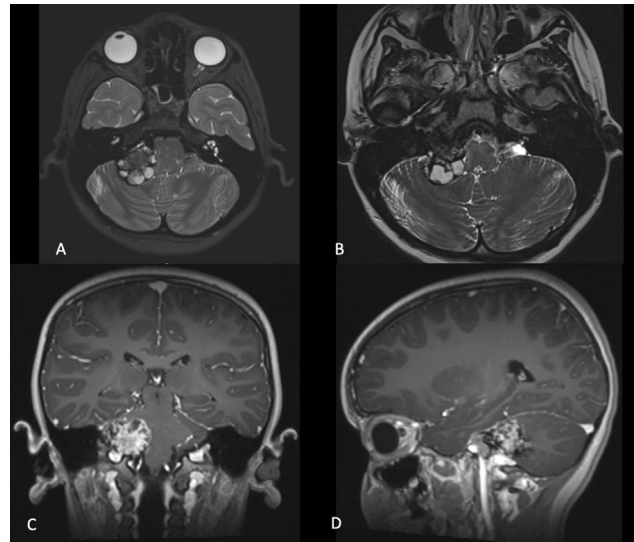


Fig. 1 Preoperative MRI showing a right jugular foramen heterogeneous mass with solid and cystic components that appear hypervascular. (A) Axial T2. (B) Axial balanced fast field echo. (C) Coronal T1 with contrast. (D) Sagittal T1 with contrast.

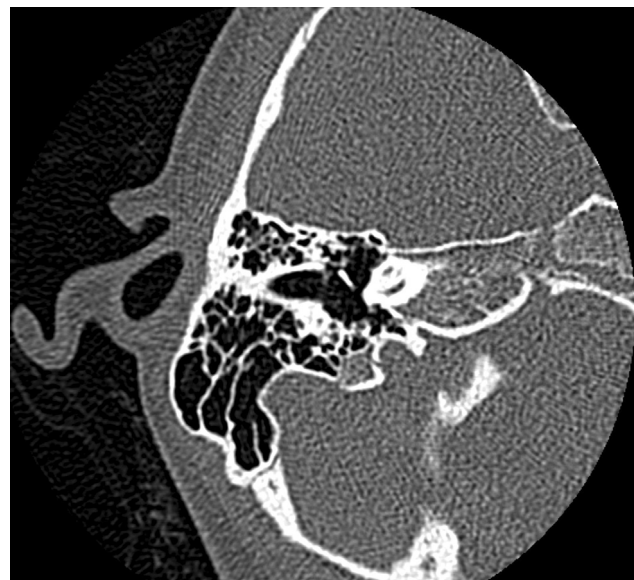

Fig. 2 Preoperative CT temporal bone protocol. No evidence of bone remodeling or osseous involvement.

Operative Technique

On the day prior to surgery, she underwent an angiogram for particle and coil embolization of the right APA (▶Fig. 5). A 4 French Pinnacle Introducer Sheath (Terumo, Somerset, NJ, United States) was placed in the right femoral artery. A 4 French Tegtmeier catheter was navigated over a 0.035" Glidewire (Terumo, Somerset, NJ, United States) into the common carotid artery. Using roadmap imaging, the right APA was selectively catheterized. Next, a 1018 Excelsior microcatheter (Stryker, Fremont, CA, United States) was navigated over a Fathom microwire (Boston Scientific, Marlborough, MA, United States) to superselectively catheterize the distal posterior branch of the APA. Embolization was performed using 355 to 500-micron polyvinyl alcohol

Frequency (Hz)	250	500	1,000	2,000	3,000	4,000	6,000	8,000
Right ear dB HL (masked)	NR up to 90	NR up to 100	NR up to 100	NR up to 100		NR up to 100		NR up to 90
Left ear dB HL	15	15	10	5	5	5	0	0

Fig. 3 Preoperative audiometry showing no serviceable hearing on the affected side.

particles (Cook Medical, Bloomington, IN, United States) followed by a 2 mm × 5 mm figure-eight coil (Boston Scientific, Marlborough, MA, United States). The microcatheter was removed under gentle aspiration. A final angiographic run revealed embolization of the feeding artery and a significant reduction of flow to the lesion.

The next day, she went for surgical resection (► **Video 1**). She underwent a right translabyrinthine approach for the resection of mass with an abdominal fat graft for closure. The patient was monitored with somatosensory evoked potentials, motor-evoked potentials, facial nerve electromyography, and electroencephalography. A neurootologist performed the surgical approach and closure, while a neurosurgeon performed the durotomy and resection. Intraoperatively, the mass was readily identifiable. There was a clear plane between the tumor and the cerebellum. Due to neoplasm size, internal bulking was required. The tissue had portions that were soft, while other portions were firm, requiring ultrasonic aspiration with an aggressive bit (CUSA

Clarify, Integra, Princeton, NJ, United States) and dissection with microscissors (Kamiyama series, Takayashi Instrument, Inc, Natick, MA, United States). Frozen specimen revealed a low-grade neoplasm with a differential diagnosis including hemangioblastoma, meningioma, and schwannoma with low suspicion for papillary endolymphatic sac tumor. The mass was dissected off the trigeminal nerve and cranial nerves VII/VIII complex and found to likely originate from the jugular foramen as it was intimately involved with the lower cranial nerves (IX/X) with primary attachments to the petrous temporal bone around the jugular foramen. A small amount of residual tumor was left due to dense adherence to the lower cranial nerves. No changes were noticed in neuro-monitoring throughout the case including intact stimulation of the facial nerve. The patient went directly to MRI to obtain both a safety postprocedural scan and a postresection baseline brain scan. This MRI revealed a gross total resection with no obvious complication or radiographically residual disease (► **Fig. 6**).

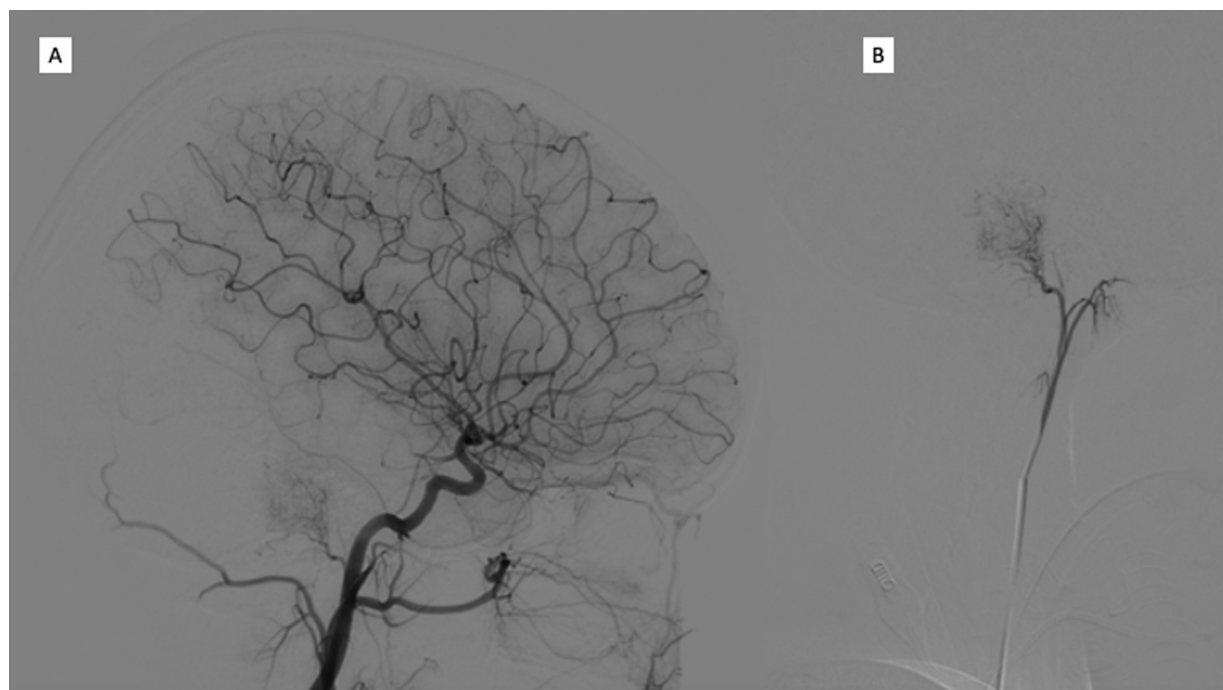


Fig. 4 Preoperative digital subtraction angiography. (A) Injection of the right common carotid artery during the arterial phase showing tumor blush from the posterior branch of the ascending pharyngeal artery. (B) Microcatheter injection of the ascending pharyngeal artery in the arterial phase.

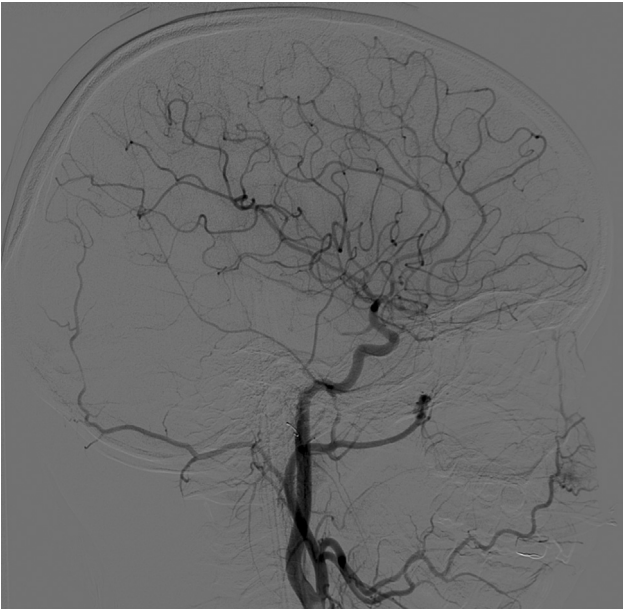


Fig. 5 Digital subtraction angiography showing preoperative embolization of the right ascending pharyngeal artery on a lateral projection of a right common carotid injection during the arterial phase. Embolization products are noted with no residual tumor blush.

Video 1

Case summary and operative techniques. Online content including video sequences viewable at: <https://www.thieme-connect.com/products/ejournals/html/10.1055/s-0042-1754320>.

Postoperative Management

The patient was extubated in the postanesthesia care unit and transferred to the PICU. She was noted to have some dysarthria and coughing with difficulty in swallowing postoperatively. She was evaluated by speech therapist who offered suggestions on safe swallowing techniques with a plan for regular diet and thin liquids. She was transferred to the stepdown unit on postoperative day (POD) 1. She was discharged home with her parents on POD 2. Her final histological diagnosis returned as AFH, positive for *EWSR1* rearrangement by fluorescence in situ hybridization analysis (►Figs. 7 and 8). At a 2-week postoperative follow-up, her facial weakness had resolved. She underwent a full body positron emission tomography computed tomography (PET-CT) with no evidence of disease. At a 10-week follow-up, her diplopia had resolved. She was noted by her mother to cough throughout the day but had no difficulty swallowing and was on a regular diet. Brain MRI showed no progression of known residual disease. At a 5-month follow up, she remained well with no progression on surveillance brain MRI with no further coughing. At a 9-month follow up, surveillance brain MRI noted disease progression. She showed no clinical signs of worsening disease. She was referred to radiation oncology for consideration of adjuvant radiotherapy with initial plan for 55.8 Gy over 31 fractions.

Literature Review

A systemic PubMed/Medline literature search was performed using the algorithm ["intracranial" AND "angiomatoid fibrous histiocytoma"] through December 2020. We reviewed the search results for intracranial cases of histologically proven AFH. Twenty-three manuscripts were found with 46 unique cases (►Table 1). We recorded patient age and gender, symptomatology at presentation, intracranial

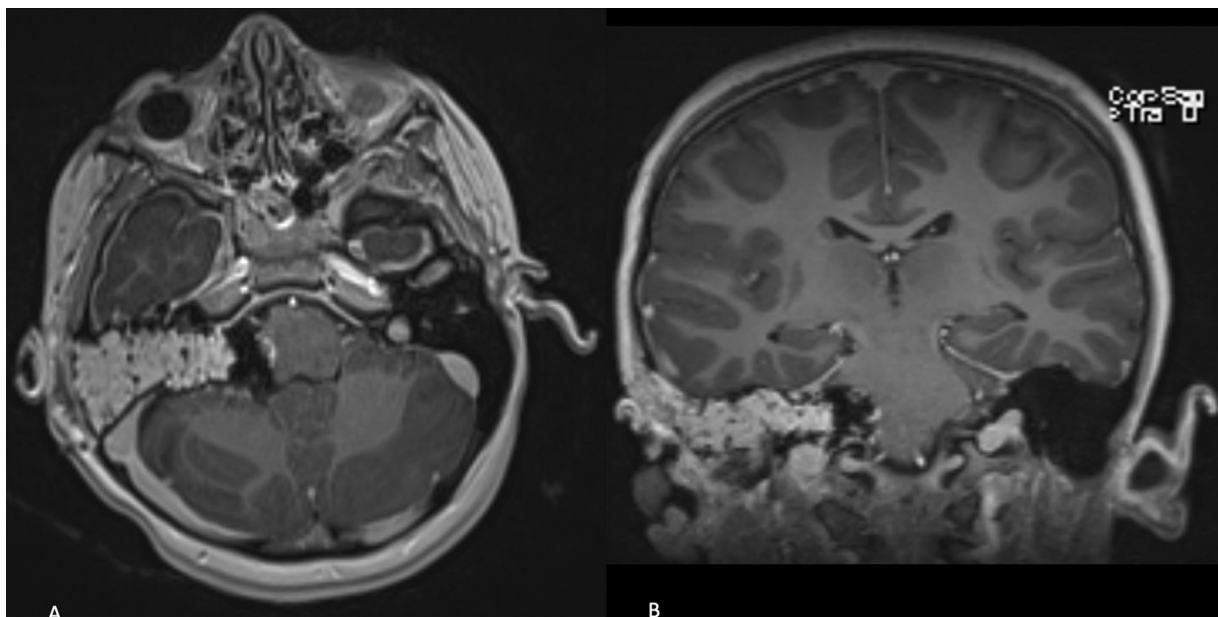


Fig. 6 Postoperative MRI showing gross total resection through a translabyrinthine approach with fat graft. (A) Axial T1 with contrast. (B) Coronal T1 with contrast.

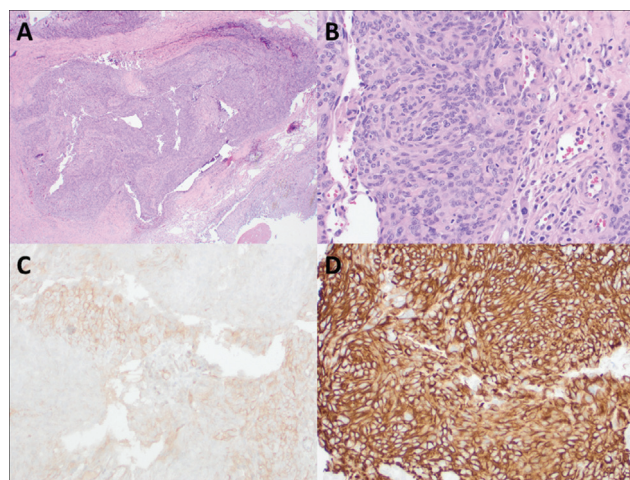


Fig. 7 Histological slides of this intracranial angiomatoid fibrous histiocytoma. (A) The lesion demonstrates a nodular proliferation with blood-filled pseudoangiomatous spaces and abundant hemosiderin deposition. The characteristic lymphoplasmacytic cuff often seen in this entity is absent in this case (x40 magnification). (B) Syncytial growth of bland spindled to epithelioid tumor cells; cytologic atypia is minimal, and mitotic figures are inconspicuous (x200 magnification). (C) The lesional cells show focal positivity for CD99 (x200 magnification) and (D) strong, diffuse staining for desmin (x200 magnification).

location, radiographic size, presence of gene fusion, treatment modalities, and longest point of known follow-up.

Discussion

AFH is a rare tumor that can infrequently appear intracranially. The tumor has rarely been reported in the skull base. There have been four reported cases of this tumor in the cerebellopontine angle (CPA) and an additional case at the petrous apex (►Table 1).^{3,13} We report only the sixth case of a skull base AFH and the first at the jugular foramen. Alshareef et al described a case at the petrous apex in which the patient presented with right facial weakness, pain, and numbness.¹³ The first consideration on their differential diagnosis was a trigeminal schwannoma. The tumor was approached through a pterional craniotomy with one-piece orbitozygomatic craniotomy. They were able to perform a gross total resection. The patient did develop a delayed cerebrospinal fluid leak from petrous apex air cells that was repaired. There was no evidence of recurrence on 6-month postoperative MRI.

Sloan et al reported four CPA masses in their series of 20 cases.³ Three of the four patients with CPA masses underwent a subtotal resection, and the final was a gross total resection. The surgical approach to these tumors was not described. One of the patients with subtotal resections underwent adjuvant radiation and chemotherapy. Unfortunately, they had metastases of their disease and passed away 27 months postoperatively. The second patient with subtotal resection did not undergo adjuvant therapy with ultimate progression of their disease. They passed away 1 month postoperatively. The final patient with subtotal resection has not undergone adjuvant therapy and remains alive at

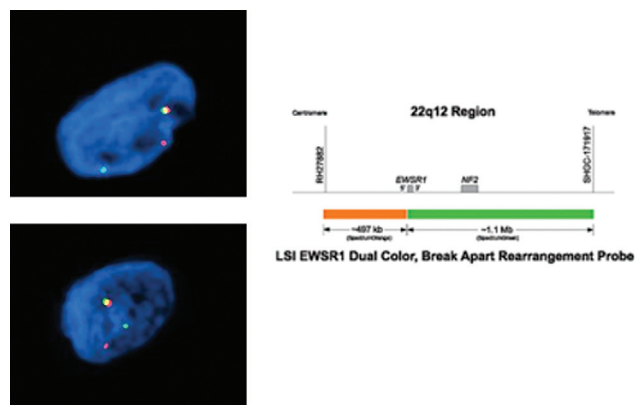


Fig. 8 Fluorescence in situ hybridization analysis of tumor specimen showing gene rearrangement of EWSR1. (86% 1 red/ 1 green/ 1 yellow [normal signal pattern = 2 yellow]). Courtesy of Susan Olson, Ph.D., Knight Diagnostic Laboratories, Portland, Oregon, United States.

13 months postoperatively with stable disease. The gross total resection has had local recurrence without adjuvant therapy. They remain alive at 30 months postoperatively.

Our case is unique in that it is the first described AFH case at the jugular foramen. The patient presented with multiple cranial nerve abnormalities and symptoms concerning for increased intracranial pressure. Imaging was concerning for an extra-axial mass along the petrous bone concerning for meningioma, schwannoma, solitary fibrous tumor, endolymphatic sac tumor, or other rare pediatric tumor. None of these diagnoses seemed to fit based on patient demographics, patient presentation, and radiographic appearance. Intraoperatively, the mass was found to originate from the jugular foramen. Postoperatively, the patient largely recovered with expected hearing loss. Her diplopia resolved and there was no evidence of facial weakness. Her mother noted that she coughed more throughout the day, which may be a sign of lower cranial nerve dysfunction, but she has had no difficulty swallowing and has remained on a regular diet.

Based on brain MRI, the mass appeared to be dural based and hypervascular and the patient underwent a preoperative diagnostic cerebral angiogram, which identified the primary arterial supply from the APA. A prior study has shown high rates of success for embolization of the APA.²⁵ It was decided that the patient should undergo a preoperative embolization to aid in surgical resection. Our case is unique in that our treatment management included the preoperative use of endovascular arterial embolization followed by surgical resection.

The preoperative use of endovascular embolization assisted in the ease of surgical resection. This has been demonstrated in preoperative embolization of meningiomas. A systematic review of preoperative embolization of meningiomas found less intraoperative blood loss and less overall operative time.²⁶ This has also been found in preoperative embolization of other hypervascular pathologies like arteriovenous malformations, paragangliomas, and carotid body tumors.²⁷⁻³⁰ Another systematic review found that preoperative embolization has a low morbidity/mortality profile.³¹ It has also been found to be safe in pediatric

Table 1 PubMed/Medline literature search using the algorithm [“intracranial” AND “angiomatoid fibrous histiocytoma”] through December 2020

Series	Year	Age (years)	Sex	Presentation	Location	Size (cm)	Gene fusion	Adjuvant therapy	Follow-up (months)	Status
Dunham et al	2008	25	M	HA, N/V, right HH	Left occipital	5.3	EWS/ATF-1			
Ochalski et al	2010	35	M	HA, right facial weakness	Left mesial temporal	0.5 × 0.5	EWSR1 gene rearranged	Seven repeat surgeries for clot evacuation and/or debulking; two radiosurgeries	49	Deceased
Hansen et al	2015	17	F	HA, blurry vision, anemia, left arm hyper-reflexia	Bioccipital (extra-axial)			Repeat resection	16 ^a	Alive
Alshareef et al	2016	58	F	Weight loss, right facial weakness, right hearing loss	Meckel's cave	6.1 × 4.8 × 2.9	EWSR1 rearranged		6	Alive
Kao et al	2017	15	F		Meninges		EWSR1-CREB		17	Alive
		23	F		Meninges (occipital)		EWSR1-CREB1			
		20	M		Frontal		EWSR1-CREB1		156 ^b	Alive
		12	M	Seizure, tongue jittering	Left frontal		EWSR1-ATF1			
Spatz et al	2018	22	F	HA, seizure, left HH	Right occipital (extra-axial)	3.1 × 3.1 × 2.6		Repeat resection	3	Alive
Bale et al	2018	12	M	HA	Left cerebellar (extra-axial)	2.5 × 2.3 × 1.0	EWSR1-CREB1		46 ^c	Alive
		14	F	HA, N/V, diplopia	Left lateral ventricle	3.8 × 3.6 × 3	EWSR1-CREB1		47 ^c	Alive
		18	M	Seizure	Right frontal	3.0 × 2.0 × 1.5	EWSR1-CREB		12	Alive
Gareton et al	2018	19	M	Seizure	Right temporo-occipital (extra-axial)		EWSR1-CREB	API/Al type chemotherapy; radiation 61.2 Gy in 34 fractions; repeat resection for recurrence	120	Alive
Sciote et al	2018	17	F	Seizure, right hemiparesis	Left frontal	5.9	ESWR1-ATF1	Repeat resection for recurrence; radiation 59.4 Gy; additional resection for recurrence	90	Alive
Gunness et al	2019	32	F	HA, neck pain, papilledema	Right lateral ventricle			Repeat resection for recurrence; shunt for recurrent cyst	24	Alive
Konstantinidis et al	2019	13	F	HA, nystagmus	Right frontal (extra-axial)		EWSR1-ATF1	Repeat resection for recurrence	132	Alive
		12	F	HA, N/V, blurry vision, right pronator drift	Left frontal		EWSR1-CREB		28	Alive
Ghanbari et al	2019	58	F	Seizure, left hemiparesis	Right parietal (extra-axial)	1.6	EWSR1-CREB1		3	Alive
Aizpurua et al	2019	9	M	HA, N/V, transient vision loss, papilledema, left facial weakness, right uvula deviation	Left precentral gyrus	2.5 × 2.0 × 1.8	ESWR1-ATF1		12	Alive
White et al	2019	9	M	Fatigue, weight loss, abulia	Right frontal (extra-axial)	2.1	EWSR1-CREB	Repeat resection for recurrence; radiation 50 Gy in 26 fractions with a boost of 10 Gy to cavity	6	Alive
Bin Abdulqader et al	2020	10	M	HA, N/V, seizure, left hemiparesis, left facial weakness, left pronator drift	Bifrontal	4	EWSR1 rearranged		3	Alive

(Continued)

Table 1 (Continued)

Series	Year	Age (years)	Sex	Presentation	Location	Size (cm)	Gene fusion	Adjuvant therapy	Follow-up (months)	Status
Komatsu et al	2020	11	F	Seizure	Right frontal (extra-axial)	2.8 × 1.9	EWSR1 rearranged		5	Alive
Domingo et al	2020	53	F	HA, dizziness	Third ventricle		ESWRI-CREB1	Radiation	3 ^d	Alive
Ballester et al	2020	36	F	HA, N/V, diplopia, lower extremity weakness	Interhemispheric (extra-axial)		EWSR1-CREM		3	Alive
Valente Aguiar et al	2020	67	M	Confusion, expressive aphasia	Left temporal (extra-axial)		EWSR1-ATF1		3.5	Alive
Ward et al	2020	58	F	HA, N/V, confusion, gait imbalance, right hemiparesis	Left lateral ventricle		EWSR1-CREB1		6	Alive
Gilbert et al	2020	48	F	HA	Left lateral ventricle		EWSR1-ATF1	Repeat resection for recurrence; radiation for recurrence 35 Gy in 5 fractions	16	Alive
Sloan et al	2020	52	M	HA, N/V, imbalance, weight loss	Vermian (extra-axial)		EWSR1-CREM		12	Alive
	2020	12	M		Parietal		EWSR1-ATF1	Radiation 59.4 Gy	24	Alive
		9	F		Frontal		EWSR1-ATF1		63	Deceased
		24	F		Occipital		EWSR1-ATF1			
		13	F		Frontal		EWSR1-ATF1		24	Alive
		34	F		Tentorium		EWSR1-ATF1		81	Alive
		17	F		CPA		EWSR1-ATF1	Radiation 59.4 Gy; chemotherapy	27	Deceased
		70	M		CPA with spinal dissemination		EWSR1-ATF1		1	Deceased
		17	F		CPA		EWSR1-ATF1		13	Alive
		14	F		Lateral ventricle		EWSR1-CREB1		59	Alive
		39	F		Lateral ventricle		EWSR1-CREB1		6	Alive
		10	M		Falk (parietal)		EWSR1-CREB1		57	Alive
		25	F		CPA		EWSR1-CREB1		30	Alive
		14	F		Parietal		EWSR1-CREB1		57	Alive
		15	F		Spinal cord (thoracic)		EWSR1-CREM	Radiation	30	Alive
		14	F		Lateral ventricle		EWSR1-CREM		38	Alive
		5	F		Frontal		EWSR1-CREM	Chemotherapy	11	Alive
		30	M		Falk (frontal)		EWSR1-CREM	Radiation 54 Gy	6	Alive
		4	F		Occipital		FUS-CREM		36	Alive
Authors	2021	8	F	N/V, right facial weakness, right hearing loss	Right jugular foramen	3.2 × 2.7 × 2.6	EWSR1 rearranged		3	Alive

Abbreviations: API/AI, doxorubicin-cisplatin-irifosfamide; CPA, cerebellopontine angle; F, female; Gy, Gray; HA, headache; HH, homonymous hemianopsia; M, male; N, nausea; V, vomiting.
^aupdated follow up from Ballester et al.
^bupdated follow up from Valente Aguiar et al.
^cupdated follow up from Sloan et al.
^dupdated follow up from Bin Abdulqader et al.

patients and in skull base pathologies.^{32,33} Like meningiomas, AFH is most commonly extra-axial or intraventricular with radiographic dural attachments. As the feeding vessel for this tumor was from the APA, the major arterial supply was from the external carotid artery and deep to the tissue mass. Embolization involved the external carotid instead of the internal carotid circulation, which decreases catheter time in the intracranial circulation and decreases risk of stroke. However, attention must be paid to the APA itself as there may be collaterals to the internal carotid or vertebral artery as well as supply to the vasa nervosa of the lower cranial nerves.^{34,35} The arterial feeder for this tumor was also deep and obtaining surgical devascularization would have come late in the procedure.

Similar to meningiomas, it appears that AFH outcomes are linked to extent of resection. Sloan et al reported in their case series that patients that received gross total resection had better survival and local recurrence rates, but those values did not reach statistical significance.³ Due to their propensity for local recurrence, follow-up radiation was suggested by their group. Since these can be hemorrhagic masses with deep arterial feeders, we suggest preoperative embolization may allow for the best chance at safely achieving gross total resection.

Conclusion

AFH is a rare tumor that mimics more commonly found intracranial neoplasms. We present a rarely reported skull base AFH and the first located at the jugular foramen. Due to the importance of gross total resection, we recommend preoperative evaluation with diagnostic cerebral angiogram to evaluate for preoperative embolization, which may improve rates of gross total resection. In the setting of gross total resection, adjuvant radiation therapy may be avoided. This is beneficial as the tumor is more common in children and young adults for which radiation carries long-term risks.

Conflict of Interest

None declared.

Acknowledgments

The authors thank Shirley McCartney, PhD, for editorial assistance.

References

- 1 Thway K, Fisher C. Angiomatoid fibrous histiocytoma: the current status of pathology and genetics. *Arch Pathol Lab Med* 2015;139(05):674–682
- 2 Spatz M, Nussbaum ES, Lyons L, Greenberg S, Kallmes KM, Nussbaum LA. Primary intracranial angiomatoid fibrous histiocytoma: a case report and literature review. *Br J Neurosurg* 2021;35(02):233–235
- 3 Sloan EA, Chiang J, Villanueva-Meyer JE, et al. Intracranial mesenchymal tumor with FET-CREB fusion—a unifying diagnosis for the spectrum of intracranial myxoid mesenchymal tumors and angiomatoid fibrous histiocytoma-like neoplasms. *Brain Pathol* 2021;31(04):e12918
- 4 Ochalski PG, Edinger JT, Horowitz MB, et al. Intracranial angiomatoid fibrous histiocytoma presenting as recurrent multifocal intraparenchymal hemorrhage. *J Neurosurg* 2010;112(05):978–982
- 5 Gilbert AR, Yan L, McDougall CM. Broadening the age of incidence of intracranial angiomatoid fibrous histiocytoma with EWSR1-CREM fusion: a case report. *J Neuropathol Exp Neurol* 2020;79(11):1244–1246
- 6 Konstantinidis A, Cheesman E, O'Sullivan J, et al. Intracranial angiomatoid fibrous histiocytoma with EWSR1-CREB family fusions: a report of 2 pediatric cases. *World Neurosurg* 2019;126:113–119
- 7 Aizpurua M, Zebian B, Minichini V, et al. A case of childhood intracerebral angiomatoid fibrous histiocytoma radiologically mimicking infection and with unusual immunopositivity for placental alkaline phosphatase. *Clin Neuropathol* 2019;38(05):245–248
- 8 White MD, McDowell MM, Pearce TM, Bukowinski AJ, Greene S. Intracranial myxoid mesenchymal tumor with rare EWSR1-CREM translocation. *Pediatr Neurosurg* 2019;54(05):347–353
- 9 Bin Abdulqader S, Altuhaini K, Tallab R, et al. Primary intracranial angiomatoid fibrous histiocytoma: two case reports and literature review. *World Neurosurg* 2020;143:398–404
- 10 Louis DN, Perry A, Wesseling P, et al. The 2021 WHO Classification of Tumors of the Central Nervous System: a summary. *Neuro-oncol* 2021;23(08):1231–1251
- 11 Dunham C, Hussong J, Seiff M, Pfeifer J, Perry A. Primary intracerebral angiomatoid fibrous histiocytoma: report of a case with a t(12;22)(q13;q12) causing type 1 fusion of the EWS and ATF-1 genes. *Am J Surg Pathol* 2008;32(03):478–484
- 12 Hansen JM, Larsen VA, Scheie D, Perry A, Skjøth-Rasmussen J. Primary intracranial angiomatoid fibrous histiocytoma presenting with anaemia and migraine-like headaches and aura as early clinical features. *Cephalalgia* 2015;35(14):1334–1336
- 13 Alshareef MA, Almadidy Z, Baker T, Perry A, Welsh CT, Vandergrift WA III. Intracranial angiomatoid fibrous histiocytoma: case report and literature review. *World Neurosurg* 2016;96:403–409
- 14 Kao YC, Sung YS, Zhang L, et al. EWSR1 fusions with CREB family transcription factors define a novel myxoid mesenchymal tumor with predilection for intracranial location. *Am J Surg Pathol* 2017;41(04):482–490
- 15 Bale TA, Oviedo A, Kozakewich H, et al. Intracranial myxoid mesenchymal tumors with EWSR1-CREB family gene fusions: myxoid variant of angiomatoid fibrous histiocytoma or novel entity? *Brain Pathol* 2018;28(02):183–191
- 16 Gareton A, Pierron G, Mokhtari K, et al. EWSR1-CREM fusion in an intracranial myxoid angiomatoid fibrous histiocytoma-like tumor: a case report and literature review. *J Neuropathol Exp Neurol* 2018;77(07):537–541
- 17 Sciot R, Jacobs S, Calenbergh FV, Demaerel P, Wozniak A, Debiec-Rychter M. Primary myxoid mesenchymal tumour with intracranial location: report of a case with a EWSR1-ATF1 fusion. *Histopathology* 2018;72(05):880–883
- 18 Gunness VRN, Munoz I, González-López P, Alshafai N, Mikalkova A, Spears J. Intracranial angiomatoid fibrous histiocytoma with Hodgkin lymphoma. *Med J Malaysia* 2019;74(03):234–236
- 19 Ghanbari N, Lam A, Wycoco V, Lee G. Intracranial myxoid variant of angiomatoid fibrous histiocytoma: a case report and literature review. *Cureus* 2019;11(03):e4261
- 20 Komatsu M, Yoshida A, Tanaka K, et al. Intracranial myxoid mesenchymal tumor with EWSR1-CREB1 gene fusion: a case report and literature review. *Brain Tumor Pathol* 2020;37(02):76–80
- 21 Domingo RA, Vivas-Buitrago T, Jentoft M, Quinones-Hinojosa A. Intracranial myxoid mesenchymal tumor/myxoid subtype angiomatous fibrous histiocytoma: diagnostic and prognostic challenges. *Neurosurgery* 2020;88(01):E114–E122

- 22 Ballester LY, Meis JM, Lazar AJ, et al. Intracranial myxoid mesenchymal tumor with EWSR1-ATF1 fusion. *J Neuropathol Exp Neurol* 2020;79(03):347–351
- 23 Valente Aguiar P, Pinheiro J, Lima J, Vaz R, Linhares P. Myxoid mesenchymal intraventricular brain tumour with EWSR1-CREB1 gene fusion in an adult woman. *Virchows Arch* 2021;478(05):1019–1024
- 24 Ward B, Wang CP, Macaulay RJB, Liu JKC. Adult intracranial myxoid mesenchymal tumor with EWSR1-ATF1 gene fusion. *World Neurosurg* 2020;143:91–96
- 25 Barros G, Feroze AH, Sen R, et al. Predictors of preoperative endovascular embolization of meningiomas: subanalysis of anatomic location and arterial supply. *J Neurointerv Surg* 2020;12(02):204–208
- 26 Chen L, Li DH, Lu YH, Hao B, Cao YQ. Preoperative embolization versus direct surgery of meningiomas: a meta-analysis. *World Neurosurg* 2019;128:62–68
- 27 Purdy PD, Samson D, Batjer HH, Risser RC. Preoperative embolization of cerebral arteriovenous malformations with polyvinyl alcohol particles: experience in 51 adults. *AJNR Am J Neuroradiol* 1990;11(03):501–510
- 28 Liu DG, Ma XC, Li BM, Zhang JG. Clinical study of preoperative angiography and embolization of hypervascular neoplasms in the oral and maxillofacial region. *Oral Surg Oral Med Oral Pathol Oral Radiol Endod* 2006;101(01):102–109
- 29 Catapano JS, Almefty RO, Ding D, et al. Onyx embolization of skull base paragangliomas: a single-center experience. *Acta Neurochir (Wien)* 2020;162(04):821–829
- 30 Economopoulos KP, Tzani A, Reifsnyder T. Adjunct endovascular interventions in carotid body tumors. *J Vasc Surg* 2015;61(04):1081–91.e2
- 31 Ilyas A, Przybylowski C, Chen CJ, et al. Preoperative embolization of skull base meningiomas: a systematic review. *J Clin Neurosci* 2019;59:259–264
- 32 Wang HH, Luo CB, Guo WY, et al. Preoperative embolization of hypervascular pediatric brain tumors: evaluation of technical safety and outcome. *Childs Nerv Syst* 2013;29(11):2043–2049
- 33 Przybylowski CJ, Baranoski JF, See AP, et al. Preoperative embolization of skull base meningiomas: outcomes in the onyx era. *World Neurosurg* 2018;116:e371–e379
- 34 Lasjaunias P, Moret J. The ascending pharyngeal artery: normal and pathological radioanatomy. *Neuroradiology* 1976;11(02):77–82
- 35 Haccin-Bey L, Daniels DL, Ulmer JL, et al. The ascending pharyngeal artery: branches, anastomoses, and clinical significance. *AJNR Am J Neuroradiol* 2002;23(07):1246–1256