



Since January 2020 Elsevier has created a COVID-19 resource centre with free information in English and Mandarin on the novel coronavirus COVID-19. The COVID-19 resource centre is hosted on Elsevier Connect, the company's public news and information website.

Elsevier hereby grants permission to make all its COVID-19-related research that is available on the COVID-19 resource centre - including this research content - immediately available in PubMed Central and other publicly funded repositories, such as the WHO COVID database with rights for unrestricted research re-use and analyses in any form or by any means with acknowledgement of the original source. These permissions are granted for free by Elsevier for as long as the COVID-19 resource centre remains active.

**Guido Guidotti, MD**  
**Alexander D. Jobrack, MD**

Occupational Medicine  
 Cambridge Health Alliance  
 Harvard Medical School  
 Cambridge, MA

Department of Environmental Health  
 Harvard University T.H. Chan School of Public  
 Health  
 Boston, MA

**Jane Buley, RN**  
**Neetha Nathan**

Occupational Medicine  
 Cambridge Health Alliance  
 Harvard Medical School  
 Cambridge, MA

**Rebecca Osgood, MD**

Pathology  
 Cambridge Health Alliance  
 Harvard Medical School  
 Cambridge, MA

Pathology  
 Massachusetts General Hospital  
 Harvard Medical School  
 Boston, MA

**Lou Ann Bruno-Murtha, DO**

Infection Prevention and Infectious Diseases  
 Cambridge Health Alliance  
 Harvard Medical School  
 Cambridge, MA

**Stefanos N. Kales, MD, MPH**

Occupational Medicine  
 Cambridge Health Alliance  
 Harvard Medical School  
 Cambridge, MA

Department of Environmental Health  
 Harvard University T.H. Chan School of Public  
 Health  
 Boston, MA

**Potential Competing Interests:** The authors report no competing interests.

**ORCID**

Stefanos N. Kales:  <https://orcid.org/0000-0002-7712-4664>

1. Thompson MG, Burgess JL, Naleway AL, et al. Interim estimates of vaccine effectiveness of BNT162b2 and mRNA-1273 COVID-19 vaccines in preventing SARS-CoV-2 infection among health care personnel, first responders, and other essential and frontline workers—eight U.S. locations, December 2020–March 2021. *MMWR Morb Mortal Wkly Rep.* 2021; 70(13):495–500.

2. Swift MD, Breeher LE, Tande AJ, et al. Effectiveness of mRNA COVID-19 vaccines against SARS-CoV-2 infection in a cohort of healthcare personnel. *Clin Infect Dis.* 2021;73(6):e1376–e1379.
3. Lan FY, Filler R, Mathew S, et al. Sociodemographic risk factors for coronavirus disease 2019 (COVID-19) infection among Massachusetts healthcare workers: a retrospective cohort study. *Infect Control Hosp Epidemiol.* 2021 Jan 28:1–6. <https://doi.org/10.1017/ice.2021.17>.
4. Lan FY, Filler R, Mathew S, et al. COVID-19 symptoms predictive of healthcare workers' SARS-CoV-2 PCR results. *PLoS One.* 2020;15(6):e0235460.
5. Massachusetts Department of Public Health. Archive of COVID-19 cases in Massachusetts. <https://www.mass.gov/info-details/archive-of-covid-19-cases-in-massachusetts>. Accessed September 9, 2021.

<https://doi.org/10.1016/j.mayocp.2021.10.005>

mRNA COVID-19  
 Vaccine—Related  
 Anaphylactoid Reaction  
 and Coronary  
 Thrombosis

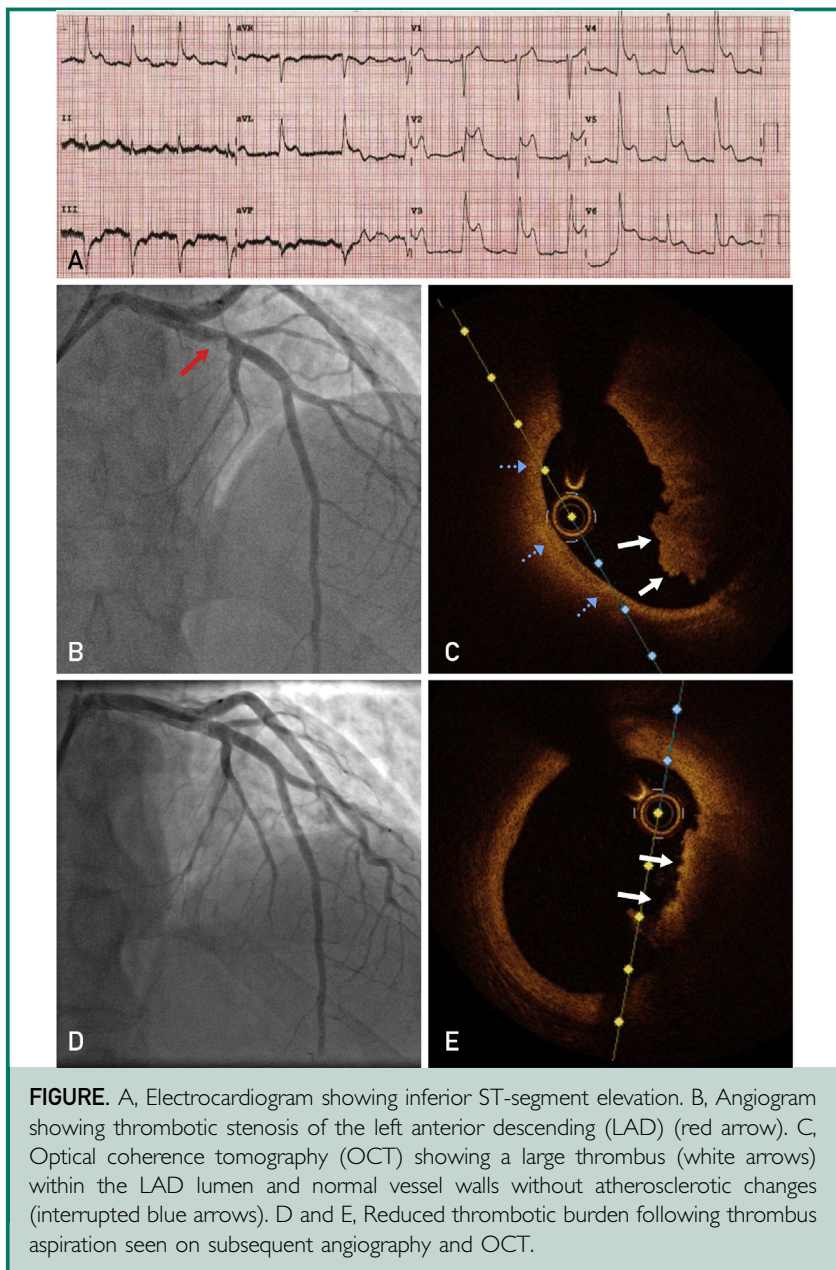


**To the Editor:** The emergence of vaccines, with clear evidence of their efficacy, has been key to tackling the coronavirus disease 2019 (COVID-19) pandemic. However, as these vaccines are rolled out to larger numbers of patients, rare complications are inevitable, and clinicians should be aware of this possibility. We present a case of a young man who presented with an anaphylactoid reaction a day after having the Pfizer-BioNTech COVID-19 vaccine with thrombotic occlusion of his left anterior descending (LAD) artery.

Paramedics attended a 38-year-old man with a sudden onset widespread erythematous rash, dyspnea, and stridor 18 hours after receiving his first dose of the Pfizer-BioNTech COVID-19 vaccine. Past medical history was notable for asthma and eczema but no known allergies. He was treated with 500 µg of adrenaline intramuscularly with initial good response; however,

he developed severe central chest pain. Serial electrocardiograms revealed evolving ST-segment elevation — initially inferiorly and then anteriorly (Figure, A). He was therefore transferred to hospital and underwent urgent coronary angiography which surprisingly showed severe thrombotic stenosis of the proximal LAD with distal embolization (Figure, B). Optical coherence tomography confirmed significant LAD thrombus (Figure, C; white arrows) but no evidence of underlying atherosclerotic plaque rupture and normal smooth vessel wall segments (Figure, C; interrupted blue arrows). Multiple thrombus aspiration runs were undertaken, and the patient was started on a glycoprotein 2b/3a inhibitor with improvement of the angiographic appearances. Transthoracic echocardiography showed an apical left ventricular thrombus. Subsequent angiography 2 days later was reassuring with reduced thrombotic burden and no features suggestive of plaque rupture (Figure, D and E). Given the absence of coronary stenosis from an atherosclerotic plaque, a coronary stent was not deployed. The patient was managed medically with dual-antiplatelet therapy and a direct oral anticoagulant. On further questioning, he denied any insect bites or taking any drugs, and had been fasting for 12 hours. Interestingly, his mast cell tryptase was normal (10.7 ng/mL) and no cocaine metabolites were seen on urinalysis. The patient had an uneventful recovery and an EpiPen issued before discharge. The adverse event was reported to the Medicine and Healthcare products Regulatory Agency of the Department of Health and Social Care in the United Kingdom.

Importantly, the Pfizer-BioNTech COVID-19 vaccine has been shown to be safe and effective



**FIGURE.** A, Electrocardiogram showing inferior ST-segment elevation. B, Angiogram showing thrombotic stenosis of the left anterior descending (LAD) (red arrow). C, Optical coherence tomography (OCT) showing a large thrombus (white arrows) within the LAD lumen and normal vessel walls without atherosclerotic changes (interrupted blue arrows). D and E, Reduced thrombotic burden following thrombus aspiration seen on subsequent angiography and OCT.

in protecting against severe disease.<sup>1,2</sup> Severe adverse reactions are rare and for the vast majority anaphylaxis occurs within minutes of administration.<sup>3,4</sup> We postulate that, in the absence of significant underlying atherosclerotic coronary artery disease, spontaneous LAD thrombosis resulted either from a delayed anaphylactoid reaction or

a combination of the immune reaction and adrenaline administered. Indeed, adrenaline injection promotes platelet aggregation and thrombus formation by increasing the levels of thromboxane and sensitivity to thrombin.<sup>5,6</sup> Adrenaline injection can induce vasospasm with occlusion or near occlusion of the lumen,<sup>7</sup> the resultant blood stasis

in the coronary circulation may also facilitate thrombogenesis. Although a previous case report of LAD thrombosis following Pfizer-BioNTech COVID-19 vaccination shares some features with this case, the patient was 86 years of age with cardiovascular risk factors and their reaction occurred within 30 minutes of vaccination and was not associated with an anaphylactoid-type pattern.<sup>8</sup>

Physicians should be aware of the possibility for late anaphylactoid reactions, including potential thrombotic coronary artery occlusion, following COVID-19 vaccination.

**Jonathan Hinton, BM**  
**Andre Briosa e Gala, MD**  
**Simon Corbett, PhD**

University Hospital Southampton NHS  
foundation Trust  
Southampton, United Kingdom

1. Polack FP, Thomas SJ, Kitchin N, et al. Safety and efficacy of the BNT162b2 mRNA COVID-19 vaccine. *N Engl J Med.* 2020;383(27):2603-2615.
2. Lopez Bernal J, Andrews N, Gower C, et al. Effectiveness of the Pfizer-BioNTech and Oxford-AstraZeneca vaccines on COVID-19 related symptoms, hospital admissions, and mortality in older adults in England: test negative case-control study. *BMJ.* 2021;373:n1088.
3. Shimabukuro TT, Cole M, Su JR. Reports of anaphylaxis after receipt of mRNA COVID-19 vaccines in the US — December 14, 2020–January 18, 2021. *JAMA.* 2021;325(11):1101-1102.
4. Shimabukuro T, Nair N. Allergic reactions including anaphylaxis after receipt of the first dose of Pfizer-BioNTech COVID-19 vaccine. *JAMA.* 2021;325(8):780-781.
5. Laustiola K, Kaukinen S, Seppälä E, Jokela T, Vapaatalo H. Adrenaline infusion evokes increased thromboxane B2 production by platelets in healthy men: the effect of beta-adrenoceptor blockade. *Eur J Clin Invest.* 1986;16(6):473-479.
6. Wallén NH, Goodall AH, Li N, Hjemdahl P. Activation of haemostasis by exercise, mental stress and adrenaline: effects on platelet sensitivity to thrombin and thrombin generation. *Clin Sci (Lond).* 1999;97(1):27-35.
7. Yasue H, Nakagawa H, Itoh T, Harada E, Mizuno Y. Coronary artery spasm — clinical features, diagnosis, pathogenesis, and treatment. *J Cardiol.* 2008;51(1):2-17.
8. Tajstra M, Jaroszewicz J, Gasior M. Acute coronary tree thrombosis after vaccination for COVID-19. *J Am Coll Cardiol Interv.* 2021;14(9):e103-e104.

<https://doi.org/10.1016/j.mayocp.2021.10.010>