

CORRECTION

# Correction: Increased Metallothionein I/II Expression in Patients with Temporal Lobe Epilepsy

José Eduardo Peixoto-Santos, Orfa Yineth Galvis-Alonso, Tonicarlo Rodrigues Velasco, Ludmyla Kandratavicius, João Alberto Assirati, Carlos Gilberto Carlotti, Renata Caldo Scandiuzzi, Luciano Neder Serafini, João Pereira Leite

Fig 2 appears incorrectly in the published article. Please see the correct [Fig 2](#) and its caption below.

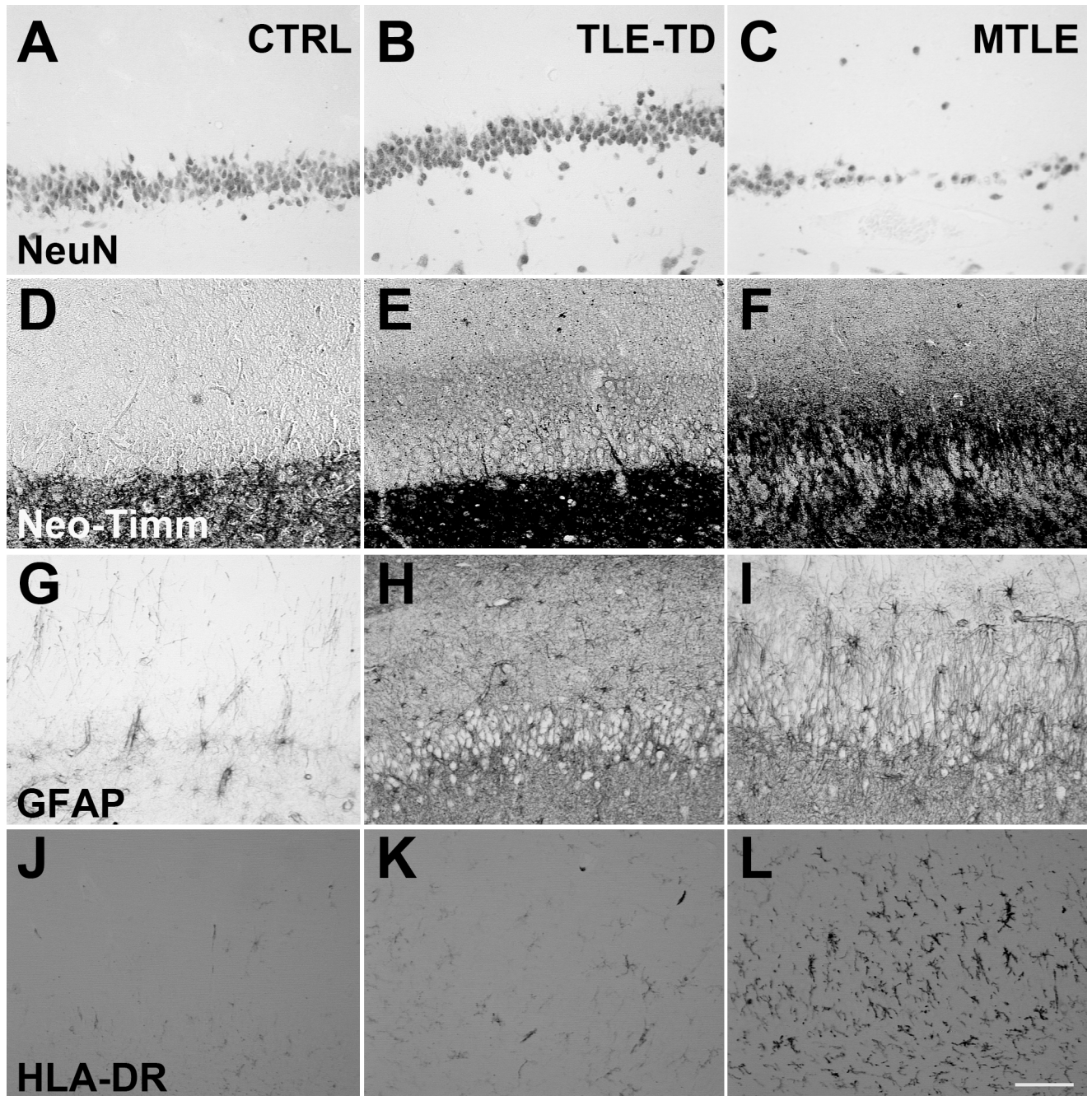


 OPEN ACCESS

**Citation:** Peixoto-Santos JE, Galvis-Alonso OY, Velasco TR, Kandratavicius L, Assirati JA, Carlotti CG, et al. (2016) Correction: Increased Metallothionein I/II Expression in Patients with Temporal Lobe Epilepsy. PLoS ONE 11(7): e0159122. doi:10.1371/journal.pone.0159122

**Published:** July 7, 2016

**Copyright:** © 2016 Peixoto-Santos et al. This is an open access article distributed under the terms of the [Creative Commons Attribution License](#), which permits unrestricted use, distribution, and reproduction in any medium, provided the original author and source are credited.



**Fig 2. Representative images of NeuN, neo-Timm, GFAP and HLA-DR staining in the Fascia dentata of Ctrl, TLE-TD and MTLE patients.** The pattern of NeuN staining is the same in Ctrl (A), TLE-TD (B) and MTLE (C) groups, but MTLE shows reduced neuronal population in this subfield. Compared to Ctrl (D), increased neo-Timm staining was observed in the inner molecular layer of fascia dentata in MTLE patients (F), but not in TLE-TD (E). As for the astroglial population, both hyperplasia and hypertrophy are observed in MTLE (I) and TLE-TD (H), compared to Ctrl (G). Hyperplasia is also observed in microglial cells in TLE-TD (K) and, more notable, in MTLE (L), compared to Ctrl (J). Bar in L indicates 100 micrometers.

doi:10.1371/journal.pone.0159122.g001

## Reference

1. Peixoto-Santos JE, Galvis-Alonso OY, Velasco TR, Kandratavicius L, Assirati JA, Carlotti CG, et al. (2012) Increased Metallothionein I/II Expression in Patients with Temporal Lobe Epilepsy. PLoS ONE 7(9): e44709. doi:10.1371/journal.pone.0044709 PMID: 23028585