



Contents lists available at ScienceDirect

International Journal of Surgery Case Reports

journal homepage: www.casereports.com

Letrozole-induced necrotising leukocytoclastic small vessel vasculitis: First report of a case in the UK



Pirunthan Pathmarajah^a, Karishma Shah^a, Kathy Taghipour^b, Su Ramachandra^c, Mangesh A Thorat^{d,e}, Ziaullah Chaudhry^d, Vivek Patkar^d, Francesca Peters^d, Thomas Connor^d, Emma Spurrell^d, Jeffrey S Tobias^d, Jayant S Vaidya^{d,f,*}

^a University College London Medical School, Gower St, London WC1E6BT, United Kingdom

^b Department of Dermatology, The Whittington Hospital, London N195NF, United Kingdom

^c Department of Histopathology, The Whittington Hospital, London N195NF, United Kingdom

^d The Breast Unit, The Whittington Hospital, London N195NF, United Kingdom

^e Centre for Cancer Prevention, Wolfson Institute of Preventive Medicine, Queen Mary University of London, EC1M 6BQ, United Kingdom

^f Division of Surgery and Interventional Science, University College London, 132 Hampstead Road, London NW1 2PS, United Kingdom

ARTICLE INFO

Article history:

Received 7 September 2015

Accepted 17 September 2015

Available online 26 September 2015

Keywords:

Leukocytoclastic vasculitis

Letrozole

Breast cancer

Hypersensitivity reaction

ABSTRACT

INTRODUCTION: Letrozole, an aromatase inhibitor, is a commonly used neo-adjuvant drug to treat hormone-sensitive breast cancer. There have been a few cases of aromatase inhibitor induced vasculitis but the first case of letrozole-induced vasculitis was reported from Switzerland in 2014 (Digkolia et al. [1]).

PRESENTATION OF CASE: We report the case of a 72-year-old woman with a small breast cancer. She was started on pre-operative letrozole (2.5 mg/d) whilst awaiting surgery. Ten days later she presented with burning pain and purpuric skin lesions which progressed to extensive ischaemic superficial necrosis of the lower limb skin, resolving over 3–4 months after local and systemic steroids. Histologically, it showed leukocytoclasia with evidence of eosinophilia consistent with a diagnosis of cutaneous leukocytoclastic small vessel vasculitis.

DISCUSSION: The initial clinical presentation was severe burning pain around the ankles and a spreading violaceous rash. Letrozole was stopped. Wide local excision (lumpectomy) and sentinel node biopsy were postponed because of the accompanying pneumonitis and gastrointestinal upset, and were carried out 3.5 months later. Fortunately, the tumour size did not increase, but appeared to reduce, and axillary lymph nodes remained negative, i.e., this patient's cancer outcome does not seem to have been jeopardized.

CONCLUSION: Leukocytoclastic vasculitis is a hypersensitivity reaction that is usually self-resolving, though our case needed systemic steroid treatment. Letrozole is a commonly used drug in clinical practice and prescribers should be aware of this rare side effect, which in our case delayed treatment without any apparent harm and possibly reduced tumour size.

© 2015 The Authors. Published by Elsevier Ltd. on behalf of Surgical Associates Ltd. This is an open access article under the CC BY-NC-ND license (<http://creativecommons.org/licenses/by-nc-nd/4.0/>).

1. Introduction

Aromatase inhibitors have replaced tamoxifen as the preferred adjuvant endocrine treatment in the majority of postmenopausal breast cancer patients. They inhibit or inactivate the aromatase enzyme and therefore inhibit oestrogen synthesis in peripheral fat, the main source of oestrogen after menopause. Generally, they are well-tolerated and common side effects include nausea, vomiting,

alopecia, dry skin and osteoporosis. Cutaneous manifestations are rare, with few documented cases of erythema nodosum, cutaneous vasculitis, toxic epidermal necrolysis, Henoch-Schönlein purpura, and cutaneous lupus erythematosus [2–8].

A vasculitis secondary to letrozole has been reported in Switzerland [1] but to the best of our knowledge, this is the only other case reported in the world.

2. Presentation of case

A 72 year old woman with left-sided invasive lobular carcinoma of the breast (18 × 8 × 7 mm on ultrasound, Grade 2, ER positive, PR positive, HER2 negative, Mib-1/Ki67 proliferation index 15%) was scheduled to have a wide local excision of the cancer (lumpectomy) and sentinel node biopsy. However, due to her wish to visit

Abbreviations: PCR, protein creatinine ratio; ANCA, anti-neutrophil cytoplasmic antibody; CLSVV, cutaneous leukocytoclastic small vessel vasculitis; HE, hematoxylin and eosin stain.

* Corresponding author at: Division of Surgery and Interventional Science, University College London, 132 Hampstead Road, London NW1 2PS, United Kingdom.

E-mail address: jayant.vaidya@ucl.ac.uk (J.S. Vaidya).

<http://dx.doi.org/10.1016/j.ijscr.2015.09.024>

2210-2612/© 2015 The Authors. Published by Elsevier Ltd. on behalf of Surgical Associates Ltd. This is an open access article under the CC BY-NC-ND license (<http://creativecommons.org/licenses/by-nc-nd/4.0/>).

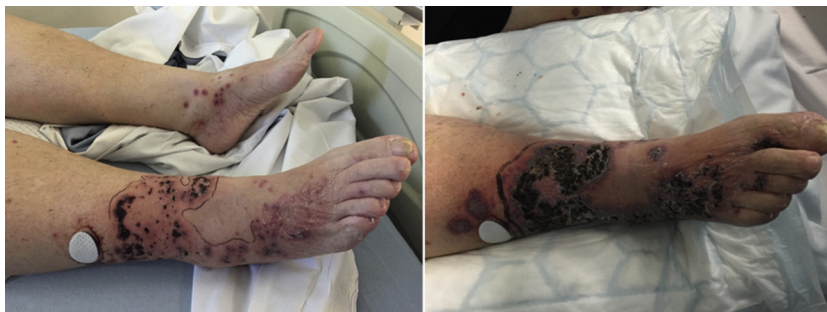

Fig. 1. Images taken on the first day and a week later showing palpable purpura and violaceous macules becoming confluent with superficial skin necrosis: Left 17th Feb 2015, Right 24th Feb 2015.

her elderly husband in Ireland, the surgery was postponed and letrozole was started in the meantime. She was taking amlodipine and bendroflumethiazide for hypertension, digoxin and aspirin for atrial fibrillation, simvastatin, occasionally a salbutamol inhaler for asthma, and co-codamol for knee pain. She has no known drug allergies.

A day before the surgery (i.e 14 days after starting letrozole) the patient gave a four-day history of a severe burning sensation around both ankles. The overlying skin had an erythematous and violaceous rash with blisters and was tender on palpation (Fig. 1). She gave a two-day history of vomiting and diarrhoea as well as a productive cough and wheeze, but no haematemesis and no haemoptysis.

Urine dipstick showed mild proteinuria and Protein Creatinine Ratio (PCR) of 48 (normal range: <45 mg/mmol), but no haematuria. Her observations including blood pressure (131/81 mmHg) were all normal and blood cultures did not show any growth. Anti-Nuclear Antibody was negative, Anti-Neutrophil Cytoplasmic Antibody (ANCA) was negative but complement C4 was raised to 51 mg/dL (normal range: 20–40 mg/dL). A diagnosis of vasculitis, possibly related to letrozole use, was considered and a skin punch biopsy of the rash on the right leg was taken (Fig. 1).

Letrozole was stopped and the patient was started on topical steroid, clobetasol propionate 0.05% (Dermovate). The pneumonitis and gastrointestinal upset meant that the scheduled lumpectomy had to be cancelled. Amoxicillin was started.

Five days later there was increased burning sensation around both ankles and lower legs (Fig 1, right). There was circumferential necrosis on the right leg and multiple non-exudative violaceous small lesions extending to both upper thighs and lower back. There was breakdown of the skin with crusting of coalescent areas. The right leg was warm to touch and pedal oedema extended to the mid-shin. She was unable to tolerate clobetasol propionate due to intense pain when applying it and instead was started on analgesia

and 40 mg of oral Prednisolone. She was admitted for observation and pain relief.

By this time, the histopathology of the punch biopsy was available and showed extensive ischaemic necrosis of the epidermis and the papillary dermis, with the formation of a sub-epidermal blister. There was interstitial haemorrhage with scattered nuclear dust and karyorrhectic debris (leucocytoclasia). Neutrophils and eosinophils surrounded the blood vessels and there was infiltration of vessel walls with fibrinoid necrosis, consistent with a diagnosis of cutaneous leukocytoclastic small vessel vasculitis (Fig. 2).

Renal function improved quickly, ruling out significant renal involvement. Three days later the legs were still painful but the erythematous area had decreased in size. The following week there were no new lesions but there was extensive superficial skin necrosis. The prednisolone dose was tapered off. Letrozole was not re-introduced. The lesions healed over the next 10–12 weeks (Fig. 3).

Three and a half months after the initial scheduled surgery (17th February 2015), the patient underwent wire guided wide local excision of the tumour and sentinel node biopsy on 2nd June 2015. The final pathology report confirmed a 12 mm invasive lobular carcinoma excised with clear margins. Lymphovascular invasion was absent and the sentinel lymph node was free of metastasis. She received postoperative breast radiotherapy with tumour bed boost and is currently on tamoxifen (20 mg/d), a selective oestrogen receptor modulator (SERM), rather than an aromatase inhibitor for adjuvant systemic therapy.

3. Discussion

Leukocytoclastic vasculitis is an immune complex-mediated reactive transient small-vessel vasculitis. It causes 10–20% of all small-vessel vasculitides [9]. Cutaneous leukocytoclastic small vessel vasculitis (CLSVV) is a diagnosis of exclusion, and infection and

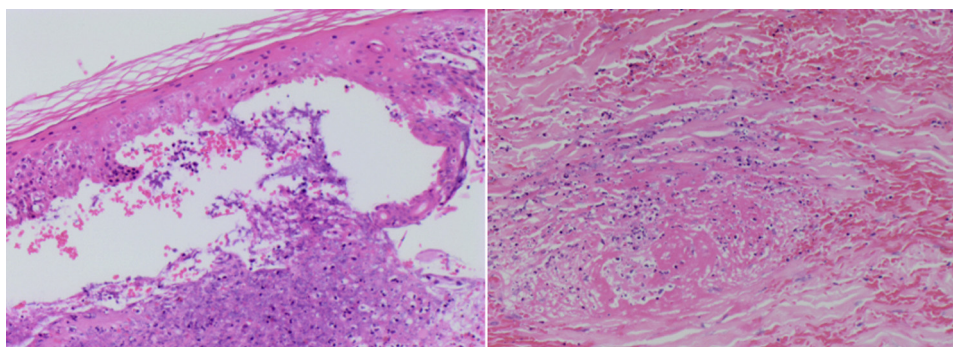


Fig. 2. Left HE; $\times 100$ magnification: Necrotic epidermis lies partly detached from the underlying dermis to form a subepidermal blister. Right HE; $\times 200$ magnification: Dermal changes of fibrinoid necrosis involving small vessels, karyorrhectic debris (leucocytoclasia) and red blood cell extravasation.

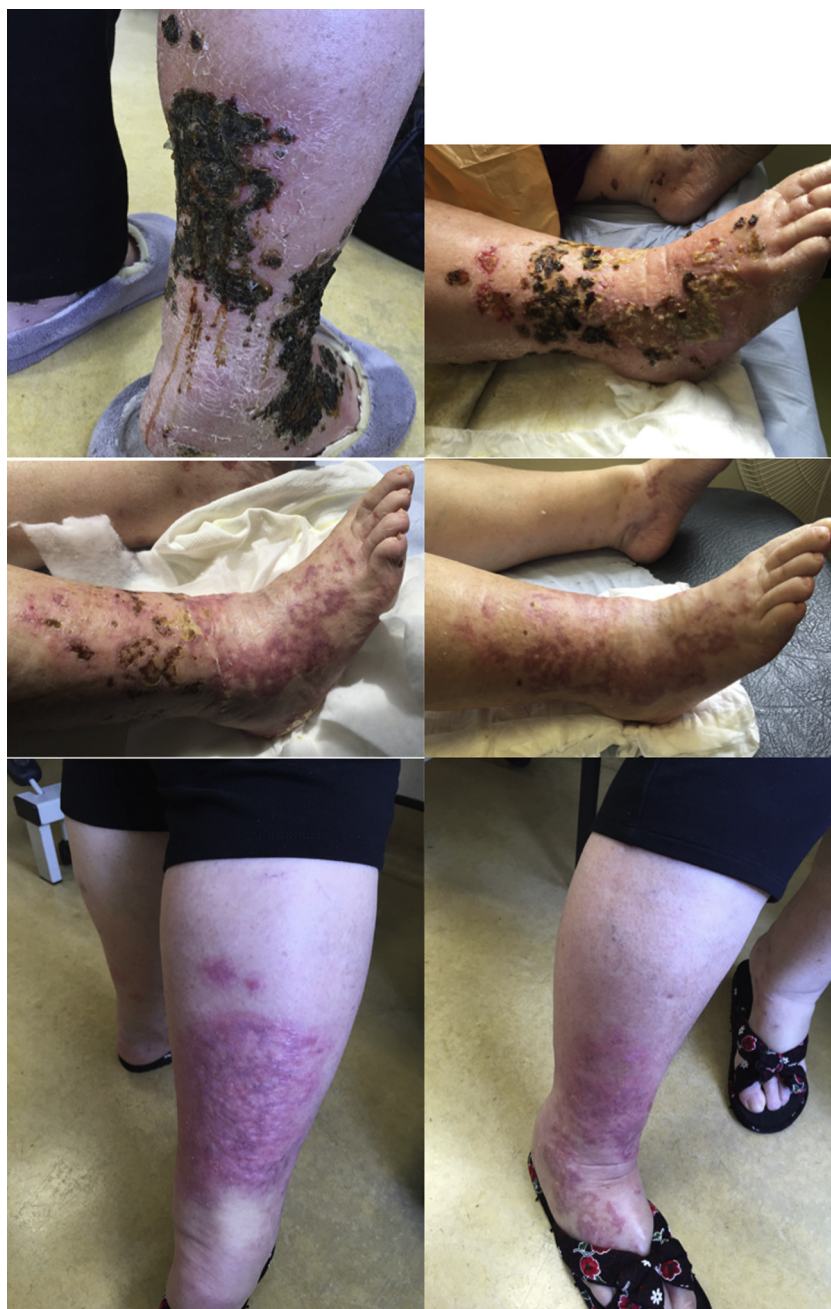

Fig. 3. The lesions at 1 month top left (18th March 2015), 6 weeks top right (30th March 2015), 12 weeks middle left (11th May 2015), 14 weeks middle right (20th May 2015), and 18 weeks bottom left and bottom right (both 15th June 2015).

connective tissue disease need to be ruled out by negative ANCA levels and through biopsy. Over 100 drugs have been known to cause either CLSVV or drug-induced lupus, though the absolute frequency of drug-induced vasculitis is approximately 1/100,000 people [10,11].

The pathogenesis of aromatase inhibitor induced vasculitis is not fully understood. It is thought that higher circulating oestrogen levels inhibit neutrophil function. Therefore, the reduction of oestrogen due to aromatase inhibition could increase neutrophil activity. This would account for the high levels of neutrophils seen in the biopsy. Neutrophils adhere to the blood vessel endothelium, resulting in autoimmunity [12]. Similar case reports have also postulated that the down-regulation of oestrogen could in fact directly induce vasculitis [4,6]. A similar vasculitic reaction around the ankles occurred in a patient after commencing letrozole in

Switzerland in 2014 [1]. As this is a hypersensitivity reaction, not an allergy, we do not believe that the preservatives or excipients could be implicated.

It is important to think about vasculitis as a spectrum. Although often asymptomatic, patients can present with non-specific symptoms such as fever and malaise, cutaneous symptoms such as localised pain, pruritus and palpable purpura, or multi-organ failure affecting the kidney and the lung [13]. Skin lesions arise in clusters and commonly affect the lower legs and ankles [14].

The CLSVV in this patient was histologically characterised by three main features. Firstly, karyorrhexis of neutrophil nuclei, also known as leukocytoclasia. Secondly, vascular damage from the leukocytoclastic granules and fibrinoid necrosis. Thirdly, the presence of tissue eosinophilia. Though tissue eosinophilia is not specific for CLSVV, Bahrami et al. found that it was significantly

more common in drug-induced CLSVV compared to small-vessel vasculitides not caused by drugs [15].

CLSVV is a transient vasculitis and usually self-limiting. As such, treatment is often unnecessary. The drug causing the reaction needs to be removed; and stasis needs to be minimised by compression, elevation and the use of non-steroidal anti-inflammatory drugs. Anti-histamines and systemic corticosteroids may need to be prescribed, particularly when the cutaneous lesions are progressive, as in our case. Up to 10% of patients could suffer from recurrent disease.

It is possible that the CLSVV was unrelated to letrozole. It might have been related to the pneumonitis, rather than the other way round. It is unlikely to have been a paraneoplastic phenomenon [14,16] because the vasculitis improved while the tumour remained in situ and the tumour may have reduced in size (as discussed below).

It is interesting that the final histological tumour size was smaller (12 mm) than the initial tumour size seen on imaging (15 mm on mammography, 18 mm on ultrasound and 21 mm on MRI); the patient had taken letrozole for less than 2 weeks followed by nearly 4 months of no specific treatment for the cancer. Although we do not have tumour size measurement when the drug was stopped, it is unlikely to have reduced so dramatically, so one could speculate that the immune reaction leading to the vasculitis might have had a tumour suppressive effect.

4. Conclusion

In conclusion, we report the second case worldwide of CLSVV very likely to be secondary to letrozole treatment. In all patients with this presentation, it is important to exclude systemic primary vasculitides, which would require treatment with immunosuppressant therapy. CLSVV is a transient hypersensitivity reaction with good prognosis. The suspected offending drug needs to be discontinued and symptomatic treatment should be given and may need to be supplemented with local and systemic steroids. Although exceptionally rare and not life threatening, it is important to keep in mind this alarming side effect of letrozole, particularly because it is a commonly used drug in breast cancer treatment. It is interesting that the cancer did not appear to grow during the 4 months of 'no-treatment' after the initial 10–12 days of letrozole treatment and may have even shrunk.

Conflict of interest

Authors have no conflict of interest to declare.

Funding

Authors have no sources of funding to declare.

Ethical approval

No ethical approval needed for this manuscript.

Author contribution

Pirunthan Pathmarajah: Study concept, data acquisition and manuscript writing.

Karishma Shah: Study concept, data acquisition and manuscript writing.

Open Access

This article is published Open Access at sciedirect.com. It is distributed under the [IJSCR Supplemental terms and conditions](#), which permits unrestricted non commercial use, distribution, and reproduction in any medium, provided the original authors and source are credited.

Kathy Taghipour: Management of case, data interpretation and manuscript revision. Su Ramachandra: Data interpretation and manuscript writing

Emma Spurrell and Jeffrey S Tobias: Manuscript revision.

Ziaullah Chaudhry, Vivek Patkar, Francesca Peters, Thomas Connor & Mangesh Thorat: Management of case & Manuscript revision.

Jayant S Vaidya: Study concept, management of case, data acquisition, interpretation and manuscript writing and revision.

Guarantor

Professor Jayant S Vaidya.

Consent

Written informed consent was obtained from the patient for publication of this case report and accompanying images. A copy of the written consent is available for review by the Editor-in-Chief of this journal on request.

Acknowledgements

The authors thank rest of the Whittington breast multidisciplinary team including Veronica Conteh, Lucy Mavriano, Elizabeth Tamufor, Eugene Massassa, Elzbieta Lupienska, Peng H. Tan, Debashish Ghosh and Mulyati Mohamed for helping in the care of this patient throughout.

References

- [1] A. Digkila, E. Tzika, I.A. Voutsadakis, Cutaneous leukocytoclastic vasculitis associated with letrozole, *J. Oncol. Pharm. Pract.* 20 (2) (2014) 146–148.
- [2] K. Jhaveri, P. Halperin, S.J. Shin, L. Vahdat, Erythema nodosum secondary to aromatase inhibitor use in breast cancer patients: case reports and review of the literature, *Breast Cancer Res. Treat.* 106 (3) (2007) 315–318.
- [3] M. Trancart, A. Cavailles, B. Balme, F. Skowron, Anastrozole-induced subacute cutaneous lupus erythematosus, *Br. J. Dermatol.* 158 (3) (2008) 628–629.
- [4] S. Santoro, M. Santini, C. Pepe, E. Tognetti, C. Cortelazzi, E. Ficarelli, et al., Aromatase inhibitor-induced skin adverse reactions: exemestane-related cutaneous vasculitis, *J. Eur. Acad. Dermatol. Venereol.* 25 (5) (2011) 596–598.
- [5] T. Bremec, J. Demsar, B. Luzar, M.D. Pavlovic, Drug-induced pruritic micropapular eruption: anastrozole, a commonly used aromatase inhibitor, *Dermatol. Online J.* 15 (7) (2009) 14.
- [6] M. Wong, J. Grossman, B.H. Hahn, A. La Cava, Cutaneous vasculitis in breast cancer treated with chemotherapy, *Clin. Immunol. (Orlando Fla)* 129 (1) (2008) 3–9.
- [7] H. Shoda, S. Inokuma, N. Yajima, Y. Tanaka, K. Setoguchi, Cutaneous vasculitis developed in a patient with breast cancer undergoing aromatase inhibitor treatment, *Ann. Rheum. Dis.* 64 (4) (2005) 651–652.
- [8] M. Conti-Beltraminelli, O. Pagani, G. Ballerini, A. Richetti, R. Graffeo, M. Ruggeri, et al., Henoch-Schonlein purpura (HSP) during treatment with anastrozole, *Ann. Oncol.* 18 (1) (2007) 205–207.
- [9] J.J. Dubost, P. Souteyrand, B. Sauvezie, Drug-induced vasculitides, *Baillieres's Clin. Rheumatol.* 5 (1) (1991) 119–138.
- [10] M.C. Calvino, J. Llorca, C. Garcia-Porrúa, J.L. Fernandez-Iglesias, P. Rodriguez-Ledo, M.A. Gonzalez-Gay, Henoch-Schonlein purpura in children from northwestern Spain: a 20-year epidemiologic and clinical study, *Medicine* 80 (5) (2001) 279–290.
- [11] P.A. Merkel, Drug-induced vasculitis, *Rheum. Dis. Clin. N. Am.* 27 (4) (2001) 849–862.
- [12] B. Styrts, B. Sugarman, Estrogens and infection, *Rev. Infect. Dis.* 13 (6) (1991) 1139–1150.
- [13] M. Radic, D. Martinovic Kaliterna, J. Radic, Drug-induced vasculitis: a clinical and pathological review, *Neth. J. Med.* 70 (1) (2012) 12–17.
- [14] D.F. Fiorentino, Cutaneous vasculitis, *J. Am. Acad. Dermatol.* 48 (3) (2003) 311–340.
- [15] S. Bahrami, J.C. Malone, K.G. Webb, J.P. Callen, Tissue eosinophilia as an indicator of drug-induced cutaneous small-vessel vasculitis, *Arch. Dermatol.* 142 (2) (2006) 155–161.
- [16] R. Solans-Laqué, J.A. Bosch-Gil, C. Perez-Bocanegra, A. Selva-O'Callaghan, C.P. Simeon-Aznar, M. Vilardell-Tarres, Paraneoplastic vasculitis in patients with solid tumors: report of 15 cases, *J. Rheumatol.* 35 (2) (2008) 294–304.