

An Unusual Case of Atrial Wall Cardiac Sarcoidosis Detected on Fluorine-18 Fluorodeoxyglucose Positron Emission Tomography-Computed Tomography Scan

Abstract

Isolated cardiac sarcoidosis (ICS) accounts for 5%–10% of patients with sarcoidosis. It can involve atrioventricular node causing heart block, as well as the basal septum, papillary muscles, focal regions in the free wall, and the myocardium being more commonly involved. The diagnosis is achieved on magnetic resonance imaging (MRI) and endomyocardial biopsy. Recently, Fluorine-18 fluorodeoxyglucose positron emission tomography and computed tomography (F-18 FDG PET) has been incorporated in the diagnosis as well as management algorithm. We describe an interesting case of ICS detected on F-18 FDG PET and MRI and discuss its role in the management of this rare presentation.

Keywords: Fluorodeoxyglucose positron emission tomography, isolated cardiac sarcoidosis, magnetic resonance imaging

Introduction

Sarcoidosis is a systemic granulomatous disease most commonly affecting the patients of 25–60 years of age.^[1,2] Cardiac involvement occurs in 5% of these patients with symptoms of palpitations, chest pain, dyspnea, and fatigue. Isolated cardiac sarcoidosis (ICS), however, is rare. Fluorodeoxyglucose positron emission tomography-computed tomography (FDG PET-CT) scan has been added to the diagnostic algorithm of cardiac sarcoidosis (CS), which so far included chest X-ray, echocardiography (2D-echo), electrocardiogram (EKG), cardiac magnetic resonance imaging (MRI), and endomyocardial biopsy. It is also helpful for therapeutic response assessment. We present a case of ICS and discuss various findings on F-18 FDG PET/CT and MRI in our patient and discuss the relevant literature.

Case Report

A 50-year-old male presented with complaints of low-grade intermittent fever for 1 month associated with chest heaviness, anorexia, and loss of weight. His workup for pyrexia of unknown origin revealed a positive antinuclear antibody (1:320) and

right-sided pleural effusion on chest X-ray and pleural tap revealed mesothelial cells, few lymphocytes, and neutrophils with no malignant cells. Serum calcium and angiotensin-converting enzyme levels were within the normal range. 2D-echo was normal apart from mild pericardial effusion.

In view of persistent pyrexia of unknown origin and no significant contributory findings on the conventional investigations, F-18 FDG PET/CT scan was performed to detect the source of infection/inflammation.

F-18 FDG PET/CT imaging was performed on an integrated scanner (Biograph™ scanners, PET/CT scanner, Siemens Healthineers). After an overnight fasting of 12 h, the patient was injected with 7 mCi (259 megabecquerel) of F-18 FDG, and images were obtained at 1 and 3 h; contrast CT images were also obtained. The blood sugar level before FDG injection was 110 mg/dl.

The study revealed high-grade (SUV_{max} 10) metabolic activity in both atrial walls and interatrial septum with extensive involvement of the left atrial wall [Figure 1]. The possibilities of sarcoidosis, atrial fibrillation, and lipomatous hypertrophy were considered. The patient had no atrial fibrillation, and CT was negative for

Raksha Jeevan Rao Kulkarni, Aniruddha Y Phadke¹, Pralhad P Prabhudesai², Krishna A Balkundi

Departments of Nuclear Medicine, ¹Gastroenterology and ²Respiratory Medicine, Lilavati Hospital and Research Centre, Mumbai, Maharashtra, India

Address for correspondence:

Dr. Raksha Jeevan Rao Kulkarni, Department of Nuclear Medicine, Lilavati Hospital and Research Centre, A-791, Bandra Reclamation, Bandra West, Mumbai - 400 050, Maharashtra, India. E-mail: iamrakshajk.10@gmail.com

Received: 03-08-2020

Revised: 13-08-2020

Accepted: 13-08-2020

Published: 04-03-2021

Access this article online

Website: www.ijnm.in

DOI: 10.4103/ijnm.IJNM_178_20

Quick Response Code:



How to cite this article: Rao Kulkarni RJ, Phadke AY, Prabhudesai PP, Balkundi KA. An unusual case of atrial wall cardiac sarcoidosis detected on fluorine-18 fluorodeoxyglucose positron emission tomography-computed tomography scan. Indian J Nucl Med 2021;36:46-9.

This is an open access journal, and articles are distributed under the terms of the Creative Commons Attribution-NonCommercial-ShareAlike 4.0 License, which allows others to remix, tweak, and build upon the work non-commercially, as long as appropriate credit is given and the new creations are licensed under the identical terms.

For reprints contact: reprints@medknow.com

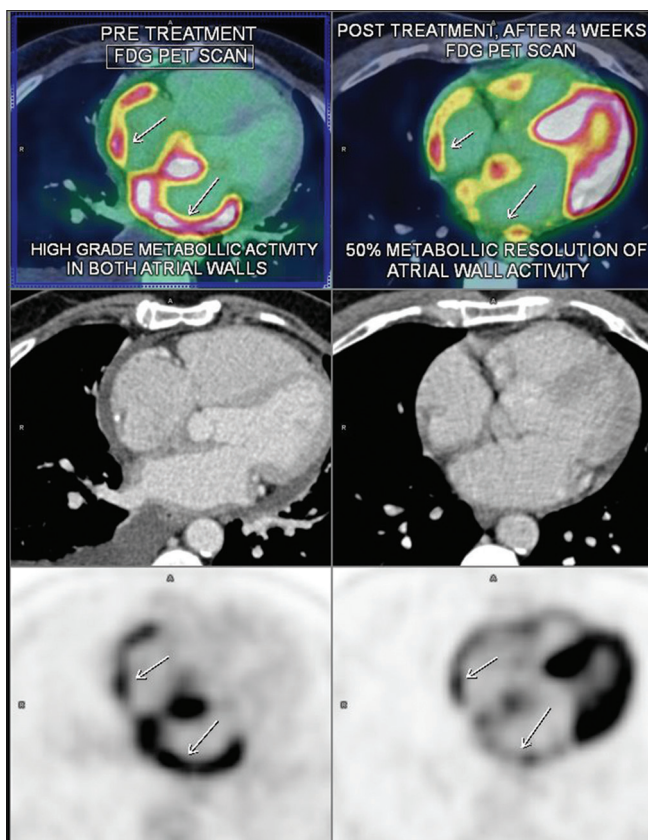


Figure 1: Pretreatment fluorodeoxyglucose positron emission tomography and computed tomography scan (on the left) shows high-grade metabolic activity in both atrial walls, interatrial septum with extensive left atrial wall involvement, posttreatment scan (on the right) shows about 50% decrease in the metabolic activity along the right and left atrium

lipomatous pattern. Hence, high probability of sarcoidosis was raised. The ventricles did not show any appreciable abnormality. There was low-grade metabolic activity in the bilateral pleural effusion and moderate pericardial effusion, which were in the reactive range. The liver, spleen, lungs, and nodal stations did not reveal any abnormality.

To confirm the PET-CT findings, the patient underwent a cardiac MRI [Figure 2] which revealed suspicious delayed enhancement in the inferior part of interatrial septum, minimal myocardial enhancement in the basal interventricular septum of indeterminate etiology, and mild pericardial effusion.

A day after the FDG PET-CT, the patient developed episodes of giddiness. His cardiac evaluation revealed bradycardia (pulse rate of 48/min). The electrocardiography revealed junctional rhythm, and ejection fraction was normal on 2D-echo. There was no ventricular involvement either on the FDG-PET study or on the 2D-echo evaluation. As it was purely an atrial wall abnormality and even the referring cardiologist was not keen on any further study as the patient got admitted with junctional rhythm in the intensive care unit a day after the PET-CT study, hence myocardial perfusion imaging (MPI) was not considered.

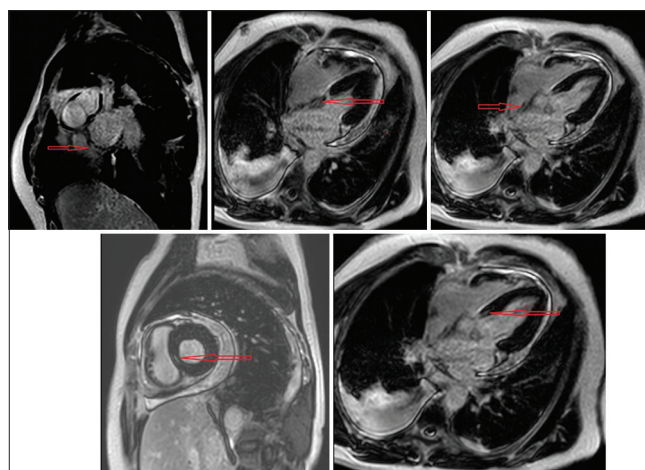


Figure 2: Top row shows delayed enhancement in the inferior part of interatrial septum, bottom row shows minimal enhancement in the basal interventricular septum (as marked)

Since both the FDG PET-CT and MRI raised the possibility of ICS and endomyocardial biopsy was considered risky in the presence of junctional rhythm, the patient was started on oral prednisolone 40 mg once daily and tablet orceprinaline.

The patient improved over the next week after which prednisolone dose was tapered gradually and was maintained on a dose of 5 mg OD. After 30 days of treatment, patient's heart rhythm had normalized, and all the symptoms had regressed. The follow-up F-18 FDG PET-CT scan was done after 30 days of treatment. The blood sugar level before FDG injection was 118 mg/dl. The scan revealed 50% decrease in the metabolic activity along the right atrium and the left atrium, suggesting fairly good response in 1 month [Figures 1,3,4]. The patient is currently on 5 mg prednisolone and doing well at follow-up.

Since the first PET-CT was done for pyrexia of unknown origin, and at no stage, sarcoidosis was under consideration, hence PET-CT was done using conventional protocol (modified diet/injection heparin protocol was not followed). Therefore, during follow-up also, we had to perform using the conventional protocol for quantitative as well as qualitative analysis.

Discussion

ICS is challenging and is difficult to diagnose as existence of the cardiac lesion should be detected from cardiac manifestations alone. The most common clinical manifestations of ICS are dyspnea, syncope, and palpitations. CS can cause dilated/restrictive cardiomyopathy which can lead to heart failure. CS most frequently involves the left ventricular free wall (96%), followed by the interventricular septum (73%), whereas the atrial wall is rarely affected (right, 11%; left, 7%).^[3] Enzan *et al.* reported a patient with left atrial CS manifesting as left atrial reentrant tachycardia.^[4]

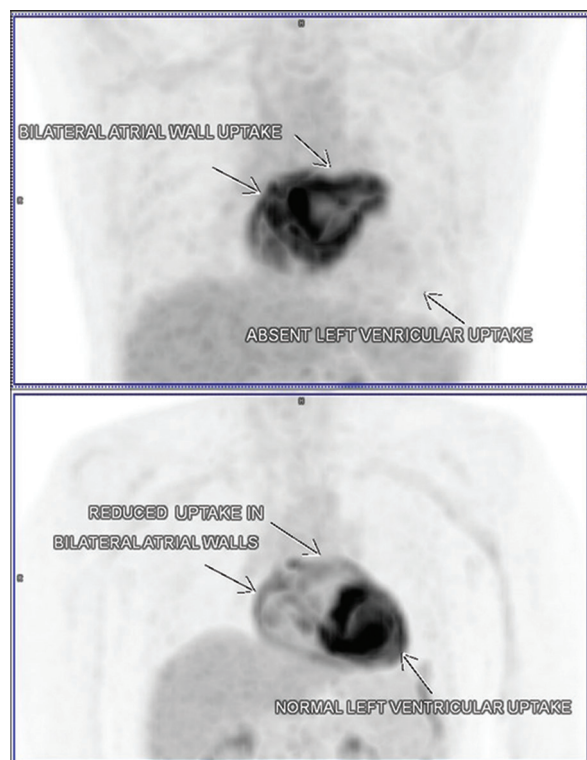


Figure 3: The maximum intensity projection image of the chest, the top image (pretreatment) shows bilateral atrial wall uptake with absent left ventricular uptake and the bottom image (posttreatment) shows reduced atrial wall uptake with normal left ventricular uptake

CS is usually a diagnosis of exclusion, as the available diagnostic tests have limited sensitivity and specificity and the absence of true biological marker. Atrioventricular block and right bundle branch block are more commonly seen EKG changes. The 2D-echo findings are usually nonspecific although basal interventricular thinning,^[5] ventricular systolic and diastolic dysfunction, isolated wall motion abnormalities, and aneurysms can be feature of CS.^[6,7]

There is no specific pattern of late gadolinium enhancement (LGE) on cardiac MRI that is diagnostic for CS, and it is patchy, multifocal with sparing of the endocardial border.^[8,9] LGE is most commonly seen in basal segments, particularly of the septum and lateral wall, and usually in the midmyocardium and epicardium of the myocardium.^[10-12]

FDG is a glucose analog that is useful in differentiating between normal and active inflammatory lesions where the activated pro-inflammatory macrophages show a higher metabolic rate and glucose utilization.^[13] It has been suggested that PET might be useful as a disease activity marker to guide CS therapy. The suppression of physiological FDG uptake in the cardiac muscle is a key factor in optimizing diagnostic accuracy.

On a pathophysiologic basis, CS may alter coronary microcirculation, leading to myocardial perfusion defects. These defects may represent either active

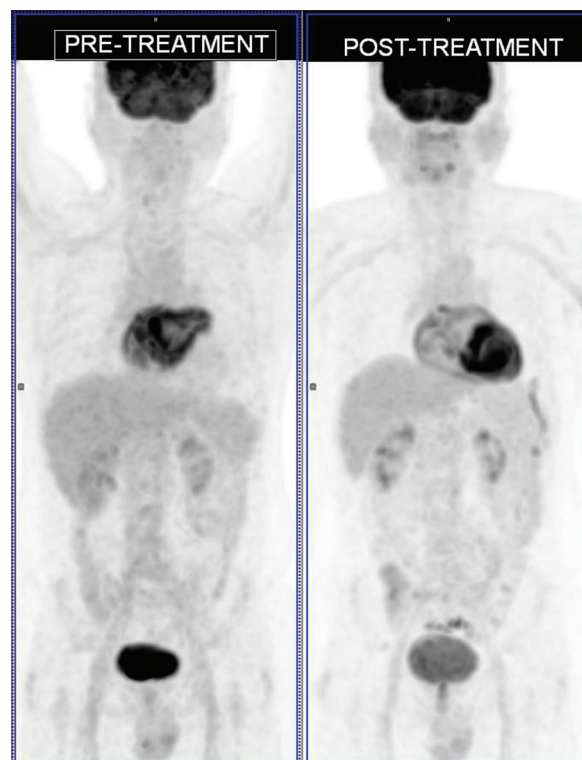


Figure 4: The whole-body pretreatment maximum intensity projection image (on the left) and posttreatment maximum intensity projection image (on the right)

inflammation or scar, with abnormal FDG uptake representing inflammation. Based on the different uptake patterns, various classifications of the scintigraphic images (FDG-PET and MPI) have been proposed: early (only FDG positive), progressive inflammatory (FDG positive without major perfusion defects), peak active (high SUV FDG uptake with small perfusion defects), progressive myocardial impairment (high SUV FDG uptake with large perfusion defects), or fibrosis-predominant (FDG negative, but with perfusion defects).

Endomyocardial biopsy reveals noncaseating epithelioid cell granulomas with multinucleated giant cells, but it has low sensitivity due to the focal nature of the disease. To increase sensitivity, electroanatomic mapping or image-guided (PET or cardiac MRI) biopsy procedures are now recommended.

Our case demonstrates the utility of FDG PET-CT in the diagnosis of Cardiac Sarcoidosis. It is an unusual case with predominantly involving atrial wall which probably explains the absence of any significant cardiac symptoms which are common with ventricular involvement. The MRI findings also suggest possibility of early disease with very minimal contrast enhancement changes. Since endomyocardial biopsy is risky with many complications, FDG PET-CT would act as a reliable alternative with response assessment benefit as well.

Declaration of patient consent

The authors certify that they have obtained all appropriate patient consent forms. In the form the patient (s) has/have given his/her/their consent for his/her/their images and other clinical information to be reported in the journal. The patients understand that their names and initials will not be published and due efforts will be made to conceal their identity, but anonymity cannot be guaranteed.

Financial support and sponsorship

Nil.

Conflicts of interest

There are no conflicts of interest.

References

1. Morimoto T, Azuma A, Abe S, Usuki J, Kudoh S, Sugisaki K, *et al.* Epidemiology of sarcoidosis in Japan. *Eur Respir J* 2008;31:372-9.
2. Hillerdal G, Nöu E, Osterman K, Schmekel B. Sarcoidosis: Epidemiology and prognosis. A 15-year European study. *Am Rev Respir Dis* 1984;130:29-32.
3. Roberts WC, McAllister HA, Jr., Ferrans VJ. Sarcoidosis of the heart: A clinicopathologic study of 35 necropsy patients (group I) and review of 78 previously described necropsy patients (group II). *Am J Med* 1977;63:86-108.
4. Enzan N, Ohtani K, Nagaoka K, Sakamoto I, Tsutsui H. Left atrial involvement of cardiac sarcoidosis manifesting as left atrial re-entrant tachycardia. *Eur Heart J Cardiovasc Imaging* 2019;20:948.
5. Ayyala US, Nair AP, Padilla ML. Cardiac sarcoidosis. *Clin Chest Med* 2008;29:493-508, ix.
6. Sköld CM, Larsen FF, Rasmussen E. Determination of cardiac involvement in sarcoidosis by magnetic resonance imaging and Doppler echocardiography. *J Intern Med* 2002;252:465-71.
7. Burstow DJ, Tajik AJ, Bailey KR, DeRemee RA, Taliercio CP. Two-dimensional echocardiographic findings in systemic sarcoidosis. *Am J Cardiol* 1989;63:478-82.
8. Ichinose A, Otani H, Oikawa M, Takase K, Saito H, Shimokawa H, *et al.* MRI of cardiac sarcoidosis: Basal and subepicardial localization of myocardial lesions and their effect on left ventricular function. *AJR Am J Roentgenol* 2008;191:862-9.
9. Cummings KW, Bhalla S, Javidan-Nejad C, Bierhals AJ, Gutierrez FR, Woodard PK. A pattern-based approach to assessment of delayed enhancement in nonischemic cardiomyopathy at MR imaging. *Radiographics* 2009;29:89-103.
10. Patel MR, Cawley PJ, Heitner JF, Klem I, Parker MA, Jaroudi WA, *et al.* Detection of myocardial damage in patients with sarcoidosis. *Circulation* 2009;120:1969-77.
11. Smedema JP, Snoep G, van Kroonenburgh MP. Evaluation of the accuracy of gadolinium-enhanced cardiovascular magnetic resonance in the diagnosis of cardiac sarcoidosis. *J Am CollCardiol* 2005;45:1683-90.
12. Patel AR, Klein MR, Chandra S, Spencer KT, Decara JM, Lang RM, *et al.* Myocardial damage in patients with sarcoidosis and preserved left ventricular systolic function: An observational study. *Eur J Heart Fail* 2011;13:1231-7.
13. Pellegrino D, Bonab AA, Dragotakes SC, Pitman JT, Mariani G, Carter EA. Inflammation and infection: Imaging properties of 18F-FDG-labeled white blood cells versus 18F-FDG. *J Nucl Med* 2005;46:1522-30.