

Received: 2012.09.12  
Accepted: 2013.01.02

## Intervertebral disc calcification in children: Case description and review of relevant literature

Dominik Sieroń<sup>1</sup>, Katarzyna Gruszczyńska<sup>2</sup>, Magdalena Machnikowska-Sokołowska<sup>3</sup>,  
Zbigniew Olczak<sup>3</sup>, Daniel Knap<sup>2</sup>, Jan Baron<sup>2</sup>

<sup>1</sup> District Hospital of Orthopedics and Trauma Surgery, Piekary Śląskie, Poland

<sup>2</sup> Department of Radiology and Nuclear Medicine, Silesian University School of Medicine, Katowice, Poland

<sup>3</sup> Division of Diagnostic Imaging, Department of Radiology and Nuclear Medicine, Medical University of Silesia, University Hospital no. 6, John Paul II Upper Silesian Centre for Child Care, Katowice, Poland

**Author's address:** Dominik Sieroń, District Hospital of Orthopedics and Trauma Surgery, Piekary Śląskie, Poland,  
e-mail: dominik.sieron@googlemail.com

### Summary

<b>Background:</b>	Intervertebral disc calcification is a rare condition in children; in most cases, it is asymptomatic and therefore not diagnosed.
<b>Case Reports:</b>	In our study, we present a case of idiopathic intervertebral disc calcification within the cervical segment, at the level of C2/C3 and C4/C5 vertebrae in a 5-year-old girl with torticollis. Basic neurological examination supplemented by X-ray examination was performed, showing calcification within the cervical segment at the level of C2/C3 and C4/C5 vertebrae.
<b>Conclusions:</b>	In order to complement the diagnostics, a CT scan of the cervical spine was performed; the scan confirmed the diagnosis and revealed additional calcification of the anterior longitudinal ligament at the level of C4/C5 vertebrae.
<b>Key words:</b>	intervertebral disc • calcification • neck pain • childhood
<b>PDF file:</b>	<a href="http://www.polradiol.com/fulltxt.php?ICID=883773">http://www.polradiol.com/fulltxt.php?ICID=883773</a>

### Background

Idiopathic intervertebral disc calcification is a very rare condition in children, with less than 200 cases reported to date.

In a vast majority of cases, children do not experience any pain symptoms, and therefore the diagnosis of calcification lesions is largely incidental. However, in some cases patients may experience pain within the spine or the head, nausea, possibly reduced range of motion of cervical spine or torticollis. Epidemiology of intervertebral disc calcification reveals higher incidence in boys [1]. The mean age of onset is 7.7 years [2].

### Case Reports

A 5-year-old girl with headaches, torticollis and neck pains was presented at the neurological outpatient clinic.

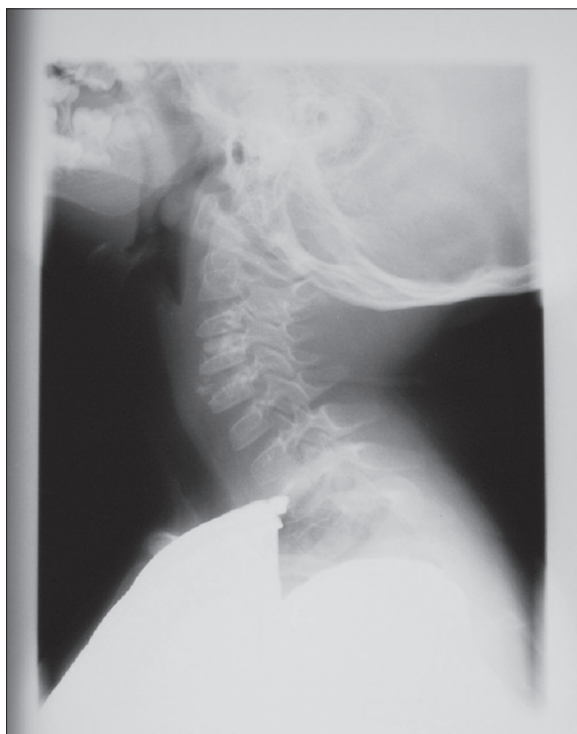The patient was subjected to neurological examination. Anteroposterior and right lateral X-ray scans were performed to complement the diagnostics.

The X-rays revealed intervertebral calcifications at the level of the C2/C3 vertebrae as well as irregular calcifications at the C3/C4 level and calcification of the anterior longitudinal ligament (Figure 1).

A CT scan was performed for more accurate assessment of the cervical spine structures, confirming the X-ray image and diagnosis (Figures 2 and 3).

### Discussion

The etiology of intervertebral disc calcifications in children is poorly understood. Some isolated reports suggest that the lesions are of traumatic origin [3,4]; this, however, was never proven.

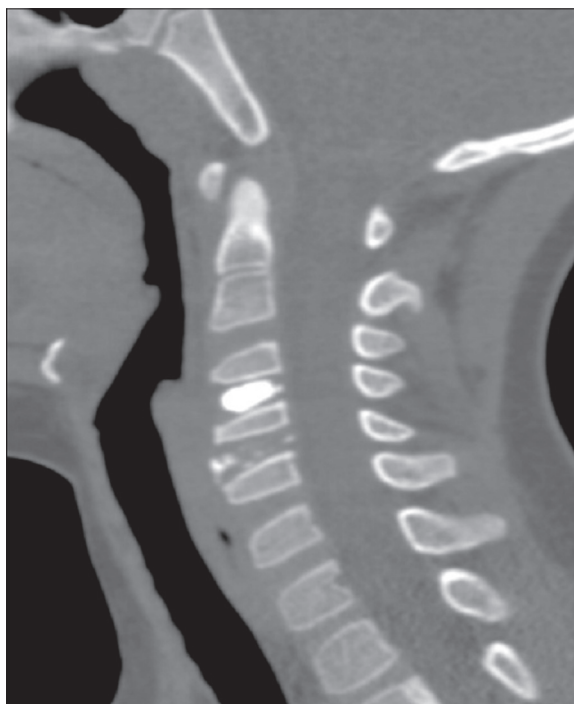


**Figure 1.** Lateral X-ray of cervical spine at retroversion reveals oval intervertebral disc calcification at the level of C2/C3 vertebrae as well as irregular calcifications at the C3/C4 level and calcification of the anterior longitudinal ligament.

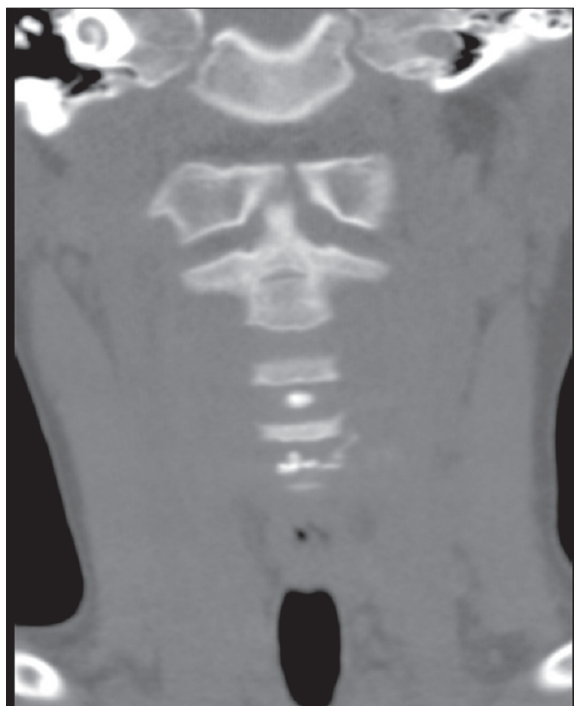In most cases, intervertebral disc calcifications within the cervical spine do not evoke clinical symptoms [5–7] and are diagnosed in an incidental manner upon X-ray examinations performed for other reasons [8]. The patient described in this study was presented at the physician's office due to pain symptoms and torticollis.

Recent retrospective study by Beluffi et al. [5] showed how uncommon are intervertebral discs calcifications in children and how rarely they are accompanied by pain disorders. Beluffi et al. assessed a pediatric study population aged 0–18 back over the period of 26 years. As shown by their studies, calcifications occurred in as little as 6 children, of whom 5 were asymptomatic and only one experienced pain symptoms. Another retrospective study conducted by Zhang et al. [9] in a study group consisting of 10 children (5 girls and 5 boys) at the mean age of 9.4 years showed that only 3 out of 10 children had pain symptoms translating into nerve root compression, intervertebral disc protrusion without spinal cord compression, or subluxation of the C1 and C2 vertebrae, respectively, as observed by X-ray imaging. Gerlach et al. [3] presented a case of a 10-year old girl with cervical spine calcifications at the C6/C7 and Th1/Th2 level with C7/Th1 herniation compressing the spinal cord. In such cases, as well as in the case of persisting pain, intervertebral discectomy or intervertebral disc arthroplasty with or without arthrodesis is performed [4,10].

However, as shown by the literature review, in most cases the pain symptoms subside after several days as the result of analgesic and anti-inflammatory treatment [11,12].



**Figure 2.** Sagittal CT scan reveals a regular oval calcification within the C2/C3 intervertebral disc and irregular calcifications in the anterior part of the C3/C4 intervertebral disc and in the anterior longitudinal ligament at the same level.



**Figure 3.** Coronal CT scan reveals calcifications at the C2/C3 level and calcifications in the anterior part of the C3/C4 intervertebral disc and in the anterior longitudinal ligament at the same level.

Complete regression of intervertebral disc calcifications as observed in X-ray images in the study groups occurred after 2–8 months [5,9,11].

In their retrospective study, Wong et al. [7] suggested the occurrence of subsequent intervertebral disc changes as regards the length and width of the disc in adults with the history of intervertebral disc calcifications in childhood.

Intervertebral disc calcifications should be differentiated from inflammatory or post-inflammatory lesions with the intervertebral discs [13].

## References:

1. Falcone L, Rossiello P, D'Addetta I et al: Idiopathic intervertebral disc calcification in children: the role of diagnostic imaging. A case report. *Reumatismo*, 2006; 58(1): 62-65
2. Dai LY, Ye H, Qian QR: The natural history of cervical disc calcification in children. *J Bone Joint Surg Am*, 2004; 86-A(7): 1467-72
3. Gerlach R, Zimmermann M, Kellermann S et al: disc calcification in childhood – a case report and review of the literature. *Acta Neurochir (Wien)*, 2001; 143(1): 89-93
4. Mainzer F: Herniation of the nucleus pulposus. A rare complication of intervertebral-disk calcification in children. *Radiology*, 1973; 107: 167-70
5. Beluffi G, Fiori P, Sileo C: Intervertebral disc calcifications in children. *Radiol Med*, 2009; 114(2): 331-41
6. Eyring EJ, Peterson CA, Bjornson DR: Intervertebral-disc calcification in childhood: a distinct clinical syndrome. *J Bone Joint Surg Am*, 1964; 46: 1432-41
7. Wong CC, Pereira B, Pho RW: Cervical disc calcification in children. A long-term review. *Spine*, 1992; 17(2): 139-44
8. Ginalski JM, Landry M, Gudinchet F et al: Is tomography of intervertebral disc calcification useful in children? *Pediatr Radiol*, 1992; 22(1): 59-61
9. Zhang K, Dang G, Lou S: Cervical intervertebral disc calcification in children: report of 10 patients. *Zhonghua Wai Ke Za Zhi*, 1996; 34(4): 197-200
10. Oga M, Terada K, Kikuchi N et al: Herniation of calcified cervical intervertebral disc causes dissociated motor loss in a child. *Spine*, 1993; 18(15): 2347-50
11. Lernout C, Haas H, Rubio A et al: Pediatric intervertebral disk calcification in childhood: three case reports and review of literature. *Childs Nerv Syst*, 2009; 25(8): 1019-23
12. Pilliard D, Masse P, Taussig G: Intervertebral disc calcification in childhood. *Rev Chir Orthop Reparatrice Appar Mot*, 1980; 66(8): 515-21
13. PD Aker, AA Lopes, K Yong-Hing et al: Cervical disc calcification in children: a case report. *J Can Chiropr Assoc*, 1989; 33(4): 191-94

## Conclusions

Intervertebral disc calcification occurring within the cervical segment in children is a very rare condition, which usually resolves spontaneously and is asymptomatic in a vast majority of cases. Intervertebral disc calcification should be taken into account in the diagnostics of children with pains within the neck region.