



EndoFLIP assessment of pyloric sphincter in children: a single-center experience

Mara Popescu¹, Emily White², Mohamed Mutalib^{1,2^}

¹Faculty of Life Sciences and Medicine, Kings College London, London, UK; ²Department of Paediatric Gastroenterology, Evelina London Children's Hospital, London, UK

Contributions: (I) Conception and design: M Mutalib; (II) Administrative support: All authors; (III) Provision of study materials or patients: E White, M Mutalib; (IV) Collection and assembly of data: All authors; (V) Data analysis and interpretation: M Popescu, E White; (VI) Manuscript writing: All authors; (VII) Final approval of manuscript: All authors.

Correspondence to: Mohamed Mutalib. Department of Paediatric Gastroenterology, Evelina London Children's Hospital, Westminster Bridge Road, London SE1 7EH, UK. Email: Mohamed.mutalib@gstt.nhs.uk.

Background: Gastrointestinal complaints are common in children with neurodisabilities, vomiting, retching and poor feed tolerance are frequently reported. Endolumenal functional lumen imaging probe (EndoFLIP) is used to assess compliance and distensibility of the pylorus and can predict response to Botulinum Toxin in adult with gastroparesis. We aimed to review pyloric muscle measurements using EndoFLIP in children with neuromuscular disabilities and significant foregut symptoms and to assess the clinical response to intrapyloric Botulinum Toxin.

Methods: Retrospective review of clinical notes of all children who underwent pyloric EndoFLIP assessment in Evelina London Children's Hospital from March 2019 to January 2022. EndoFLIP catheter was inserted at the time of endoscopy via existing gastrostomy tract.

Results: A total of 335 measurement from 12 children were obtained, mean age 10.7±4.2 years. Measurements (pre and post Botox) were obtained with 20, 30 and 40 mL balloon volume. Diameter (6.5, 6.6), (7.8, 9.4) and (10.1, 11.2), compliance (92.3, 147.9), (89.7, 142.9) and (77, 85.4) mm³/mmHg, distensibility (2.6, 3.8), (2.7, 4.4) and (2.1, 3) mm²/mmHg and balloon pressure was (13.6, 9.6), (20.9, 16.2) and (42.3, 35) mmHg. Eleven children reported clinical symptom improvement after Botulinum Toxin injection. Balloon pressure was positively correlated to diameter ($r=0.63$, $P<0.001$).

Conclusions: Children with neurodisabilities who present with symptoms suggestive of poor gastric emptying do have a low pyloric distensibility and poor compliance. EndoFLIP via existing gastrostomy tract is quick and easy to perform. Intrapyloric Botulinum Toxin appears to be safe and effective in this cohort of children leading to clinical and measurements improvement.

Keywords: Botulinum toxin; children; endolumenal functional lumen imaging probe (EndoFLIP); gastrostomy; pyloric sphincter; pylorus

Received: 29 June 2022; Accepted: 17 January 2023; Published online: 14 February 2023.

doi: 10.21037/tgh-22-58

View this article at: <https://dx.doi.org/10.21037/tgh-22-58>

Introduction

Children with neurological disabilities often have multiple associated gastrointestinal (GI) problems which can affect their nutritional status and quality of life. Ninety two per

cent of children with cerebral palsy have clinically significant GI complications (1). Due to the inherent difficulties with communication, gastrointestinal symptomatology in these children can manifest as early satiety, recurrent vomiting,

[^] ORCID: 0000-0001-8869-9466.

retching, distress with feeds and prolonged feeding times (2). The sequelae of these problems does not only compromise nutritional status, but can also cause significant distress to the affected children and their carers (3). Similar symptoms are often reported in patients with delayed gastric emptying and gastroparesis (4).

The pylorus is known to play a salient role in drainage of gastric content into the duodenum and pyloric dysfunction can contribute to the pathophysiology of delayed gastric emptying (5). The incidence of pylorospasm was reported to be higher in diabetic gastroparesis patients compared to healthy volunteers and abnormal pylorus compliance was associated with severe clinical symptoms and altered quality of life (6-8). In the absence of a single effective strategy to manage symptoms secondary to delayed gastric emptying, the consensus is to try improve symptoms and to identify the group of patient who may benefit from targeted therapy (9). Botulinum Toxin is extensively used to treat spasticity in children with neurodisabilities and in a range of gastrointestinal conditions associated with abnormal sphincter tone (10-12). It is not recommended for the routine treatment of all patients with gastroparesis but is increasingly reported to be effective in patients with abnormal pyloric motility and compliance (7,13,14).

EndoFLIP® (endolumenal functional lumen imaging probe) uses impedance planimetry to characterise the

geometry of the measurement area and is able to measure luminal distensibility, compliance and cross sectional area (CSA) (15). It consists of 16 sensors inside a distensible balloon that can be filled to characterise sphincters diameter and CSA (15). It is often used to map lower oesophageal sphincter (LOS) distensibility in achalasia, to guide gastroesophageal reflux disease (GORD) surgery and to assess oesophageal compliance in eosinophilic oesophagitis (16-18). In achalasia, the LOS distensibility, rather than pressure appears to correlate well with oesophageal emptying and predict response to pneumatic dilatation (19,20). EndoFLIP is also increasingly used to assess the pyloric muscle to identify patients with low pyloric distensibility and poor compliance who will benefit from direct intervention to the pylorus (dilatation and/or intrapyloric Botulinum Toxin) (5,7,8).

We report our experience in using EndoFLIP via existing gastrostomy tracts to assess the pyloric muscles in children with neuromuscular disabilities and the response to targeted intrapyloric Botulinum Toxin injections. To the best of our knowledge, this is the first report in paediatric use of EndoFLIP to obtain pylorus measurement and to guide therapy. We present the following article in accordance with the STROBE reporting checklist (available at <https://tgh.amegroups.com/article/view/10.21037/tgh-22-58/rc>).

Methods

The study was registered in our hospital's clinical governance database as a review of clinical practice, in line with Declaration of Helsinki (as revised in 2013) and a full ethical review was not required (No. 10902).

Retrospective data collection of all children who had pylorus EndoFLIP assessment at Evelina London Children's Hospital in London, United Kingdom between March 2019 and January 2022.

All included children have neuromuscular disabilities (apart from one child), are fed via gastrostomy tubes and had significant foregut symptoms including retching, vomiting, inability to tolerate large bolus feeds and/or discomfort while feeding. None of the included children had anatomical or structural abnormalities to explain their symptoms, they had normal stomach, duodenum biopsies and their symptoms did not respond to optimum acid suppression therapy, prokinetic use or feed manipulation. Demographic data, underlying medical conditions, gastrointestinal complaints and response to treatment were collected from medical records.

Highlight box

Key findings

- EndoFLIP is easy to use and can predict clinical response to intra pyloric injection of Botulinum Toxin in children with symptoms of impaired gastric drainage.
- Over two third of the studied children showed clinical response to Botulinum Toxin.
- Botulinum Toxin can result in long term improvement in pylorus EndoFLIP measurements.

What is known and what is new?

- Gastrointestinal complaints are common in children with neuromuscular disabilities.
- EndoFLIP can be used to predict response to intra pyloric Botulinum Toxin injection in adults with gastroparesis.
- All EndoFLIP measurements in the study have improved after Botulinum Toxin injection.

What is the implication, and what should change now?

- EndoFLIP should be used as an added tool to assess children with suspected gastroparesis.
- EndoFLIP catheter can be inserted via existing gastrostomy tract.

The following symptoms were assessed at baseline and criteria used to assess improvement were included between brackets: vomiting and regurgitation (more than 50% reduction in episodes), retching (more than 50% reduction in episodes), feed intolerance (full volume feed tolerance), pain during feeding (more than 50% reduction in episodes) and suboptimum weight gain (objective documented weight gain).

Statistical analysis

Analysis was performed using IBM SPSS® Statistics Version 25. Variables were reported as mean and standard deviation, Student's *t*-test, ANOVA and Pearson's correlation were used for analysis of variables and $P < 0.05$ was regarded as statistically significant.

EndoFLIP measurement and technique description

EndoFLIP measurements were taken at the time of endoscopy under propofol anaesthesia. With the endoscope in the stomach, the balloon gastrostomy was removed and the EndoFLIP® catheter (EF-325N, 16 points over 80 mm measurement length along the balloon) (Medtronic®) was

inserted through the gastrostomy tract into the pylorus under direct vision prior to endoscopic intubation of the pylorus. The balloon was filled with 20, 30 and 40 mL to assess minimum diameter, distensibility (defined as the resistance of the luminal wall to a distending force), compliance (defined as the change in volume in response to the change in pressure) and balloon pressure. A minimum of three measurements were obtained after a settling down period of 5 seconds (to avoid pressure during peristalsis and variation in pylorus volume) for each balloon volume. The mean value of each parameter was used and all individual measurements were used for subsequent analysis. For distensibility, there is published normality cut off of 10 mm²/mmHg for adults (8).

After EndoFLIP assessment, intrapyloric Botulinum Toxin (6 iu/kg to the maximum of 200 iu) was injected under the same anaesthesia. We used a sclerotherapy needle inserted through the biopsy channel of the endoscope to inject the Toxin in divided doses around the pylorus.

Symptoms were assessed 6 weeks after Botulinum Toxin injection.

Results

Measurements were obtained from 12 children, 5 (42%) were females, mean age \pm standard deviation (SD) was 10.7 \pm 4.2 years. From each child, a minimum of three measurements were obtained with three sets of balloon volumes (20, 30 and 40 mL as detailed above). All children (apart from 1) had neuromuscular disabilities (9 had cerebral palsy, 1 had Nemaline myopathy, 1 with no unifying neuromuscular diagnosis and another had no unifying diagnosis but was neurologically able) (*Table 1*). EndoFLIP measurements showed the mean diameter, distensibility, compliance and pressure at balloon volumes of 20, 30 and 40 mL as summarised in *Table 2*. Diameter and pressure

Table 1 Demographic profile

Parameter	N=12
Females, n (%)	5 (42%)
Age (years), mean \pm SD	10.7 \pm 4.2
Background diagnosis	
Cerebral palsy	9
Nemaline myopathy	1
No unifying diagnosis	2

SD, standard deviation.

Table 2 EndoFLIP measurement before and after Botulinum Toxin

Parameter (mean \pm SD)	20 mL balloon volume			30 mL balloon volume			40 mL balloon volume		
	Before	After	P value	Before	After	P value	Before	After	P value
Diameter (mm)	6.5 \pm 1.3	6.6 \pm 1.3	0.013	7.8 \pm 2.3	9.4 \pm 1.8	0.05	10.1 \pm 2.7	11.2 \pm 2.4	0.03
Balloon pressure (mmHg)	13.6 \pm 4.4	9.6 \pm 2.5	0.046	20.9 \pm 8.1	16.2 \pm 4.4	0.1	42.3 \pm 13.1	35 \pm 16.3	0.2
Distensibility (mm ² /mmHg)	2.6 \pm 1.1	3.8 \pm 1.4	0.011	2.7 \pm 1.8	4.4 \pm 1.4	0.008	2.1 \pm 1	3.0 \pm 0.6	0.01
Compliance (mm ³ /mmHg)	92.3 \pm 38	147.9 \pm 37.1	0.030	89.7 \pm 43.5	142.9 \pm 36.6	0.047	77 \pm 28.9	85.4 \pm 28.3	0.3

EndoFLIP, endolumenal functional lumen imaging probe; SD, standard deviation.

Table 3 Clinical symptom reported at baseline and 6 weeks after Botulinum injection for all children who received Botulinum Toxin injections

Symptoms	Pre Botulinum (% of children)	Post Botulinum (% of children improved)
Vomiting and regurgitation	100	83
Retching	83	80
Feed intolerance (did not tolerate feed volume)	100	78
Pain during feeding	100	78
Suboptimum weight gain	58	85
Improved wellbeing (subjective reports from parents)	–	83

measurements at 20 mL balloon volume were at the lower limit of normal but all other measurements were outside the normal range reported in healthy adult volunteers (21). All children received intrapyloric Botulinum Toxin and all but one child showed clinical symptom improvement as detailed in *Table 3*. Although all EndoFLIP measurements have improved after the Botox injection during the subsequent measurement in symptomatic children (6–9 months later), the diameter, distensibility and pressure values have remained outside the normative adult values (21) (*Table 2*). Nine children had reassessment of pylorus 6–9 months after Botulinum Toxin injection, their EndoFLIP measurements are included in *Table 2*. Seven children had poor weight gain in the months prior to the procedure, 6 children showed sustained weight gain after the Botulinum Toxin injection for a minimum of 6 months duration. One child was able to stop jejunal feeding and maintain full gastric feeding.

Individual EndoFLIP measurements were then categorised into three groups based on balloon volumes. There were significant changes in diameter and distensibility ($P < 0.05$) pre and post Botulinum Toxin injection with all balloon volumes (20, 30 and 40 mL), while the pre/post difference in pressure and compliance were only statistically significant with 20 mL balloon volume as detailed in *Table 2*. There was a significant improvement in diameter ($P < 0.001$) and distensibility ($P < 0.001$) measurements in the whole group after Botulinum Toxin injection (*Figure 1*) and significant improvement pressure measurements ($P = 0.002$) and increased in compliance ($P = 0.001$) in the whole cohort (*Figure 1*).

There was significant increase in balloon pressure with each incremental increase in balloon volume between 20, 30 and 40 mL ($P = 0.02$, < 0.001 and < 0.001 respectively) leading to significant differences in diameter with balloon volume of 20 to 30 mL and 20 to 40 mL ($P = 0.026$ and < 0.001 respectively), and a significant change from 30 to

40 mL ($P = 0.004$). Increasing balloon pressure appears to positively influence diameter ($r = 0.63$, $P < 0.001$) (*Figure 2*) an important factor to consider in paediatric patient as the high balloon pressure may lead to inadvertent increase in balloon diameter and subsequent pylorus dilatation. While as expected distensibility and compliance (as defined as the volume of the enclosed region between above and below the minimum diameter divided by balloon distended pressure) were strongly correlated ($r = 0.79$, $P < 0.001$).

Discussion

Gastrointestinal complaints are common in children with neurodisabilities and can affect up to 90% of this population (1). Regurgitation, vomiting, GORD and impaired stomach emptying can lead to feeding difficulties and malnutrition (22). In this cohort, all included children had refractory foregut symptoms including vomiting and regurgitation, retching, feed intolerance affecting their ability to maintain sufficient nutrition, pain during feeding and suboptimum weight gain, not responding to optimum medical therapy. All children appeared to have abnormal pyloric EndoFLIP measurements and had shown a clinical improvement after Botulinum Toxin injection. Although there was some improvement in EndoFLIP values in subsequent measurements, the procedures were done 6–9 months after the injection in children who have had recurrence of symptoms. Children who had a repeat Botulinum Toxin injection also showed a similar clinical improvement to the first dose.

The European Society of Paediatric Gastroenterology, Hepatology and Nutrition (ESPGHAN) recommends jejunal feeding in children intolerant to gastric feeding, in paediatric gastroparesis and GORD, as well as in the neurologically disabled (23). However, jejunal tube feeding can lead to increasing morbidity and may negatively affect

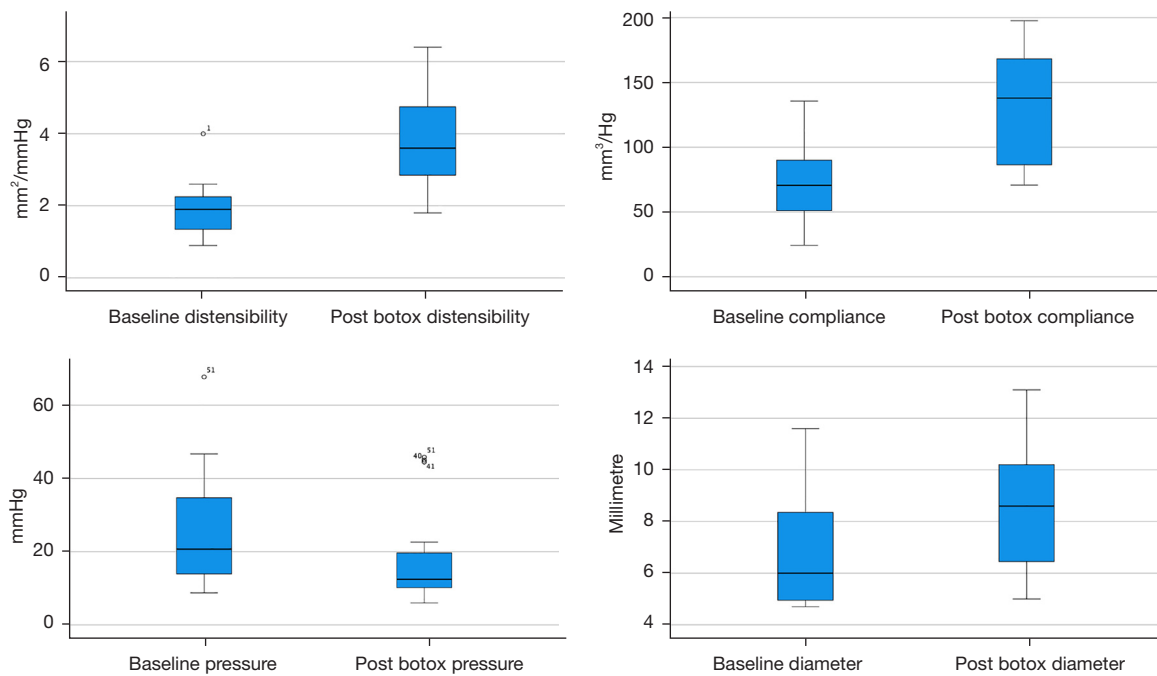


Figure 1 EndoFLIP measurement. EndoFLIP, endolumenal functional lumen imaging probe.

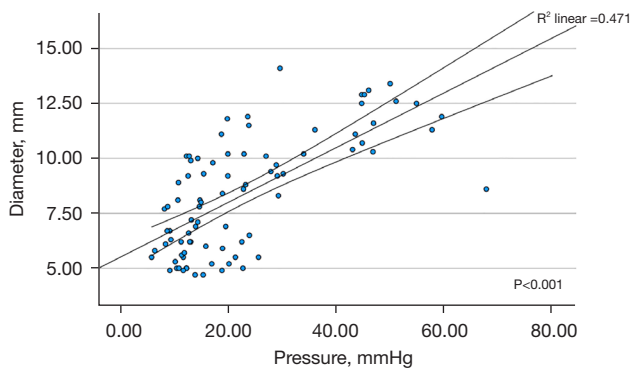


Figure 2 Intra balloon pressure and pylorus diameter correlation.

quality of life (24). Transpyloric jejunal tubes require frequent replacement under a specialist care setting often under general anaesthesia. They are unpredictable and can malfunction without warning leading to unplanned hospital admissions (25,26). Feeding into the jejunum is delivered as a continuous infusion to prevent intermittent dilatation of the small bowel, this can disrupt sleep patterns if administered overnight or disturb activities and routines during daytime administration. Abnormal pyloric distensibility measured by EndoFLIP was previously reported in adults with gastroparesis and was associated

with delayed gastric emptying (5). Intrapyloric Botulinum Toxin improved symptoms of poor gastric emptying in patients with abnormal pyloric distensibility (7). In children with feed intolerance and refractory foregut symptoms, assessment of pylorus by EndoFLIP may provide a useful tool to maintain gastric feeding and prevent progression to jejunal feeding. One child in our cohort was able to wean jejunal feeding and tolerated full feeds into stomach.

In this study, all included children had impaired pyloric distensibility which was consistent with three different balloon volume (20, 30 and 40 mL). Pyloric distensibility improved after Botulinum Toxin injection (*Figure 1*). Although there are no reported paediatric values, these readings are far below the accepted adult cut off value of 10 mm²/mmHg (6,8), age or the size of the child did not appear to affect distensibility measurements. All children received intrapyloric Botulinum Toxin 6 iu/kg up to a maximum of 200 iu in divided doses, all (apart from one child) showed clinical symptom improvement after 6 weeks and sustained weight gain.

The incremental increase in balloon volume led to significant increase in balloon pressure which showed strong positive correlation with the diameter of the pylorus. This raises an important question about the optimum balloon volume in children. Although the EndoFLIP

balloon is complained and does not cause hollow organ dilatation, it appears to cause unplanned dilatation of the pylorus with increasing intra balloon pressure, with no effect on distensibility or compliance. We did not observe any adverse effect from this and the intra balloon pressure remained well below the default safety pressure (60 mmHg), it is an area where further research is warranted and clinicians will need to be aware of the association between pressure and diameter as it may have clinical implications in small children. Although this is a small sample size, inflating the balloon volume to 40 mL did not produce added measurement value but did produce undue pyloric stretch.

Conclusions

In conclusion, we report our experience in the assessment of pyloric distensibility, compliance and diameter in children with neurodisabilities by EndoFLIP via existing gastrostomy tract. This can be easily performed under the same general anaesthetic as endoscopy, does not add much time to the total procedure duration (added an average of extra 10 minutes to the endoscopy time) and can guide the administration of intrapyloric Botulinum Toxin. The injections are an effective therapy to improve foregut symptoms in a subset of children, showing good clinical response and a trend of improvement in EndoFLIP measurements. Paediatricians can use EndoFLIP to select the cohort of children who may respond to intra pyloric Botulinum Toxin injection, this can potentially allow continuation of gastric feeding, avoidance of jejunal feeding and overall improvement in foregut symptoms, although more data from larger studies will be required to study the pathophysiology of pylorus muscle in children.

This study has a number of limitations. It is a retrospective design in a small number of children but to the best of our knowledge this is the first report in paediatric pylorus assessment by using EndoFLIP documented measurement parameters and guiding clinical management. We did not use breath test or scintigraphy to assess gastric emptying as our study's population of children with neurodisabilities are unlikely to comply with such tests.

Acknowledgments

We would like to acknowledge the contribution of Ms. Emily Kelly for her help in language editing in the early stages of manuscript preparation.

Funding: None.

Footnote

Reporting Checklist: The authors have completed the STROBE reporting checklist. Available at <https://tgh.amegroups.com/article/view/10.21037/tgh-22-58/rc>

Data Sharing Statement: Available at <https://tgh.amegroups.com/article/view/10.21037/tgh-22-58/dss>

Peer Review File: Available at <https://tgh.amegroups.com/article/view/10.21037/tgh-22-58/prf>

Conflicts of Interest: All authors have completed the ICMJE uniform disclosure form (available at <https://tgh.amegroups.com/article/view/10.21037/tgh-22-58/coif>). The authors have no conflicts of interest to declare.

Ethical Statement: The authors are accountable for all aspects of the work in ensuring that questions related to the accuracy or integrity of any part of the work are appropriately investigated and resolved. The study was registered in our hospital's clinical governance database as a review of clinical practice, in line with Declaration of Helsinki (as revised in 2013) and a full ethical review was not required (No. 10902).

Open Access Statement: This is an Open Access article distributed in accordance with the Creative Commons Attribution-NonCommercial-NoDerivs 4.0 International License (CC BY-NC-ND 4.0), which permits the non-commercial replication and distribution of the article with the strict proviso that no changes or edits are made and the original work is properly cited (including links to both the formal publication through the relevant DOI and the license). See: <https://creativecommons.org/licenses/by-nc-nd/4.0/>.

References

1. Del Giudice E, Staiano A, Capano G, et al. Gastrointestinal manifestations in children with cerebral palsy. *Brain Dev* 1999;21:307-11.
2. Quitadamo P, Thapar N, Staiano A, et al. Gastrointestinal and nutritional problems in neurologically impaired children. *Eur J Paediatr Neurol* 2016;20:810-5.
3. Sullivan PB, Juszczak E, Bachlet AM, et al. Impact of gastrostomy tube feeding on the quality of life of carers of children with cerebral palsy. *Dev Med Child Neurol* 2004;46:796-800.

4. Parkman HP. Idiopathic gastroparesis. *Gastroenterol Clin North Am* 2015;44:59-68.
5. Gourcerol G, Tissier F, Melchior C, et al. Impaired fasting pyloric compliance in gastroparesis and the therapeutic response to pyloric dilatation. *Aliment Pharmacol Ther* 2015;41:360-7.
6. Saadi M, Yu D, Malik Z, et al. Pyloric sphincter characteristics using EndoFLIP® in gastroparesis. Características del esfínter pilórico utilizando EndoFLIP® en gastroparesia. *Rev Gastroenterol Mex (Engl Ed)* 2018;83:375-84.
7. Desprez C, Melchior C, Wuestenberghs F, et al. Pyloric distensibility measurement predicts symptomatic response to intrapyloric botulinum toxin injection. *Gastrointest Endosc* 2019;90:754-760.e1.
8. Malik Z, Sankineni A, Parkman HP. Assessing pyloric sphincter pathophysiology using EndoFLIP in patients with gastroparesis. *Neurogastroenterol Motil* 2015;27:524-31.
9. Camilleri M, Chedid V, Ford AC, et al. Gastroparesis. *Nat Rev Dis Primers* 2018;4:41.
10. Multani I, Manji J, Hastings-Ison T, et al. Botulinum Toxin in the Management of Children with Cerebral Palsy. *Paediatr Drugs* 2019;21:261-81.
11. Vanuytsel T, Bisschops R, Farré R, et al. Botulinum toxin reduces Dysphagia in patients with nonachalasia primary esophageal motility disorders. *Clin Gastroenterol Hepatol* 2013;11:1115-1121.e2.
12. Lacy BE, Weiser K, Kennedy A. Botulinum toxin and gastrointestinal tract disorders: panacea, placebo, or pathway to the future? *Gastroenterol Hepatol (N Y)* 2008;4:283-95.
13. Camilleri M, Parkman HP, Shafi MA, et al. Clinical guideline: management of gastroparesis. *Am J Gastroenterol* 2013;108:18-37; quiz 38.
14. Thomas A, de Souza Ribeiro B, Malespin M, et al. Botulinum Toxin as a Treatment for Refractory Gastroparesis: a Literature Review. *Curr Treat Options Gastroenterol* 2018;16:479-88.
15. McMahon BP, Frøkjær JB, Liao D, et al. A new technique for evaluating sphincter function in visceral organs: application of the functional lumen imaging probe (FLIP) for the evaluation of the oesophago-gastric junction. *Physiol Meas* 2005;26:823-36.
16. Donnan EN, Pandolfino JE. Applying the Functional Luminal Imaging Probe to Esophageal Disorders. *Curr Gastroenterol Rep* 2020;22:10.
17. Su B, Callahan ZM, Novak S, et al. Using Impedance Planimetry (EndoFLIP) to Evaluate Myotomy and Predict Outcomes After Surgery for Achalasia. *J Gastrointest Surg* 2020;24:964-71.
18. Su B, Callahan ZM, Kuchta K, et al. Use of Impedance Planimetry (Endoflip) in Foregut Surgery Practice: Experience of More than 400 Cases. *J Am Coll Surg* 2020;231:160-71.
19. Rohof WO, Hirsch DP, Kessing BF, et al. Efficacy of treatment for patients with achalasia depends on the distensibility of the esophagogastric junction. *Gastroenterology* 2012;143:328-35.
20. Benitez AJ, Budhu S, Burger C, et al. Use of the functional luminal imaging probe in pediatrics: A comparison study of patients with achalasia before and after endoscopic dilation and non-achalasia controls. *Neurogastroenterol Motil* 2021;33:e14133.
21. Jagtap N, Kalapala R, Reddy DN. Assessment of Pyloric Sphincter Physiology Using Functional Luminal Imaging Probe in Healthy Volunteers. *J Neurogastroenterol Motil* 2020;26:391-6.
22. Kuperminc MN, Stevenson RD. Growth and nutrition disorders in children with cerebral palsy. *Dev Disabil Res Rev* 2008;14:137-46.
23. Broekaert IJ, Falconer J, Bronsky J, et al. The Use of Jejunal Tube Feeding in Children: A Position Paper by the Gastroenterology and Nutrition Committees of the European Society for Paediatric Gastroenterology, Hepatology, and Nutrition 2019. *J Pediatr Gastroenterol Nutr* 2019;69:239-58.
24. Fortunato JE, Darbari A, Mitchell SE, et al. The limitations of gastro-jejunal (G-J) feeding tubes in children: a 9-year pediatric hospital database analysis. *Am J Gastroenterol* 2005;100:186-9.
25. Blumenstein I, Shastri YM, Stein J. Gastroenteric tube feeding: techniques, problems and solutions. *World J Gastroenterol* 2014;20:8505-24.
26. Al-Zubeidi D, Demir H, Bishop WP, et al. Gastrojejunal feeding tube use by gastroenterologists in a pediatric academic center. *J Pediatr Gastroenterol Nutr* 2013;56:523-7.

doi: 10.21037/tgh-22-58

Cite this article as: Popescu M, White E, Mutalib M. EndoFLIP assessment of pyloric sphincter in children: a single-center experience. *Transl Gastroenterol Hepatol* 2023;8:17.