

Scientific Article

# Brachial plexopathy after stereotactic body radiation therapy for apical lung cancer: Dosimetric analysis and preliminary clinical outcomes

Sumit S. Sood MD, Christopher McClinton MD, Rajeev Badkul MS, Nathan Aguilera MS, CMD, Fen Wang MD, PhD, Allen M. Chen MD \*

Department of Radiation Oncology, The University of Kansas School of Medicine, Kansas City, Kansas

Received 25 June 2017; received in revised form 17 August 2017; accepted 3 October 2017

## Abstract

**Purpose:** The treatment of apical lung tumors with stereotactic body radiation therapy (SBRT) is challenging due to the proximity of the brachial plexus and the concern for nerve damage.

**Methods and materials:** Between June 2009 and February 2017, a total of 75 consecutive patients underwent SBRT for T1-T3N0 non-small cell lung cancer involving the upper lobe of the lung. All patients were treated with 4-dimensional computed tomography (CT)-based image guided SBRT to a dose of 40 to 60 Gy in 3 to 5 fractions. For dosimetric analysis, only apical tumors as defined by the location of the tumor epicenter superior to the aortic arch were included. The anatomical brachial plexus was delineated using the Radiation Therapy Oncology Group atlas.

**Results:** Thirty-one patients with 31 apical lung tumors satisfied the anatomical criteria for inclusion. The median age was 73 years (range, 58-89). The median planning target volume was 26.5 cc (range, 8.2-81.4 cc). The median brachial plexus, brachial plexus maximum dose (Dmax), Dmax per fraction, V22 (cc, 3-4 fractions), V30 (cc, 5 fractions), and biologically effective dose 3 Gy were 15.8 Gy (range, 1.7-66.5 Gy), 3.4 Gy (range, 0.6-14.7 Gy), 0.0 cc (range, 0-0.9 cc), 0.06 cc (range, 0-2.5 cc), and 31.5 Gy (range, 3.3-133.1 Gy), respectively. At a median follow-up of 17 months, the observed incidence of brachial plexopathy was 0%.

**Conclusions:** There is significant variation in dose to the brachial plexus for patients treated with SBRT for apical lung tumors. Although the incidence of neuropathic symptoms in this series was zero, further attention should be focused on the clinical implications of these findings.

© 2017 The Author(s). Published by Elsevier Inc. on behalf of the American Society for Radiation Oncology. This is an open access article under the CC BY-NC-ND license (<http://creativecommons.org/licenses/by-nc-nd/4.0/>).

Conflicts of interest: The authors indicate that they have no potential conflicts of interest.

\* Corresponding author. Department of Radiation Oncology, University of Kansas School of Medicine, 3901 Rainbow Blvd, MS 4033, Kansas City, KS 66160

E-mail address: [achen5@kumc.edu](mailto:achen5@kumc.edu) (A.M. Chen).

## Introduction

Stereotactic body radiation therapy (SBRT) represents an effective treatment modality for early stage non-small cell lung cancer (NSCLC), and published series suggest that

<https://doi.org/10.1016/j.adro.2017.10.002>

2452-1094/© 2017 The Author(s). Published by Elsevier Inc. on behalf of the American Society for Radiation Oncology. This is an open access article under the CC BY-NC-ND license (<http://creativecommons.org/licenses/by-nc-nd/4.0/>).

SBRT may provide similar efficacy to surgery.<sup>1,2</sup> In comparison with conventional techniques, SBRT uses highly conformal dose distributions with ablative fraction sizes that allow for reduction of the normal tissue irradiated, intensification of the biological dose to target tissue, and a decrease in overall treatment time. Despite the low toxicity rates generally observed with SBRT, the use of these hypofractionated regimens carry a theoretical risk of normal tissue complication, particularly with respect to neural structures, where structural subunits are serially arranged and exhibit lower alpha-beta ratios, which makes them more sensitive to higher doses per fraction.<sup>3</sup>

The treatment of apical lung tumors with SBRT is especially challenging due to the proximity of the brachial plexus and the associated concern for treatment-related nerve damage. Although dose-volume tolerances of the brachial plexus have been reported for conventionally fractionated regimens for head and neck cancer, data in the setting of lung SBRT are limited.<sup>4-8</sup> We hypothesize that despite the possibility of injury to the brachial plexus, the actual dose delivered to this critical structure is often overlooked, especially in scenarios in which target coverage to apical tumors may otherwise be compromised. The purpose of this analysis was to review of our institution's experience with the SBRT treatment of apical lung cancers with particular focus on correlating brachial plexus dosimetric details with preliminary clinical outcomes.

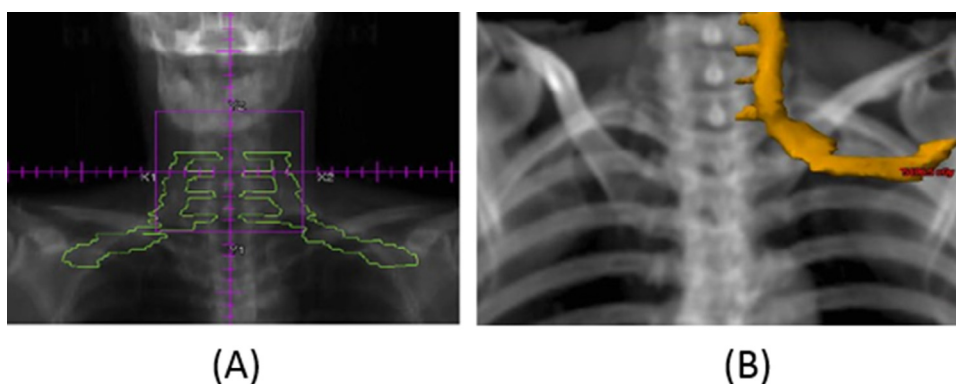
## Methods and materials

The medical records of 75 consecutive patients treated with SBRT for primary NSCLC involving the upper lobe of the lung at a tertiary-care academic medical center between June 2009 and February 2017 were reviewed. All patients underwent computed tomography (CT)-based simulation with intravenous contrast using a stereotactic body fixation device with abdominal compression to limit respiratory excursion. Four-dimensional CT was obtained, and

an internal target volume (ITV) was delineated by identifying the gross tumor on maximum intensity projection image data sets considering 8 phases of the respiratory cycle. No additional margin was added for possible microscopic tumor extension. An additional margin of 5 mm circumferentially was added to the ITV to account for setup errors and to generate a planning target volume (PTV).

All tumors were treated to a dose of 40 to 60 Gy in 3 to 5 fractions with the application of heterogeneity correction. Fractions were separated by at least 40 hours, and the entire 3 to 5 fraction regimen was required to be completed within 14 days. SBRT treatment plans were generated with a combination of noncoplanar 3-dimensional conformal arcs or beams and were delivered by Novalis-TX (Brainlab AG, Munich, Germany), consisting of high-definition multileaf collimators and a 6MV-SRS (1000MU/min) beam. Treatment plans were optimized to achieve a PTV receiving 100% of the prescription dose (PTV100) of 95% or higher. Cone beam CT was used with each fraction to confirm the position of the target. Intensity modulated radiation therapy was not routinely used unless normal tissue dose constraints were exceeded with conformal beams. A Monte Carlo treatment planning algorithm was used.

Adequate target coverage was achieved when 95% of the PTV was covered by the prescription dose. High- and intermediate-dose spillages were measured by calculating the conformality index (ratio of the volume receiving 60 Gy to the PTV:  $\leq 1.2$ ) and the ratio of 50% prescription isodose volume to the PTV (R50) and by measuring the maximum dose 2 cm from the PTV in any direction (D2cm). Normal tissue structures contoured included the spinal cord, esophagus, chest wall, heart, and normal lungs. The brachial plexus organ at risk (OAR) was also delineated in accordance with the Radiation Therapy Oncology Group (RTOG) guidelines as proposed by Hall et al, although no attempt was made to limit the dose to this structure during SBRT planning.<sup>9</sup> Figure 1 illustrates a representative coronal slice of the brachial plexus depicted using the RTOG contouring atlas versus a coronal slice that was obtained from a



**Figure 1** Coronal slice of brachial plexus depicted using the Radiation Therapy Oncology Group contouring atlas (A) compared with a coronal slice that was obtained from a digital reconstructed radiograph of a patient who was treated with stereotactic body radiation therapy in this review. The orange structure outlines the contoured ipsilateral brachial plexus (B).

**Table 1** Patient and disease characteristics

Characteristic	n (%)
Sex	
Male	16 (52)
Female	15 (48)
Age (y)	
Median	72.6
Range	58-89
Histology	
Adenocarcinoma	18 (58)
Squamous	9 (29)
Other	4 (13)
Tumor Classification	
T1a	23 (74)
T1b	4 (13)
T2a	3 (10)
T3	1 (3)
Planning Target Volume (cc)	
Median	26.5
Range	8.2-81.4
Laterality	
Right	15 (48)
Left	16 (52)

digital reconstructed radiograph of a patient treated with SBRT in this review.

For the purposes of this analysis, only apical tumors (n = 31), defined anatomically by localizing the tumor epicenter superior to the aortic arch, were included for dosimetric evaluation. Dosimetry was subsequently reported using the following descriptive statistics: brachial plexus maximum dose (Dmax), Dmax per fraction, volume receiving 22 Gy or higher (V22, in cc, for 3-4 fractions), V30 (cc, for 5 fractions), and biologically effective dose (BED, using an alpha/beta ratio of 3) for the entire patient cohort.

The dose-volume parameters chosen for analysis were selected because they represent dose constraints on current SBRT protocols. A subset of 18 patients who were deemed to be at a higher risk due to tumor proximity (within 2 cm) to the brachial plexus were reanalyzed for the dosimetric parameters listed. Patient medical records were retrospectively reviewed to determine the incidence of brachial plexus-related symptoms, defined as the development of ipsilateral upper extremity pain, motor weakness, and/or sensory abnormalities.

## Results

**Table 1** outlines the characteristics of the patient population. Thirty-one patients with apical lung tumors satisfied the anatomical criteria for inclusion and comprised the primary study population. None had received previous treatment. All patients had histologically proven primary NSCLC,

of which the most common histology was adenocarcinoma (52%), followed by squamous cell carcinoma (29%). The T-classification was 23 (74%) T1a, 4 (13%) T1b, 3 (10%) T2a, and 1 (3%) T3. Median patient age was 73 years (range, 58-89 years) and median PTV was 27 cc (range, 8-81 cc). Anatomically, 15 (48%) and 16 (52%) tumors were right- and left-sided, respectively. **Table 2** details the characteristics of treatment. The most common prescription dose and fractionation scheme was 50 Gy in 5 fractions (n = 18). The delivered fraction size ranged from 8 to 20 Gy.

**Table 3** presents detailed dosimetric information for the brachial plexus OAR. The median brachial plexus Dmax, Dmax per fraction, V22 (cc, 3-4 fractions), V30 (cc, 5 fractions), and BED3 were 15.8 Gy (range, 1.7-66.5 Gy), 3.4 Gy (range, 0.6-14.7 Gy), 0.0 cc (range, 0-0.9 cc), 0.06 cc (range, 0-2.5 cc), and 31.5 Gy (range, 3.3-133.1 Gy), respectively. For a subset of 18 patients who were deemed to be at higher risk due to tumor proximity to the brachial plexus, the median Dmax was 30.1 Gy (range, 10-66.6 Gy), Dmax per fraction was 6.6 Gy (range, 2-14.7 Gy), and BED3 was 60.1 Gy (range, 20.0-133.1 Gy). Within this subpopulation, 10 (55%), 7 (39%), and 4 (22%) patients experienced brachial plexus maximum doses per fraction greater than 6, 8, and 10 Gy, respectively. **Figure 2** depicts a graphical representation of the substantial dosimetric variation in Dmax per fraction received by the brachial plexus in the entire cohort and the large proportion of high doses per fraction actually delivered to the higher-risk subpopulation.

At a median follow-up of 17 months (range, 5-66 months), clinical evaluation of the high-risk population (n = 18) revealed the observed incidence of brachial plexopathy to be 0%. Associated local tumor control was observed in 17 of 18 patients (94%). **Figure 3** provides a representative example of a dose distribution color wash in relationship to ipsilateral brachial plexus in a patient with a left apical T2aN0 NSCLC treated with 50 Gy in 5

**Table 2** Treatment characteristics

Characteristics	n (%)
No. of Treated Lesions	31
Dose Fractionation (Total Dose in Gy/fractions)	
50/5	18 (58)
54/3	6 (18)
60/5	2 (7)
60/3	2 (7)
40/5	2 (7)
48/4	1 (3)
Dose Per Fraction (Gy)	
Median Dose	10
Range	8-20
Biologically Effective Dose (10 in Gy)	
Median	100
Range	72-180

**Table 3** Dosimetric evaluation of the brachial plexus

	All apical tumors (n = 31)	Higher risk apical tumors in close proximity to brachial plexus (n = 18)
Maximum Brachial Plexus Dose (Gy)		
Median	15.8	30.1
Range	1.7-66.5	10-66.6
Maximum Brachial Plexus Dose/Fraction (Gy)		
Median	3.4	6.6
Range	0.6-14.7	2-14.7
Biologically Effective Dose 3 Gy		
Median	31.5	60.1
Range	3.3-133.1	20.0-133.1
V22 (cc, 3 -4 fractions)		
Median	0.0	0.2
Range	0-0.9	0-0.9
V30 (cc, 5 fractions)		
Median	0.06	0.66
Range	0-2.5	0-2.5

fractions and exhibits a brachial plexus Dmax of 54.1 Gy in this high-risk population of patients.

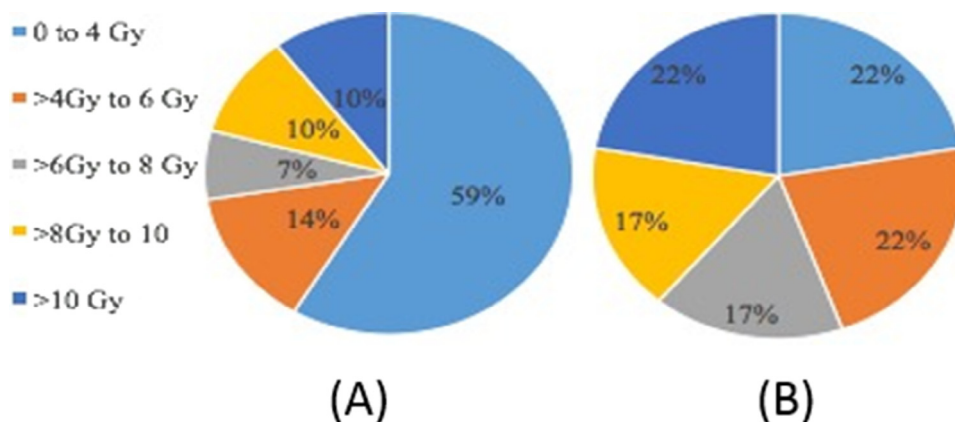
## Discussion

The results of the present analysis illustrate the significant variability in dose to the brachial plexus that exists for patients undergoing SBRT for apical lung tumors. As importantly, we showed that dose to this normal structure can dramatically exceed conventionally recommended limits, with the BED greater than 100 Gy in some cases. Given the high rates of cure generally observed with SBRT and the potential for prolonged survival, further attention should be focused on the clinical implications of such findings. Although the low incidence of clinically reported bra-

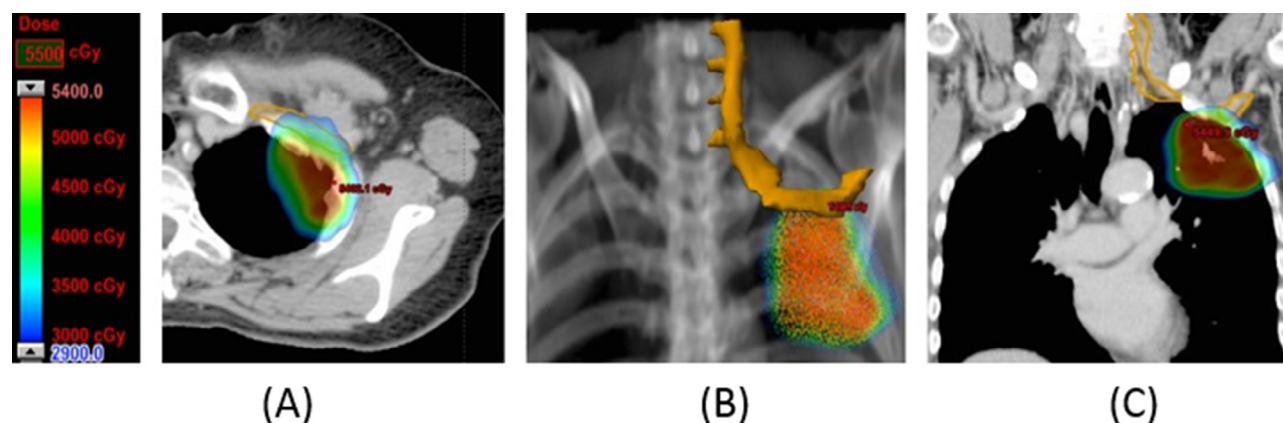
chial plexus-related symptoms reported herein should provide some reassurance that treatment can be performed safely, longer follow-up is imperative.

Dose constraint recommendations for anatomical OARs, including the brachial plexus, were historically based on reports by Emami et al, who estimated the probability of complication depending on the dose and partial volumes of tissue irradiated.<sup>10</sup> Although these guidelines assumed the use of conventional fractionation (1.8-2 Gy per fraction), the tolerance dose limits that are recommended for irradiation of one-third, two-thirds, and the entirety of the brachial plexus were 62, 61, and 60 Gy, respectively.

However, more recently published data suggest that these dose-volume limits are likely overly conservative.<sup>4,6</sup> For instance, prospective data from Chen et al identified the brachial plexus volume receiving 70 and 74 Gy or greater



**Figure 2** Graphical representation demonstrating the large dosimetric variation in brachial plexus maximum dose per fraction in (A) all apical tumors (n = 31, left pie chart) and (B) the high-risk subpopulation with tumors in close proximity to the brachial plexus (n = 18). The higher-risk cohort pie chart further demonstrates that actual doses delivered to the brachial plexus often far exceed current protocol guidelines.



**Figure 3** Depiction of dose distribution color wash in relationship to ipsilateral brachial plexus in a patient with a left apical T2aN0 non-small cell lung cancer treated with 50 Gy in 5 fractions exhibiting a brachial plexus maximum dose of 54.1 Gy. Sequential images from left to right characterize (A) a representative axial slice, (B) coronal digital reconstructed radiograph, and (C) corresponding coronal slice with the isodose color wash and brachial plexus contoured in orange.

as most predictive of neuropathic injuries for patients treated for head and neck cancer, with the probability increasing with the dose.<sup>4</sup> Similarly, Eblan et al demonstrated that the risk of brachial plexus–associated neuropathy increased significantly when the volume received greater than 74 and 76 Gy, which again suggests that the tolerance of this structure to high-dose radiation is greater than once believed.<sup>11</sup>

Theoretically, OARs that are arranged as serial structures, such as the spinal cord and brachial plexus, are the most sensitive to higher doses per fraction, and preclinical data show that the lower alpha-beta ratio of these neural tissues influences repair. Indeed, data from patients with breast cancer have clearly delineated the effect that increasing fraction sizes has on the incidence of injury.<sup>12-14</sup> Johannsson et al showed that the use of large daily fractions (3 or 4 Gy) to doses of 44 to 54 Gy was associated with brachial plexopathy among patients treated for breast cancer.<sup>12</sup>

In the largest published series, Powell et al identified a significant difference among patients irradiated using 3 Gy per fraction compared with 1.8 Gy among 449 patients who were treated with postoperative radiation therapy for breast cancer, with the total incidence being approximately 5% at 5.5 years.<sup>13</sup> The investigators did identify a significant difference among patients who were irradiated using 3 Gy per fraction compared with 1.8 Gy. Given these previous reports, concern logically exists that the ablative hypofractionated doses used with SBRT may carry a relatively higher risk of normal-tissue complication.

The literature on brachial plexus injury after SBRT is conflicting. Forquer et al analyzed the outcomes of 37 patients with apical lung tumors that were treated with SBRT.<sup>7</sup> In their report, 7 of 37 patients developed brachial plexopathy after SBRT, and maximum total dose to the brachial plexus of >26 Gy predicted for significantly higher risk of complication at 2 years. Chang et al similarly evalu-

ated outcomes for centrally located tumors treated with SBRT to 50 Gy in 4 fractions and reported a higher incidence of brachial plexopathy when the maximum total dose exceeded 35 Gy.<sup>8</sup>

Additional insight may be derived from the irradiation of melanoma with hypofractionated regimens. In the largest series to date, Ballo et al reported on 89 patients with melanoma who were treated with hypofractionated radiation (6 Gy  $\times$  5 fractions) to the axilla and supraclavicular nodal basins and did not document any cases of brachial plexopathy with subsequent follow-up.<sup>15</sup> Most recently, Stubblefield et al analyzed the incidence of peripheral nerve injury after single-fraction radiation to a dose of 24 Gy for 557 paraspinal tumors and documented the incidence of clinical and/or electrophysiological symptoms as 2.5%.<sup>16</sup> The median time to symptom onset after treatment was 10 months, and the most common symptoms were related to pain and/or weakness.

It is notable that current SBRT protocols recommend limiting the maximum dose per fraction to the brachial plexus between 6 and 8 Gy, depending on the number of fractions used for treatment.<sup>17,18</sup> In evaluation of our higher-risk population, almost 40% of patients exhibited maximum dose per fraction that exceeded 8 Gy. In addition, a closer review revealed 4 (22%) and 2 (11%) patients with brachial plexopathy plexus Dmax doses per fraction that were greater than 10 and 12 Gy, respectively. Although no clinical evidence of brachial plexus nerve damage in these patients was observed during follow-up, larger prospective data sets are needed to confirm our preliminary observations. Meanwhile, we recommend proceeding with caution and adhering to the common principle of delivering doses as low as reasonably achievable to critical OARs.<sup>19</sup> It also must be recognized that the BED delivered to the brachial plexus is diluted by the fact that fractions are generally delivered on nonconsecutive days during SBRT. How

and whether repair influences the low incidence of complications remains to be determined.

The major limitation of this analysis is related to its retrospective nature. Notably, the lack of a standardized assessment tool to screen for symptoms of brachial plexus injury may have underestimated its true incidence. Because brachial plexopathy is often considered a diagnosis of exclusion after ruling out phenomena such as recurrent tumor, secondary cancers, and benign etiologies, electrophysiological studies may have been helpful for confirmatory purposes.<sup>20</sup>

Although common symptoms include sensory and motor deficits, brachial plexus-associated neuropathies may also present in a variety of manners. However, brachial plexopathy is considered irreversible, and effective treatments are generally lacking. Given the substantial variation in dose delivered to the brachial plexus in our treatment plans, which were optimized to achieve a PTV100 of 95% or higher even at the expense of nearby critical structures with the exception of the spinal cord, additional studies to analyze clinical-dosimetric factors for toxicity among patients treated for lung cancer using SBRT are needed.

## References

1. Timmerman R, Paulus R, Galvin J, et al. Stereotactic body radiation therapy for inoperable early stage lung cancer. *JAMA*. 2010;303:1070-1076.
2. Chang JY, Senan S, Paul MA, et al. Stereotactic ablative radiotherapy versus lobectomy for operable stage I non-small-cell lung cancer: A pooled analysis of two randomised trials. *Lancet Oncol*. 2015;16:630-637.
3. Kirkpatrick JP, van der Kogel AJ, Schultheiss TE. Radiation dose-volume effects in the spinal cord. *Int J Radiat Oncol Biol Phys*. 2010;76:S42-S49.
4. Chen AM, Wang PC, Daly ME, et al. Dose-volume modeling of brachial plexus-associated neuropathy after radiation therapy for head-and-neck cancer: Findings from a prospective screening protocol. *Int J Radiat Oncol Biol Phys*. 2014;88:771-777.
5. Chen AM, Hall WH, Li J, et al. Brachial plexus-associated neuropathy after high-dose radiation therapy for head-and-neck cancer. *Int J Radiat Oncol Biol Phys*. 2012;84:165-169.
6. Amini A, Yang J, Williamson R, et al. Dose constraints to prevent radiation-induced brachial plexopathy in patients treated for lung cancer. *Int J Radiat Oncol Biol Phys*. 2012;82:e391-e398.
7. Forquer JA, Fakiris AJ, Timmerman RD, et al. Brachial plexopathy from stereotactic body radiotherapy in early-stage NSCLC: Dose-limiting toxicity in apical tumor sites. *Radiother Oncol*. 2009;93:408-413.
8. Chang JY, Li QQ, Xu QY, et al. Stereotactic ablative radiation therapy for centrally located early stage or isolated parenchymal recurrences of non-small cell lung cancer: How to fly in a "no fly zone". *Int J Radiat Oncol Biol Phys*. 2014;88:1120-11128.
9. Hall WH, Guiou M, Lee NY, et al. Development and validation of a standardized method for contouring the brachial plexus: Preliminary dosimetric analysis among patients treated with IMRT for head-and-neck cancer. *Int J Radiat Oncol Biol Phys*. 2008;72:1362-1367.
10. Emami B, Lyman J, Brown A, et al. Tolerance of normal tissue to therapeutic irradiation. *Int J Radiat Oncol Biol Phys*. 1991;21:109-122.
11. Eblan MJ, Corradetti MN, Lukens JN, et al. Brachial plexopathy in apical non-small cell lung cancer treated with definitive radiation: Dosimetric analysis and clinical implications. *Int J Radiat Oncol Biol Phys*. 2013;85:175-181.
12. Johansson S, Svensson H, Denekamp J. Timescale of evolution of late radiation injury after postoperative radiotherapy of breast cancer patients. *Int J Radiat Oncol Biol Phys*. 2000;48:745-750.
13. Powell S, Cooke J, Parsons C. Radiation-induced brachial plexus injury: Follow-up of two different fractionation schedules. *Radiother Oncol*. 1990;18:213-220.
14. Boyaciyan A, Oge AE, Yazici J, Aslay I, Baslo A. Electrophysiological findings in patients who received radiation therapy over the brachial plexus: A magnetic stimulation study. *Electroenceph Clin Neurophysiol*. 1996;101:483-490.
15. Ballo MT, Strom EA, Zagars GK, et al. Adjuvant irradiation for axillary metastases from malignant melanoma. *Int J Radiat Oncol Biol Phys*. 2002;524:964-972.
16. Stubblefield MD, Ibanez K, Riedel ER, et al. Peripheral nervous system injury after high-dose single-fraction image-guided stereotactic radiosurgery for spine tumors. *Neurosurg Focus*. 2017;42:E12.
17. Radiation Therapy Oncology Group. RTOG 0813: A seamless phase I/II study of stereotactic lung radiotherapy (SBRT) for early stage, centrally located, non-small cell lung cancer (NSCLC) in medically inoperable patients. 2012. Available at: <http://www.rtog.org>. Accessed March 12, 2017.
18. Radiation Therapy Oncology Group. NRG-BR001: A phase 1 study of stereotactic body radiotherapy (SBRT) for the treatment of multiple metastases. 2017. Available at: <http://www.rtog.org>. Accessed March 12, 2017.
19. National Council on Radiation Protection and Measurements. Report 107: Implementation of the principle of as low as reasonably achievable (ALARA) for medical and dental personal. Bethesda, MD: NCRP; 1990.
20. Ko K, Sung DH, Kang MJ, et al. Clinical, electrophysiological findings in adult patients with non-traumatic plexopathies. *Ann Rehabil Med*. 2011;37:807-815.