

# Conjunctivitis as the important indicator of pediatric granulomatosis with polyangiitis

SAGE Open Medical Case Reports  
Volume 10: 1–3  
© The Author(s) 2022  
Article reuse guidelines:  
sagepub.com/journals-permissions  
DOI: 10.1177/2050313X221114727  
journals.sagepub.com/home/sco



Mohsen Jari<sup>1</sup> , Zahra Rastinmaram<sup>2</sup>, Elahe Niazi<sup>2</sup>  
and Zahra Mousavi<sup>2</sup>

## Abstract

Granulomatosis with polyangiitis disease is a rare vasculitis characterized by granulomatous inflammation of respiratory tracts and glomerulonephritis along with vasculitis of other organs. In this study, a 14-year-old boy was referred from ophthalmology clinic to the pediatric rheumatology ward due to drug-resistant conjunctivitis. He had a history of chronic rhinorrhea and nighttime coughing, and he was diagnosed with allergic rhinitis. Complete blood count showed leukocytosis and thrombocytosis, and the estimated sedimentation rate was elevated. Laboratory tests showed hematuria, proteinuria, and highly positive antineutrophil cytoplasmic antibody. Moreover, sinus computed tomography demonstrated pansinusitis, and spiral chest computed tomography showed multiple pulmonary nodules in both his lungs. Finally, based on renal biopsy, the patient was confirmed as a case of granulomatosis with polyangiitis. It is notable that acute or chronic conjunctivitis may be a manifestation of rheumatic diseases.

## Keywords

Granulomatosis with polyangiitis, children, pediatrics, conjunctivitis

Date received: 17 February 2022; accepted: 4 July 2022

## Introduction

Granulomatosis with polyangiitis (GPA) disease, known as Wegner granulomatous, is a rare multisystem autoimmune disease with unknown etiology, which is characterized by granulomatous inflammation, tissue necrosis, and vasculitis in small and medium-sized vessels.<sup>1</sup> The main clinical characteristics of this disease include the upper and/or lower respiratory tract and kidneys. Ear, nose, and throat manifestations with recurrent sinusitis and crusting rhinorrhea are usually severe as well.<sup>2</sup> In this regard, diagnosis of GPA is performed based on the clinical assessment, serological tests for antineutrophil cytoplasmic antibody (ANCA), and histological analysis.<sup>3</sup>

One of the organs that may be involved in this disease is eye with various manifestations. In fact, conjunctivitis is considered as a very rare manifestation that appeared at the first stage in GPA.<sup>4–7</sup> In this study, the unusual case in whom bilateral conjunctivitis was the important indicator of GPA in adolescence is reported.

## Case presentation

A 14-year-old boy was referred from ophthalmology clinic to the pediatric rheumatology ward of Imam Hossein Children's

Hospital, Isfahan University of Medical Sciences only due to drug-resistant conjunctivitis. On ophthalmic examination, anterior and posterior chambers and funduscopy of his both eyes were found to be completely normal. Moreover, visual acuity was 9/10 bilaterally. Of note, he was treated with prednisolone eye drop due to redness of both eyes, tearing, and photophobia for a 3-month period. As well, he was under intermittent therapy with montelukast, nasal steroid spray, and oral cetirizine for 2 years due to having constant rhinorrhea and nighttime coughing, so he was diagnosed with allergic rhinitis. Physical examination of the patient revealed bilateral nonpurulent conjunctivitis (Figure 1).

By outpatient testing, complete blood count (CBC) showed leukocytosis, thrombocytosis, and anemia, and erythrocyte sedimentation rate (ESR) was obtained as

<sup>1</sup>Department of Pediatric Rheumatology, Imam Hossein Children's Hospital, Isfahan University of Medical Sciences, Isfahan, Iran

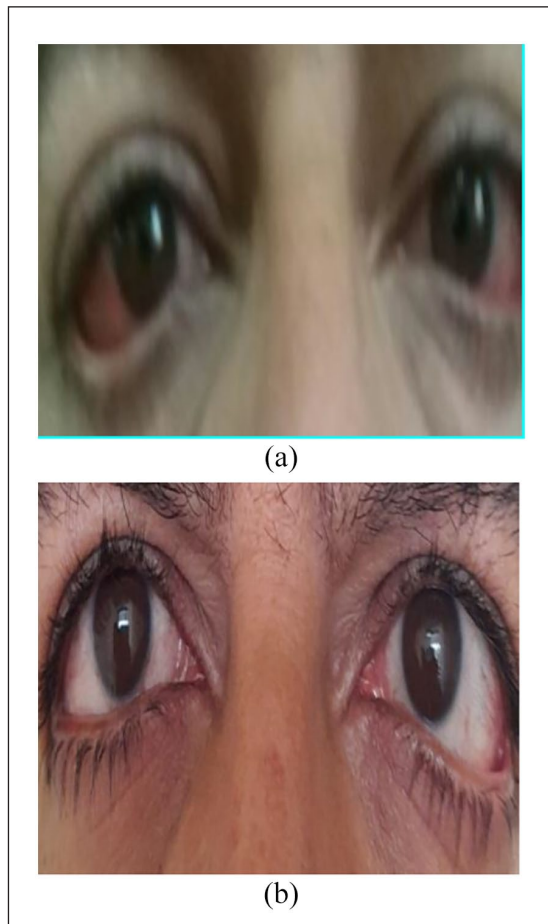
<sup>2</sup>Isfahan University of Medical Sciences, Isfahan, Iran

### Corresponding Author:

Mohsen Jari, Department of Pediatric Rheumatology, Imam Hossein Children's Hospital, Isfahan University of Medical Sciences, Isfahan 8174673758, Iran.

Email: mjari14@yahoo.com

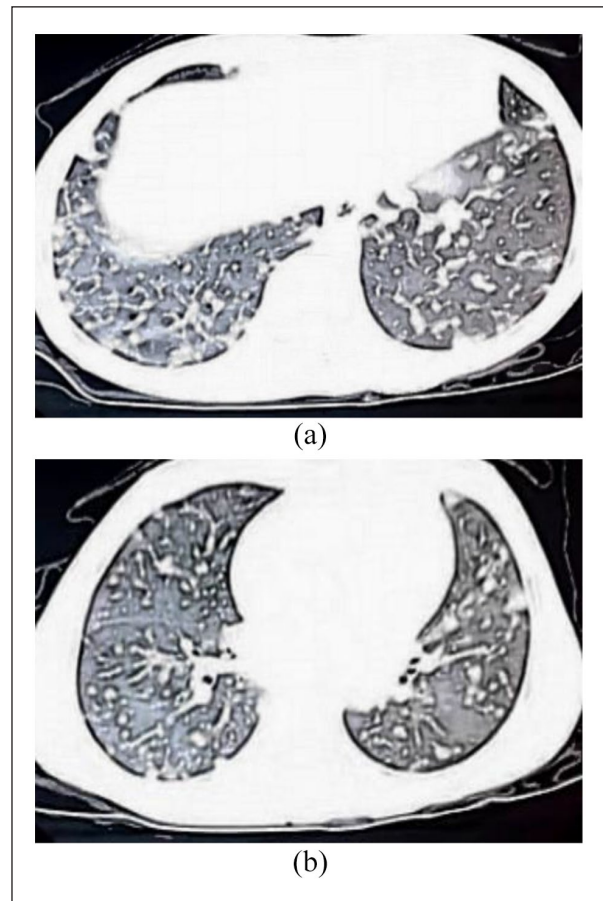




**Figure 1.** (a) Bilateral nonpurulent conjunctivitis at the first admission and (b) after treatment.

115 mm/h. Based on these laboratory findings, the patient was admitted to rheumatology ward. In addition, urinalysis showed 3+ proteinuria and 2+ hematuria, and protein in 24-hour urine was 1450 mg/24 h. Thereafter, due to a history of chronic sinusitis, paranasal sinus computed tomography (CT) scan was done, which revealed maxillary and bilateral frontal sinusitis. Besides, spiral chest CT scan showed multiple pulmonary nodules in both lungs (Figure 2).

Serum autoantibody levels were measured (antinuclear antibody), antiphospholipid antibodies and anti-DNA antibody (double-stranded DNA) were negative, but serum antineutrophil cytoplasmic antibody (C-ANCA) level was calculated as 450 IU/L, which was very high (NL <25 IU/L). Considering renal involvement and a high level of C-ANCA, renal biopsy was done. Its result confirmed ANCA-associated focal sclerosing glomerulonephritis with pauci-immune vasculitis. The patient was diagnosed with GPA in terms of the EULAR/PRINTO/PRES criteria and then methylprednisolone pulse 30 mg/kg daily (max: 1 g) and cyclophosphamide intravenous (IV) infusion were started for him, followed by oral prednisolone and cyclophosphamide IV infusion every



**Figure 2.** Multiple pulmonary nodules in both lungs.

2 weeks for a 6-week duration after being discharged and then continued every 3 weeks. After 3 months, the conjunctivitis resolved and ocular examination through slit lamp and funduscopy was found to be normal (Figure 1).

Moreover, CBC was normal, serum C-ANCA level was 75 IU/L, ESR was 45 mm/h, and protein in 24-h urine was 350 mg. Thereafter, the treatment continued based on the EULAR/PRINTO/PRES recommendation.

## Discussion

GPA is an ANCA-associated autoimmune disease, which involves small to medium-sized arteries and veins, which is characterized by necrotizing granulomatous inflammation. The common clinical characteristics of this disease include sinusitis, lung nodules, rhinorrhea, ear, and ocular manifestations.<sup>2</sup>

Diagnosis of GPA is performed based on the laboratory and clinical findings. Laboratory tests play an important role in the diagnosis of GPA. In addition, it is noteworthy that serologic indicators of the generalized inflammation such as ESR and C-reactive protein (CRP) commonly increase in

GPA. However, C3 and C4 complement levels may be reduced during this disease.<sup>2,3</sup>

One of the organs that may be involved during the course of this disease is eye with various manifestations, including episcleritis, proptosis, scleritis, uveitis, conjunctivitis, and corneal ulceration.<sup>4-6</sup> A previous study has shown that the most ocular involvement at the time of diagnosis is scleritis, followed by proptosis and uveitis. However, at the time of diagnosis, no manifestation of conjunctivitis was found.<sup>4</sup> In fact, conjunctivitis is a very rare manifestation in GPA appearing at the first stage.<sup>4,7</sup> In the present study, we attempted to report the unusual case in which bilateral conjunctivitis was the first sign in adolescence.

The patient reported in this case study presented with drug-resistant conjunctivitis, which was diagnosed by the redness of both eyes, tearing, and photophobia for 3 months.

Conjunctivitis can be inflammation or infection of the translucent mucous membrane covering the anterior part of the sclera and inside the eyelids. Conjunctiva in GPA may be ulcerative, necrotic, or cicatricial. The common manifestations of conjunctivitis are irritation, itching, foreign body sensation, and watering or discharge.<sup>8-11</sup> Although the prevalence rate of ophthalmic manifestation in GPA is about 58%, conjunctivitis is known as a very rare first manifestation.<sup>4,12,13</sup>

As the ocular manifestation of GPA is one of the most important signs of this disease, the collaboration between different specialists such as ophthalmologist and rheumatologist seems very essential in this regard.

## Conclusion

Although ocular involvement sometimes occurs in GPA, this is the first report showing that conjunctivitis may be an important indicator of GPA in adolescence.

## Declaration of conflicting interests

The author(s) declared no potential conflicts of interest with respect to the research, authorship, and/or publication of this article.

## Funding

The author(s) received no financial support for the research, authorship, and/or publication of this article.

## Ethical approval and consent to participate

We confirm that the written informed consent form has been provided by the legally authorized representatives to have the case

details published. Also, we restate that institutional approval is not required to publish the case details.

## Consent for publication

Consent for publication was obtained.

## ORCID iD

Mohsen Jari  <https://orcid.org/0000-0001-7001-6794>

## References

1. Sfiniadaki E, Tsiara I, Theodossiadi P, et al. Ocular manifestations of granulomatosis with polyangiitis: a review of the literature. *Ophthalmol Ther* 2019; 8(2): 227–234.
2. Comarmond C and Cacoub P. Granulomatosis with polyangiitis (Wegener): clinical aspects and treatment. *Autoimmun Rev* 2014; 13(11): 1121–1125.
3. Greco A, Marinelli C, Fusconi M, et al. Clinic manifestations in granulomatosis with polyangiitis. *Int J Immunopathol Pharmacol* 2016; 29(2): 151–159.
4. Hinojosa-Azaola A, García-Castro A, Juárez-Flores A, et al. Clinical significance of ocular manifestations in granulomatosis with polyangiitis: association with sinonasal involvement and damage. *Rheumatol Int* 2019; 39(3): 489–495.
5. Havuz E and GÜDÜL Havuz S. Rare presentation of severely limited granulomatosis with polyangiitis manifesting with orbital wall destruction: literature review and case report. *Arch Rheumatol* 2020; 35(2): 292–299.
6. Yang B, Yin Z, Chen S, et al. Imaging diagnosis of orbital Wegener granulomatosis: a rare case report. *Medicine* 2017; 96(23): e6904.
7. Rogaczewska M, Puszczewicz M and Stopa M. Exclusively ocular and cardiac manifestation of granulomatosis with polyangiitis—a case report. *BMC Ophthalmology* 2019; 19(1): 139.
8. Wiwatwongwana D, Esdaile JM, White VA, et al. Intravenous immunoglobulin (IVIG) for orbital Wegener's granulomatosis. *Can J Ophthalmol* 2012; 47(1): 82–83.
9. Breda L, Nozzi M, De Sanctis S, et al. Laboratory tests in the diagnosis and follow-up of pediatric rheumatic diseases: an update. *Semin Arthritis Rheum* 2010; 40(1): 53–72.
10. Azari AA and Barney NP. Conjunctivitis: a systematic review of diagnosis and treatment. *Jama* 2013; 310(16): 1721–1729.
11. Epling J. Bacterial conjunctivitis. *BMJ Clin Evid* 2012; 2012: 0704.
12. Robinson MR, Lee SS, Sneller MC, et al. Tarsal–conjunctival disease associated with Wegener's granulomatosis. *Ophthalmology* 2003; 110(9): 1770–1780.
13. Lozano-López V, Rodríguez-Lozano B, Losada-Castillo MJ, et al. Central retinal artery occlusion in Wegener's granulomatosis: a diagnostic dilemma. *J Ophthalmic Inflamm Infect* 2011; 1(2): 71–75.