



# Infection and extrusion of a subcutaneous access port in a cat: a long-term postoperative complication of a subcutaneous ureteral bypass device

*Journal of Feline Medicine and Surgery Open Reports*  
1–5

© The Author(s) 2020

Article reuse guidelines:

sagepub.com/journals-permissions

DOI: 10.1177/2055116920911765

journals.sagepub.com/home/jfmsopenreports

This paper was handled and processed by the European Editorial Office (ISFM) for publication in *JFMS Open Reports*



Aurore Fouhety<sup>1</sup> and Jean-François Boursier<sup>2</sup> 

## Abstract

**Case summary** A 5-year-old domestic shorthair neutered female cat was presented for a wound in the region of the subcutaneous ureteral bypass shunting port with externalisation of the device, 2 years after its initial positioning. The cat had had positive urine bacterial cultures over the previous year and a half without any clinical signs of urinary tract infection. Bacterial cultures of urine and the wound revealed the same bacteria, suggesting a complication caused by infected urine from the implanted system. The wound was successfully treated with surgery and at the time of writing, 3 months later, the cat is healthy with no evidence of recurrence.

**Relevance and novel information** To our knowledge, this is the first report of a subcutaneous ureteral bypass shunting port extrusion as a long-term major complication of the bacterial infection of the device.

**Keywords:** Subcutaneous ureteral bypass; complication; bacterial infection; wound; skin necrosis

**Accepted:** 7 February 2020

## Introduction

Ureteral obstruction is a well-described condition in cats and traditional surgical treatments are associated with a significant mortality and morbidity rate.<sup>1–3</sup> Benign ureteral obstruction can be due to ureterolithiasis, ureteral stricture, either alone or in combination, or the presence of a mucopurulent plug or a solidified blood clot.<sup>1,2,4,5</sup> Subcutaneous ureteral bypass (SUB) device placement has a high success rate of decompression with a low perioperative mortality rate in cats with benign ureteral obstructions.<sup>1,6–8</sup> Outcomes of a study on SUB device placement in a large population of cats have recently been published.<sup>8</sup> The long-term complications, observed more than 30 days after surgery, include obstruction of the device owing to mineralisation, kinking or blood clot.<sup>8</sup> Dysuria and chronic urinary tract infection (UTI) were also recorded and a positive postoperative urine bacterial culture result was documented in 24% of cats.<sup>8</sup> For 78% of them, a single appropriate antimicrobial treatment resulted in a negative urine

culture. Chronic bacteriuria was documented in 13% of cases; however, a third of these did not have clinical signs of UTI (subclinical bacteriuria).<sup>8</sup>

## Case description

A 5-year-old domestic shorthair neutered female cat weighing 2.6 kg was referred for a cutaneous wound overlying the SUB shunting port. Two years earlier, the cat had been seen for acute kidney injury with left ureteral obstruction caused by ureterolithiasis. At this time, the blood urea nitrogen (BUN) was 1.8 g/l (reference interval [RI] 0.2–0.6 g/l) and the creatinine was 45 mg/l

<sup>1</sup>Pommery Veterinary Hospital Centre, Internal Medicine Service, Reims, France

<sup>2</sup>Saint-Max Veterinary Clinic, Surgical Service, Saint-Max, France

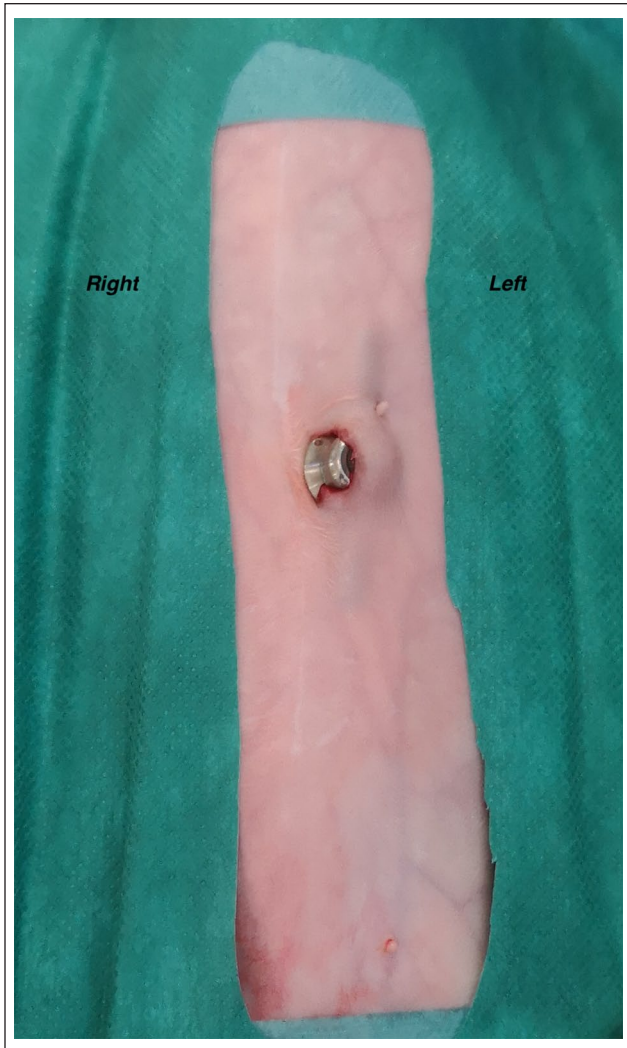
### Corresponding author:

Aurore Fouhety DVM, 56C Rue de Sillery, Reims 51100, France  
Email: aurore.fouhety@gmail.com



Creative Commons Non Commercial CC BY-NC: This article is distributed under the terms of the Creative Commons

Attribution-NonCommercial 4.0 License (<https://creativecommons.org/licenses/by-nc/4.0/>) which permits non-commercial use, reproduction and distribution of the work without further permission provided the original work is attributed as specified on the SAGE and Open Access pages (<https://us.sagepub.com/en-us/nam/open-access-at-sage>).



**Figure 1** Subcutaneous ureteral bypass shunting port encrusted with the skin on the left of the midline

(RI 5–16 mg/l). A SUB device was placed into the left kidney and the bladder, under fluoroscopic guidance, following the surgical guidelines for this procedure. The system shunting port had been placed subcutaneously, to the left of the midline. Device leakage was evaluated perioperatively during placement of the system and no leakage was observed. A urine sample was obtained from the renal pelvis during surgery and submitted for urinalysis and bacterial culture with a negative result. The cat was discharged on amoxicillin–clavulanic acid (20 mg/kg PO q12h for a week [Synulox; Zoetis]).

The device was routinely flushed 1 and 3 months after surgery. At that time the cat did not present any clinical signs of UTI and the bacterial cultures performed were negative. Blood analysis was also performed, revealing a normalisation of BUN at 0.75 g/l (RI 0.2–0.6 g/l) and the creatinine at 16 mg/l (RI 5–16 mg/l). Six months later, the cat still had no clinical signs of urinary tract disease. The

device was flushed under ultrasound guidance, and urine culture was positive. No sign of obstruction of the device was observed during the ultrasound abdominal examination. A haemolytic *Escherichia coli* sensitive to amoxicillin–clavulanic acid was isolated with a significant number of bacteria ( $10^5$  colony-forming units [CFU]/ml in a SUB port urine sample). The cat was treated with amoxicillin–clavulanic acid (20 mg/kg PO q12h; Synulox).

Three weeks later, while still on antibiotic treatment, the device was flushed again under ultrasound guidance. A urine sample was collected from the system and submitted for urinalysis and culture. No sign of obstruction of the device was observed during the ultrasound abdominal examination. As a result of the urine culture, a persistent bacteriuria was identified with a bacterium sensitive to gentamycin, tetracycline, enrofloxacin, marbofloxacin, trimethoprim–sulfamethoxazole, and resistant to ampicillin, amoxicillin–clavulanic acid, cephalexin and cefazolin. *E coli* was identified with a significant number of bacteria ( $10^5$  CFU/ml in a SUB port urine sample). At this time, the BUN was 0.5 g/l (RI 0.2–0.6 g/l) and the creatinine was 18 mg/l (RI 5–16 mg/l). No more antibiotic treatment was given. The SUB device was flushed every 3–5 months and the cat was doing well.

The last flush of the SUB device was performed 2 months before developing the wound; *E coli* was still present with a significant number of bacteria ( $10^5$  CFU/ml in a SUB port urine sample) and no associated clinical signs of UTI. At this time the BUN was 0.4 g/l (RI 0.2–0.6 g/l) and the creatinine was 15 mg/l (RI 5–16 mg/l). No sign of obstruction of the device was observed during the ultrasound abdominal examination.

On presentation, the SUB shunting port was visible within a wound, encrusted to the skin on the left of the midline (Figure 1). The patient was alert and responsive, and the rest of the physical examination revealed no abnormalities. At this time the BUN was 0.8 g/l (RI 0.2–0.6 g/l) and the creatinine was 26 mg/l (RI 5–16 mg/l). No free fluid or gas were observed on abdominal radiographs. The ultrasound did not reveal any signs of mesenteric inflammation or any evidence of extension of the infection into the abdominal cavity. There was also no observed dilatation of the renal pelvis or any sign of device obstruction.

It was decided to treat the wound surgically. The cat was anaesthetised, placed in dorsal recumbency and the ventral abdominal and thoracic regions were clipped and prepared for surgery. Perioperative analgesia was provided with intravenous buprenorphine (Vetergesic; CEVA) 0.02 mg/kg. At this time, urine was collected directly from the system port using a Huber needle. An elliptical incision was made around the wound to remove the necrotic tissues. Cutaneous and subcutaneous tissues covering the shunting port were removed

and the port was externally cleaned using 0.05% diluted chlorhexidine solution ensuring 5 mins of contact time. All tissues encrusted to the external surface of the port were removed and sent for bacterial culture. The system was checked for leaks by clamping each part of the device and injecting physiological saline solution under pressure into the port; no leakage was seen during this procedure. The port was sutured to the ventral body wall using non-absorbable monofilament suture through the ventral rectus sheath to each of the four eyelets of the port. The subcutaneous pocket was closed routinely and any dead space eliminated using absorbable monofilament suture. Postoperative analgesia was provided with buprenorphine (0.02 mg/kg IV q6h [Vetergesic; CEVA]).

The cat was discharged the day after surgery and received trimethoprim–sulfamethoxazole (15 mg/kg PO q12h for 15 days [Septotryl; Vetoquinol]). A bacterial culture was performed on the excised wound edges removed and urine collected. Urinalysis revealed a specific gravity of 1.035, pH of 6 and bacteriuria. Cytology of the urine revealed red blood cells, neutrophils and intracellular bacteria. Bacterial culture was positive for an *E coli* sensitive and resistant to the same antibiotics as previously described (sensitive to gentamycin, tetracycline, enrofloxacin, marbofloxacin and trimethoprim–sulfamethoxazole, and resistant to ampicillin, amoxicillin–clavulanic acid, cephalixin and cefazolin). Results of the bacterial culture of the wound, cutaneous and subcutaneous fragments, were identical to the result of bacterial urinalysis performed on the urine collected from the SUB device. No further antibiotic treatment was given after the end of the postoperative treatment.

At the check-up 3 weeks and then 3 months after surgery, the wound was fully healed and the cat was doing well with no clinical abnormality. The owners reported no sign of stranguria, haematuria or dysuria, and normal micturition. During the last check-up 3 months after the surgery, and 2.5 months after the end of the antibiotic treatment, a blood analysis and urine culture were performed. At this time the BUN was 0.4 g/l (RI 0.2–0.6 g/l) and the creatinine was 15 mg/l (RI 5–16 mg/l). The urine analysis revealed a density of 1.025 and *E coli* sensitive and resistant to the same antibiotics as previously described (sensitive to gentamycin, tetracycline, enrofloxacin, marbofloxacin and trimethoprim–sulfamethoxazole, and resistant to ampicillin, amoxicillin–clavulanic acid, cefalexin and cefazolin) was once again identified with a moderate number of bacteria ( $10^2$  CFU/ml in a SUB port urine sample).

## Discussion

In this case, extrusion of the SUB shunting port was observed, characterised by the visualisation of the shunting port encrusted to the skin. Major complications of

SUB device placement already reported include obstruction of the device by an obstructive blood clot or a mineralisation in 8% and 24% of cases, respectively.<sup>8</sup> Identification of the same bacteria in the urine and the tissue culture was suggestive of a wound infected by urine contamination from the SUB system. To our knowledge, extrusion of the port observed 2 years after initial positioning of the SUB device in a context of chronic UTI without clinical signs has never been reported in the veterinary medicine literature.

In the present case, a close relationship between the wound and urine leakage was highly suspected. However, it was not possible to determine whether the complication could be due to urine contamination/spreading during flushing or due to a system leakage. Device leakage was only described during the intraoperative and/or perioperative period with a reported rate of 2.3% of cases.<sup>8</sup> In our opinion, device leakage is often due to a technical surgical error from not cutting the locking string close enough to the catheter. This point of the procedure was clearly performed very carefully during the initial placement of the device and no macroscopic leakage was observed in the immediate or short-term postoperative period. Moreover, testing for leaks under pressure during the wound revision surgery did not reveal any macroscopic abnormality. In our opinion, the origin of the cutaneous and subcutaneous infection is still unclear and microscopic urine leakage cannot be ruled out. Given this fact and the fact that the device was clearly infected, replacement of the SUB device was proposed to the owner but excluded for financial reasons. Under these conditions, a diluted chlorhexidine solution was used to clean the port at a bactericidal activity concentration. Regardless of how the contamination of the wound occurred, the UTI was responsible for the long-term complication observed in this case, emphasising the importance of improving the management of cats with chronic positive urinalysis despite the absence of clinical signs of UTI.

A positive urine bacterial culture has been reported in 13–25% of cases after surgical treatment of ureteral obstruction by a SUB device or stent implantation.<sup>7–10</sup> A positive bacterial urinalysis observed a long time after the surgery has already been reported with a median time of 55 days after discharge.<sup>10</sup> The most commonly identified bacteria during the postoperative period after SUB device placement were *Enterococcus* species, *E coli* and *Staphylococcus* species for more than 70% of cases.<sup>8,10</sup> In this study, a positive urinalysis was observed for the first time 6 months after surgery with the identification of *E coli*.

Cats that received direct postoperative antibiotic treatment were significantly less likely to present a bacteriuria after the surgery.<sup>10</sup> In this case, antibiotics were administered directly after the surgery and urine cultures

performed up to 3 months after surgery were negative, which is consistent with this study.

Only 7–37% of cats with a SUB device and positive bacterial urinalysis presented clinical signs of UTI.<sup>8,10</sup> Recent guidelines for the diagnosis and management of bacterial UTIs define subclinical bacteriuria as the presence of bacteria in urine revealed by a positive bacterial culture of a properly collected urine specimen, in the absence of clinical evidence of infectious urinary tract disease.<sup>11</sup> Guidelines for antimicrobial use in human medicine contain strong recommendations against screening for and treating asymptomatic bacteriuria.<sup>12</sup> The presence of multidrug-resistant bacteria should not affect the decision of whether or not to treat subclinical bacteriuria.<sup>11,12</sup> Nowadays, the medical strategy facing positive urinalysis in cats with a SUB has not been clearly established. There is no consensus on the introduction of an antibiotic therapy in the management of renal implants (SUB or stent) associated with positive urine culture with no clinical signs.<sup>10,11</sup> Prospective, randomised studies that evaluate the effect of postoperative antimicrobial use in cats following SUB device placement are required.<sup>11,13</sup>

In this case, after the first postoperative positive urine culture, despite the absence of clinical signs of UTI, an appropriate antimicrobial treatment was used, based on antimicrobial susceptibility testing. The follow-up urine bacterial culture was once again positive for *E coli*, but the bacteria had developed a resistance to amoxicillin-clavulanic acid. At this point, because of the absence of concomitant clinical signs of UTI, it was decided to discontinue the antibiotics administration. The goal was to avoid development of a multi-resistant bacteria resulting in a difficult to treat chronic UTI. This case describes a not previously reported long-term complication of a SUB device in close relationship with the bacteriuria without clinical signs. Further studies could be necessary to improve understanding and management of subclinical bacteriuria and UTI in cats with a SUB device.

The subcutaneous shunting port is available for flushing the device, helping to maintain a high patency rate. The use of a tetrasodium EDTA acid flush solution through the subcutaneous shunting port in order to demineralise and restore patency of the SUB device has already been established in veterinary medicine.<sup>14</sup> Moreover, the antimicrobial and anti-biofilm properties of EDTA in wounds and indwelling catheters have been studied.<sup>15–17</sup> In a recent study, it was shown that the implementation of routine irrigation of the SUB device using tetrasodium EDTA solution appeared to decrease infection rates associated with SUB devices in cats.<sup>14</sup> However, large clinical studies are required to establish the effectiveness of tetrasodium EDTA acid flush solution to prevent and treat biofilms in SUB devices, and to manage chronic SUB system infections, before this becomes common practice in veterinary medicine.

Concerning the present case, a moderate number of bacteria (10<sup>2</sup> CFU/ml in a SUB port urine sample) were identified at the last check-up 3 months after the surgery, which is lower than the threshold for significance in cats. However, other complications such as a new extrusion of the system or clinical bacteriuria will be possible. More frequent follow-up and flushing of the system with tetrasodium EDTA acid flush solution were recommended for this case but declined by the owner for financial reasons.

## Conclusions

To our knowledge, this is the first report of a SUB device extrusion observed 2 years after the initial positioning of the system in the context of chronic UTI without clinical signs in a domestic cat. This new long-term major complication suggests the need to improve the management of chronic UTI following SUB device placement despite the absence of clinical signs.

**Conflict of interest** The authors declared no potential conflicts of interest with respect to the research, authorship, and/or publication of this article.

**Funding** The authors received no financial support for the research, authorship, and/or publication of this article.

**Ethical approval** This work involved the use of non-experimental animal(s) only (owned or unowned), and followed established internationally recognised high standards ('best practice') of individual veterinary clinical patient care. Ethical approval from a committee was not necessarily required.

**Informed consent** Informed consent (either verbal or written) was obtained from the owner or legal custodian of all animal(s) described in this work for the procedure(s) undertaken. For any animals or humans individually identifiable within this publication, informed consent for their use in the publication (verbal or written) was obtained from the people involved.

**ORCID iD** Jean-François Boursier  <https://orcid.org/0000-0002-5217-6695>

## References

- 1 Kyles AE, Hardie EM, Wooden BG, et al. **Management and outcome of cats with ureteral calculi: 153 cases (1984–2002).** *J Am Vet Med Assoc* 2005; 226: 937–944.
- 2 Berent AC. **Ureteral obstructions in dogs and cats: a review of traditional and new interventional diagnostic and therapeutic options.** *J Vet Emerg Crit Care* 2011; 21: 86–103.
- 3 Culp WT, Palm CA, Hsueh C, et al. **Outcome in cats with benign ureteral obstructions treated by means of ureteral stenting versus ureterotomy.** *J Am Vet Med Assoc* 2016; 249: 1292–1300.
- 4 Westropp JL, Ruby AL, Bailiff NL, et al. **Dried solidified blood calculi in the urinary tract of cats.** *J Vet Intern Med* 2006; 20: 828–834.

- 5 Zaid MS, Berent AC, Weisse C, et al. **Feline ureteral strictures: 10 cases (2007–2009).** *J Vet Intern Med* 2011; 25: 222–229.
- 6 Horowitz C, Berent AC, Weisse C, et al. **Predictors of outcome for cats with ureteral obstructions after interventional management using ureteral stents or a subcutaneous ureteral bypass device.** *J Feline Med Surg* 2013; 15: 1052–1062.
- 7 Berent AC, Weisse CW, Todd K, et al. **Technical and clinical outcomes of ureteral stenting in cats with benign ureteral obstruction: 69 cases (2006–2010).** *J Am Vet Med Assoc* 2014; 244: 559–576.
- 8 Berent AC, Weisse CW, Bagley DH, et al. **Use of a subcutaneous ureteral bypass device for treatment of benign ureteral obstruction in cats: 174 ureters in 137 cats (2009–2015).** *J Am Vet Med Assoc* 2018; 253: 1309–1327.
- 9 Wormser C, Clarke DL and Aronson LR. **Outcomes of ureteral surgery and ureteral stenting in cats: 117 cases (2006–2014).** *J Am Vet Med Assoc* 2016; 248: 518–525.
- 10 Kopečný L, Palm CA, Drobotz KJ, et al. **Risk factors for positive urine cultures in cats with subcutaneous ureteral bypass and ureteral stents (2010–2016).** *J Vet Intern Med* 2019; 33: 178–183.
- 11 Weese JS, Blondeau J, Boothe D, et al. **International Society for Companion Animal Infectious Diseases (ISCAID) guidelines for the diagnosis and management of bacterial urinary tract infections in dogs and cats.** *Vet J* 2019; 247: 8–25.
- 12 Dorsch R, Teichmann-Knorrn S and Lund HS. **Urinary tract infection and subclinical bacteriuria in cats: a clinical update.** *J Feline Med Surg* 2019; 21: 1023–1038.
- 13 Berent AC. **Treatment of feline ureteral obstructions: stents versus SUBs – the last 10 years of experience.** Proceedings of the American College of Veterinary Internal Medicine Forum; 2016 Jun 8–11; Denver, CO, USA.
- 14 Chik C, Berent AC, Weisse CW, et al. **Therapeutic use of tetrasodium ethylenediaminetetraacetic acid solution for treatment of subcutaneous ureteral bypass device mineralization in cats.** *J Vet Intern Med* 2019; 33: 2124–2132.
- 15 Raad I, Hanna H, Dvorak T, et al. **Optimal antimicrobial catheter lock solution, using different combinations of minocycline, EDTA, and 25-percent ethanol, rapidly eradicates organisms embedded in biofilm.** *Antimicrob Agents Chemother* 2007; 51: 78–83.
- 16 Finnegan S and Percival SL. **EDTA: an antimicrobial and antibiofilm agent for use in wound care.** *Adv Wound Care (New Rochelle)* 2015; 4: 415–421.
- 17 Percival SL and Salisbury AM. **The efficacy of tetrasodium EDTA on biofilms.** *Adv Microbiol Infect Dis Public Health* 2018; 9: 101–110.