



Case Report

Intractable myoclonic seizures in an allogeneic stem cell transplant recipient: A rare case of myoclonic epilepsy



Anna Robuccio^{a,b,1}, Paddy Ssentongo^{a,b,1}, Michael D. Sather^d, David F. Claxton^e, Frank G. Gilliam^{a,c,d,*}

^a Center for Neural Engineering, Science and Mechanics, The Pennsylvania State University, University Park, PA 16802, USA

^b Department of Engineering, Science and Mechanics, The Pennsylvania State University, University Park, PA 16802, USA

^c Department of Neurology, Penn State Hershey College of Medicine, 500 University Drive, Hershey, PA 17033, USA

^d Department of Neurosurgery, Penn State Hershey College of Medicine, 500 University Drive, Hershey, PA 17033, USA

^e Penn State Cancer Institute, Penn State Hershey College of Medicine, 500 University Drive, Hershey, PA 17033, USA

ARTICLE INFO

Article history:

Received 19 May 2015

Received in revised form 12 June 2015

Accepted 15 June 2015

Available online xxx

Keywords:

GVHD

Allogeneic transplants

Myoclonus

Epilepsy

Seizure

ABSTRACT

Introduction: Myoclonus may be a rare complication of stem cell transplant but has limited discussion in the scientific literature.

Case: We present a case of an acute myeloid leukemia survivor who developed refractory myoclonic epilepsy four years after graft versus host disease (GVHD) developed six days following matched unrelated allogeneic hematopoietic stem cell transplant.

Discussion: Graft versus host disease occurs in 30–50% of allogeneic hematopoietic stem cell transplant patients and may cause pharmacoresistant myoclonic epilepsy; however, the mechanisms by which GVHD leads to recurrent myoclonic seizures are not well understood (Lee, 2005) [1]. The paucity of clinical reports of such manifestation makes it difficult to diagnose and effectively manage these patients.

© 2015 The Authors. Published by Elsevier Inc. This is an open access article under the CC BY-NC-ND license (<http://creativecommons.org/licenses/by-nc-nd/4.0/>).

1. Introduction

The definition of “epileptic myoclonus” has changed several times over the past 3 decades. Myoclonus is currently defined as sudden involuntary jerking of a muscle or groups [2]. Myoclonus is associated with multiple epilepsy syndromes such as juvenile myoclonic epilepsy and the progressive myoclonic epilepsies. Although the neurophysiology of myoclonus is incompletely understood [1], spatial and temporal amplification within relevant networks may cause the epileptic motor activity. [3].

Recently, graft versus host disease was observed to cause central nervous system (CNS) complications following allogeneic stem cell transplants (allo-HSCTs) [4–9]. However, very few patients have presented with myoclonus [6,9]. We describe an allo-HSCT patient who developed chronic GVHD, associated with intractable myoclonic seizures. This appears to be an uncommon example of symptomatic myoclonic epilepsy, defined as clinical myoclonus associated with diffuse polyspike activity on EEG following a known cerebral insult.

2. Case

A 48-year-old male was diagnosed with Philadelphia chromosome positive acute myelogenous leukemia in 9/03/2008. He received a 7 + 3 induction chemotherapy (3 days of daunorubicin and 7 days of continuous infusion of cytosine arabinoside) in September with 400 mg of imatinib given for 14 days of the induction. A bone marrow on 10/23/2008 was consistent with a complete remission – there was no morphological evidence of residual acute leukemia. At that time, quantitative PCR for bcr-abl p210, previously positive, was negative. Imatinib was resumed at 800 mg daily. The patient subsequently remained in complete morphological and molecular remission of his leukemia. He then received nonmyeloablative conditioning chemotherapy with fludarabine and cyclophosphamide prior to allogeneic stem cell transplantation with matched unrelated donor stem cells on 2/23/09 without incident. He remained stable and tolerated the course well.

The patient recovered normal hematopoiesis rapidly, but donor engraftment as documented by XY fluorescence in-situ hybridization (FISH) was initially modest – XX was initially only 1.4%.

Between 06/22/2009 and 07/23/2009, his XX engraftment rose from 9.2% to 98.0%. He was diagnosed with chronic graft versus host disease on 10/20/2011 (more than two years after stem cell transplant); the patient presented with significant irritation and thickening of the

* Corresponding author at: Department of Neurology, Penn State Hershey College of Medicine, 500 University Drive Hershey, PA 17033, USA.

E-mail address: fgilliam@hmc.psu.edu (F.G. Gilliam).

¹ Authors contributed equally.

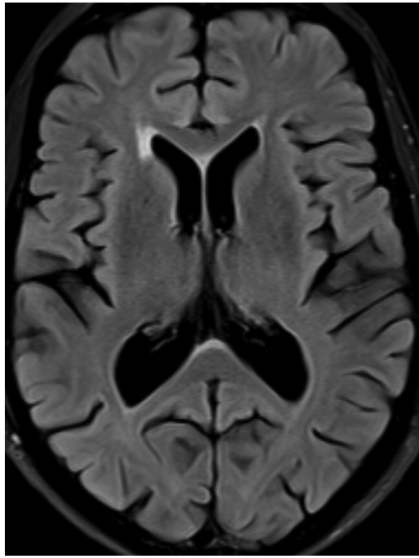


Fig. 1. MRI of axial FLAIR sequence with right periventricular increased signal.

mucosae over the tongue and buccal surfaces. He was treated with topical oral dexamethasone swish and spit and tacrolimus.

In June 2012, the patient presented with myoclonic jerks involving his arms and legs. They caused occasional falls, but he denied any loss of consciousness. In spite of levetiracetam, he continued to have episodes multiple times per day. He was admitted to the neurology service after a myoclonic jerk that resulted in a fall with loss of consciousness. His neurological exam was unremarkable except for frequent myoclonic jerks of the extremities with brief alteration in awareness and responsiveness. Brain magnetic resonance imaging revealed periventricular

white matter lesions (Fig. 1). Electroencephalography showed frequent generalized 40–70 μ V polyspike activity that occurred in runs lasting from 0.5–3 s, maximal in the frontocentral regions (Fig. 2). This activity was seen spontaneously and during photic stimulation. Perampanel improved his symptoms by 40%. However, his seizures then worsened and were intractable to levetiracetam, valproic acid, topiramate, lorazepam, clonazepam, zonisamide, and lacosamide. Vagal nerve stimulation did not improve the frequency or severity of the myoclonic jerks. For chronic oral graft versus host disease, the patient requires ongoing immunosuppression with tacrolimus, mycophenolate, and oral topical dexamethasone. Attempts to taper tacrolimus have resulted in problematic ulcerative oral inflammation. In spite of immunosuppressive agents, he experiences some ongoing oral mucosal irritation.

3. Discussion

Chronic GVHD is recognized to cause neurological manifestations [4–9], but little is known about its relationship with symptomatic myoclonus, resulting in a scarcity of information of the natural history or treatment outcomes. Initially, our patient received partial relief from perampanel, but his condition proved to be intractable to more than eight antiepileptic drugs and vagal nerve stimulation. He continues to have 3 or more seizures per hour, resulting in up to 100 per day. We summarize several case studies written within the last 30 years in Table 1. However, nearly all reported patients have died or are still suffering from severe epilepsy. Further research is needed to determine an appropriate protocol for patients who develop myoclonus following GVHD.

Conflict of interest statement

The authors declare that there are no conflicts of interest.

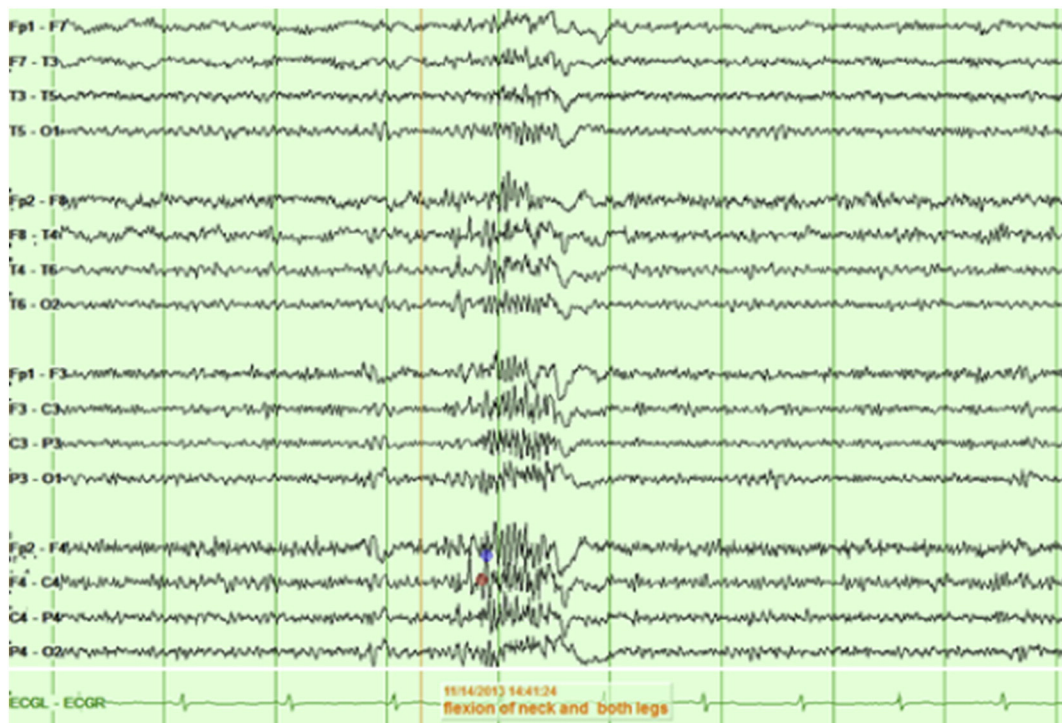


Fig. 2. EEG with diffuse polyspike activity associated with prominent myoclonus consisting of brief flexion of the neck and both legs.

Table 1

Author	Type of transplant/GVHD	Number of patients	Clinical features	MRI/neuropathology	CSF	EEG	Other	Type of seizures	Treatment for epilepsy	Treatment outcome	Time of onset after transplant
Starzl et al. (1978) [10]	OLT	9	Leg spasticity, decreased mentation, right hemiparesis, akinetic mutism, stupor and coma, seizures	Multifocal areas of infarction in cerebral cortex and basal ganglia, CPM	N/A	Diffusely slow and nonfocal	Cerebral angiography: thrombotic or embolic disease	G, F	N/A	Died	Between 3 and 72 days
Adams et al. (1987) [11]	OLT	13	Convulsions	N/A	N/A	Focal EEG abnormalities, right posterior quadrant abnormalities, right sided continuous spikes	CAT scan showing low density areas right occipital lobe	G (10), F (1), M (2)	Phenytoin (worked in 10 of 13)	Died in SE (2)	Median: 7 days
Iwasaki et al. (1993) [8]	allo-HSCT	2	Encephalopathy, spasticity, seizures	Cortical atrophy, ventricular dilatation	EP, Pleo	N/A	Autopsy: diffuse infiltration of white matter with CD3 lymphocytes	G	N/A	Died	Both patients died 8–9 months after transplant.
Provenzale and Graham (1996) [6]	allo-HSCT	1	Disorientation, myoclonus, tremor	Diffuse WML, multiple foci of hyper-intense signal on T2-weighted images in the brain stem and deep white matter	EP, elevated IGG and albumin, no Pleo	Diffuse slowing	Biopsy of colonic mucosa: persistent GVHD	M	Methyl prednisone	Partial response died on day 123	71 days
Ma et al. (2002) [12]	allo-HSC	1	Cognitive decline, seizures, encephalopathy	WML, atrophy	EP + L, NG	Moderate to severe bilateral slowing	Antemortem histology: vasculitis	F	Methyl prednisone	Partial improvement	2 months
Shortt et al. (2006) [13]	auto-HSCT and allo-HSCT	1	Personality changes, seizures, cognitive dysfunction, headache	Diffuse WML with periventricular predominance	EP + L, NG	N/A	No brain biopsy	F	Methyl prednisolone, phenytoin, and sirolimus	Complete response	14 months after second transplant
Kamble et al. (2007) [5]	allo-HSCT/	2	Right hemiparesis/encephalopathy, seizures	Infiltrating WML, left frontal parietal lobe with minimal enhancement/patch areas of increased intensity in pontine white matter, caudate nuclei, putamina, bilateral cerebral and cerebellar white matter	WNL/EP + L, NG, normal LDH	N/A	Perivascular lymphocytic infiltrates composed of T-lymphocytes from the donor predominantly in the brain parenchyma (BB), autopsy: leptomenigeal perivascular inflammation	N/A	Methyl prednisone/high dose steroids	Complete response, died	18 months/178 days
Zhang et al. (2013) [14]	allo-HSCT	79	Seizures	Demyelination (8), CNS infection (8), intracranial hemorrhage (3), cerebral infarction (2), and CNS tumors (1)	WNL (3), increased pressure or EP (12)	Abnormal (2)	CNS fungal infection (BB, 1)	F (21), G (51)	Diazepam and phenobarbital	42 (53.2%) died	Conditioning stage (3), day 0–100 (52), day 100–365 (20), 365+ (4)

Abbreviations: F = focal, G = generalized, M = myoclonus, N/A = not available, OLT = orthotopic liver transplant, allo-HSCT = allogeneic hematopoietic stem cell transplant, auto-HSCT = autogenic hematopoietic stem transplant, WML = white matter lesion, CPM = central pontine myelinolysis, EP = elevated protein, EP + L = elevated protein + lymphocytes, NG = normal glucose, LDH = lactate dehydrogenase, Pleo = Pleocytosis, CSF = cerebral spinal fluid, MRI = magnetic resonance imaging, CAT = computer axial tomography, GVHD = graft versus host disease, WNL = within normal limits, BB = brain biopsy.

Literature review describing neurological manifestations in transplant recipients.

Acknowledgments

We would like to acknowledge Dr. Steven J. Schiff for helpful discussions.

References

- [1] Lee SJ. New approaches for preventing and treating chronic graft-versus-host disease. *Blood* 2005;105:4200–6. <http://dx.doi.org/10.1182/blood-2004-10-4023>.
- [2] Aigner B, DW M. Myoclonus: clinical significance and an approach to classification. *AMA Arch Neurol* 1960;2:600–15.
- [3] Guerrini R, Parmeggiani L, Kaminska A, Dulac O. Myoclonic astatic epilepsy. *Epileptic Syndr Infancy Child Adolesc* 2002;3:105–12.
- [4] Taylor JW, Schiff D. Neurologic complications. *Blood Marrow Transpl. Handb. Springer*; 2015. p. 311–21.
- [5] Kamble RT, Chang C-C, Sanchez S, Carrum G. Central nervous system graft-versus-host disease: report of two cases and literature review. vol. 39. 2007. <http://dx.doi.org/10.1038/sj.bmt.1705540>.
- [6] Provenzale JM, Graham ML. Reversible leukoencephalopathy associated with graft-versus-host disease: MR findings. *Am J Neuroradiol* 1996;17:1290–4.
- [7] Marosi C, Budka H, Grimm G, Zeitlhofer J, Sluga E, Brunner C, et al. Fatal encephalitis in a patient with chronic graft-versus-host disease, vol. 6 ; 1990.
- [8] Iwasaki Y, Sako K, Ohara Y, Miyazawa M, Minegishi M, Tsuchiya S. et al. Subacute panencephalitis associated with chronic graft-versus-host disease. *Acta Neuropathol* 1993;85(5):566–72.
- [9] Lockman LA, Sung JH, Krivit W. Acute parkinsonian syndrome with demyelinating leukoencephalopathy in bone marrow transplant recipients. *Pediatr Neurol* 1991; 7:457–63. [http://dx.doi.org/10.1016/0887-8994\(91\)90031-F](http://dx.doi.org/10.1016/0887-8994(91)90031-F).
- [10] Starzl TE, Schneck SA, Mazzoni G, Aldrete JA, Porter KA, Schröter GP, et al. Acute neurological complications after liver transplantation with particular reference to intraoperative cerebral air embolus. *Ann Surg* 1978;187:236–40. <http://dx.doi.org/10.1097/0000658-197803000-00003>.
- [11] Adams DH, Gunson B, Honigsberger L, Buckels J, Ponsford S, Boon A, et al. Neurological complications following liver transplantation. *Lancet* 1987;329:949–51. [http://dx.doi.org/10.1016/S0140-6736\(87\)90294-7](http://dx.doi.org/10.1016/S0140-6736(87)90294-7).
- [12] Ma M, Barnes G, Pulliam J, Jezek D, Baumann RJ, Berger JR. CNS angiitis in graft vs host disease. *Neurology* 2002;59:1994–7.
- [13] Shortt J, Hutton E, Faragher M, Spencer A. Central nervous system graft-versus-host disease post allogeneic stem cell transplant. *Br J Haematol* 2006;132:245–7. <http://dx.doi.org/10.1111/j.1365-2141.2005.05864.x>.
- [14] Zhang XH, Huang XJ, Liu KY, Xu LP, Liu DH, Chen H, et al. Idiopathic inflammatory demyelinating diseases of the central nervous system in patients following allogeneic hematopoietic stem cell transplantation: a retrospective analysis of incidence, risk factors and survival. *Chin Med J (Engl)* 2013;126:1096–102. <http://dx.doi.org/10.1111/ctr.12000>.