

Injury of the cortico-ponto-cerebellar tract in a patient with mild traumatic brain injury

A case report

Sung Ho Jang, MD^a, Hyeok Gyu Kwon, PhD^{b,*}

Abstract

Rationale: We report on a patient with injury of the cortico-ponto-cerebellar tract (CPCT) following mild traumatic brain injury (TBI), diagnosed by diffusion tensor tractography (DTT).

Patient concerns: A 53-year-old female patient was injured in a car crash. While under treatment at a local medical center for headache, mild motor weakness, and cognitive impairment that developed following the car crash, she fell, hitting her head on the ground, about six weeks after the car crash.

Diagnoses: Approximately three months after the car crash, she began to show tremor on both hands and mild truncal ataxia. Twenty months after the car crash, when she underwent neurological evaluation at the rehabilitation department of a university hospital, she presented with mild resting and intentional tremor on both hands, and mild truncal ataxia.

Interventions: N/A.

Outcomes: On 20-month DTT, the left CPCT showed tearing at the level of the subcortical white matter and pons, and discontinuation at the cerebellar portion. However, the integrity of the DRTT was well-preserved in both hemispheres.

Lessons: Using DTT, injury of the CPCT was demonstrated in a patient with ataxia and tremor following mild TBI.

Abbreviations: CPCT = cortico-ponto-cerebellar tract, DRTT = dentato-rubro-thalamic tract, DTI = diffusion tensor imaging, DTT = diffusion tensor tractography, GCS = Glasgow Coma Scale, ROI = region of interest, TAI = traumatic axonal injury, TBI = traumatic brain injury.

Keywords: ataxia, cortico-ponto-cerebellar tract, diffusion tensor imaging, mild traumatic brain injury, tremor

1. Introduction

The cerebellum, located in the posterior fossa of the brain, is important in coordinating movement by communicating with the cerebrum via cerebellar peduncles.^[1] The cortico-ponto-cerebellar tract (CPCT) and dentato-rubro-thalamic tract (DRTT) are major neural circuits on the cerebellum for movement coordination.^[2,3] The CPCT, a major afferent fiber in the middle cerebellar peduncle, and the DRTT, a major efferent fiber in the superior

cerebellar peduncle, are involved in coordination of movement.^[2] Hence, injury of the CPCT and DRTT is usually accompanied by cerebellar symptoms including ataxia and tremor.^[4-8] Several studies have reported clinical features following injury of the CPCT or DRTT in stroke, neurodegenerative disease, and traumatic brain injury (TBI).^[4-8]

Mild TBI, comprising 70% to 90% of all TBI, is defined as less than 30 minutes of loss of consciousness, less than 24 hours of post-traumatic amnesia, and an initial Glasgow Coma Scale (GCS) score of 13 to 15. At least 15% of patients with mild TBI present with disabling symptoms even though no abnormal lesion is observed in the brain computed tomography (CT) and magnetic resonance imaging (MRI).^[9-11] It is very difficult to find an abnormal lesion following mild TBI with conventional MRI.^[12-14] Recently developed diffusion tensor tractography (DTT), derived from diffusion tensor imaging (DTI), allows estimation and visualization of the microstructural integrity of white matter and has a unique advantage in detection of invisible neural injury in patients with mild TBI.^[15-18] A recent study using DTT demonstrated injury of the DRTT in a patient with mild TBI.^[8] However, no study on injury of the CPCT in patients with mild TBI has been reported.

In this study, we report a patient with injury of the CPCT following mild TBI, diagnosed by DTT.

2. Case report

A 53-year-old female patient was injured in a car crash. The patient was struck from behind by a mini-bus while stopped waiting for a signal at an intersection. Her head hit the wheel during head flexion. The patient lost consciousness for approximately 10 minutes and experienced post-traumatic

Editor: N/A.

Funding/support: This research was supported by Basic Science Research Program through the National Research Foundation of Korea (NRF) funded by the Ministry of Education (2015R1D1A4A01020385).

The authors have no conflicts of interest to disclose.

^a Department of Physical Medicine and Rehabilitation, College of Medicine, Yeungnam University, Gyeongsangbuk-do, ^b Department of Physical Therapy, College of Health Sciences, Catholic University of Pusan, Pusan, Republic of Korea.

* Correspondence: Hyeok Gyu Kwon, Department of Physical Therapy, College of Health Sciences, Catholic University of Pusan, Department of Physical Therapy, College of Health Sciences, Catholic University of Pusan, 57 Oryundae-ro, Geumjeong-gu, Pusan 46252, Republic of Korea (e-mail: khg0715@hanmail.net).

Copyright © 2017 the Author(s). Published by Wolters Kluwer Health, Inc. This is an open access article distributed under the terms of the Creative Commons Attribution-Non Commercial-No Derivatives License 4.0 (CCBY-NC-ND), where it is permissible to download and share the work provided it is properly cited. The work cannot be changed in any way or used commercially without permission from the journal.

Medicine (2017) 96:49(e8749)

Received: 25 August 2017 / Received in final form: 12 October 2017 /

Accepted: 16 October 2017

<http://dx.doi.org/10.1097/MD.00000000000008749>

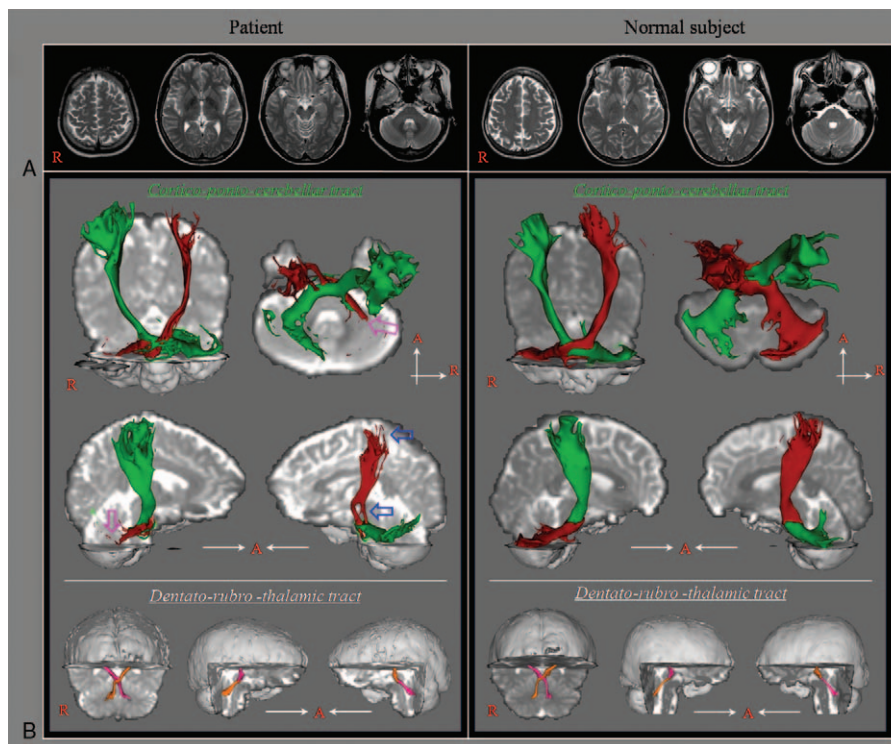


Figure 1. (A) T2-weighted brain MR images at 20 months after onset show no abnormality. (B) Results of diffusion tensor tractography for the cortico-ponto-cerebellar tract (CPCT). The left CPCT shows tearing (blue arrows) at the level of the subcortical white matter and pons, and discontinuation (purple arrows) at the cerebellar portion. However, the integrity of the dentato-rubro-thalamic tract is well preserved in both hemispheres.

amnesia for approximately 15 minutes after the head trauma. Her GCS score was 15. While under treatment at a local medical center for headache, mild motor weakness, and cognitive impairment that developed following the car crash, she fell, hitting her head on the ground, about 6 weeks after the car crash. She lost consciousness for approximately 10 minutes, without post-traumatic amnesia. However, her GCS score was 15. Approximately 3 months after the car crash, she began to show tremor on both hands and mild truncal ataxia. Twenty months after the car crash, when she underwent neurological evaluation at the rehabilitation department of a university hospital, she presented with mild resting and intentional tremor on both hands, and mild truncal ataxia (the Scale for the Assessment and Rating of Ataxia—8 points, full score: 40 points; higher points means more severe ataxia).^[19] No specific lesion was observed on conventional brain MRI (Fig. 1A). The patient provided written and informed consent. The study protocol was approved by the Yeungnam University Hospital Institutional Research Board.

2.1. Diffusion tensor tractography

DTI data were acquired at 20 months after the car crash using a 1.5T (Philips, Ltd, Best, The Netherlands) with 32 gradients. Imaging parameters were as follows: acquisition matrix = 96×96 ; reconstructed to matrix = 192×192 ; field of view = $240 \times 240 \text{ mm}^2$; echo time = 10,398ms; repetition time = 72ms; $b = 1000 \text{ s/mm}^2$; and a slice thickness of 2.5mm. Before the fiber tracking, eddy current correction was applied to correct the head motion effect and image distortion using the Oxford Centre for Functional Magnetic Resonance Imaging of the Brain (FMRIB) Software Library.^[20] For fiber tracking, we used FMRIB

Software Library based on probability tracking with a result threshold of 2 streamlines.^[20] For reconstruction of the CPCT, seed region of interest (ROI) was given at the primary sensorimotor cortex on the axial image and 2 target ROIs were placed at the anterior portion of pons on the axial image and the contralateral middle cerebellar peduncle on the coronal image.^[16] For the DRTT, seed ROI was placed on the dentate nucleus behind the floor of the fourth ventricle on the coronal image.^[15] Two target ROIs were given at the junction of the superior cerebellar peduncle between the upper pons and cerebellum on the coronal image and the contralateral red nucleus of the upper midbrain on the axial image.

On 20-month DTT, the left CPCT showed tearing at the level of the subcortical white matter and pons, and discontinuation at the cerebellar portion (Fig. 1B). However, the integrity of the DRTT was well preserved in both hemispheres.

3. Discussion

In this study, using DTT, we found injury (tearing and discontinuation) of the left CPCT with preservation of the DRTT in both hemispheres in a patient with ataxia and tremor following mild TBI. Thus, the ataxia and tremor in this patient can be partially ascribed to injury of the left CPCT. Because no definite brain lesion was detected on conventional brain MRI, traumatic axonal injury (TAI) was the most likely pathogenetic mechanism in this patient.^[21–24] However, we could not discern whether this injury resulted from the car crash or the later fall. The delayed onset (3 months after the car crash and 6 weeks after the fall) of ataxia and tremor suggests that the TAI was a secondary injury in which axons were not initially damaged, but

injured by a sequential process of impaired axoplasmic transport, continued axonal swelling, and disconnection.^[25]

Several studies using DTI have reported injury of the CPCT in patients following stroke and neurodegenerative disease.^[4–7] Kitamura et al^[4] reported that fractional anisotropy value of damaged CPCT was associated with ataxia severity in 18 patients with neurodegenerative disease. In 2012, Min et al^[5] described an abnormal portion of the CPCT in a patient with cerebellar ataxia following central pontine myelinolysis. In 2016, Jang et al^[6] reported that severe ataxia in a patient with bilateral tegmental pontine hemorrhage was attributed to thinning of the CPCTs in both hemispheres. The following year, Schulz et al^[7] reported that injury of the CPCT related with residual motor function in 26 patients with chronic ischemic stroke. To our best knowledge, this is the first study to demonstrate injury of the CPCT in a patient with mild TBI. However, this study is limited because it is based on a single case report. In addition, DTT can produce both false-positive and negative results due to multiple fiber directions in a voxel or partial volume effect throughout the white matter of the brain.^[26]

In conclusion, using DTT, injury of the CPCT was diagnosed in a patient with ataxia and tremor following mild TBI. We believe that evaluation of the CPCT would be helpful in diagnosis of patients who show movement coordination problems such as ataxia and tremor following mild TBI.

References

- Javalkar V, Khan M, Davis DE. Clinical manifestations of cerebellar disease. *Neurol Clin* 2014;32:871–9.
- Affi AK, Bergman RA. *Functional Neuroanatomy: Text and Atlas*. 2nd ed. New York: Lange Medical Books/McGraw-Hill; 2005.
- Mendoza JE, Foundas AL. *Clinical Neuroanatomy: a Neurobehavioral Approach*. New York; London: Springer; 2007.
- Kitamura K, Nakayama K, Kosaka S, et al. Diffusion tensor imaging of the cortico-ponto-cerebellar pathway in patients with adult-onset ataxic neurodegenerative disease. *Neuroradiology* 2008;50:285–92.
- Min Y, Park SH, Hwang SB. Corticospinal tract and pontocerebellar fiber of central pontine myelinolysis. *Ann Rehabil Med* 2012;36:887–92.
- Jang SH, Chang CH, Jung YJ, et al. Severe ataxia due to injuries of neural tract detected by diffusion tensor tractography in a patient with pontine hemorrhage: a case report. *Medicine (Baltimore)* 2016;95:e5590.
- Schulz R, Frey BM, Koch P, et al. Cortico-cerebellar structural connectivity is related to residual motor output in chronic stroke. *Cereb Cortex* 2017;27:635–45.
- Jang SH, Kwon HG. Injury of the dentato-rubro-thalamic tract in a patient with mild traumatic brain injury. *Brain Inj* 2015;29:1725–8.
- Alemanly Ripoll M, Stenborg A, Sonninen P, et al. Detection and appearance of intraparenchymal haematomas of the brain at 1.5T with spin-echo, FLAIR and GE sequences: poor relationship to the age of the haematoma. *Neuroradiology* 2004;46:435–43.
- Rutherford WH, Merrett JD, McDonald JR. Symptoms at one year following concussion from minor head injuries. *Injury* 1979;10:225–30.
- McLean AJr, Temkin NR, Dikmen S, et al. The behavioral sequelae of head injury. *J Clin Neuropsychol* 1983;5:361–76.
- Bazarian JJ, Zhong J, Blyth B, et al. Diffusion tensor imaging detects clinically important axonal damage after mild traumatic brain injury: a pilot study. *J Neurotrauma* 2007;24:1447–59.
- Hughes DG, Jackson A, Mason DL, et al. Abnormalities on magnetic resonance imaging seen acutely following mild traumatic brain injury: correlation with neuropsychological tests and delayed recovery. *Neuroradiology* 2004;46:550–8.
- Xiong KL, Zhu YS, Zhang WG. Diffusion tensor imaging and magnetic resonance spectroscopy in traumatic brain injury: a review of recent literature. *Brain Imaging Behav* 2014;8:487–96.
- Kwon HG, Hong JH, Hong CP, et al. Dentatorubrothalamic tract in human brain: diffusion tensor tractography study. *Neuroradiology* 2011;53:787–91.
- Hong JH, Jang SH. Functional magnetic resonance imaging and diffusion tensor tractography of the corticopontocerebellar tract in the human brain. *Neural Regen Res* 2011;6:76–80.
- Shenton ME, Hamoda HM, Schneiderman JS, et al. A review of magnetic resonance imaging and diffusion tensor imaging findings in mild traumatic brain injury. *Brain Imaging Behav* 2012;6:137–92.
- D'Souza MM, Trivedi R, Singh K, et al. Traumatic brain injury and the post-concussion syndrome: a diffusion tensor tractography study. *Indian J Radiol Imaging* 2015;25:404–14.
- Weyer A, Abele M, Schmitz-Hubsch T, et al. Reliability and validity of the scale for the assessment and rating of ataxia: a study in 64 ataxia patients. *Mov Disord* 2007;22:1633–7.
- Smith SM, Jenkinson M, Woolrich MW, et al. Advances in functional and structural MR image analysis and implementation as FSL. *Neuroimage* 2004;23(Suppl 1):S208–19.
- Povlishock JT, Christman CW. The pathobiology of traumatically induced axonal injury in animals and humans: a review of current thoughts. *J Neurotrauma* 1995;12:555–64.
- Alexander MP. Mild traumatic brain injury: pathophysiology, natural history, and clinical management. *Neurology* 1995;45:1253–60.
- Buki A, Povlishock JT. All roads lead to disconnection? Traumatic axonal injury revisited. *Acta Neurochir (Wien)* 2006;148:181–93. discussion 193–194.
- Jang SH. Diagnostic history of traumatic axonal injury in patients with cerebral concussion and mild traumatic brain injury. *Brain Neurorehabil* 2016;9:1–8.
- Povlishock JT. Traumatically induced axonal injury: pathogenesis and pathobiological implications. *Brain Pathol* 1992;2:1–2.
- Yamada K, Sakai K, Akazawa K, et al. MR tractography: a review of its clinical applications. *Magn Reson Med Sci* 2009;8:165–74.